

Evaluation of the clinical and ultrasonographic findings in abdominal disorders in cattle

Başak Kurt*, and Mete Cihan

Department of Surgery, Faculty of Veterinary Medicine, Kafkas University, Kars, Turkey

KURT, B., M. CIHAN: Evaluation of the clinical and ultrasonographic findings in abdominal disorders in cattle. Vet. arhiv 83, 11-21, 2013.

ABSTRACT

In this study, 100 cattle were examined clinically and ultrasonographically in order to identify their abdominal disorders. The importance and advantages of ultrasonography were evaluated by testing the findings of radiography and abdominocentesis in suspicious cases. Examinations revealed that subjects were suffering from omphalitis (n = 30), extraumbilical abscess (n = 22), traumatic reticulitis (n = 14), urolithiasis and bladder rupture (n = 10), traumatic reticuloperitonitis (n = 6), hernia umbilicalis (n = 6), omphalophlebitis (n = 4), urachal fistula (n = 3), abomasum fistula (n = 2), hernia ventralis (n = 2) or ruminal fistula (n = 1). This investigation indicated that clinical symptoms were unspecific and insufficient for definitive diagnosis even though they provided valuable data at first. However, ultrasonography not only provided definitive results, but also dispelled doubts raised by techniques applied in previous or subsequent procedures.

Key words: cattle, ultrasonography, abdominal disorders, diagnosis

Introduction

In recent years, veterinary practice has seen the development and introduction of new methods for diagnostic imaging (ALKAN, 1999; BRAUN, 2003; TAN, 2001). One of these is ultrasonography, which is described as an eye into the abdominal cavity in situations where disorders that are extremely important in cattle cannot be diagnosed with clinical examinations (BATMAZ, 1997; BRAUN, 2004; BRAUN, 2006; GUL, 2002; HAN and CANPOLAT, 2002). In addition, it is also extremely beneficial for confirming diagnosis of the umbilical structure in calves (ELMA and ALKAN, 1998; LISCHER and STEINER, 1993 and 1994; O'BRIEN and FORREST, 1996; WATSON et al., 1994).

The purpose of this study, which was planned on the basis of this information, was to shed light on professional practice and subsequent studies by conducting radiography

*Corresponding author:

Başak Kurt, Department of Surgery, Faculty of Veterinary Medicine, Kafkas University, 36100 Kars, Turkey, Phone: +90 474 242 6836/ 5217; Fax: +90 474 242 6853; E-mail: basakyakin@hotmail.com.tr

and laparotomy in situations required by the findings of clinical and ultrasonography examinations in the diagnosis of abdominal disorders in cattle, and identifying the importance of the ultrasonography examination technique as well as its advantages and limitations in applied situations.

Materials and methods

Material for the study consisted of 100 cattle of varying breeds, ages and genders which were brought to Kafkas University School of Veterinary Medicine Clinics on suspicion of dysfunctional abdominal organs.

Clinical examination was performed with routine materials. The ultrasonography examination was conducted with a "Pie Medical" brand (Model: 100 Falko Vet) ultrasonography device with a 3.5-5.0 MHz convex and 6.0-8.0 MHz linear rectal probe. To prevent artifacts, ultrasonography gel was used. The radiographic examination was conducted with a "Vetox 110-Trophy" brand x-ray device and 30x40 cm film.

After the initial history, in the clinical examination, inspection, palpation, auscultation, percussion and puncture were performed.

The ultrasonography examination was performed while the animals were standing, without sedation and their hair was clipped. In adult cattle, trans-abdominal images were taken through the ventral abdominal wall and the right and left flank with 3.5-5.0 MHz (BRAUN, 2003) and in calves, images were taken with a 5.0 MHz convex probe through the ventral and lateral wall (LISCHER and STEINER, 1993). In adult cattle, the left kidney and bladder were examined trans-rectally with a 6.0-8.0 MHz rectal linear probe (BRAUN, 2004).

In situations where the digestive system was suspected of containing a foreign object, direct graphs were taken in the latero-lateral (L/L) position with a 90-110 kV and 50-60 mAs dose.

In subjects suspected of having a ruptured bladder, samples of abdominal fluid were screened with the spectrophotometric method for urea, uric acid and creatine, in order to define the nature of the fluids and when they were seen together, it was determined whether the sample contained urine.

Results

The study included a total of 100 head of cattle, 47 of which were female and 53 of which were males. Ages ranged from 0-6 months (n = 68), 6-12 months (n = 8), more than 12 months (n = 24). Breeds included Montafon (n = 34), Simmental (n = 22), Native Black Cattle (n = 14), Eastern Anatolia Red (n = 2) and Zavot (n = 2).

As a result of examinations, the following cases were identified: omphalitis (n = 30), extraumbilical abscess (n = 22), traumatic reticulitis (TR) (n = 14), urolithiasis and

bladder rupture (n = 10), traumatic reticuloperitonitis (TRP) (n = 6), hernia umbilicalis (n = 6), omphalophlebitis (n = 4), urachal fistula (n = 3), abomasal fistula (n = 2), hernia ventralis (n = 2) and ruminal fistula (n = 1). However, no pathological symptoms were found in the liver, gall bladder, spleen, omasum or intestines.

Clinical examination

Findings related to the digestive system. Inspection of adult cattle suspected of TR (14) and TRP (6) revealed depression, hunchback stance, groaning and gas-buildup in the rumen. And in all patients, a decrease in appetite and milk yield was learned. Palpation and auscultation showed that rumen movement was absent or decreased in some of the subjects, but was normal in others. It was determined that in acute cases body temperature rose as high as 40 °C. The results of the detector examination were positive.

In the examination of a subject whose left flank had been punctured with a knife due to tympany, it was determined that there was a fistula in the horizontal direction in the region, from which contents of the rumen were leaking, and emphysema in the surrounding tissue.

In the clinical examination of another subject, it was found that the stomach contents were coming out of a lesion in the right ventral of the abdomen. A fistula duct was seen at the level of the last three ribs. The duct ran parallel to the ribs.

Findings related to lesions in the umbilical area. Fifty-nine of the 66 calves, brought in for complaints related to umbilical lesions, had extra-abdominal and 7 were intra-abdominal lesions.

Palpation of 34 subjects suspected of Omphalitis and Omphalophlebitis revealed thickening of the umbilical cord all around or in the cranial direction, with elevated local temperature, and in chronic subjects, there was also ulceration and purulence. Enlargement and fluctuation at the end of the umbilical cord was identified in 22 calves brought in with similar complaints.

A fistula was encountered in the examination of 3 calves in which urine was observed coming from the umbilical area when they assumed the urination position and a fistula oozing a greenish brown substance with a mud-like consistency was found in one subject, who had stomach contents coming from the umbilical area.

In the examination of the other 6 calves, which had swellings in the umbilical area, it was determined that the hot and fluctuating swellings exhibited reducibility in response to pressure.

Hot, fluctuating and painful swellings that exhibited reducibility in response to palpation were found in two of the cattle that had suffered trauma, one in the right inguinal region and one in the left.

Findings related to the urinary system. A hard mass and pain in the post-scrotal region, depression, dehydration and uremia were discovered in the examination of 10 subjects, 8 of which were weaned calves and 2 of which were calves. They were either unable to urinate or were only able to dribble in spite of the fact that they frequently assumed the urination position and had complaints such as extreme pain initially which suddenly disappeared. A clear, yellowish-pink fluid was obtained via abdominal puncture.

Ultrasonography examination

Findings related to the digestive system. The examination of 14 subjects suspected of TR found that the reticulum wall had grown thicker (Fig. 1), organ echogenicity had increased, the number of contractions in 8 of them had decreased and in 6 of them there were no contractions at all. It was also observed that amplitude was decreased in subjects with a reduced number of contractions, intervals between contractions were longer and there were hyperechoic areas that seemed to suggest adhesion to the surrounding tissue.

In 4 of the 6 subjects suspected of TRP, reticular contractions were normal. In one subject, the number of contractions was reduced and the interval between contractions was extended. In the other one, there were no contractions. In subjects with normal reticular contractions, it was determined that the images obtained were not clear, there was increased echogenicity, the contour of the reticulum was irregular and there was a thickening of the walls.

In subjects that had developed rumen fistula, there was increased echogenicity in the region, and hyperechoic areas were accompanied by adhesion. Adhesion focuses were found in the hyperechoic image surrounding the hypoechoic areas in a subject suspected of having an abomasum fistula (Fig. 2). However, no pathological findings were encountered in reticulum examinations performed in the light of possible peritonitis.

Findings related to lesions in the umbilical area. Omphalitis was observed with a thickening of the umbilical cord (Fig. 3), and in acute cases the cord was homogenous and hypoechoic, while in purulent cases, it had a hyperechoic structure.

Omphalophlebitis exhibited cranial thickening of the cord, while homogenous and hypoechoic images were obtained. However, there was hyperechogenic material that filled the lumen of the umbilical veins in purulent subjects.

An anechoic area, touching the umbilical structures in the abdomen, was observed in cases of urachal fistula (Fig. 4). The urachus could be not clearly distinguished at the apex of the bladder. The wall of the bladder had become thicker and the urachus lumen was filled with anechoic contents. In cases of abomasum fistula, the cord was surrounded by a hypoechoic and homogenous structure, with a hyperechoic line, and there were hyperechoic focuses around it (Fig. 5).

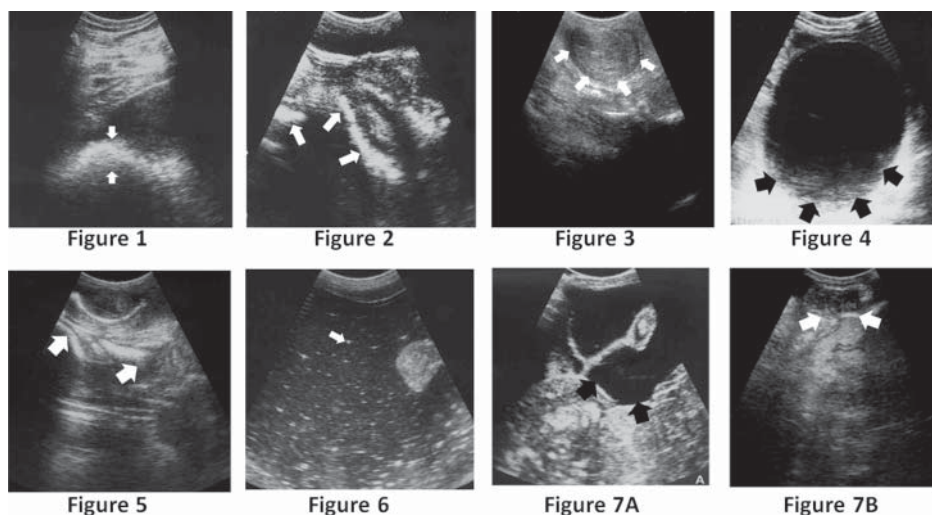


Fig. 1. Thickening of the reticular wall (arrows) in a traumatic reticulitis
Fig. 2. Hyperechoic image (arrows) surrounding hypoechoic areas in the abomasum fistula in a cattle
Fig. 3. Thickening of the umbilical cord (arrows) and homogenous-hypoechoic image in an omphalitis
Fig. 4. Anechoic content (arrows) in urachus lumen in an urachal fistula
Fig. 5. Hypoechoic and homogenous cord and abomasal wall with hyperechoic lines (arrows) in the abomasum fistula in a calve
Fig. 6. Hyperechoic particles (arrow) on the anechoic background and cloudy content in an extraumbilical abscess
Fig. 7. The herniated organ (A) (arrows) and hernial passage (B) (arrows) in the Hernia umbilicalis

Images were obtained of an extra-umbilical abscess with hyperechoic particles on the anechoic background and cloudy content filling the space between them (Fig. 6).

The herniated organ in hernia umbilicalis and ventralis were the intestines, and the wall, lumen, contents and contractions were observed (Fig. 7A). The abdominal fluid in the herniated pouch exhibited an anechoic structure. No hernia passage was identified in hernia ventralis, but it was viewed in one subject with hernia umbilicalis (Fig. 7B).

Findings related to the urinary system. The bladder could not be seen in 8 subjects during the transrectal examination (Fig. 8A) and in 2 subjects a self-repaired bladder was captured in spite of uroabdomen (Fig. 8B). All of the subjects presented an anechoic image during the transabdominal examination (Fig. 8C). Hydronephrosis was researched

as an indirect finding. In this regard, there were findings of enlargement in *Pelvis renalis*, which was unilateral in some and bilateral in others, as well as enlargement and the accumulation of anechoic content in the calyx.

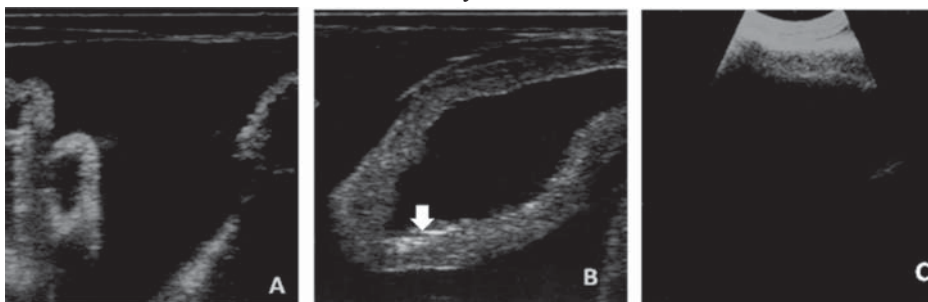

Fig. 8. The bladder could not be seen during the transrectal examination (A) and a self-repaired (arrow) bladder was captured in spite of uroabdomen (B) and anechoic image during the transabdominal examination (C)

Radiographic examination

In six of the subjects suspected of TR and TRP, linear foreign objects with a radiopaque appearance were found on the reticulum floor (Fig. 9), 4 of which were cranial and 4 of which were caudal. Furthermore, the boundaries of the diaphragm had become irregular

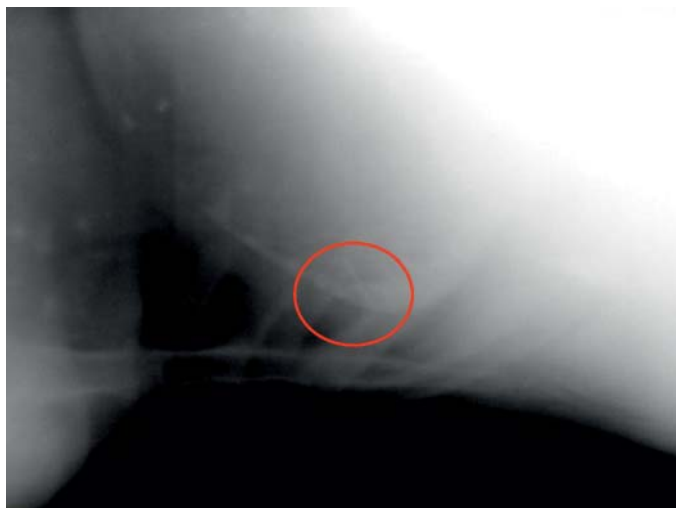

Fig. 9. Foreign body in the vertical direction and view radio-opaque on the reticulum floor

B. Kurt and M. Cihan: Evaluation of the clinical and ultrasonographic findings in abdominal disorders in cattle

in 6 subjects, two of which had an accumulation of sand on the reticulum floor and 4 of which had linear foreign objects with a radiopaque appearance.

Laboratory examination

Biochemical analysis of the fluid aspirated from the abdominal cavity via abdominal puncture was determined to be urine in subjects thought to have urolithiasis complicated by bladder rupture.

Discussion

Abdominal disorders are a frequent occurrence in cattle. Increased expenditure related to negative developments in the diagnostic process, such as treatment before the factors causing the disorder have been identified or misdiagnosis, and the decline in productivity result in significant economic loss. Therefore, the development and application of diagnostic methods that will take the veterinarian to the source of the problem will play a significant role in solving the problems.

TR and TRP, which are known to have a significant impact on animal health and economy, present themselves with clinical findings such as depression, hunchback stance, elevated body temperature, positive response to pain tests and tautness in the abdominal wall. In a similar way, BRAUN et al. (1993) found support for this general view and obtained the same findings in the research they conducted. The absence of typical clinical symptoms makes it difficult to diagnose the chronic form because similar findings are presented in numerous problems, such as abomasum ulcers, pleuritis, pulmonary and hepatic disorders.

For this reason, there is a felt need for additional diagnostic procedures, such as determining the number of total and differential leukocytes with total protein, fibrinogen and gamma globulin concentrations, the glutaraldehyde test, abdominocentesis, use of a detector, exploratory laparoruminotomy, laparoscopy, reticulum radiography and ultrasonography. Laparoruminotomy, laparoscopy, reticulum ultrasonography and radiography are applications with direct diagnostic importance in terms of confirmation. The other methods, on the other hand, only present information that shows the inflammatory process and as a result they are not specific (BRAUN et al., 1994).

The ultrasonography technique is regarded as important for accurately diagnosing reticular apses in particular and for evaluating the localization and dimensions of the apse (BRAUN et al., 1998). However, even though foreign metallic objects located inside or outside the reticulum can be easily viewed with radiography, similar success has not been achieved with ultrasonography (BRAUN et al., 1994). The reason for this is said to be the limitations placed on viewing the contents of the organ by the gas in the reticulum (BRAUN et al., 1993). The linear foreign objects identified with radiography in this study

also could not be observed with this technique, but ultrasonography was able to detect increased organ echogenicity, adhesions to surrounding tissue and the thickening of the reticulum wall, which cannot be determined with radiography and which indicate reticulitis. Another advantage of the technique is that it provides complete information about the contour of the reticulum and makes it possible to view organ motility (BRAUN et al., 1993). Organ contour changes of varying degrees, associated with inflammation, were observed in the subject examined in this study. In addition, contractions were observed and amplitude was reduced with a reduced number of contractions. Contractions were not present, depending on the degree of adhesion, in situations where there was adhesion to surrounding tissues. When they were present, their speed was reduced and the interval between contractions was extended. Furthermore, in cases of TRP, images were not very clear because of widespread inflammatory activity.

In the light of data in the literature and the findings of this study, it could be said that the ultrasonography technique cannot replace the traditional radiography method in the diagnosis of TR and TRP cases caused, in particular, by foreign objects. Neither of these methods seems sufficient for diagnosis on its own.

Ultrasonography of fistula diagnosed as rumen and abomasum did not make any significant contribution to the findings of the clinical examination during this study. In ultrasonography examination performed around the lesion, adhesions with a hyperechoic appearance surrounding a hypoechoic area were found, but the fistula duct could not be viewed clearly. In the review conducted, information regarding the use of the method in fistula examination was only found in the field of human health. Throughout the study, there was only one subject which offered an opportunity to apply the technique and these findings cannot be supported with data from the field of veterinary practice. This was not deemed sufficient to evaluate ultrasonography in terms of these fistulas.

Another area where the ultrasonography technique has been successfully used is umbilical lesions. Since the umbilical cord is potentially a place where pathogens can enter the body during the first days of life, involution should take place as quickly as possible. Involution is delayed or impeded by factors such as: failure to comply with asepsis-antisepsis guidelines during birth, failure to provide the offspring with maternal antibodies, lack of proper care and genetic predisposition. This leads to umbilical lesions and diagnosis is generally based on a physical examination. Ultrasonography is used to confirm the diagnosis.

Ultrasonography examination becomes important, however, in the identification of the herniated organ. In this study, the ultrasonography examination that was conducted revealed a subcutaneous anechoic area which contained segments of the intestines. The walls, lumen and contents of the intestines could be viewed easily, but, with one exception, the hernia passage could not be identified. In a similar study, LISCHER and STEINER

(1994) stated that they were able to view the abdominal fluid and the contents of the hernia pouch, as well as the omentum in hyperechogenic areas that were not connected with each other. In support of this idea, ELMA and ALKAN (1998) reported that viewing the hernia pouch and contents via ultrasonography led to diagnosis in every case they worked on.

The cases of omphalophlebitis and urachal fistula encountered in this study also demonstrated the success of ultrasonography when it comes to intraabdominal umbilical lesions. In the same way, LISCHER and STEINER (1994) reported that even though intraabdominal structures were monitored with palpation, this was not helpful in any of the subjects when it came to definitively describing the degree of infection. In support of the findings of this study, ELMA and ALKAN (1998) stated that only inflamed cords running in the cranio-ventral direction were determined with palpation in omphalophlebitis cases, and that a definitive diagnosis was only reached with ultrasonography.

LISCHER and STEINER (1994) described urachal fistula by saying that a connection existed between the urachus and the bladder. They reported to have viewed the phenomenon via ultrasonography in the subjects they examined for this problem. In this study, on the other hand, the problematic region was included in the screening site and presented a limited anechoic area, integrated with the umbilical structures in the abdomen. In addition, the bladder walls were observed to have thickened and the urachus lumen was full of anechoic content. However, no connection was identified between the bladder and the urachus.

Infections of the urinary system examined within the scope of the research demonstrate the common effects of clinical, laboratory and ultrasonography examinations on the diagnosis. Clinical symptoms are dehydration, swelling in the ventral abdomen with unable urinate, pain in the post-scrotal region upon palpation and a hard mass at the Flexura sigmoidea level. Similarly, VAN METRE (2009) indicated that urethral obstructions in cattle typically occurred at the Flexura sigmoidea level. In all of the cases of urolithiasis encountered, the bladder had ruptured and it was remarkable that the anamnesis of pain, which began with the other symptoms, ended suddenly. The fact that ruptured bladders developed as a complication in cases of urolithiasis was addressed in the article published by ÖZTÜRK et al. (2007) A large amount of fluid was encountered in the abdominal cavity of these subjects, and bio-chemical tests, performed after aspiration through the puncture, determined that it was urine. The accumulation of free fluid with an anechoic appearance in the abdominal cavity was reported by ÖZTÜRK et al. (2007).

A general evaluation demonstrated that clinical evaluation provided important information at the first stage, but was not specific and was insufficient for definitive diagnosis. Ultrasonography, on the other hand, has proven to be reliable and necessary because it provides real time results for the region being viewed, it clarifies or confirms issues raised during procedures performed previously and subsequently, it can reveal other

B. Kurt and M. Cihan: Evaluation of the clinical and ultrasonographic findings in abdominal disorders in cattle

pathological phenomena in the region during the examination other than that focused on by the physician, it can identify treatment options and it makes it possible to forewarn the owners of potential risks. Operations performed at the final stage supported the findings provided by the technique and strengthened the conclusion reached at the end of the study. In addition to the sensitivity and specificity it provides, its practicality and ease of application give it important advantages over other alternatives in the field.

In conclusion, ultrasonography should definitely play a routine role as a complementary procedure, in addition to clinical examination and radiography, because it eliminates certain disadvantages and makes a valuable contribution. This will help identify the most appropriate treatment and also make an important contribution to the economy by preventing unnecessary operations and demonstrating a positive approach to animal well-being.

Acknowledgements

This is a summary of the doctoral thesis entitled "Evaluation of the Findings of Clinical and Ultrasonography Examinations in the Diagnosis of Abdominal Disorders in Cattle" and was supported by the Kafkas University Scientific and Technological Research Commission (2007-VF025).

References

- ALKAN, Z. (1999): *Veterinary Radiology*, 1st ed., Mina Ajans. Ankara. pp. 121-146.
- BATMAZ, H. (1997): *Internal Medicine of Cattle - From Symptoms to Diagnosis, From Diagnosis to Treatment*, 1st ed., Daniş San Ofset. Bursa.
- BRAUN, U. (2003): Ultrasonography in gastrointestinal disease in cattle. *Vet. J.* 166, 112-124.
- BRAUN, U. (2004): Diagnostic ultrasonography in bovine internal diseases. *Proceedings of the 23rd World Buiatrics Congress*, 11-16 July. Quebec City, Canada.
- BRAUN, U. (2006): Therapeutic decision in acute abdominal disorders of the cow. *Proceedings of the 24th World Buiatrics Congress*, 15-19 October. Nice, France.
- BRAUN, U., M. FLÜCKIGER, M. GÖTZ (1994): Comparison of ultrasonographic and radiographic findings in cows with traumatic reticuloperitonitis. *Vet. Rec.* 135, 470-478.
- BRAUN, U., M. GÖTZ, O. MARMIER (1993): Ultrasonographic findings in cows with traumatic reticuloperitonitis. *Vet. Rec.* 133, 416-422.
- BRAUN, U., U. ISELIN, C. LISCHER, E. FLURI (1998): Ultrasonographic findings in five cows before and after treatment of reticular abscesses. *Vet. Rec.* 142, 184-189.
- ELMA, E., F. ALKAN (1998): The diagnosis of umbilical lesions in calves with ultrasonography. *Vet. Cerr. Derg.* 4, 87-91.
- FUBINI, S. L., A. E. YEAGER, H. O. MOHAMMED, D. F. SMITH (1990): Accuracy of radiography of the reticulum for predicting surgical findings in adult dairy cattle with traumatic reticuloperitonitis: 123 cases (1981-1987). *J. Am. Vet. Med. Assoc.* 197, 1060-1064.

- B. Kurt and M. Cihan: Evaluation of the clinical and ultrasonographic findings in abdominal disorders in cattle
- GUL, Y. (2002): Internal Diseases of Ruminants (Cattle, Sheep-Goat). In: Pre-gastric diseases. (Gül, Y., Ed.). Medipress. Ankara. pp 37-116.
- HAN, M. C., I. CANPOLAT (2002): Examination of the structures in normal and diseased of the urinary tract in cattle. F.Ü. Sađ. Bil. Vet. Derg. 16, 199-208.
- LISCHER, C. J., A. STEINER (1993): Ultrasonography of umbilical structures in calves. Part 1: Ultrasonographic description of umbilical involution in clinically healthy calves. Schweiz. Arch. Tierheilkd. 135, 221-230.
- LISCHER, C. J., A. STEINER (1994): Ultrasonography of umbilicus in calves. Part 2: Ultrasonography, diagnosis and treatment of umbilical diseases. Schweiz. Arch. Tierheilkd. 136, 227-241.
- O'BRIEN, R., L. J. FORREST (1996): A retrospective study of umbilical sonography in calves. Vet. Radiol. Ultrasound. 37, 63-67.
- ÖZTÜRK, S., E. KILIÇ, O. AKSOY, I. ÖZAYDIN, S. YAYLA (2007): Ultrasound diagnosis and surgical treatment of bladder ruptures in cattle. Indian Vet. J. 84, 509-511.
- TAN, H. (2001): Diagnostic imaging techniques in veterinary medicine. Vet. Cerr. Derg. 7, 93-94.
- VAN METRE, D. C. (2009): Urolithiasis in ruminants. Proceedings of the 81st Western Veterinary Conference, 15-19 February. Las Vegas, Nevada.
- WATSON, E., M. B. MAHAFFEY, W. CROWELL, B. A. SELCER, D. D. MORRIS, L. SEGINAK (1994): Ultrasonography of the umbilical structures in clinically normal calves. Am. J. Vet. Res. 55, 773-780.

Received: 3 January 2012

Accepted: 6 December 2012

KURT, B., M. CIHAN: Prosudba kliničkih i ultrazvučnih nalaza kod abdominalnih poremećaja u krava. Vet. arhiv 83, 11-21, 2013.

SAŽETAK

Stotinu goveda bilo je pretraženo klinički i ultrazvučno radi dokazivanja njihovih abdominalnih poremećaja. Važnost i prednosti ultrazvučne dijagnostike bili su procijenjeni na osnovi radiografskih nalaza i punkcije abdomena u sumnjivih slučajeva. Pretragom je bilo ustanovljeno da su goveda oboljela od omfalitisa (n = 30), izvanpupčanih apscesa (n = 22), traumatskog retikulitisa (n = 14), urolitijaze i prsnuća mokraćnog mjehura (n = 10), traumatskog retikulo-peritonitisa (n = 6), pupčane hernije (n = 6), omfaloflebitisa (n = 4), urahusne fistule (n = 3), fistule sirišta (n = 2), ventralne hernije (n = 2) ili buražnih fistula (n = 1). Istraživanje upućuje na zaključak da su klinički znakovi bili nespecifični i nedovoljni za postavljanje konačne dijagnoze, iako su u početku davali obećavajuće rezultate. Ultrazvučnom dijagnostikom potvrđeni su konačni nalazi i uklonjene sumnje postavljene pretragom metodama primijenjenima u prijašnjim ili naknadnim pretragama.

Ključne riječi: govedo, ultrazvuk, abdominalni poremećaji, dijagnoza
