

Melanoma of foot in two local goats of Kashmir - a case report

Mujeeb R. Fazili^{1*}, Mohammed M. Darzi², Bashir A. Buchoo³, Hiranya K. Bhattacharyya⁴, and Aubid H. Bhat⁵

¹Teaching Veterinary Clinical Complex (T.V.C.C.), Faculty of Veterinary Sciences and Animal Husbandry (F.V.Sc & A.H.), Sher-i-Kashmir University of Agricultural Sciences and Technology of Kashmir (SKUAST-K), Shuhama-Alusteng, Srinagar, Kashmir, India

²Department of Pathology, F.V.Sc. & A.H, SKUAST-K, Shuhama-Alusteng, Srinagar, Kashmir, India

³SKUAST-K, Shuhama-Alusteng, Srinagar, Kashmir, India

⁴SKUAST-K, Shuhama-Alusteng, Srinagar, Jammu and Kashmir, India

⁵G.B.Pant University of Agriculture and Technology, Pantnagar, Uttranchal, India

FAZILI, M. R., M. M. DARZI, B. A. BUCHOO, H. K. BHATTACHARYYA, A. H. BHAT: Melanoma of foot in two local goats of Kashmir - a case report. Vet. arhiv 83, 105-113, 2013.

ABSTRACT

Two local adult goats were presented with lameness due to a soft tissue, easily bleeding growth over the medial digit of the right forelimb. Radiography did not reveal any bony involvement. The growths were meticulously resected and diagnosed histopathologically as melanomas. Recurrence was noticed two months later in one of these cases.

Key words: goat, lameness, melanoma, growth, metastasis

Introduction

Tumours are uncommon in goats, with an incidence of 0.009% (VALENTINE, 2004). Melanoma, a devastating disease encountered in both humans and animals (SMITH et al., 2002), has been rarely reported in this species (SMITH et al., 2002; ZUBAIDY, 1976; VENKATESAN et al., 1979; VENKATESAN et al., 1979; RAMADAN et al., 1988; RADOSTITS et al., 2007). In this communication we wish to put on record cases of melanoma in two local goats in Kashmir. The growths involved the medial digit of the right forelimb in both the animals.

*Corresponding author:

Dr. Mujeeb-ur-Rehman Fazili, 78-HIG (Lane-6) Colony, near Bemina Telephone Exchange, Bemina, Srinagar, Kashmir, India, Pin-91, 190018, Phone: +91 941 9095 830 (M); E-mail: fazili_mr@yahoo.co.in

Case description

Case 1. A local, brown doe, weighing 35 kg, aged six years, was presented with an extensive raw, easily bleeding, soft tissue growth in the interdigital space and the dorsal aspect of the medial toe of the right forelimb (Fig. 1). Reportedly, a foot-rot like lesion of the affected foot, had been followed by maggot infestation two months ago. The wound had not responded to the routine treatment during the intervening period. The colour of the growth was blackish in the proximal and reddish towards the distal region. The goat was severely lame, keeping the affected limb persistently off the ground. At the time of examination the animal was in her third pregnancy (four months).

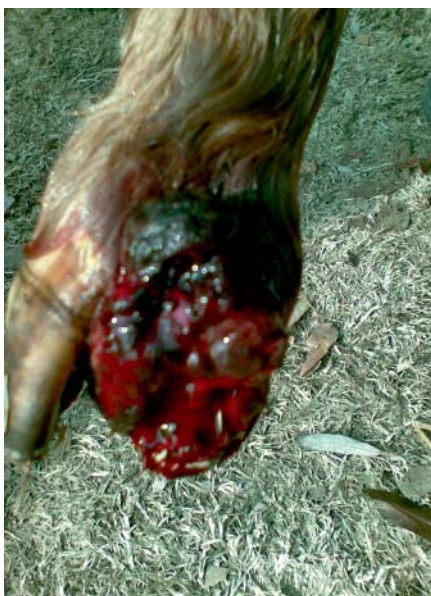

Fig. 1. Case 1. Melanotic foot tumour with a raw, bleeding, reddish surface

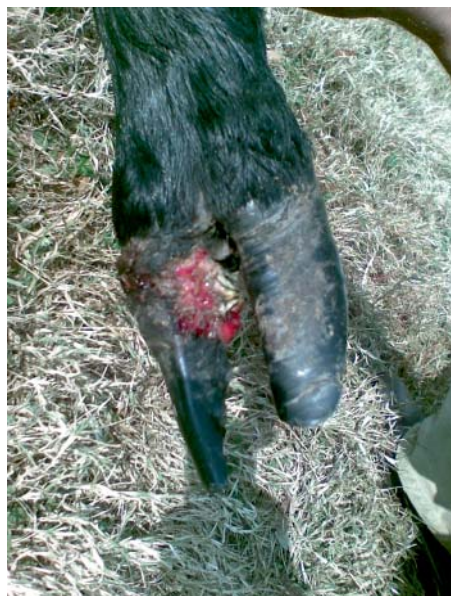

Fig. 2. Case 2. Soft tissue growth, protruding from the interdigital space area and the dorsal surface of the medial claw of right forelimb

Case 2. A local, black, non-pregnant doe, weighing 31 kg, aged four years, showing moderate lameness, was presented four months later from an area 20 kilometers away from the first case, for treatment of a soft tissue, easily bleeding growth, protruding from the interdigital area and the dorsal surface of the medial claw of the right forelimb (Fig. 2). The owner had noticed it spontaneously one month earlier as a small growth that subsequently led to lameness during the previous fortnight. The mass was arising from the medial, dorsal and part of the lateral surface of the medial digit and the hoof was loose.

Both the animals had fair general body condition and apparently were not suffering from any other ailment. Their rectal temperature, 39.4 °C and 39.2 °C (normal range 38.8-40.0 °C), respiration rate, 19 and 27/minute (normal range 15-30/minute), and rumen motility, 1.0 and 1.5/minute (normal range 1.0-1.5/minute), respectively were within the normal range (MATHEWS, 1999). The heart rate in Case 1 was higher (106/minute) than normal (70-95/minute) but not in Case 2 (81 /minute). Hematological examination revealed slightly lower haemoglobin values (7.6 g/dL) in Case 1, but normal 10.5 g/dL (range 8.0-15.0 g/dL) in Case 2. Packed cell volume (PCV) was within the normal range (24-39%) in both the animals.

Plain radiography of the affected foot in both the goats did not reveal any bony involvement.

After twelve hours' fast, the animals were injected with diazepam (Inj. Calmpose, Glaxo, India) 0.1 mg/kg intravenously, as a sedative. They were restrained in left lateral recumbency. Using 5 mL lignocaine hydrochloride (Xylocaine 2%, Astra Zeneca Pharma, India), intravenous regional analgesia (IVRA) was carried out in each animal following the standard technique (HALL et al., 2001). The growths were resected and curetted out to the maximum possible extent. In Case 1, it was found to be originating from an equilateral triangular area (each side one inch) on the medial aspect of the medial digit. In Case 2, the growth had developed all around the coronet region of the medial digit, except the palmar surface, pushing the hoof distally.

The wound surfaces were sprinkled with potassium permanganate crystals to cauterize them and they were bandaged tightly before release of the tourniquet. Thereafter, the wounds were managed routinely with parenteral antibiotic, analgesic and local antiseptic dressings to achieve second intention healing. Case 1 was additionally administered 1 mL of hematinic: iron sorbitol (50 mg), folic acid (500 mcg) and vitamin B₁₂ (50 mcg) (Inj. Ferritas, Intas Pharmaceuticals Ltd. India) intramuscularly.

The wounds in both the does healed within a fortnight and the lameness vanished. The attachment of the hoof in case 2 gained strength in the subsequent fortnight. The animals were examined fortnightly for recurrence of the growth and metastasis.

Immediately after resection, the recovered tissues were sent to the division of Pathology for histopathological evaluation. They were preserved in 10% formal saline and paraffin sections were stained with haematoxylin and eosin stains. Duplicate sections were stained by the Masons-Fontana method for demonstration of melanin (CHURUKIAN, 2002). The mitotic index was calculated by observing the total number of mitotic figures per ten high-power fields (HPF).

Histopathologically, both the tumors were diagnosed as melanomas. Case 1 consisted of spindle to round cells arranged in a lobular pattern, with evidence of rich

neovascularization. Some of the cells revealed dark pigment and pleomorphism (Figs 3 and 4), which proved positive for melanin by the Masons-Fontana method. The stroma was infiltrated with mononuclear cells. In Case 2, neoplastic cells were seen either in sheets or small groups, or were individually interspersed by fibrovascular stromal elements (Figs 5 and 6). The neoplastic cells revealed nuclei showing hyperchromatism and some pleomorphism. The mitotic figures were atypical and the index ranged from 2 to 3 in both the cases.

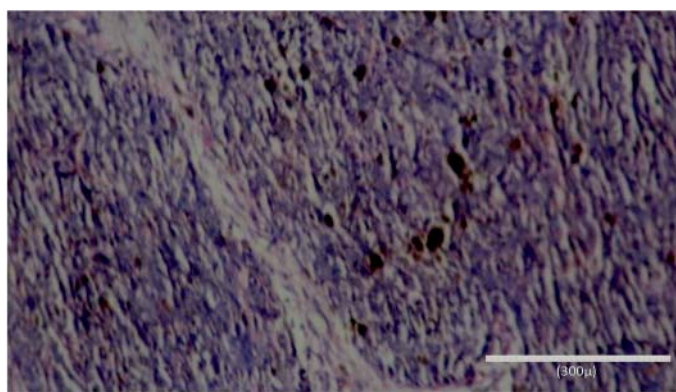


Fig. 3. Section of melanoma of Case 1 showing neoplastic cells separated by connective tissue stroma. Some cells revealed melanin pigment. H&E; $\times 280$.

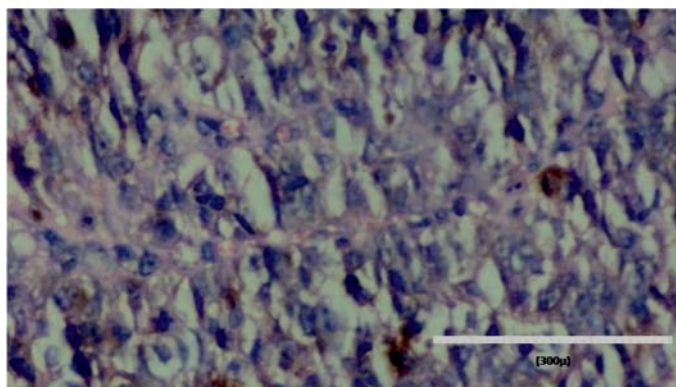


Fig. 4. Higher magnification of section of melanoma of Case 1 showing pleomorphic neoplastic cells, neovascularisation and atypical mitosis (arrow). H&E; $\times 400$.

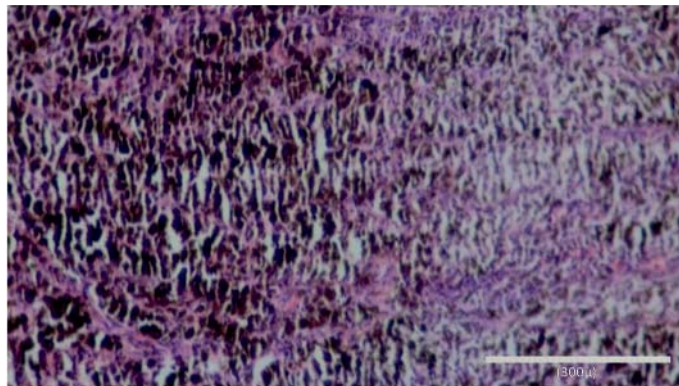


Fig. 5. Section of melanoma from Case no 2 showing melanin laden neoplastic cells arranged in sheets and interspersed by scarce connective tissue. H&E; $\times 280$.

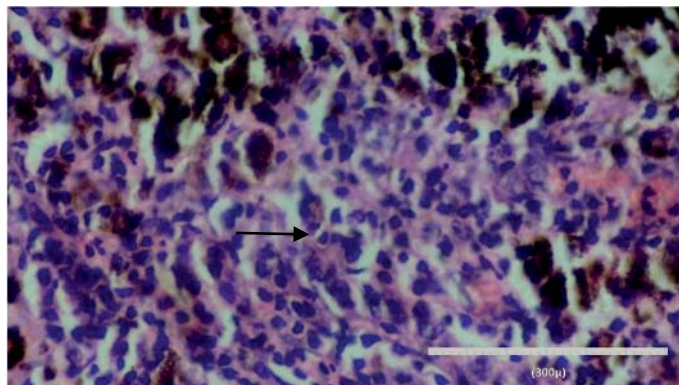


Fig. 6. Higher magnification of melanoma of Case 2 showing melanin laden neoplastic cells with atypical mitosis (arrow) and cellular pleomorphism 18. H&E; $\times 400$.

Case 1 kidded normally but recurrence of the growth at the same site was noticed two months later. At the time of examination, the animal was active and indications of metastasis at any other site were not detected. The owner disposed off the animal without further treatment. Case 2 healed completely and no recurrence at the same or any other site was noticed during an observation period of one year.

Discussion

Melanomas arise from specialized cells containing melanin (melanoblasts) situated in the stratum germinativum of the epidermis. Initially the epidermis overlying the tumor may be intact, but becomes ulcerated with rapidly growing tumors (WHITE et al., 2002). They may occur as solitary (BABIC et al., 2009) or multiple lesions. Neoplasms in goats are rare, in comparison with other species of animals (ZUBAIDY, 1976). A survey of 800,000 slaughtered goats revealed only 70 neoplasms, 5 of which were melanomas (BRADLEY and MIGAKI, 1963). In another study, three sets of (27.3%) biopsy materials out of 11 goats suffering from neoplasms were melanomas (DAMODARAN and PARTHASARTHY, 1972).

The causes of melanomas are uncertain. In humans, risk factors such as race, lack of skin pigmentation, excessive exposure to sunlight, and the presence of pre-existing nevi have been described (MADEWELL and THEILEN, 1987). Risk factors for melanomas in most domestic animals have not been fully described. In horses, the loss of melanin pigment with age and a tendency to develop on animals with grey or white hair coats have been identified as risk factors (MADEWELL and THEILEN, 1987). Both of our animals were nondescript local females and had normal hair coats. One of them was dark black and the other brown in colour. Some reports suggest that dark-skinned and hairy goats are more often affected (VENKATESAN et al., 1979; RADOSTITS et al., 2007). A white coloured, Saanen × Nubian goat affected with melanoma of coronary band was reported earlier (SOCKET et al., 1984). Other domestic animals in which melanomas are associated with dark skin include cattle, sheep, pigs, and dogs (RADOSTITS et al., 2007; MADEWELL and THEILEN, 1987). Conversely, several cases of cutaneous melanomas have been reported in Angora goats that were predominantly white (PARSONS et al., 1990). Additionally, in these goats, the sites of occurrence tend to be sparsely covered with hair, such as the ear, face, anus, vulva, tail, and udders (VENKATESAN et al., 1979; PARSONS et al., 1990; GREEN et al., 1996). Some reviews suggest that the occurrence of melanomas in Angora goats is secondary to mutations induced by ultraviolet solar radiation (SMITH et al., 2002; GREEN et al., 1996).

Both the goats of our study were adult (6 and 4 years respectively) females. Their age and sex were similar to the animals reported earlier (DAMODARAN and PARTHASARTHY, 1972; SOCKET et al., 1984). Melanomas are most often seen in female goats in the age range of 4 to 5 years (RAMADAN et al., 1988). However, in one report, a Pygora goat aged 11 years suffered from melanoma of the horn base (MAVANGIRA et al., 2008).

Both the goats presented to us were in fair condition and most of their physiological parameters were within the normal range for the species. Mild anaemia detected in Case 1 could have been due to repeated blood loss from the raw surface of the growth. VALENTINE (2004) reported that poor body condition is common in goats with melanomas.

Surprisingly, the tumor had developed at the coronary band of the medial digit of the right fore-limb in both the cases. Due to the few reported cases of melanoma in goats, it is impossible to know whether the coronary band region is predisposed to tumor involvement (SOCKET et al., 1984). In addition to the coronary band of the hoof (VENKATESAN et al., 1979; DAMODARAN and PARTHASARTHY, 1972; SOCKET et al., 1984), skin, udders and the horn base have been reported as primary sites for malignant melanomas in goats (DAMODARAN and PARTHASARTHY, 1972; MAVANGIRA et al., 2008; THOMAS, 1929).

The IVRA technique resulted in satisfactory analgesia in both the goats. Application of a tourniquet minimized intra-operative haemorrhage from the surgical site. The growths were excised meticulously to minimize the chances of leftover tissue. Surgical excision, the oldest method in the armamentarium of the fight against cancer, is still considered the treatment of choice (MAVANGIRA et al., 2008).

One of the goats showed recurrence of the growth at its previous site. Recurrence following surgical excision has not been evaluated (RAMADAN et al., 1988). Prognosis of malignant melanomas in goats is guarded to poor (RAMADAN et al., 1988) or grave (SMITH et al., 2002). Reportedly, melanomas of goats are highly malignant, locally aggressive, and commonly metastasize to other organs via the lymphatics and the blood stream (VALENTINE, 2004; SMITH et al., 2002; RAMADAN et al., 1988; SOCKET et al., 1984; SCOTT, 1988). Tumors arising on the digits and on mucocutaneous junctions are reported to be more aggressive and behave in a similar manner to oral melanoma (MORRIS and DOBSON, 2001). However, in the present cases no lymphadenopathy or enlargement of the ipsilateral regional lymph nodes was detected, denoting locally aggressive nature of the tumors. Common sites for metastasis include regional lymph nodes, lungs, and liver, but other sites of distant metastasis have also been reported (VALENTINE, 2004; RAMADAN et al., 1988; SOCKET et al., 1984).

References

- BABIC, T., Z. GRABAREVIC, S. VUKOVIC, J. KOS, D. MATICIC (2009): Congenital melanoma in a 3-month old bull calf - a case report. *Vet. Arhiv* 79, 315-320.
- BRADLEY, P. J., G. MIGAKI (1963): Types of tumors found by Federal meat inspectors in an 8year survey. *Ann. N. Y. Acad. Sci.* 108, 872-879.
- CHURUKIAN, C. J. (2002): Masson-Fonta method for melanin In: *Theory and Practice of Histological Technique*. (Bancroft, J. D., M. Gamble, Eds.), 5th ed., Churchill Livingstone, London, p. 252.
- DAMODARAN, S., K. R. PARTHASARTHY (1972): Neoplasms of goat and sheep. *Indian Vet. J.* 49, 649-652.
- GREEN, A., R. NEALE, R. KELLY, I. SMITH, E. ABLETT, B. MEYERS, P. PARSONS (1996): An animal model for human melanoma. *Photochem. Photobiol.* 64, 577-580.

- HALL, L. W., K. W. CLARKE, C. M. TRIM (2001): Anaesthesia of sheep, goat and other herbivores. In: *Veterinary Anaesthesia*. 10th ed., London, W.B. Saunders, p. 236, 344-345.
- MADWELL, B. R., G. H. THEILEN (1987): Mast cell and melanocytic neoplasms. In: *Veterinary Cancer Medicine*, Madwell BR, Theilen GH. 2nd ed., Philadelphia, PA: Lea and Febiger, pp. 315-322.
- MATHEWS, J. (1999): Appendix 1: The normal goat. In: *Diseases of the Goat*. 2nd ed., Chelmsford, UK: Blackwell Science, pp. 328-333.
- MAVANGIRA, V., J. M. HUGHES, J. R. MIDDLETON, W. H. MITCHELL, D. Y. KIM (2008): Malignant melanoma of the horn base in a Pygora goat. *J. Vet. Diagn. Invest.* 20, 104-107.
- MORRIS, J., J. DOBSON (2001): *Small Animal Oncology*. 1st ed, Blackwell Science Ltd. p. 58
- PARSONS, P. G., H. TAKAHASHI, J. CANDY, B. MEYERS, J. VICKERS, W. R. KELLY, I. SMITH, P. SPRADBROW (1990): Histopathology of melanocytic lesions in goats and the establishment of a melanoma cell line: a potential model for human melanoma. *Pigment Cell Res.* 3, 297-305.
- RADOSTITS, O. M., C. C. GAY, K. W. HINCHCLIFF, P. D. CONSTABLE (2007): *Veterinary Medicine: a Textbook of the Diseases of Cattle, Horses, Sheep, Pigs and Goats*, 10th ed., Philadelphia, PA: Saunders, Elsevier, p. 387.
- RAMADAN, R. O., A. M. EL HASSAN, DEEN TAJ EL (1988): Malignant melanoma in goats: a clinico-pathological study. *J. Comp. Pathol.* 98, 237-246.
- SCOTT, D. W. (1988): Neoplastic diseases. In: *Large Animal Dermatology*, (Pederson D., Ed.) Philadelphia, PA: W. B. Saunders. pp. 448-452.
- SMITH, S. H., M. H. GOLDSCHMIDT, P. M. MCMANUS (2002): A comparative review of melanocytic neoplasms. *Vet. Pathol.* 39, 651-678.
- SOCKET, D. C., A. P. KNIGHT, L. W. JOHNSON (1984): Malignant melanoma in a goat. *J. Am. Vet. Med. Assoc.* 185:907-908.
- THOMAS, A. D. (1929): Skin cancer of the Angora goat in South Africa. In: *Department of Agriculture, Onderstepoort, 15th Annual Report of the Director of Veterinary Services, Pretoria. The Government Printer, Pretoria, South Africa.* p. 661-686.
- VALENTINE, B. A. (2004): Neoplasia. In: *Farm Animal Surgery*. Fubini SL, Ducharme NG, 1st ed., St Louis: Saunders, p. 25-26.
- VENKATESAN, R. A., S. C. NANDY, M. SANTAPPA (1979): A note on the incidence of melanoma on the goat skin. *Indian J. Anim. Sci.* 49, 154-156.
- WHITE, S. D., A. G. EVANS, D. C. VAN METRE (2002): Melanoma. In: *Large Animal Internal Medicine*, (Smith B.P., Ed.), 3rd ed., St Louis, M.O., Mosby, p. 1225-1226.
- ZUBAIDY, A. J. (1976): Caprine neoplasms in Iraq: case reports and review of the literature. *Vet. Pathol.* 13, 460-461.

Received: 18 November 2011

Accepted: 5 December 2012

FAZILI, M. R., M. M. DARZI, B. A. BUCHOO, H. K. BHATTACHARYYA, A. H. BHAT: Melanom papka u dvije koze - prikaz slučaja. Vet. arhiv 83, 105-113, 2013.

SAŽETAK

U dvije koze ustanovljena je hromost zbog promjena u mekom tkivu i izrasline s obilnim krvarenjem u području unutarnjeg papka prednje desne noge. Radiografski nisu bile ustanovljene promjene na kostima. Izrasline su bile pažljivo uklonjene te je patohistološki utvrđen melanom. U jedne koze melanom se ponovo javio dva mjeseca nakon odstranjivanja.

Ključne riječi: koza, hromost, melanom, novotvorina, metastaze
