

# Morfologija kao temelj dentalne identifikacije: prikaz slučaja

Hrvoje Brkić  
Jadranka Keros-Naglić

Zavod za dentalnu antropologiju  
Stomatološki fakultet  
Sveučilišta u Zagrebu

## Sažetak

*Odontogeneza trajnih zuba pretežito pripada postnatalnom razvoju i traje više godina. Nakon rođenja djetetov je organizam i sva njegova tkiva u mnogo dinamičnijem suodnošaju s izvanjskom sredinom nego u razdoblju intrauterinog života. Time se stvaraju uvjeti da mnogi izvanjski čimbenici utječu na formativnu djelatnost zubnog organa. Poremećaji u razvoju zuba koji nastaju u razdoblju morfološke diferencijacije mogu se očitovati i kao fuzija zuba.*

*Fuzionirani su zubi osebujnog izgleda te mogu stvarati estetski ne sklad ili, zbog povećanog mezio-distalnog promjera, utjecati na svekoliku morfološku zubnoga luka.*

*U radu je prikazan slučaj uspješne identifikacije žrtve Domovinskoga rata iz godine 1991. ekshumirane 1995. iz masovne grobnice u Petrinji temeljem nalaza fuzioniranih zuba, odgovarajućih podataka dobivenih od rodbine, te nekolicine dodatnih materijalnih dokaza koji su našu tvrdnju još podkrijepili.*

**Ključne riječi:** fuzija, morfološki zubi

Acta Stomatol Croat  
1999; 359—362

PRIKAZ SLUČAJA  
Prilježeno: 12. srpnja 1999.

Adresa za dopisivanje:

Doc.dr.sc. Hrvoje Brkić  
Zavod za dentalnu antropologiju  
Stomatološki fakultet  
Sveučilišta u Zagrebu  
Gundulićeva 5, 10000 Zagreb

Razvoj zuba dugotrajan je i zamršen proces koji ne mora uvijek imati uvriježen tijek i čije osobitosti mogu uzrokovati nastanak raznih nepravilnosti. U mliječnim zuba odontogeneza djelom pripada intrauterinom razvoju, a djelom razdoblju nakon rođenja. Trajno se pak zubalo razvija pretežito nakon rođenja.

Nepravilnosti mogu nastati u svakom stupnju zubnoga razvoja (inicijacija, profileracija, histologijska i morfološka diferencijacija, apozicija, mineralizacija).

Promjene oblika zuba nastaju, primjerice, u razdoblju morfološke diferencijacije, a nepravilna oblika može biti cijeli zub ili su izobličeni samo nje-

govu pojedini dijelovi. Nepravilnosti oblika jesu: mikrodoncija, makrodoncija, fuzija, geminacija, konkrescencija, taurodontizam, Hutchinsonovi sjekutići, malinasti kutnjak, šiljasti lateralni sjekutić, palatinalni žlijeb, paramolarne kvržice, *dens in dente* (*dens invaginatus*), Carabellijeva kvržica, izrazito povećan opseg zubnoga vrata, pandžasti zubi, hipoplastični defekti, te ostala izobličena.

Među nepravilnosti oblika zuba ubrajamo i fuziju dvaju susjednih zametaka tijekom njihova razvoja, a prije mineralizacije (1,2,3). Mogući su etiološki čimbenici fuzije: tlak uvjetovan manjkom prostora što dva susjedna zuba dovodi u doticaj i uvjetuje njihovo spajanje, zaostajanje dentalne lami-

ne, poremećaji metabolizma, manjak hormona i vitamina. Pojedini pak istraživači drže kako je fuzija dominantno nasljedna anomalija s reduciranom penetracijom gena (4,5,6.).

Ovisno o vremenu i o razvojnoj fazi u kojoj je nastalo stapanje, zubi mogu biti stopljeni cijelom dužinom i svim dijelovima, pa je riječ o pravoj fuziji. Nepotpuna se stapanja očituju samo u području zubne krune (što je razmjerno rijetkost) ili samo u području zubnoga korijena pa govorimo o konkrescenciji korijena (7,4,8,9).

Prigodom fuzije najčešće su sljedeće kombinacije:

1. Fuzija dvaju susjednih zuba u nizu, pa u tom segmentu manjka jedan zub. Diferencijalno dijagnostički valja pomisliti na geminaciju jednog uz nedostatak (hipodonciju) susjednoga zuba.
2. Fuzija normalnoga zuba s prekobrojnim zubom, pa je broj zuba normalan. Diferencijalno dijagnostički mogućnost je geminacije jednoga zuba.
3. Fuzija dvaju prekobrojnih zuba, pa je u tome segmentu jedan zub više. Diferencijalno dijagnostički valja pomišljati na geminaciju jednoga prekobrojnoga zuba.

Oblik fuzioniranih zuba sličan je onom u geminacije, tj. povećan je mezio-distalni promjer zubne krune s urezom na griznome bridu i brazdom na vestibularnoj i oralnoj površini, što dijeli krunu na dva nejednaka dijela. Pri geminaciji se za razliku od fuzije na rendgenskoj snimci vide jedna pulpna šupljina i jedan korijenski kanal. Ako se fuzionirani zubi računaju kao jedan, tada u tom segmentu nedostaje jedan zub pa postoji slika prirođenog manjka zuba, odnosno hipodoncije (10,11,12,13).

Fuzija je češća pojava u mliječnome nego u trajnome zubalu. U trajnoj denticiji pojavljuje se u 0,5 do 2,5 osoba, a najčešće se, kao u našem primjeru, fuzija javlja u području sjekutića, jednostrano ili obostrano, a u našem je primjerku bilo jednostrano. Pri tome su najčešće po dva zuba stopljena pod kutom od 140° do 150°, rjeđe se nalazi i fuzija triju zuba (14,15).

### Prikaz slučaja

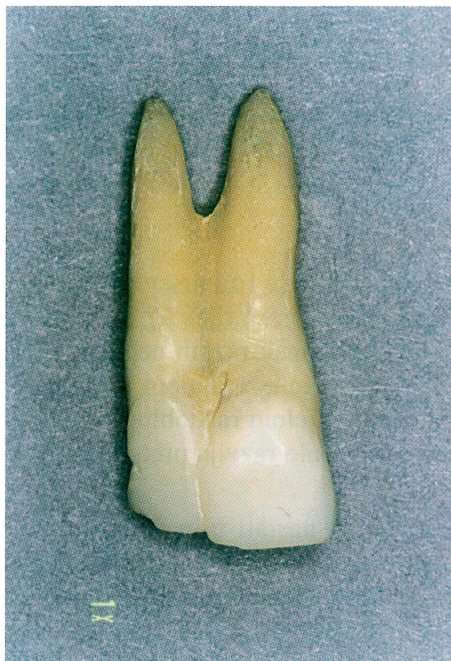Tijela ljudi ubijenih tijekom godine 1991. na području Hrvatske dijelom su ekshumirana iz masov-

nih grobnica 1995. Među najvećim grobnicama s više od dvadeset ekshumiranih trupla jest pronađena u Petrinji. U identifikaciji žrtava sudjelovao je i stomatolog, član tima za identifikaciju iz Zavoda za dentalnu antropologiju Stomatološkog fakulteta Sveučilišta u Zagrebu. Zubi su se pri identificiranju ubijenih ljudi pokazali vrlo važnim. Identifikaciju jednog ubijenog mladića u toj skupini omogućilo je vrlo rijetko dentalno obilježje.

Premortalni podatci dobiveni od rodbine upućivali su na zdravo i bijelo zubalo s postojanjem "dvostrukoga zuba", veliki zub. U Zavodu za sudsku medicinu i kriminalistiku Medicinskog fakulteta Sveučilišta u Zagrebu dopremljeno je muško truplo u kojega su dentalna obilježja upućivala na dobivene podatke, a nalaz su potkrijepili još neki dodatni materijalni dokazi.

Dvostruki zub 21+22 gornjega desnog kvadranta u nizu između prvoga lijevog središnjeg sjekutića i gornjega desnog očnjaka izvađen je iz usne šupljine uz pristanak rodbine, te rendgenski i odontometrijski istražen.

Izvađeni je zub 22 tijekom 48 sati uronjen u 3% vodikov peroksid, a potom u 10% otopinu formalina. Nakon nekoliko dana zub je rendgenski snim-



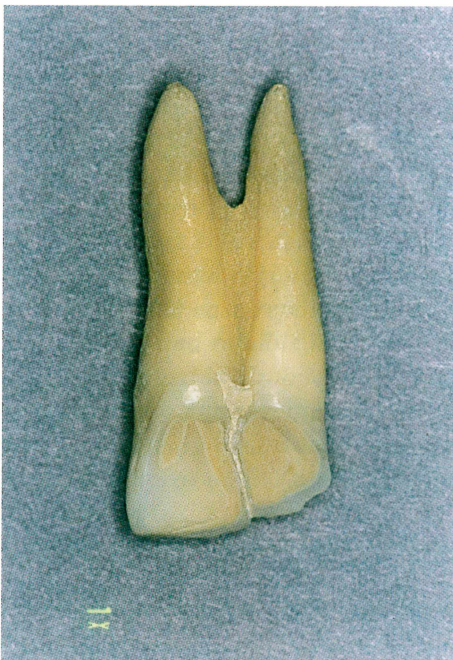Slika 1. Fuzija 21 i 22 promatrana s vestibularne strane  
Figure 1. Fusion of 21 and 22 seen from the vestibular side



Ijen postupkom male intraoralne snimke s dugim konusom, a zatim je dijagnosticirana ta rijetka dentalna anomalija.

Morfološki se zub 22 doima podijeljenim na dva međusobno nejednolika zuba, pri čemu je medijalni veći od distalnoga. Zub, koji inače spada u genetski labilne zubne jedinice, anatomski gledano ima dvije nejednake krune i dva nejednaka korijena (Slika 1).

Zubne su krune odijeljene uzdužnom brazdom koja je uočljiva i s labijalne i s oralne strane. Jasno su izražena dva korijena, što potvrđuje njihovu odvojenost pri razvoju te na njihovo kasnije stapanje (konkrescenciju) nastalo povećanim nakupljanjem cementa tijekom žrtvina života (Slika 2).

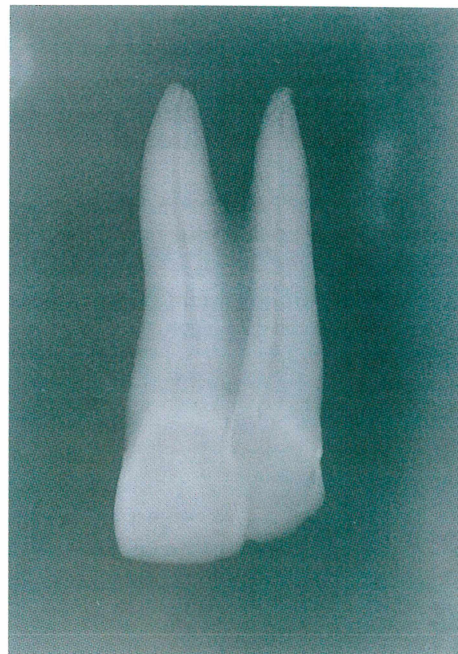


Slika 2. Fuzija 21 i 22 promatrana s oralne strane  
Figure 2. Fusion of 21 and 22 seen from the oral side

Stapanje je krune dakle nastalo u fazama razvoja zuba (histodiferencijacija), dok je srašćavanje korijena nastalo kasnije tijekom života.

Raščlamba endodoncijskih prostora potvrđuje dva posve odvojena endodoncijska sustava oblikovana iz dviju pulpnih komora i dvaju korijenskih kanala.

Sva nabrojena obilježja otklanjaju geminaciju kao moguću dentalnu anomaliju (Slika 3).



Slika 3. Rendgenska snimka stopljenih zuba 21 i 22  
Figure 3. X-ray scan of the tooth by using the technique of small intraoral scanning with long cone

Postojanje spomenute anomalije imalo je presudno značenje da se točno i pouzdano identificira ta žrtva rata tijekom godine 1991. ekshumirane iz masovne grobnice u Petrinji 1995. godine.

Specifičnosti morfološkog izgleda zubala opisane žrtve nedvojbeno je potvrdila njezin pravi identitet, što je dodatnim nalazima nekih materijalnih dokaza samo potkrijepljeno.

## Literatura

1. PRINDBORG JJ. Pathology of dental hard tissues. Copenhagen: Munksgaard 1970:47-58.
2. LEVITAS TC. Geminatio, fusio, twinning and concrecence. ASDC 1965;32:93-100.
3. CAMM JH, WOOD AJ. Geminatio, fusio and supernumerary tooth in the primery dentition; report of a case. ASDC 1989;56:60-61.
4. DIXON GH, STEWART RE. Genetic aspect of tooth anomalies development. St Louis: Mosby 1976.
5. STEWART RE, BARBER TK, TROUTAN KC et al. Pediatric dentistry. St Louis: Mosby 1982:91-105.
6. BROOK AH, WINTER GB. Double teeth: a retrospective study of "geminated" and "fused" teeth in children. Br Dent J 1970;129:123-130.

7. YUEN SWS, CHAN JCY, WEI SHS. Double primary teeth and their relationship with their permanent successors. *Pediatr Dent* 1987;9:42-52.
8. CROLL TP, RAINS NJ, CHEN E. Fusion and gemination in one dental arch: Report of a case. *Asdc* 1981;48:279-2299.
9. NIK-HUSSEIN NN. Bilateral symmetrical fusion of primary and permanent mandibular lateral incisors and canines. *J Pedod* 1989;13:378.383.
10. DUNCAN WK, HELPIN ML. Bilateral fusion and gemination: a literature analysis and case report. *Oral Surg Oral Med Oral Pathol* 1987;64:82-87.
11. KELLY JR. Gemination, fusion or both. *Oral Surg Oral Med Oral Pathol* 1978;45:655-666.
12. EIDELMAN E. Fusion of maxillary primary central and lateral incisors bilaterally. *Pediatr Dent* 1981;3:346-347.
13. KILLIAN CM, CROLL TP. Dental twinning anomalies: the nomenclature enigma. *Quintessence Int* 1990;21:571-576.
14. REISEINBERGER RE, KILLIAN CM. Triplication and twinning in one dental arch: report of a case. *Quintessence Int* 1990;21:621-623.
15. ŠUTALO J, HULJEV S, LEDIĆ B, ANIĆ I. Fusion and gemination of the permanent teeth. *Acta Stomatol Croat* 1993;27:195-198.



# Tooth Morphology as the Basis of Dental Identification: Case Report

Hrvoje Brkić  
Jadranka Keros-Naglić

Department of Dental  
Anthropology  
School of Dental Medicine  
University of Zagreb

---

## Summary

*Odontogenesis of permanent teeth in its major part belongs to the process of postnatal growth and continues for many years following the birth of an individual. After the child is born her or his organism and all the tissues establish a much more dynamic relationship with the external environment than they do during intrauterine life. In this way conditions are made for numerous external factors to affect the formation activity of tooth organs. Disorders in the development of teeth and other structures within the oral cavity may occur at any stage of organogenetic growth. Fused teeth, apart from their causing aesthetic impairment, may on account of their enlarged mesiodistal diameter affect the entire dental arch morphology and cause compression of the front dental region, rotation and malposition of the approximate teeth. In this case report the presence of such an anomaly facilitated accurate and reliable identification of a victim killed during 1991. when war raged in Croatia, and exhumed from the mass grave in Petrinja in 1995. The specific morphological shape of the victim's dentition undoubtedly contributed to accurate identification of this young male, which was additionally substantiated by other available material evidence.*

Key words: *fusion, tooth morphology*

---

Acta Stomatol Croat  
1999; 363—365

CASE REPORT  
Received: July 12, 1999

Address for correspondence:

Doc.dr.sc. Hrvoje Brkić  
Department of Dental  
Anthropology  
School of Dental Medicine  
University of Zagreb  
Gundulićeva 5, 10000 Zagreb  
Croatia

---

## Introduction

Development of dentition is a long and complex process that need not always take a regular course and its characteristics may cause various anomalies. With regard to deciduous teeth their odontogenesis partially belongs to intrauterine development and partially to postnatal growth. Permanent teeth develop as a rule after the birth of an individual.

Abnormalities may occur at any stage of dental development (initiation, proliferation, histological

and morphological differentiation, apposition, mineralisation). Changes in the form of the teeth may occur during morphological differentiation when either the whole tooth or only parts of it may acquire irregular shapes. The following irregularities are among the most common: microdontia, macrodontia, fusion, gemination, concrescence, taurodontism, Hutchinson's incisors, raspberry or mulberry molars, conical lateral incisors (peg teeth), palatal groove, paramolar prominence, dens invaginatus (dens in dente), carabelli tubercle (or cusp), markedly enlarged

ged dental neck volume, claw teeth, hypoplastic defects, and other anomalies.

Fusion or union of two approximating tooth germs in the course of their development, prior to the process of mineralisation, is also considered a dental abnormality (1-3). The following are among etiological factors of teeth fusion: pressure caused by insufficient space because of which two neighbouring teeth become too close during their growth - which eventually leads to their fusion, delay of dental lamina, metabolic disorders, deficient hormone production and lack of vitamins. However, a great number of authors are of the opinion that fusion is a dominant heritable abnormality with reduced genetic penetration (4-6).

Depending on the stage of development during which fusion has occurred the teeth may be fused along their entire length and in all their segments, which is referred to as true fusion. Incomplete fusion indicates union in the crown region (which is a rare case), or only in the root region and is referred to as concrescence of the roots (4,7-9).

In fusion defects the following combinations have usually been noticed:

1. Fusion of two approximating teeth in sequence: in this segment one tooth is missing. In differential diagnosis gemination of one tooth and absence (hypodontia) of the neighbouring one should be taken into consideration.
2. Fusion of a normal tooth with a supernumerary one, so that the total number of teeth is normal. In differential diagnosis the gemination of only one tooth should be taken into account.
3. Fusion of two supernumerary teeth producing one supernumerary tooth should be considered.

The shape of a fused tooth is similar to the shape of a geminated one, i.e. it has an enlarged mesiodistal diameter of the dental crown with an incision in the biting edge and a groove in the vestibular and oral surface dividing the crown into unequal parts. In gemination, as opposed to the fusion process, the x-ray scan shows one pulp cavity and one root canal. If the fused teeth count as one then there is one missing tooth in this segment and is similar to the natural absence of a tooth, or hypodontia (10-13).

Fusion occurs more commonly in deciduous than in permanent dentition. In permanent teeth, as in our case, fusion usually takes place in the region of the

incisors, either on one side or bilaterally: ours was a unilateral case of fusion. During the process two teeth are usually fused together at an angle of 140 to 150 degrees. The fusion of three teeth is an extremely rare case (14,15).

### Case report

The bodies of people killed during the 1991 war in Croatia were exhumed to some extent from mass graves in 1995. One such mass grave, containing more than twenty bodies, was recently found in the town of Petrinja. In the identification of victims a forensic odonto-stomatologist was also included as a member of the identification team, acting on behalf of the Zagreb University School of Dental Medicine, Department of dental Anthropology. During the identification process of war victims teeth have proved of great importance as essential identification factors. A rare dental feature made it possible to identify a young man, one of the victims found in the Petrinja mass grave.

Premortal history obtained from his relatives indicated that the man had healthy white dentition with the presence of "double tooth" (incisors). At the Department of Forensic medicine and Criminology School of Medicine University of Zagreb the body the young male was identified in whom dental features corresponded to the obtained information and the finding was further substantiated by additional material evidence.

After obtaining the informed consent of the relatives, the double tooth (22) in the upper right canine was removed from the oral cavity. W-ray scanning and odontometric examination were then performed. The extracted tooth (22) was suspended for 48 hours in 3% hydrogen peroxide and after words in 10% formaline solution. After a few days, an x-ray scan was made of the tooth by using the technique of small intraoral scanning with long cone. The image showed a rare dental abnormality (Figures 1,2,3).

Morphologically (22), the tooth appeared to be divided into two unequal teeth, with the medial tooth being larger than the distal one. The tooth, otherwise considered a genetically unstable dental unit, from the anatomical point of view has two unequal crowns and two unequal roots.



The dental crowns are divided by a longitudinal furrow that may be seen from both the labial and the oral sides. Two roots are seen quite clearly, indicating their separate development and later concrescence, resulting from excessive deposits of cementum during the victim's lifetime. The fusion of crowns took place in the course of different deve-

lopmental stages of the teeth (histodifferentiation), while the fusion of the roots occurred later in life. The analysis of endodontial spaces shows two entirely separated endodontial systems formed out of two pulp chambers and two root canals. All of the above described features rule out the possibility of gemination as dental irregularity.