

Impakcija donjih trećih kutnjaka - prikaz slučajeva

Ivana Bagić¹
Mato Sušić²
Jadranka Keros³
Goranka Prpić-Mehičić⁴
Dubravka Radionov¹

¹Zavod za pedodonciju
Stomatološkog fakulteta
Sveučilišta u Zagrebu

²Zavod za oralnu kirurgiju
Stomatološkog fakulteta
Sveučilišta u Zagrebu

³Zavod za dentalnu
antropologiju Stomatološkog
fakulteta Sveučilišta u Zagrebu

⁴Zavod za dentalnu patologiju
Stomatološkog fakulteta
Sveučilišta u Zagrebu

Sažetak

Treći su kutnjaci zubi koji kongenitalno najčešće nedostaju. Istraživanja o razvoju trećih kutnjaka upućuju nas da utvrdjemo radiografske osobitosti korisne u predviđanju nicanja tih zuba. Istražili smo klinički i radiografski nalaz donjih trećih kutnjaka i pronašli pet različitih tipova impakcije donjih trećih kutnjaka.

Ključne riječi: donji treći kutnjaci, impakcija

Acta Stomatol Croat
1998; 509—513

STRUČNI RAD
Primljeno: 27. listopada 1997.

Adresa za dopisivanje:

Mr. sc. dr. Ivana Bagić
Filipovićeve 26/1
10000 Zagreb

Uvod

Donji treći kutnjaci zubi su koji kongenitalno najčešće nedostaju. Ako pak postoje, bitno se razlikuju oblikom, veličinom, dužinom razvojnoga razdoblja i odstupanjem od očekivanoga termina nicanja (1-6). Incidencija zakašnjela nicanja donjih trećih kutnjaka različita je u raznim dijelovima svijeta i kreće se od 9,5 do 39%. U ortodontskih pacijenata ona doseže do 50%, što se može pripisati razlici u dobi u kojoj je impakcija utvrđena i činjenici da se u tih pacijenata ortopantomogrami rade rutinski, što olakšava dijagnostiku (7-12). Zakašnjelo nicanje trećih donjih kutnjaka često je prvi znak kongenital-

nog nedostatka zubnoga zametka ili pak njegove impakcije zbog nedostatka prostora. Iz tih razloga predmet je mnogih istraživanja nagib zuba u lateralnom i anteroposteriornom smjeru, s obzirom na to da veći nagib uzrokuje jaču impakciju (9,13,14). Na impakciju se može posumnjati u sljedećim slučajevima: kada ramus mandibule pojačano raste u okomitome smjeru, ako je tijelo donje čeljusti izuzetno kratko, kad je rast alveolarnog segmenta donje čeljusti usporen te pri retrogradnom smjeru nicanja zuba i njihovoj zakašnjeloj mineralizaciji (9,13). Svrha našega rada bila je opisati razne tipove i stupnjeve impakcije donjih trećih kutnjaka. Za istraživanje smo upotrijebili ortopantomograme iz zbirke Zavoda za oralnu kirurgiju.

Prikaz slučajeva

Slučaj 1

Petnaestogodišnja djevojka žalila se na povremene umjerene spontane bolove i zadah iz desnog donjeg kvadranta usne šupljine. Opće zdravstveno stanje pacijentice bilo je zadovoljavajuće, osim što smo iz anamneze saznali za alergiju na azitromicin. Kliničkim pregledom otkrili smo djelomično iznikli drugi donji kutnjak. Na distobukalnoj strani zuba bio je parodontni džep dubok 4 mm. Meka tkiva u području desnoga donjeg kutnjaka i iza njega bila su zacrvenjena i upaljena. Ortopantomogram je pokazao dobro ograničenu radioluculentnu tvorbu promjera 1,5 cm koja je očito priliježala uz impaktirani treći donji kutnjak. Radiolucencija, jasno odijeljena od okolne kosti, sezala je sve do spojišta cakline i cementa na distalnome dijelu drugoga donjeg kutnjaka. Preliminarna dijagnoza cistične tvorbe bila je dovoljna da se pacijent pripravi za kirurški tretman koji je uključio enukleaciju ciste i vađenje impaktiranog zuba. Kirurški zahvat potvrdio je početnu dijagnozu.

Slučaj 2

Tridesetdvogodišnji muškarac zatražio je našu pomoć zbog dugotrajnog oticanja u donjem desnom dijelu čeljusti. Anamnezom smo saznali da je riječ o pacijentu s visokim rizikom za zahvat zbog srčane bolesti i kontinuirane antikoagulantne terapije. Oteklina je odgovarala položaju donjih desnih kutnjaka. Imao je i zadah iz usta, a zubalo je bilo nesanimirano. Pregledom smo utvrdili nedostatak desnoga donjeg prvog i trećeg kutnjaka, a lingvalne su kvržice donjega drugog kutnjaka bile djelomice vidljive. Drugi donji desni kutnjak pozitivno je reagirao na ispitivanje električnim vitalometrom. Nije bilo preosjetljivosti na perkusiju unatoč dubokom parodontnom džepu od 10 mm koji je bio uz zub meziolingvalno. Rendgenska slika pokazala je neobičan položaj svih triju kutnjaka. Prvi i treći kutnjak bili su potpuno impaktirani, a drugi je kutnjak samo neznatno izniknuo. Drugi donji desni kutnjak bio je impaktiran prema mezijalno, pritom prekrivajući impaktirani i rotirani prvi kutnjak, dok mu je distalnu stranu "prekrivao" treći kutnjak. Vodoravno impaktirani prvi kutnjak i korijeni drugoga kutnjaka priliježali su uz mandibularni kanal. Preporučili smo izvaditi

impaktirane zube s obveznom prethodnom hospitalizacijom zbog previsoka rizika prekida antikoagulantne terapije i iznimno važne kontinuirane kardiološke kontrole protrombinskog vremena (PT).

Slučaj 3

Dvadesetpetogodišnji mladić zatražio je našu pomoć zbog krvarenja, zadaha i bolova tijekom žvakanja u donjem desnom kvadrantu. Kliničkim pregledom utvrdili smo pomičnost prvoga donjeg desnog kutnjaka (2. stupanj) s distobukalno i distolingvalno smještenim parodontnim džepom dubokim 10 mm. Zub je pozitivno reagirao na test električnim vitalometrom. Drugi donji desni kutnjak nije bio u zubnome nizu, a treći je kutnjak bio nagnut mezijalno. Na ortopantomogramu se je vidio neznatni drugi donji kutnjak, impaktiran vodoravno i smješten baš uz mezijalno nagnut i djelomice izniknuo treći kutnjak. Karioznu leziju bilo je moguće vidjeti neposredno ispod kontakne točke između drugog i trećeg kutnjaka. Drugi i treći kutnjak kirurški smo odstranili i preostalu šupljinu ispunili materijalom Bio-Oss (spongioza i membrana) te ranu sašili s četiri šava. Tjedan dana nakon operacije pacijent nije više imao bolne simptome, a rana je dobro zacjeljivala. Prvi donji kutnjak ostao je vitalan.

Slučaj 4

Četrdesetdvogodišnji pacijent došao je zbog obostranog oticanja u području donjih kutnjaka. Iz anamneze smo saznali za preosjetljivost na penicilin. Kliničkim pregledom utvrdili smo obostrano djelomično iznikle druge donje kutnjake. Zacrvenjena sluznica, bolna na dodir, prekrivala je distookluzalnu plohu oba zuba. Pregled parodontnom sondom pokazao je pseudo džepove bez sekreta, s ostacima hrane. Prostor je ispran fiziološkom otopinom. Prvi parodontni džep dubok 4,5 mm bio je uz distolingvalnu stranu drugoga donjeg kutnjaka. Rendgenski je potvrđen klinički nalaz obostrano izniklih drugih donjih kutnjaka i impaktiranih trećih. Desni treći kutnjak bio je impaktiran mezijalno, a lijevi je bio rotiran za 180 stupnjeva, što je doista rijedak nalaz. Rendgenogramom se nadalje vidjela radiolucencija između drugog i trećega lijevog kutnjaka na mjestu gdje je kliničkim pregledom utvrđen parodontni džep. Isplanirali smo izvaditi oba impaktirana um-

njaka i osloboditi krune morfološki neobično oblikovanih drugih dvaju kutnjaka. Naime, bukhalno na njihovim žvačnim plohamo bile su tri umjesto uobičajene dvije kvržice što se može pripisati njihovoj genetskoj labilnosti.

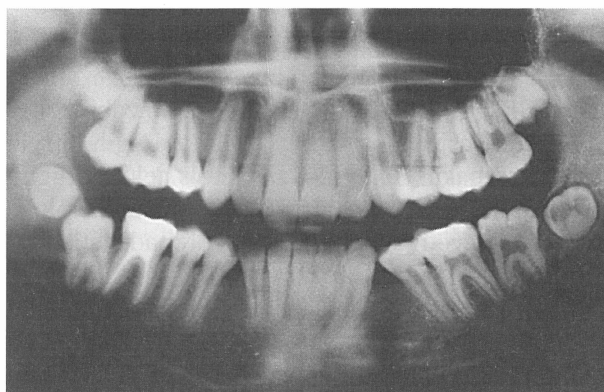
Slučaj 5

Dvanaestogodišnja djevojčica je nakon stomatološkog tretmana prvih trajnih kutnjaka, upućena na ortopantomografsko snimanje zbog potrebne ortodontske terapije i neizniklih preostalih drugih donjih trajnih kutnjaka. Nije imala subjektivnih simptoma. Kliničkim pregledom utvrdili smo lagano zadebljanje mukoze neposredno iza prvih donjih trajnih kutnjaka, a svi ostali zubi, osim prvih pretkutnjaka, bili su u zubnome nizu, zdravi ili ispravno sanirani. Ortopantomogramom se vidjela horizontalna impakcija drugih donjih kutnjaka s naznačenom radiolucencijom uokolo mezijalnih kvržica. Korijeni, još nezavršenoga rasta, sezali su do mandibularnoga kanala. Zametci umnjaka bili su smješteni iznad drugih kutnjaka i tako dodatno smanjili meziodistalnu dimenziju potrebnu za ispravni položaj drugih donjih kutnjaka u zubni niz. Kirurško-ortodontska terapija koju smo isplanirali uključila je izvaditi umnjake te ortodontski izvući i uspostaviti druge donje kutnjake.

Rasprava

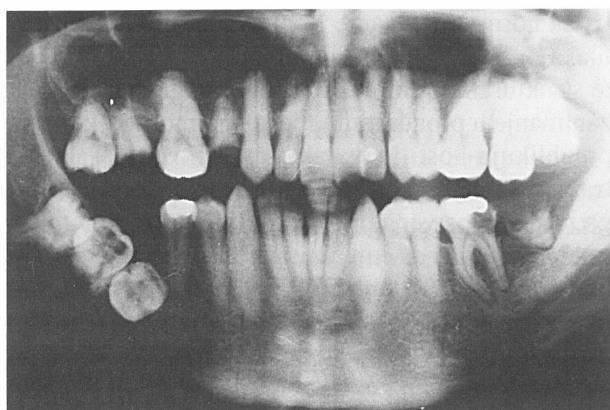
Impakcija je često stanje koje nastaje tijekom razvoja donjih trećih kutnjaka i zbog svojih brojnih kliničkih komplikacija važan je problem u stomatologiji (15). Ovisno o metodi klasifikacije stupnja impakcije, incidencija neizniklih donjih trećih kutnjaka kreće se od 22,3% do 66,6% (16-18). Stvaranje zametaka zuba može se objasniti aktivnošću sile u dinamičkoj korelaciji između njihova rasta i sadržaja kosti, dok mnogi dodatni čimbenici kao što je dob, prehrana, hormoni itd., određuju dužinu i smjer toga procesa (19,20). Okomita sastavnica rasta donje čeljusti čest je uzrok smanjenoga prostora koji je inače bitan za normalan položaj i razvoj donjega trećeg kutnjaka (21,22). Richardson (23) i Olive (24) govore da je transverzalna širina donje čeljusti i njezin odnos prema širini ramusa, tj. oblik i veličina retromolarnoga područja, važna pretpostav-

ka za normalno nicanje i položaj donjih trećih kutnjaka. Najnovije spoznaje u biokemiji, imunologiji te strukturalnoj i molekularnoj biologiji oživljavaju zanimanje u proučavanju mehanizama zbog kojih se preoblikuju kosti i stvaraju zametci zuba. Tako istraživanja koja se bave tim temama uključuju i druga nova znanstvena područja (25,26). Mnogi autori imaju stajalište da impaktirane treće kutnjake valja izvaditi (27-29). Stanley i sur. (2) istraživali su skupinu od 1756 pacijenata s 3702 impaktirana zuba i njihovi rezultati potvrđuju da gotovo 10% impaktiranih donjih trećih kutnjaka ima neku patološku promjenu; zaključili su da, zadrže li se impaktirani zubi, nastaju patološke posljedice u gotovo 85% pacijenata. Postoji visok rizik resorpcije korjenova drugih donjih kutnjaka, razvoj karijesa, perikoronitis, periodontitis, interna resorpcija, stvaranje dentinogene ciste, destrukcija alveolarne kosti, pa čak i razvoj tumora (3,4,30). Ako se pronađe kripta trećeg kutnjaka prije početka kalcifikacije, a prema studijama Adamsona (3) i Garna (4) kripte se javljaju već u dobi od 8 do 10 godina, kirurški zahvat bit će manje traumatski jer folikul još nije prožet koštanim tkivom, a gubitak kosti enukleacijom bit će minimalan (7). Sažimajući znanje i rezultate istraživanja o impakciji donjih trećih kutnjaka, ocijenili smo nalaze u prikazu slučajeva naših pet pacijenata. Svi naši pacijenti imali su i subjektivne i objektivne, blaže ili jače izražene simptome, poput oticanja, crvenila sluznice, perikoronitisa, zadaha iz usta, patoloških džepova itd. Njihovi rendgenski nalazi poka-

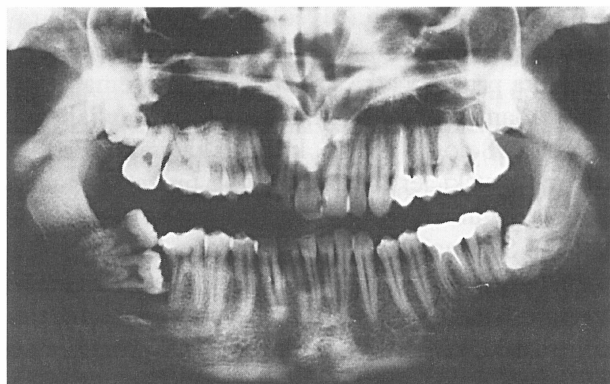


Slika 1. Ortopantomogram na kojem se vide djelomice iznikli donji drugi kutnjaci i impaktirani treći donji kutnjaci (s neobičnom rotacijom lijevog)

Figure 1. A panoramic radiograph showing partially erupted mandibular second molars and impacted mandibular third molars (with unusual rotation of the left molar)



Slika 2. Ortopantomogram na kojem se vidi jednostrana neobična impakcija svih triju donjih desnih kutnjaka
 Figure 2. A panoramic radiograph showing unilateral unusual impaction of all three mandibular right molars

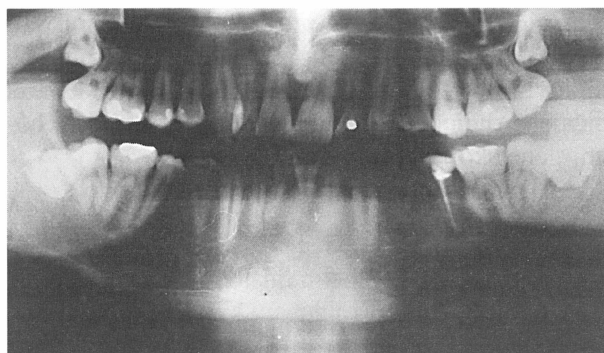


Slika 3. Ortopantomogram impaktiranoga donjeg desnog drugoga kutnjaka i donjeg lijevog trećega kutnjaka
 Figure 3. A panoramic radiograph of impacted lower right second molar and lower left third molar

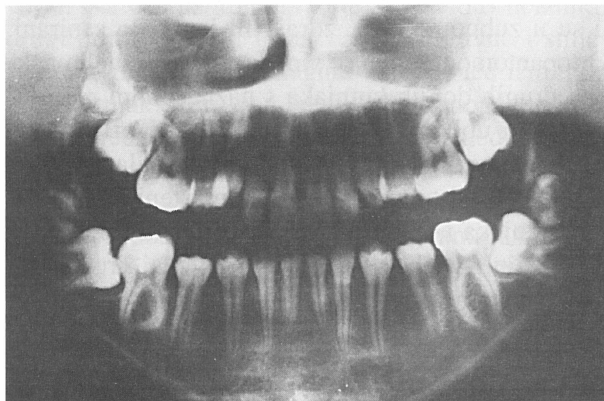
zali su različite tipove impakcije donjih trećih kutnjaka i postojanje unilateralne (Slike 1,2) i bilateralne (Slika 3) impakcije. Također smo zabilježili i impakciju susjednih zuba, tj. osobito drugih i prvih donjih kutnjaka (Slike 1,4) zajedno s nekim drugim abnormalnostima položaja i oblika okluzalne plohe (Slike 2,4). Kod jednog pacijenta pronađena je i cista (Slika 5). Terapijski zahvati koje smo uporabili kod pacijenata bili su vađenje, vađenje uz dodatni kirurški zahvat (cistektomija), i vađenje s ortodontskom terapijom.

Zaključci

Impaktirani je zub onaj kod kojeg je nicanje poremećeno zbog drugih zuba, zbog prekrivajuće ko-



Slika 4. Ortopantomogram s obostranom impakcijom donjih drugih kutnjaka
 Figure 4. A panoramic radiograph with bilateral impaction mandibular second molars



Slika 5. Ortopantomogram na kojem se vidi velika perikoronarna radiolucencija koja obuhvaća impaktirani donji desni treći i drugi kutnjak.
 Figure 5. A panoramic radiograph showing a large pericoronar radiolucency involving impacted lower right third and second molars

sti ili zbog fibroznoga tkiva. Najčešće impaktirani zubi jesu treći kutnjaci. Dok su impakcije u maksili češće od onih u mandibuli, impaktirani treći kutnjak u čeljusti uzrokuje više problema. Netretirani impaktirane zube velik je rizik. Budući da moguće posljedice ne možemo predvidjeti sve impaktirane zube trebalo bi izvaditi. Vađenje je osobito indicirano kad impaktirani zub uzrokuje ponavljane infekcije, zatim ako postoji manjak prostora, kad je zub izvan funkcije, i u slučaju kad impaktirani zub stvara cistu ili odontogeni tumor. Zahvat na impaktiranome zubu nije indiciran zbog oštećenja okolnih struktura, teških bolesti i urgentnih stanja. Odmjeravanje rizika i koristi za svaki impaktirani zub obavlja se

prije nego što se preporuča određena vrsta zahvata. Stoga bi većinu impaktiranih zuba trebalo izvaditi kako bi spriječili nastanak problema u budućnosti.

Literatura

1. RICHARDSON M. Late third molar genesis. Its significance in orthodontic treatment. *Angle Orthod* 1980; 50:121-128.
2. BLAŠKOVIĆ-ŠUBAT V. Frequency and most Common Localisation of Root Canal Curvature. *Acta Stomatol Croat* 1991; 25: 109-115.
3. NANDA RS. Agenesis of the third molar in man. *Am J Orthod* 1954;40:698-706.
4. KALLAY J. Dental anthropology. Zagreb: JAZU, 1974:45-53.
5. GRABER TM. Orthodontic Principles and Practice. Philadelphia-London-Toronto: WB Saunders & Co., 1972:276-286.
6. LASKIN DM. Evaluation of the third molar problem. *JADA* 1971;82:824-828.
7. VUKOVOJAC S. The dimensios of permanent molars in the population of Zagreb. *Acta Stomatol Croat* 1983; 17 (2): 103-112.
8. HARALABAKIS H. Observations on the time of eruption, congenital absence and impaction of the third molars. *Trans Eur Orthod Soc* 1957;308-309.
9. BJÖRK A, JENSEN E, PALLING M. Mandibular growth and third molar impaction. *Trans Eur Orthod Soc* 1956;164-197.
10. DACHI SF, HOWELL FV. A study of impacted teeth. *Oral Surg Oral Med Oral Pathol* 1961;14:1165-1169.
11. AITASALO K, LEHTINEN R, OKSALA E. An orthopantomographic study of prevalence of impacted teeth. *Int J Oral Surg* 1972;1:117-120.
12. GIBLISCO JA. Oral roentgenographic diagnosis. Philadelphia: W.B. Saunders Co., 1985:47-48.
13. BJÖRK A, JENSEN E, PALLING M. Mandibular growth and third molar impaction. *Acta Odont Scand* 1956;14:231-272.
14. VENTA I. Predictive model for impaction of lower third molars. *Oral Surg Oral Med Oral Pathol* 1933; 76:699-703.
15. CAPELLI J Jr. Mandibular growth and third molar impaction in extraction cases. *Angle Orthod* 1991;61:223-229.
16. GANSS C, HOOHBAN W, KIELBASSA AM, UMSTADT HE. Prognosis of third molar eruption. *Oral Med Oral Surg Oral Pathol* 1993;76:688-693.
17. MORRIS CR, JERMAN AC. Panoramic radiographic survey: a study of embeded third molars. *J Oral Surg* 1971;29:122-125.
18. VENTA I, MURTOMAA H, TURTOL L, MEURMAN J, YLIPAAVALNIEMI P. Clinical follow-up study of third molar eruption from ages 20 to 26 years. *Oral Surg Oral Med Oral Pathol* 1991;72:150-153.
19. KARDOS TB. The mechanism of tooth eruption. *Brit Dent J* 1996;181:91-95.
20. MARKS SC, CHILL DR. Regional control of alveolar bone metabolism by the dental follicle during tooth eruption. *J Oral Path* 1987;16:164-169.
21. SCHULHOF RJ. Third molars and orthodontic diagnosis. *J Clin Res* 1976;10:272-281.
22. KAPLAN RG. Some factors related to mandibular third molar impaction. *Angle Orthod* 1974;45:153-158.
23. RICHARDSON ME. The etiology and prediction of mandibular third molar impaction. *Angle Orthod* 1978;48:165-172.
24. OLIVE RJ, BASFORD KE. Transverse dentoskeletal relationships and third molar impaction. *Angle Orthod* 1981;51:41-47.
25. SCHROEDER HE, LUDER HU, BOSSHARDT DD. Morphological and labelling evidence supporting and extending a modern theory of tooth eruption. *Schweiz Monatschr Zahnmed* 1992;102:20-31.
26. SUTTON PRN, BAYE HR. The blood-vesel thrust theory of tooth eruption and migration. *Med Hypoth* 1985;18:289-295.
27. BISHARA SE, BURKEY PS. Second molar extractions. A review. *Am J Orthod Dentofac Orthop* 1986;89:415-424.
28. JOHNSON KV, QUIRK GP. Surgical repositioning of impacted mandibular second molar teeth. *Am J Orthod Dentofac Orthop* 1987;91:242-251.
29. TULLOCH JFC, ANTCZAK-BOUCKOMS AA. Decision analysis in the evaluation of clinical strategies for the management of mandibular third molars. *J Dent Educ* 1987;51:652-660.
30. LILLY G. Pathological processes associated with third molars. *Am J Orthod* 1983;83:131-137.

Impaction of Lower Third Molars

- Case Reports

Ivana Bagić¹
Mato Sušić²
Jadranka Keros³
Goranka Prpić-Mehičić⁴
Dubravka Radionov¹

¹Department of Pedodontics
School of Dental Medicine
University of Zagreb

²Department of Oral Surgery
School of Dental Medicine
University of Zagreb

³Department of Dental
Anthropology, School of Dental
Medicine University of Zagreb

⁴Department of Dental
Pathology, School of Dental
Medicine University of Zagreb

Summary

Third molars are the most often congenitally missing teeth. Studies on the development of third molars have lead to the identification of radiographic characteristics that are useful in predicting the eruption. We have investigated the clinical and radiographic status of lower third molars. In the course of our studies five different types of impaction pattern of the mandibular third molars have been revealed.

Key words: lower third molars, impaction

Acta Stomatol Croat
1998; 515—518

PROFESSIONAL PAPER
Received: October 27, 1997

Address for correspondence:

Mr. sc. Ivana Bagić
Filipovićevea 26/1
10000 Zagreb

Introduction

The third lower molars are the most commonly congenitally missing teeth and if they do exist they differ significantly in shape, size, position, duration of development and irregularity of eruption (1-6). The incidence of delayed eruption of lower third molars differs from one part of the world to the other and ranges from 9.5 to 39%. In orthodontic patients it is as high as 50%, and it may be accounted for by the difference in age at which impaction has been identified and also by the fact that in these patients orthopantomographs are regularly made, which facilitates the diagnosis (7-12). Delayed eruption of third lower molars is often the first sign of congenital absence of the tooth germ or its impac-

tion caused by lack of space. For these reasons many studies deal with inclination of the teeth in both lateral and anteroposterior projections, since it has been noticed that greater inclination causes greater impaction (9,13,14). Predictability of impaction is possible in the following cases: when the growth of ramus mandibulae shows a marked vertical direction, in short jaws, when the growth of the alveolar lower jaw segment is slow; in retrograde direction of teeth eruption and their delayed mineralisation (9,13). Our objective was to describe different patterns and degrees of lower third molar impaction. For this purpose orthopantomographic images were used from the collection of Oral Surgery Department.

Case reports

Case 1

A 15-year old female patient complained of occasional mild spontaneous pain and bad breath in the right lower lateral quadrant of the oral cavity. The general health condition of the patient was satisfactory and her medical history indicated allergy to azithromycin. Clinical examination revealed a partially erupted second lower molar (although with regard to the age of the patient it should have already developed). On the distobuccal side of the tooth there was a 4 mm deep periodontal pocket. The soft tissues in the region of the right lower molar and distally from it were reddened and inflamed. The orthopantomograph showed a well-confined radiolucent growth of 1.5 cm in diameter, apparently adhering to the impacted third lower molar. Radiolucency, clearly separated from the surrounding bone, reached up to the juncture line between the enamel and cementum of the distal part of the second lower molar. Preliminary diagnosis of the cystic growth was sufficient to prepare the patient for surgery, which that comprised enucleation of the cyst and removal of the impacted tooth. The surgery confirmed the initial diagnosis.

Case 2

A 32-year old man asked for our help because of a long-term swelling in the lower right lateral segment. His medical history revealed a high patient risk due to his primary heart condition and continuous anticoagulant therapy. The swelling corresponded to the location of the lower right molars. Bad breath was also present and dentition had not been treated. Examination revealed missing right lower first and third molars while the lingual tubercles of the lower second molar were partially visible. The second lower right molar reacted positively to examination by electric vitalometer. There was no hypersensitivity to percussion in spite of a 10-mm deep periodontal pocket on the mesiolingual side of the tooth. Radiography showed an unusual positional pattern of all three molars. The first and the third molar were entirely impacted and the second molar only partially erupted. The second lower right molar was mesioangularly impacted, covering the im-

acted and rotated first molar, whereas on its distal side it was "covered" by the third molar. The horizontally impacted first molar and roots of the second molar lay adjacent to the mandibular canal. Extraction of the impacted teeth was recommended on an in-patient basis, i.e. obligatory hospitalisation because the risk of discontinuing anticoagulant therapy was too high and it was extremely important to have the prothrombin time (PT) continuously monitored by a cardiologist.

Case 3

A 25-year old man came to us for help because of bleeding, bad breath and pain experienced during mastication in the lower right quadrant. Clinical examination showed mobility of the first lower right molar (2nd degree) with 10-mm periodontal pocket in the distobuccal and distolingual aspects. The electric vitalometer showed the tooth to be vital. The second lower right molar was not in the dental arch while the third molar was in a mesioangular position. Orthopantomographs showed the unerupted second lower molar. It was impacted horizontally and located just beneath the mesioangularly inclined and partially erupted third molar. A caries lesion could be seen immediately under the point of contact between the second and the third molar. The second and the third lower molars were surgically removed and the remaining cavity was filled with Bio-Oss material (spongiosa and membrane) and mucosa sutured with four stitches. One week after the surgery the patient was free of symptoms and the wound was healing well. The first lower molar remained vital.

Case 4

A 42-year old patient complained of bilateral swelling in the lower molar region. Medical history showed hypersensitivity to penicillin. Clinical examination revealed bilateral partial eruption of second lower molars. The distal occlusal surfaces were covered by mucosa that was reddened and painful to the touch. The periodontal probe showed pseudo-pockets without secretions but with residues of food. The site was washed out by physiological saline. A true 4.5 mm deep periodontal pocket was present distolingually along the second lower molar.

Radiography confirmed the clinical finding of bilaterally erupted second lower molars and impacted third molars. The right third molar was impacted mesioangularly whereas the left molar was rotated for 180 degrees, which is an extremely rare finding. X-ray images further showed radiolucency between the second and the third left molar at the site at which periodontal pocket was identified during clinical examination. A detailed plan was made for bilateral removal of the impacted wisdom teeth and releasing of crowns of the morphologically unusual by formed two other molars; namely, on their occlusal surface in the vestibular direction they had three, instead of the usual two, tubercles, which may be ascribed to their genetic instability.

Case 5

Following medical treatment of the first permanent molars, a 12-year old girl was referred to radiographic scanning for reasons of orthodontic therapy and unerupted remaining lower permanent molars. The girl reported no subjective complaints. Clinical examination revealed slight thickening of the mucosa immediately behind the first lower permanent molars, while all other teeth, except the first premolars, were present, healthy and properly treated. Panoramic radiography showed the second lower molars in horizontally impacted position with marked radiolucency around the mesial tubercles. The roots, not yet fully grown, reached the mandibular canal. The germs of the wisdom teeth were located above the second molars, additionally reducing the mesiodistal dimension needed for correct positioning of second mandibular molars in the dental arch. Surgical orthodontic therapy was planned including extraction of wisdom teeth and orthodontic uncovering, and directing positioning, of the second lower molars.

Discussion

Impaction is a common condition occurring in the course of development of the lower third molars and due to its numerous clinical complications it is a significant problem in dentistry (15). Depending on the method of classification of impaction degree, the incidence of unerupted lower third molars

ranges from 22.3% to 66.6% (16-18). Germination of teeth may be explained by the activity of forces in dynamic correlation between their growth and bone content, while many additional factors such as age, nutrition, hormones etc. determine the extent and direction of this process (19,20). Vertical component of lower jaw growth is a common cause of reduced space that is otherwise essential for normal positioning and development of the third lower molar (21,22). Richardson (23) and Olive (24) report that the transversal width of the lower jaw and its relation toward the ramus width, i.e. the shape and size of retromolar region, are important prerequisites for normal eruption and positioning of the lower third molars. The most recent knowledge in the fields of biochemistry, immunology and structural and molecular biology have resulted in a revival of interest in the study of mechanisms responsible for the reshaping of bones and germination of teeth. Thus the studies of these events include other new scientific fields (25,26). Many authors have reported that impacted third molars need to be extracted (27-29). Stanley et al (2) studied a group of 1756 patients with 3702 impacted teeth and their study results indicate that nearly 10% of the impacted lower third molars showed some kind of pathological changes. They concluded that retaining the impacted tooth results in pathological consequences in almost 85% of patients. There is a high risk of root resorption of other lower molars, caries development, pericoronitis, periodontitis, internal resorption, formation of dentinogenic cyst, destruction of alveolar bone, and even the development of a tumour (3,4,30). If the crypt of the third molar is identified prior to the beginning of calcification, and according to the studies carried out by Adamson (3) and Garn (4) crypts appear as early as the age of 8 to 10 years, surgical procedure will be less traumatic because the follicle has not yet been pervaded by osseous tissue so that the removal of the bone by enucleation will be minimal (7). By summarising the knowledge and study results on impaction of third lower molars, we were able to evaluate these findings in our five patients. All had both subjective and objective symptoms expressed to a greater or lesser degree, especially in terms of swelling, redness of mucosa, marked pericoronitis, bad breath, pathological pockets, etc. Their X-ray scans showed various degrees of impaction of third lower molars and presence of unilateral (Figures 1,2) and bilateral (Figures 3)

impaction. Simultaneous impaction of the surrounding teeth, i.e. the second and the first lower molars in particular (Figure 1,4), was also noticed together with some other irregularities in the position and shape of occlusal surfaces (Figures 1,3). There was also one patient in whom a cyst developed (Figure 5). The patients were treated by extraction, extraction and additional surgical treatment (cyst), and extraction and orthodontic therapy.

Conclusions

The impacted tooth is one where eruption has been disturbed by other teeth, overlying bone, or fibrous tissue. Third molars are the most commonly impacted teeth. While maxillary impactions are more common than mandibular, the impacted mandibular

third molar causes more problems, with which we are frequently faced. The retention of impacted teeth poses significant risks, and because neither the time nor the probability of sequelae can be predicted, all impacted teeth should be considered for removal. Removal is certainly indicated when the impacted tooth causes recurrent infections, if there is a lack of space, when a tooth is out of function and when an impacted tooth forms a cyst or odontogenic tumour. Leaving impacted teeth in place is indicated in particular circumstances, such as possible damage to adjacent structures, and compromised physical status. A risk-benefit evaluation should be made prior to recommending treatment for each impacted tooth. Most impacted teeth should be removed to correct existing pathologic conditions or to prevent future problems.