

# Tuberkuloza usne šupljine

Ivan Dvorski

Djelatnost za bolesti uha, nosa  
i grla  
Opće bolnice u Varaždinu

---

## Sažetak

*Autor opisuje dva bolesnika s tuberkulozom usne šupljine u tijeku bacilarne tuberkuloze pluća. U jednog je bolesnika tuberkulozni proces bio lokaliziran na bukalnoj sluznici, a u drugog na donjoj usni. Tuberkuloza pluća otkrivena je nakon dijagnosticiranja tuberkuloze u usnoj šupljini. U oba bolesnika dijagnoza je utvrđena histološkom pretragom. Oba su bolesnika izliječena suvremenim antituberkuloticima.*

*Ključne riječi: tuberkuloza, usna šupljina, bolesti*

---

Acta Stomatol Croat  
1998; 631—634

## STRUČNI RAD

Primljeno: 10. svibnja 1998.

Adresa za dopisivanje:

Ivan Dvorski  
Opća bolnica Varaždin  
42000 Varaždin  
Hrvatska

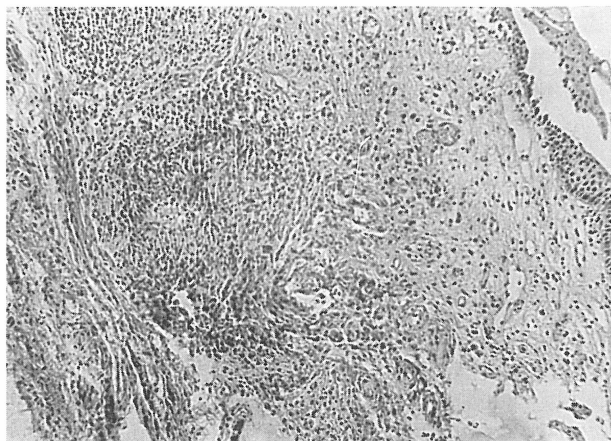
---

Lokalizacija tuberkuloznoga žarišta u usnoj šupljini vrlo je rijetka. Incidencija oralne tuberkuloze u preantibiotskoj eri kretala se je oko 1% od plućne tuberkuloze. Pojavom antituberkulotika njezina je incidencija u stalnom opadanju (1). Tuberkulozni proces najčešće je lokaliziran na jeziku, zatim na tvrdom i mekome nepcu, te na uvuli, gingivi, usnicama i žlijezdama slinovnicama (2,3,4). Bolest se javlja u primarnom, sekundarnom, odnosno u miliarnom obliku (5,6,7,8,9). Infekcija bacilom tuberkuloze nastaje na više načina: iz okoline, sputumom i ekspiriranim zrakom, ili pak hematogenim i limfnim putem (10,11,12,13,14,15). Klinička slika može biti vrlo raznolika te u diferencijalnoj dijagnozi valja isključiti mnogobrojne druge bolesti ovoga područja (16,17,18). Uporabom suvremenih antituberkulotika liječenje tuberkuloze oralne lokalizacije vrlo je uspješno.

Kao prilog problemu dijagnosticiranja tuberkuloze usne šupljine prikazujem dva bolesnika, budući da u novijoj stručnoj literaturi nema mnogo radova o takvoj lokalizaciji tuberkuloznoga procesa.

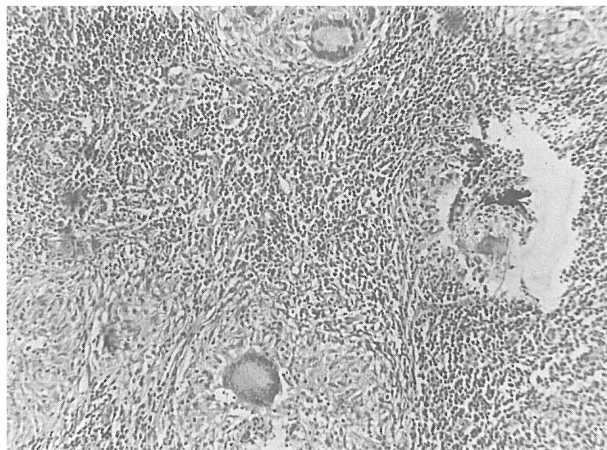
## Prvi bolesnik

S.D., muškarac u dobi od 52 godine, poljoprivrednik, primljen je na ORL odjel zbog podminiranog ulkusa na bukalnoj sluznici s desne strane veličine 2 X 1,5 cm. Okolina ulkusa je infiltrirana i bolna. Dno ulkusa je nekrotično. Bolesnik se žali na kašalj, osjeća se malaksalo i gubi na težini. Zbog sumnje na rak usne šupljine učinjena je probna ekscizija s ruba ulkusa, a patohistološki nalaz govori za tuberkulozu (Slika 1). Neposredno ispod višeslojnoga pločastog epitela vidi se nekoliko epiteloidnih žarišta s orijaškim stanicama tipa Langhans. Ujedno je učinjena i pregledana snimka pluća koja je pokazala obostrano, pretežito u gornjim i srednjim plućnim poljima, tipična mrljasta i nodozna zasjenjenja za plućnu tuberkulozu. Zato je konzultiran pulmolog koji je preporučio liječenje u specijalnoj bolnici za tuberkulozu, kamo je bolesnik i upućen na daljnje liječenje. Povremeno se kontrolirao u otorinolaringološkoj ambulanti. Uporabom antituberkulotika ulkus se u usnoj šupljini postupno samnjivao, a nakon terapije od 7 mjeseci i potpuno nestao uz potpunu epi-



Slika 1. Patohistološki nalaz prvoga bolesnika. Vidljiva su epitelioidna žarišta s orijaškim stanicama tipa Langhans. Bojenje hemalaun-eozin. Povećanje 150 X

Figure 1. Histopathological finding of the first patient. Epithelioid foci are visible with Langhans type giant cells. Staining with hemalaun-eozin. Enlargement 150 X



Slika 2. Patohistološki nalaz drugoga bolesnika. Vidljivi su nekroza i oko nje epitelioidna žarišta s dosta orijaškim stanicama tipa Langhansova. Povećanje 150 X

Figure 2. Histopathological finding of the second patient. Necrosis is visible, around which there is an epithelioid focus with several Langhans type giant cells. Staining with hemalaun-eozin. Enlargement 150 X

telizaciju toga mjesta. Zbog plućne tuberkuloze bolesnik je i dalje pod kontrolom pulmologa.

#### Drugi bolesnik

M.J., muškarac u dobi od 57 godina, građevinski radnik, primljen je na ORL odjel zbog egzulceriranoga tumorskog procesa na donjoj usnici s desne strane. Tumor raste, po bolesnikovu navodu, 3 mjeseca, bezbolan je, a na dodir lagano krvari. Kako tumor klinički podsjeća na rak, učini se kirurška ekscizija tumora. No bili smo iznenađeni jer je patohistološki nalaz pokazao da se radi o tuberkuloznom procesu (Slika. 2). U komadiću tkiva našla se je nekroza i oko nje epitelioidna žarišta s dosta orijaških stanica tipa Langhans. Učinjena radiografija pluća pokazuje u oba plućna krila fibrokazeokavernozne promjene tipične za aktivnu plućnu tuberkulozu. I taj je bolesnik nakon toga upućen u specijalnu bolnicu za liječenje tuberkuloze i pod daljnjim je nadzorom pulmologa.

#### Rasprava i zaključak

Svi se autori slažu da je tuberkuloza usne šupljine vrlo rijetka bolest, a ako se javi, može se manifestirati u primarnom, sekundarnom odnosno milijarnom obliku (4,5,6,7,8). Sama činjenica da se ri-

jetko javlja govori da postoji stanovita otpornost tkiva usne šupljine prema toj infekciji. Ta se otpornost u prvome redu pripisuje pljuvački, koja omogućuje stalno čišćenje usta od stranih tijela i bakterija, a njezine soli kao i mliječna kiselina ne pogoduju razvoju Kochova bacila. Osim toga otpornost se pripisuje i jakoj vaskularizaciji i debljini zaštitnoga epitelijskog pokrova, te normalnoj bakterijskoj flori u ustima koja sprječava zadržavanje i razvoj patogenih bakterija uopće (9).

Na oralnu sluznicu bacil tuberkuloze dolazi ili iz vanjske okoline, kao što je to kod primarne tuberkulozne lezije, ili sputumom i ekspiriranim zrakom bolesnika s aktivnom pulmonalnom tuberkulozom u slučaju sekundarne oralne tuberkuloze kod ozljeda sluznice usne šupljine (9,10,11). Postprimarna tuberkuloza usne šupljine može nastati i hematogenim i limfnim putem *per continuitatem* iz okoline (12). Huebschmann (13), međutim, nije čuo limfogeni razvoj oralne tuberkuloze. Ralson i sur. (14) pak navode da primarna tuberkuloza usne šupljine može biti uzrokovana samo bovinim tipom bacila tuberkuloze. Oni smatraju da ne postoji primarna tuberkuloza usne šupljine ako se u bioptičkom materijalu ne izolira bovinim tipom *Mycobacterium tuberculosis*. Prema Delstu i sur. (15) ne može se govoriti o primarnoj tuberkulozi u usnoj šupljini ako ne nastane konverzija negativne reakcije u pozitivnu tuberkulinsku reakciju.

Da bi se tuberkuloza pojavila na oralnome području potrebno je da postoje određeni preduvjeti, kao što su: da je oralno područje masovno onečišćeno bacilom tuberkuloze, da je bacil po svojoj virulenciji sposoban prodrijeti kroz epitel, da postoji određeni diskontinuitet epitela sluznice, da je sastav sline promijenjen (s obzirom na njezinu baktericidnu sposobnost), te da su smanjeni ostali lokalni i opći čimbenici rezistencije (9). Tuberkulozne promjene manifestiraju se na oralnome području u obliku lupusa, tuberkuloznog infiltrata, fisura, glositisa, ulceracija, hiperplastičnoga gingivitisa itd. Infiltrati mogu biti pojedinačni ili grupirani čvorići koji mogu kolikvirati i dovesti do stvaranja ulcera (4,7,16,17,18).

Diferencijalno dijagnostički dolaze u obzir i druge bolesti oralnoga područja, primjerice karcinom, lues, aktinomikoza, blastomikoza, monilijaza, mukomikoza, histoplazmoza, avitaminoze, trauma i krvne bolesti (4,8,9,11,16).

Histopatološki pregled uzorka tkiva, uz valjanu kliničku opservaciju, omogućuje jedino ispravnu dijagnozu. Ako unatoč takvu postupku postoji sumnja u dijagnozu, treba izvršiti inokulaciju tkiva na zamorčad. Valja napomenuti da je pri ustanovljenoj oralnoj tuberkulozi uvijek indiciran i specijalistički pregled pulmologa.

Značajka naših dvaju bolesnika s tuberkulozom oralnog područja jest da su obojica upućeni otorinolaringologu pod sumnjom na rak bukalne sluznice, odnosno donje usne, i da im je otorinolaringolog prvi dijagnosticirao tuberkulozu. U oba je bolesnika radiografski nađena plućna tuberkuloza i zbog nje su upućeni na specifično liječenje u specijalnu bolnicu.

Smatram da se u oba naša bolesnika radilo o sekundarnoj tuberkulozi usne šupljine. Danas kada imamo antituberkulotike koji omogućuju potpuno izlječenje tuberkuloze usne šupljine, poželjno je odmah u početku liječenja misliti i na tu lokalizaciju, prije nego se postojeći proces sanira u tijeku liječenja tuberkuloze druge lokalizacije. Naime, upotrebom modernih antituberkulotika nema ozbiljnijih poteškoća u liječenju tuberkuloze, a dijagnoza se lako postavlja ako se na nju pomišlja. U tome cilju biopsija je temeljna dijagnostička metoda. U oba naša slučaja tuberkulozni proces na plućima otkriven je nakon dijagnosticiranja tuberkuloze u usnoj šup-

ljini, što s epidemiološkoga gledišta nije nevažno. Valja imati na umu da su oba naša bolesnika kada im se je otkrila tuberkuloza bila radno aktivna i bez liječničkog nadzora.

## Literatura

1. KOMET H, SCHAEFER RF, MAHONEY PL. Bilateral tuberculous granulomas of the tongue. Arch Otolaryngol 1965;82:649-651
2. PUROHIT SD, MATHUR BB, GUPTA PR, AGARWAL KC, HARHI HH. Tuberculous fistula of cheek. Report of a case. Oral Surg Oral Med Oral Pathol 1985;60:41-42
3. METODIEV B, ČOSEVA-MANCEVA S, TRPENOV I. Retka lokalizacija tuberkulozne infekcije. Pluć Bol Tuberk 1975;27:175-177
4. KOLOKOTRONIS A, ANTINIADIS D, TRIGONIDIS G, PAPANAGIOTO U. Oral tuberculosis. Oral Dis 1996;2(3): 242-243
5. GAY ESCODA C, PUENECHEA IMAZ R. Tuberculosis oral: presentacion de tres casos. Rev Actual Odontoestomatol 1991;51(400):41-44, 47-48.
6. PORT EH. Lehrbuch der Zahnheilkunde. Muenchen: J.F. Bergmann, 1951.
7. FAVIA G, CHIARAVALLE G, LACAITA MG, LA-FORGIA A, FINA A. La tuberculosi oro-facciale. Analisi generale ed anatomo clinica di 35 casi. Minerva Stomatol 1990;39(4):261-268.
8. HENT H, KLEINSCHMIDT H, UEHLINGER E. Handbuch der Tuberkulose. Stuttgart: Thieme Verlag, 1964.
9. DOBRENIC M. Oralne bolesti. Zagreb: JUMENA, 1979.
10. KERN A, AUDRING H, BETHKE G. Differentialdiagnostische Problematik einer lokalisierten Haut- und Knochentuberkulose mit einer tuberkuloseverdächtigen Wangenschleimhautveränderung. Fallbericht. Dermatol Monatsschr 1988;174(12):748-752.
11. HARIS BC, TAYLOR CG, WADE WW. Millitary tuberculosis with oral manifestations. J Oral Surg 1973;31:305-307.
12. BENE J, SZEMKERESZTI B. Nyelz tuberculozis. Tuberkulozis 1960;12:179-180.
13. HUEBSCHMANN P. Die pathogenetischen und pathologisch-anatomischen Grundlagen der menschlichen Tuberkulose. Stuttgart: Hippokrates Verlag, 1956.
14. RALSON J, LEPOIVRE M. Primo infections tuberculeuses de la muqueuse buccale. Sem Hop Paris 1951;27:1472-1474.

15. DELST H, KRAUSS H. Die Tuberkulose. Stuttgart: Enke Verlag, 1951.
16. LAWS IM. Oral tuberculosis. Brit Dent J 1973; 134:140-148.
17. JELER E, BERČIĆ J, ROŠ-SMREKAR S. Tuberkuloza jezika i tvrdog nepca. Pluć Bol Tuberk 1977;29:256-259.
18. BUONOMO S, LEGRAND W, MAGREMANNE M. La tuberculose buccale: "a propos d' un cas". Acta Stomatol Belg 1996;93:33-36.

# Tuberculosis of the Oral Cavity

Ivan Dvorski

Ear, Nose and Throat  
Department,  
General Hospital, Varaždin

---

## Summary

*The author describes two patients with tuberculosis of the oral cavity during the course of bacillary pulmonary tuberculosis. In one of the patients the tubercular process was located on the buccal mucosa, and in the other on the lower lip. Pulmonary tuberculosis was detected after diagnosis of tuberculosis in the oral cavity. In both patients the diagnosis was confirmed by histologic examination and cured by the application of modern antituberculotics.*

Key words: *tuberculosis, oral cavity, disease*

---

Acta Stomatol Croat  
1998; 635—637

PROFESSIONAL PAPER  
Received: May 10, 1998

Address for correspondence:

Ivan Dvorski  
General hospital Varaždin  
42000 Varaždin  
Croatia

---

Localization of a tubercular focus in the oral cavity is very rare. The incidence of oral tuberculosis in the pre-antibiotics era was in the region of 1% of pulmonary tuberculosis. With the introduction of antituberculotics the incidence gradually decreased (1). The tubercular process is most frequently located on the tongue, and thereafter on the hard and soft palate, uvula, gingiva, mouth and salivary glands (2,3,4). The disease occurs in primary, secondary and milliary forms (5,6,7,8,9). Infection with the tubercular bacillus occurs in various ways: either from the exterior surroundings, sputum and expired air, or even by hematogenic and lymphatic means (10,11,12,13,14,15).

The clinical status can be very varied and for differential diagnosis numerous other diseases in this region must be excluded (16,17,18). With the application of modern antituberculotics, tuberculosis of the oral cavity can be successfully treated.

Two cases are presented here as a contribution to the problem of diagnosing tuberculosis of the oral cavity, since in recent literature similar papers on

such a localization of the tubercular process are scarce.

## *Patient I*

S.D., male, aged 52 years, an agricultural worker, was admitted to the ENT Department because of a undermine ulcer on the buccal mucosa, on the right side, 2x1.5 cm in size. The area around the ulcer was infiltrated and painful, and the base of the ulcer was necrotic. The patient complained of a cough, malaise and loss of weight. As cancer of the oral cavity was suspected a test excision was made of the ulcer edge and the histopathological finding indicated tuberculosis (Figure 1). Immediately under the multiple layered (squamous) epithelium several epithelioid foci with giant cells Langhans type can be seen. At the same time an X-ray was taken of the lungs which showed bilateral, mainly in the upper and middle pulmonary lobes, typical patchy, nodular shadows of pulmonary tuberculosis. Consequently a pulmonologist was consulted who subsequently recommended treatment in a specialized

hospital for tuberculosis, where the patient was sent for further treatment. The patient was examined occasionally in the ENT Out-patient Department. With the application of antitubercotics the ulcer in the oral cavity gradually decreased, and after 7 months of therapy completely disappeared, with complete epithelization of the site. Because of pulmonary tuberculosis the patient remains under the surveillance of the pulmonologist.

### Patient II

M.J., male, aged 57 years, a builder, was admitted to the ENT Department because of an ulcerating tumoral process on the right side of the lower lip. According to the patient the tumour had been growing for three months. It was painless, and when touched slight bleeding occurred. As the tumour clinically resembled cancer, a surgical excision was performed. However, the histopathological finding indicated a tubercular process (Figure 2). The piece of tissue contained necrosis, surrounded by an epithelial focus with numerous Langhans type giant cells. Radiography of the lungs showed fibrocavous-cavernous changes in both lungs, typical of active pulmonary tuberculosis. This patient was also sent to a specialized hospital for tuberculosis, and is also still under the surveillance of a pulmonologist.

### Discussion and conclusion

It is generally agreed that tuberculosis of the oral cavity is a very rare disease, and when it occurs it can manifest in primary, secondary, i.e. miliary form (4,5,6,7,8). The fact that it occurs so seldom indicates that the tissue of the oral cavity has a certain resistance to infection. This resistance is primarily attributed to saliva, which enables continuous cleansing of the mouth of foreign objects and bacteria, and the salts of which, together with lactic acid, do not favour the growth of Koch's bacillus. This resistance can also be attributed to the strong vascularization and thickness of the protective epithelial layer, and the presence of normal bacterial flora in the mouth, which prevents the accumulation and growth of pathogenic bacteria (9).

Tubercle bacillus reaches the oral mucosa either from the external surroundings, as in the case of pri-

mary tubercular lesion, or from the sputum and expired air of patients with active pulmonary tuberculosis, as in the case of secondary oral tuberculosis in damaged oral cavity mucosa (9,10,11). Post-primary tuberculosis can manifest via hematogenic and lymphatic pathways and also *percontinuitatem* from the surroundings. Huebschmann (13), however, denies lymphogenic development of oral tuberculosis. On the other hand, Ralson et al. (14) report that primary tuberculosis of the oral cavity can only be caused by the bovine type tubercular bacilla. They consider that if bovine type *Mycobacterium tuberculosis* is not isolated in the bioptic material primary tuberculosis of the oral cavity does not exist. According to Delst et al. (15) primary tuberculosis of the oral cavity cannot be considered if conversion of the negative reaction into positive tuberculinic reaction does not take place.

In order for tuberculosis to occur in the oral region it is necessary for certain preconditions to be present, such as: massive contamination of the oral region with the tubercle bacillus; according to its virulence, the bacillus must be capable of penetration through the epithelium; a certain discontinuity of the mucosal epithelium exists; the composition of the saliva is altered (with regard to its bactericidal capacity); and other local and general factors of resistance are decreased (9). Tubercular changes manifest on the oral region in the form of lupus, tubercular infiltrate, fissure, glossitis, ulceration, hyperplastic gingivitis etc. Infiltrates may be singly or grouped nodes, which can colliquate and lead to the formation of ulcers (4,7,16,17,18).

With regard to differential diagnostics, other diseases of the oral region should be considered, such as carcinoma, lues, actinomycosis, blastomycosis, moniliasis, mucomycosis, histoplasmosis, avitaminosis, trauma and hematological disease (4,8,9, 11,16).

Histopathological examination of a tissue sample, and clinical observation facilitate correct diagnosis. Should there still be doubt with regard to diagnosis, inoculation of the tissue onto a guinea-pig should be performed. It should be emphasized that when oral tuberculosis is established, examination by a pulmonologist is always indicated.

Because cancer of the buccal mucosa was suspected, i.e. the lower lip, both patients were sent to an ear, nose and throat specialist, who first diag-

nosed tuberculosis. In both patients pulmonary tuberculosis was detected by radiography, and they were consequently sent for treatment in a specialized hospital. The author considers that both patients had secondary tuberculosis of the oral cavity. Today, when oral cavity tuberculosis can be completely cured by treatment with antitubercotics, this localization should be considered at the start of treatment, before the existing process has healed, during the course of treatment for tuberculosis of another localization. Namely, the use of modern antitu-

berculotics does not involve any serious difficulties in the treatment of tuberculosis, and diagnosis is easily made if tuberculosis is suspected. In this respect biopsy is a comprehensive diagnostic method. In both the presented cases the tubercular process on the lungs was detected after diagnosing tuberculosis in the oral cavity, which, from the epidemiological point of view, is not irrelevant. Namely, both patients, at the time tuberculosis was detected, were working and not under the surveillance of a physician.