

Clinical and Neurophysiological Changes in Patients with Pineal Region Expansions

Sanja Hajnšek^{1,2}, Josip Paladino³, Željka Petelin Gadže^{1,2}, Sibila Nanković^{1,2}, Goran Mrak³ and Velimir Lupret³

¹ University of Zagreb, Zagreb University Hospital Centre, School of Medicine, Department of Neurology, Zagreb, Croatia

² Referral Centre of the Ministry of Health of the Republic of Croatia for Epilepsy, Zagreb, Croatia

³ University of Zagreb, Zagreb University Hospital Centre, School of Medicine, Department of Neurosurgery, Zagreb, Croatia

ABSTRACT

In the last 20 years neurological and neurosurgical follow up of our patients with pineal region expansions (118 patients) pointed to certain clinical and neurophysiological regularities. We performed retrospective study which included 84 patients with pineal region expansions in the period from 1992 to 2009. The study included 55 women and 29 men, mean age 30.08 ± 13.93 years, with positive brain magnetic resonance imaging (MRI) – 70 patients (83.4%) had simple pineal gland cysts, and 14 patients (16.67%) had expansive process in pineal region with compressive effect. All patients had headache, while 32 patients (38%) had epileptic phenomena – primary generalized seizures. Patients had common electroencephalography (EEG) pattern with paroxysmal discharges of 3Hz (or more than 3 Hz) spike-and-wave complexes. Operation with supracerebellar infratentorial approach was performed in 70 patients. In most of our patients indication for the operation was established based on the size of the cyst (15 mm or more), with the signs of compression on the quadrigeminal plate and compression of the surrounding veins, which could result in seizures and EEG changes verified in our group of patients. Pathohistological analysis revealed pineocytomas in 11 cases (15.71%), pinealoblastomas in 2 cases (2.86%), one case of teratoma (1.43%), while 56 patients had pineal gland cysts (80%). Following surgery clinical condition improved in all patients – patients became seizure-free and headaches significantly decreased. Other symptoms including diplopiae, nausea, vomiting, vertigo as well as blurred vision also disappeared. There were no complications after surgical procedures. This study points to often appearance of seizures that clinically and neurophysiologically present as primary generalized epilepsy in patients with pineal region expansions. Our hypotheses are that mass effect on the surrounding veins that affects normal perfusion, compressive effect on the quadrigeminal plate and the aqueduct of the midbrain, hemosiderin deposits, as well as secretion disturbances of anticonvulsive agent melatonin can be involved in the pathogenesis of seizures. We suggest to perform high resolution brain MRI with special demonstration of pineal region in all young patients that have seizures and specific EEG changes.

Key words: pineal gland, expansions, epilepsy, headache

Introduction

Presenting predominantly in adults in their 40s, more frequently in women, benign cysts in the pineal gland are reported in people of all ages in 25 to 40% of autopsy series¹. These non-neoplastic glial cysts are uniloculated or multiloculated with a smooth wall. There can be a thin layer or nodule on the cyst wall from the pineal parenchymal tissue. Microscopic examination reveals that the cyst is composed of an inner layer of gliotic tissue, an intermediate layer of pineal parenchymal tissue, and an outer layer of connective tissue². Most cysts are asymp-

tomatic, with diameters ranging from 2 to 15 mm³. When present, however, symptoms are usually noted in patients with cysts larger than 15 mm in diameter⁴. A typical pineal cyst, as defined by Barboriak et al.⁵, can have a thin 2 mm rim of enhancement. It is the lack of a blood-brain barrier surrounding the pineal gland that allows the walls of these benign cysts to enhance because the wall is composed of pineal tissue. The imaging features of atypical pineal cysts, including irregular nodular enhancement and hemorrhage into a typical pineal cyst,

have been previously described by multiple authors⁵⁻⁹. The pineal cyst can occasionally enlarge the pineal gland and compress adjacent structures such as the superior colliculi of the quadrigeminal plate and the aqueduct of the midbrain, producing hydrocephalus and clinical symptoms. When present, the clinical symptoms include headache, vertigo, diplopia, blurred vision, hemiparesis, epilepsy, vomiting, bradycardia, papilledema, oculomotor nerve palsy, Parinaud syndrome¹⁰, and recently described occurrence of resting tremor and/or other secondary parkinsonian symptoms¹¹. Hypothalamic dysfunctions of precocious puberty have also been attributed to pineal lesions¹², as well as sleep disturbances due to abnormal melatonin regulation. Cases of pineal apoplexy that cause sudden death from an intracystic hemorrhage have also been reported¹³.

In the last 20 years neurological and neurosurgical follow up of our patients with pineal region expansions (118 patients) pointed to certain clinical and neurophysiological regularity. We performed retrospective study in which we included 84 patients with pineal region expansions in the period from 1992 to 2009.

Patients and Methods

The study included 55 women and 29 men (2:1 female male ratio), mean age 30.08 ± 13.93 years, with positive brain magnetic resonance imaging (MRI): 70 patients (83.4%) had pineal gland cysts, and 14 patients (16.67%) had expansive process with compressive effect. All patients were suffering from headache, while 38.09% (32 patients) of those patients (20 women, 8 men) had epilep-

TABLE 1
CLINICAL SYMPTOMS IN 84 PATIENTS WITH PINEAL REGION EXPANSIONS

Symptoms	No. of patients
Headache	84
Absences	10
Myoclonisms	8
GTCS	6
Absences + Myoclonisms + GTCS	2
Precocious puberty	10
Diplopieae	4
Nausea	4
Vomiting	4
Vertigo	4
Blurred vision	4

GTCS – generalized tonic-clonic seizures

tic phenomena – primary generalized seizures of all three clinical phenotypes (Table 1). The most prevalent diagnosis was migraine (82% of patients). Notably, 42% of the migraineurs had migraine with aura. Considering epileptic phenomena, 10 patients had absences (11.90%), 8 patients myoclonisms (9.52%), 8 patients generalized tonic-clonic seizures (9.52%) and 6 patients had combination of all three clinical phenotypes (7.14%). Patients had common electroencephalography (EEG) pattern with paroxysmal discharges of 3 Hz (or more than 3Hz) spike-and-wave complexes (Figure 1). Due to seizures patients were treated with numerous antiepileptic drugs: valproic

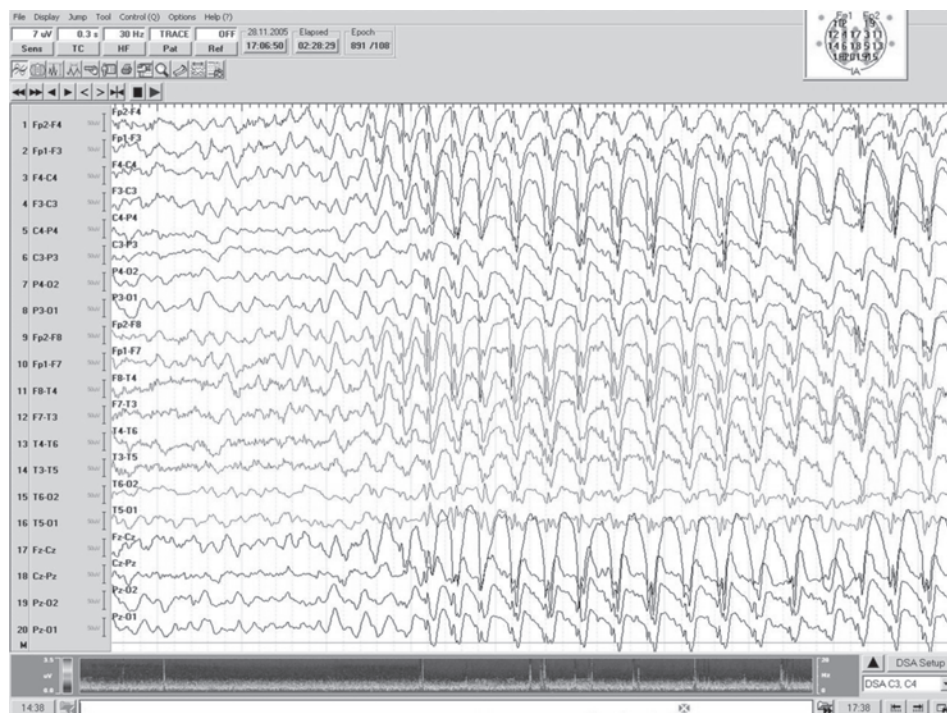


Fig. 1. Electroencephalogram (EEG) of one of our patients with typical pattern of paroxysmal discharges of 3Hz spike-and-wave complexes.

acid, topiramate, methylphenobarbital, carbamazepine, lamotrigine, levetiracetam, oxcarbazepine, clonazepam and sulthiame (Table 2). 34% of patients had medically refractory seizures. Other clinical symptoms were: precocious puberty in 2 patients (one patient had pineal gland cyst with compression of superior colliculi, other patient had teratoma maturum), diplopiae in 10 patients, and nausea, vomiting, vertigo as well as blurred vision in 4 patients (that developed hypertensive hydrocephalus due to pineal gland tumours).

TABLE 2
ANTIEPILEPTIC DRUGS (AEDs) IN PATIENTS WITH SEIZURES
AND PINEAL REGION EXPANSIONS

AED	No of patients
VPA	19
TPM	17
MPB	15
CBZ	10
LTG	10
LEV	6
OXC	4
CNZ	2
SUL	1

VPA – valproic acid, TPM – topiramate, MPB – methylphenobarbital, CBZ – carbamazepine, LTG – lamotrigine, LEV – levetiracetam, OXC – oxcarbazepine, CNZ – clonazepam, SUL – sulthiame

Operation with supracerebellar infratentorial approach was performed in 70 patients. In most of our patients indication for the operation was established based on the size of the cyst (15 mm or more), with the signs of compression on the quadrigeminal plate and compression of the surrounding veins, which could result in seizures and EEG changes verified in our group of patients. All patients in this series were operated in the same manner. Patients were placed in the sitting position with slight anterior flexion of the head. Linear skin incision was made in the midline from just above theinion to the spinous process of the C2 vertebra and the cervical muscles were opened in the midline down to the periosteum of the occipital bone and lamina of C1. After exposing the bone a 4x3 cm ellipsoid osteoplastic craniotomy was made extending from the confluence of sinuses to the cerebellomedullar cistern. The dura was opened in a curved fashion with its base towards the transverse sinus and suspended with sutures, while the dural sinuses of the midline were ligated with sutures. The arachnoid of the cisterna magna was incised in the midline in a craniocaudal direction and approximately 60-80 ml of cerebrospinal fluid was evacuated. The gravity of the sitting position and evacuating cerebrospinal fluid by opening the cisterna magna enabled the surgeon to perform the operation without the use of retractors. The surgeon could adjust the trajectory to the pineal region by further

inclination of the operating table. The arachnoid membrane was incised and superior vermian vein, basal vein of Rosenthal and the pulvinar thalami region were exposed. In some cases of simple pineal cysts a unilateral approach was sufficient while in others a bilateral approach provides a better solution (Figure 2a). Exposing the upper pole of the pineal lesion and meticulous preparation for separating it from the internal cerebral veins in the roof of the third ventricle, the tela choroidea and the angulus venosus presented the next fase of the operation. With fine preparation of the blood vessels the lateral aspect of the lesion was separated from the medial wall of the thalamus using a sharp dissection. The end of the operation consisted of a sharp dissection towards the habenular commissure which allowed a complete removal of the pineal lesion (Figure 2b). Following extirpation exact hemostasis was made and the third ventricle was irrigated. The dura was closed in a watertight manner using continuous sutures. The bone flap was fixed and secured with titanium plates. Cervical muscles, the subcutaneous tissue and the skin were carefully reconstructed and closed with sutures.

The appropriate adjustment of patients in sitting position with elevated lower extremities above the level of the head decreased negative venous pressure. Careful hemostasis of all layers, from the skin, subskin, bones, and careful coagulation of all bridge veins with glueing with fibrin glue the spaces on which we expected the entrance of air into venous sinuses decreased the risk of air embolism. We did not experience any cases of air embolism, but in cases of beginning of air embolism aspiration of air and additional procedures of closing the space of air entrance with changing the position of the patient reduces the extent and enables resolution of air embolism.

Results

Pathohistological analysis verified pineocytomas in 11 cases (15.71%), pinealoblastomas in 2 cases (2.86%), one case of teratoma (1.43%), while 56 patients had pineal gland cysts (80%), half of them with hemosiderin deposits in the walls of the pineal gland cysts, what suggests a possibility of earlier bleeding. Figure 3 reveals brain MRI of one of our patients showing pineal gland tumour with compressive effect. Figure 4 shows pathohistological finding of pineal gland cyst.

Following surgery clinical condition improved in all patients – all patients became seizure-free and headaches significantly decreased. Other symptoms including diplopiae, nausea, vomiting, vertigo as well as blurred vision also disappeared. There were no complications after surgical procedures.

Discussion

The cone-shaped pineal gland typically measures less than 1 cm in diameter and is located on the level of the diencephalon outside the blood-brain barrier. As a neuroendocrine transducer, it changes neural into endocrine

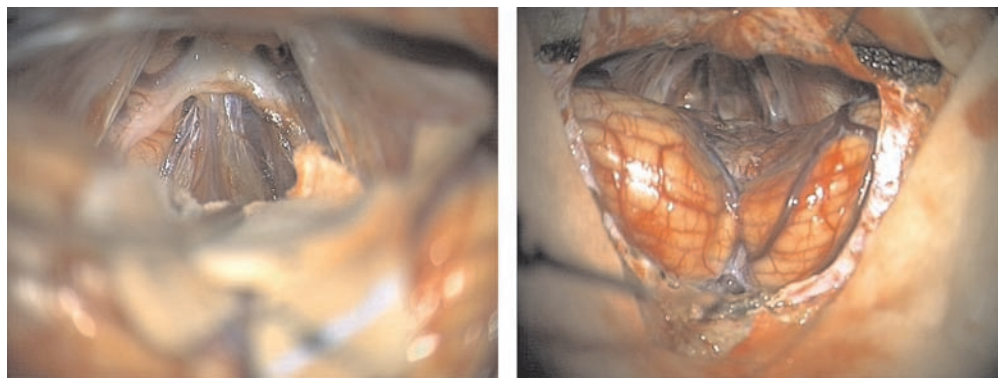


Fig. 2a. showing the pineal gland cyst and its relationship to the surrounding structures prior to its removal (left). 2b. supracerebellar infratentorial view of the pineal region after the extirpation of the pineal gland cyst (right).

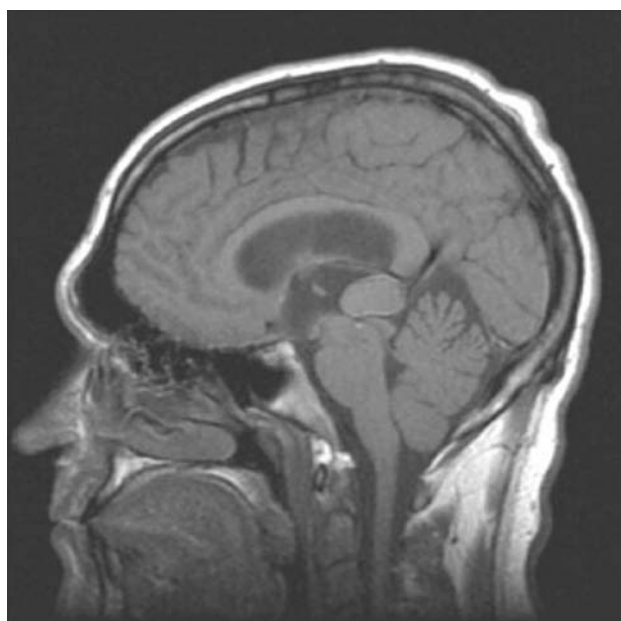

Fig. 3. Brain magnetic resonance imaging (MRI) of a 40-year old patient showing pineal gland tumour with compressive effect.

signals and is known to be the main source of melatonin production. It was identified in 1958 by Lerner et al.¹⁴. The innervation of the pineal gland derives mainly from the sympathetic superior cervical ganglion, which is controlled by the hypothalamic nucleus supra-chiasmaticus via the nucleus intermediodorsalis. Trigeminal efferents innervating the gland have also been established. Melatonin is synthesized by pinealocytes from the precursor tryptophan and has been shown to affect pain thresholds and endorphin levels. The diurnal rhythm of melatonin is light-dependent. Melatonin as anticonvulsive agent is involved in the mechanisms of epileptogenesis, regulation of the circadian rhythm, thereby affecting several biological functions such as immune function, blood pressure regulation, retinal and ovarian physiology. Recently, reductions in pineal opioid receptor binding have been shown in cluster headache and other studies found de-

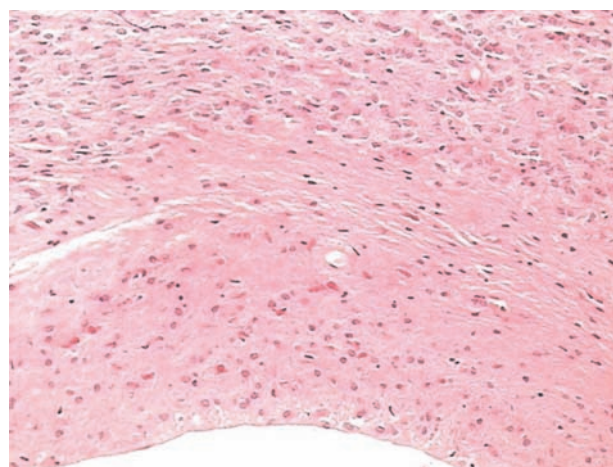


Fig. 4. Pineal gland cyst. The cyst cavity is lined by a layer of gliotic tissue containing Rosenthal fibers. This layer interfaces abruptly with the normal pineal parenchyma.

creased melatonin levels in patients with migraine and cluster headache, indicating a possible relationship between alterations in the circadian secretion of melatonin and headache¹⁵.

We present data on the incidence of headache and seizures in patients with pineal region expansions. Our study demonstrated that there is a female predominance in the occurrence of pineal cysts and region expansions, which is consistent with the results of prior retrospective MR imaging studies conducted for other medical indications^{16–18}. The results clearly indicate that pineal region expansions are related to headache and more specifically to migraine, and, for the first time, we have noticed often appearance of epileptic seizures¹⁹. Although we did not measure the level of anticonvulsive agent melatonin in our patients, we could hypothesize that secretion disturbances of melatonin can be involved in the pathogenesis of seizures. Other causes could be hemosiderin deposits found in the walls of the pineal gland cysts, with known epileptogenic properties, and compressive effect on the quadrigeminal plate and the aqueduct of the midbrain,

the structures that can also be involved in the process of the epileptogenesis. We also have to consider the possibility that the effect of prolonged compression of these lesions on the surrounding veins affects normal perfusion which can result in EEG changes and seizures verified in our group of patients. Regarding compressive effect, it is important to emphasize existence of other expansive processes in the pineal region- pineal parenchymal tumors (PPT), that, according to the currently revised WHO classification of tumors of the central nervous system, are subdivided into well-differentiated pineocytoma, poorly differentiated pineoblastoma, and PPT with intermediate differentiation. Other expansive processes are germ cell tumors (germinomas, teratomas, embryonal carcinomas, choriocarcinomas, yolk sac tumors), glial tumors (astrocytomas, anaplastic astrocytomas, glioblastomas, ependymomas) and miscellaneous tumors (cavernous angioma, cancer metastasis, lipoma, meningioma, epidermoids)²⁰. The differential diagnosis of simple pineal cysts and cystic tumors, such as astrocytoma, pineocytoma, and pineoblastoma, is crucial for clinical management^{21,22}. In our group of 70 operated patients 11 cases of pineocytomas, 2 cases of pineoblastomas, and one case of teratoma were pathohistologically verified.

The natural history of the pineal cyst is not completely understood because no studies have been performed to follow the cyst from its appearance to its complete resolution. Nevertheless, some studies demonstrated that pineal cysts are stable during relatively long follow-up periods. Barboriak et al⁵ conducted a retrospective follow-up study in 32 patients with pineal cysts and other intracranial pathologic lesions. They observed that 75% of cysts remained stable over time, ranging from 0.5 to 9.1 years; 16% decreased in size or regressed completely, whereas 8% increased in size by 2.0–3.0 mm. Tamaki et al.²³ studied 31 subjects with pineal cysts; in 29 cases, the cysts did not change in size during the follow-up time from 3 months to 4 years. In 2 cases, the cysts spontaneously ruptured and collapsed during follow-up. In another study, Golzarian et al.²⁴ followed 12 subjects with pineal cysts; the cysts did not change in size throughout the 1-year follow-up.

There is debate within the neurosurgical community regarding when surgical treatment of the pineal cysts is indicated. For instance, asymptomatic pineal cysts with a typical appearance should be followed clinically and with annual imaging studies for many years. Surgical treatment of the lesion should be instituted to relieve symptoms and/or to obtain a final tissue diagnosis. Surgical intervention with radical cyst removal is the treatment of choice for all symptomatic pineal cysts²⁴. Wisoff and

Epstein²⁵ suggest complete cyst removal as desirable; however, radical subtotal resection is appropriate, if the cyst cannot be easily separated from the quadrigeminal plate. Ventricular shunting should be reserved for patients with persistent hydrocephalus after cyst resection. Treatment can be guided based on tissue type and the presence or absence of hydrocephalus. In patients presenting with hydrocephalus, treatment of the increased intracranial pressure seems to be more beneficial than actual tumor resection regarding the resolution of symptoms. In most of our patients with pineal cyst indication for the operation was established based on the size of the cyst (15 mm or more), with the signs of compression on the quadrigeminal plate and compression of the surrounding veins. In all our operated patients radical removal of pineal gland cysts and tumours was possible, because mentioned expansions were well demarcated from surrounding structures. Pinealoblastomas, germinomas and yolk sac tumours very often have unclear border line, which requires »gross total resection«, but this was not the case in our patients.

Significant finding in all patients with pineal lesions is the mass effect of these lesions on the surrounding veins (vermian vein, internal cerebral veins, basal veins of Rosenthal and the great cerebral vein). It is possible that prolonged compression of these lesions on the surrounding veins affects normal perfusion which can result in EEG changes and seizures verified in our group of patients.

Conclusion

This study points to often appearance of seizures that clinically and neurophysiologically presents as primary generalized epilepsies in patients with pineal region expansions. Our hypotheses are that mass effect on the surrounding veins that affects normal perfusion, compressive effect on the quadrigeminal plate and the aqueduct of the midbrain, hemosiderin deposits, as well as secretion disturbances of anticonvulsive agent melatonin can be involved in the pathogenesis of seizures. We suggest to perform high resolution brain MRI with special demonstration of pineal region in all young patients that have seizures and specific EEG changes.

Acknowledgements

We would like to thank dr. Antonia Jakovčević, pathologist, and dr. Branimir Ivan Šepec, neurologist, for their help in preparing figures for this article.

REFERENCES

- HASEGAWA A, OHTSUBO K, MORI W, Brain Res, 409 (1987) 343. DOI: 10.1016/0006-8993(87)90720-7. — 2. HIRATO J, NAKAZATO Y, J Neurooncol, 54 (2001) 239. DOI: 10.1023/A:1012721723387. — 3. DI CONSTANZO A, TEDESCHI G, DI SALLE F, GOLIA F, MORRONE R, BONAVITA V, J Neurol Neurosurg Psychiatry, 56 (1993) 207. DOI: 10.1136/jnnp.56.2.207. — 4. FAIN JS, TOMLINSON FH, SCHEITHAUER BW, PARISI JE, FLETCHER GP, KELLY PJ, MILLER GM, J Neurosurg, 80 (1994) 454. DOI: 10.3171/jns.1994.80.3.0454. — 5. BARBORIAK DP, LEE L, PROVENZALE JM, AJR Am J Roentgenol, 176 (2001) 737. — 6. STEVEN DA, MCGINN GJ, MCCLARTY BM, AJNR Am J Neuroradiol, 17 (1996) 939. — 7. FLEEGLER MA, MILLER GM, FLETCHER GP, FAIN JS, SCHEITHAUER BW, AJNR Am J Neuroradiol, 15 (1994) 161. — 8.

- TAVERAS JM, Pineal region masses. In: TAVERAS JM, PILE-SPPELLMAN J (Eds) *Neuroradiology* (Lippincott Williams & Wilkins, Baltimore, 1996). — 9. MAMOURIAN AC, TOWFIGHI J, AJNR Am J Neuroradiol, 7 (1986) 1086. — 10. MANDERA M, MARCOL W, BIERZYŃSKA-MACYSZYN G, KLUCZEWSKA E, Childs Nerv Syst, 19 (2003) 750. DOI: 10.1007/s00381-003-0813-2. — 11. MORGAN JT, SCUMPIA AJ, WEBSTER TM, MITTLER MA, EDELMAN M, SCHNEIDER SJ, *Pediatr Neurosurg*, 44 (2008) 234. DOI: 10.1159/000121382. — 12. DICKERMAN RD, STEVENS QE, STEIDE JA, SCHNEIDER SJ, *Neuroendocrinol Lett*, 25 (2004) 173. — 13. MILROY CM, SMITH CL, *J Clin Pathol*, 49 (1996) 267. DOI: 10.1136/jcp.49.3.267. — 14. LERNER AB, CASE JD, TAKAHASHI Y, *J Am Chem Soc*, 80 (1958) 2587. DOI: 10.1021/ja01543a060. — 15. SPRENGER T, WILLOCH F, MIEDERER M, SCHINDLER F, VALET M, BERTHELE A, SPILKER ME, FÖRDERREUTHER S, STRAUBE A, STANGIER I, WESTER HJ, TÖLLE TR, *Neurology*, 66 (2006) 1108. DOI: 10.1212/01.wnl.0000204225.15947.f8. — 16. DI COSTANZO A, TEDESCHI G, DI SALLE F, GOLIA F, MORRONE R, BONAVITA V, *J Neurol Neurosurg Psychiatry*, 56 (1993) 207. DOI: 10.1136/jnnp.56.2.207. — 17. GOLZARIAN J, BALERIAUX D, BANK WO, MATOS C, FLAMENT-DURAND J, *Neuroradiology*, 35 (1993) 251. DOI: 10.1007/BF00602604. — 18. AL-HOLOU WN, MAHER CO, MURASZKO KM, GARTON HJ, *J Neurosurg Pediatr*, 5 (2010) 162. DOI: 10.3171/2009.9.PEDS09297. — 19. SAJKO T, KUDELIC N, LUPRET V, LUPRET V Jr, NOLA IA, *Coll Antropol*, 33 (2009) 1259. — 20. TSUMANUMA I, TANAKA R, FUJII Y, *Occipital Transtentorial Approach and Combined Treatments for Pineal Parenchymal Tumors*. In: KOBAYASHI T, LUNSFORD LD (Eds) *Pineal region Tumors. Diagnosis and Treatment Options* (Karger, Basel, 2009). — 21. SUGIYAMA K, ARITA K, OKAMURA T, YAMASAKI F, KAJIWARA Y, UEDA H, KURISU K, *Childs Nerv Syst*, 18 (2002) 157. DOI: 10.1007/s00381-002-0569-0. — 22. PALADINO J, ROTIM K, MRAK G, GRIZELJ M, GLUNČIĆ V, *Neurol Croat*, 47 (1998) 269. — 23. TAMAKI N, SHIRATAKI K, LIN T, MASUMURA M, KATAYAMA S, MATSUMOTO S, *Childs Nerv Syst*, 5 (1989) 172. — 24. GOLZARIAN J, BALERIAUX D, BANK WO, MATOS C, FLAMENT-DURAND J, *Neuroradiology*, 35 (1993) 251. DOI: 10.1007/BF00602604. — 25. WISOFF JH, EPSTEIN F, *J Neurosurg*, 77 (1992) 896. DOI: 10.3171/jns.1992.77.6.0896.

Ž. Petelin Gadže

University of Zagreb, Zagreb University Hospital Centre, School of Medicine, Department of Neurology, Kišpatićeva 12, 10000 Zagreb, Croatia
e-mail: zpetelin@mef.hr

KLINIČKE I NEUROFIZIOLOŠKE ZNAČAJKE U BOLESNIKA S EKSPANZIVNIM TVORBAMA PINEALNE REGIJE

SAŽETAK

U posljednjih 20-tak godina neurološko i neurokirurško praćenje naših bolesnika s ekspanzivnim tvorbama pinealne regije (118 bolesnika) ukazalo je na određene kliničke i neurofiziološke značajke. Stoga smo se odlučili učiniti retrospektivnu studiju koja je uključila 84 bolesnika s ekspanzivnim tvorbama pinealne regije u periodu od 1992. do 2009. godine. Studija je uključila 55 žena i 29 muškaraca, srednje životne dobi $30,08 \pm 13,93$ godina, s pozitivnim nalazom magnetske rezonance (MR) mozga – 70 bolesnika (83,4%) imalo je jednostavne ciste pinealne žlijezde, dok je 14 bolesnika (16,67%) imalo ekspanzivni proces pinealne regije s kompresivnim učinkom. Svi su bolesnici imali glavobolje, dok je 32 bolesnika (38%) imalo primarno generalizirane epileptičke napadaje. Bolesnici su imali uobičajen elektroencefalografski (EEG) uzorak s paroksizmalnim izbijanjima šiljak-val kompleksa frekvencije 3Hz (ili više od 3Hz). Operativni zahvat sa supracerebelarnim infratentorijskim pristupom izvršen je u 70 bolesnika. U većine bolesnika indikacija za operaciju postavljena je temeljem veličine pinealne ciste (15 mm ili više), uz znakove kompresije lamine kvadrigeminne i okolnih vena, što može rezultirati epileptičkim napadajima i EEG promjenama koje su verificirane u našoj grupi bolesnika. Patohistološka analiza otkrila je da se u 11 slučajeva (15,71%) radilo o pineocitomima, u 2 slučaja (2,86%) o pineoblastomima, u jednom slučaju o teratomu (1,43%), dok je 56 (80%) bolesnika imalo cistu pinealne žlijezde. Nakon operacije došlo je do poboljšanja kliničkog stanja u svih bolesnika – bolesnici više nisu imali epileptičke napadaje, a glavobolje su se značajno smanjile. Drugi simptomi uključujući dvoslike, mučninu, povraćanje, vrtoglavicu te zamagljenje vida su također nestali. U postoperativnom tijeku nisu zabilježene komplikacije. Ova studija ukazuje na učestalu pojavu epileptičkih napadaja, koji se klinički i neurofiziološki prezentiraju kao primarno generalizirana epilepsija, u bolesnika s ekspanzivnim tvorbama pinealne regije. Naše hipoteze su da u patogenezu epileptičkih napadaja mogu biti uključeni: kompresivni učinak ekspanzivnih tvorbi pinealne regije na okolne vene čime se remeti uredna perfuzija, kompresivni učinak na laminu kvadrigeminu i mezencefalički akvedukt, hemosiderinski depoziti, kao i smetnje izlučivanja melatonina koji ima antikonvulzivni učinak. Preporučamo da se u svakog bolesnika mlađe životne dobe sa specifičnim EEG promjenama učini visokorezolucijski MR mozga sa specijalnim prikazom pinealne regije.