

Cytotoxicity of $\text{Ca}(\text{OH})_2$ Endodontic Sealers on Connective, Muscle and Bone Tissues

Citotoksično djelovanje $\text{Ca}(\text{OH})_2$ materijala za punjenje korijenskog kanala na vezivno, koštano i mišićno tkivo

Summary

Among numerous root canal sealers those on the basis of $\text{Ca}(\text{OH})_2$ are used too. The purpose of this study was to examine possible toxic impact of sealers based on $\text{Ca}(\text{OH})_2$ (Sealapex, Kerr and Apexit, Vivadent) on the connective tissue, muscle, bone and cartilage, and compared the results with the impact of sealers based on the polyketonic compound (Diaket, ESPE).

In our experiment 52 female mice of the C-57 BL/6 breed were used. 0.5 ccm of the sealer was injected subcutaneously into the tail root of the laboratory animals.

This experimental model was elected due to this location all the examined structures were present. The control group was injected Hanks. The test period was 2, 8 and 30 days respectively, and the sealers impact was histologically examined. After eight days period, the most severe inflammation develops in Sealapex-injected group. After 30 days period in Apexit group, the mildest inflammatory reaction was found.

The results indicated Apexit to be the mildest irritant and it had not penetrated into the deeper layers of the tissue.

Key words: $\text{Ca}(\text{OH})_2$, endodontic sealers, cytotoxicity

Introduction

Filling the root canal is the final stage in the endodontic therapy of the root canal. The success of the entire endodontic treatment depends on the quality of this work. None of the endodontic sealers (ES) known is ideal (1, 2, 3, 4). There is a variety of ES of various compositions

on the market, which affect the surrounding tissue (5, 6, 7, 8). Recently, we have been using $\text{Ca}(\text{OH})_2$ - based ES, so we wanted to investigate their possible noxious effect on connective tissue, muscles, cartilage, and the bone, and to make a comparison with Diaket, which we have been using most until now.

Dunja Buntak-Kobler
Goranka Prpić-Mehičić
Dora Najžar-Fleger
Marina Katunarić
Jasna Talan-Hranilović*
Lidija Šuman*

Department of Dental
Pathology - School of Dentistry
University of Zagreb
* Ljudevit Jurak Department
of Pathology
»Sestre Milosrdnice« -
University Hospital
Institute Ruđer Bošković,
Zagreb

Acta Stomatol. Croat.
1993; 27: 175-180

ORIGINAL PAPER

Received: 10 June 1993
Primljeno: 10. lipnja 1993.

Materials and methods

In our experiment we have used 51 (fifty-one) C-57 BL/6 female mice. The ES were freshly mixed and injected subcutaneously into the root tail of the laboratory animals, this particular location being chosen for containing all kinds of tissue necessary, i.e. connective tissue, muscles, cartilage, and the bone. The animals were sub-divided into three groups: the first group was injected Apexit (Vivadent), the second was injected Sealapex (Kerr), and the third polyketonic Diaket (ESPE). The control group was injected HANKS. Of each material injected was 0.5 cm. The tissue was fixed in buffered 10% formalin. Decalcination was in the solution of the formic acid and the hydrochloric acid in aqua destillata (120 ccm formic acid + 80 ccm hydrochloric acid and 800 ccm aqua destillata). Paraffin embedded tissue was sectioned and stained with hemalaun and eosin. The animals were sacrificed after 2, 8 and 30 days respectively.

Results

After two days a severe acute inflammation was present in the Apexit-injected group (Fig. 1). Granulocytes were spotted around the accumulations of the material (black coloured). The inflammation was found in the skin, in the subcutaneous tissue, and in the muscles.

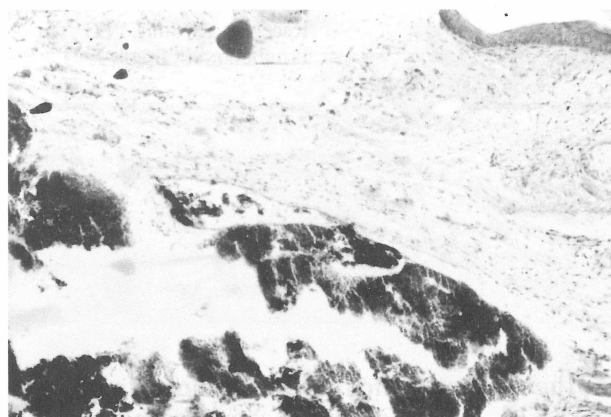


Figure 1. *Apexit, 2 days, black material is accumulated in the subcutaneous tissue with acute inflammation (H & E, 200 X)*

Slika 1. *Apexit, 2 dana, crni materijal se nakuplja u potkožnom tkivu s akutnom upalom (H & E, 200 x)*

In the Sealapex-injected group also and over the same two-day period (Fig. 11) a severe acute inflammation was found; however, in this case, necroses were present after two days. In the control group (HANKS) a mild hyperemia was found, with a low-grade granulocytes infiltration in the corium and the subcutaneous tissue. The inflammation was confined only subcutaneously.

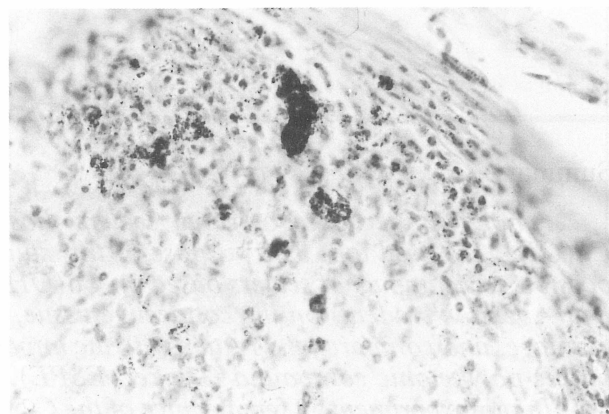


Figure 2. *Apexit, 8 days, black material is dispersed, the abundant inflammatory infiltrate in subcutaneous tissue (H & E, 200 X)*

Slika 2. *Apexit, 8 dana, crni materijal je raspršen, obilni upalni infiltrat u potkožnom tkivu (H & E, 200 x)*

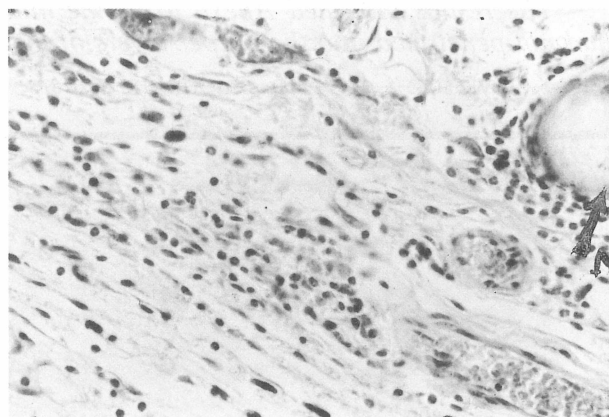


Figure 3. *Apexit, 30 days, the circumscribed necrosis (N) in subcutaneous tissue with the formation of granulation tissue (H & E, 400 X)*

Slika 3. *Apexit, 30 dana, zaokružena nekroza (N) u potkožnom tkivu sa stvaranjem granulacijskoga tkiva (H & E, 400 x)*

After 8 days, in the Apexit group (Fig. 2), necrosis of the epidermis and the initial necrosis of the subcutaneous tissue, as well as skin ulceration, were found. The black material was dispersed in the interstitium. Apart from granulocytes, mononuclears were also found in the inflammatory infiltrate.

In the Sealapex group, 8 days after the injection (Fig. 12), large necrosis areas in the subcutaneous tissue and in the muscles were found, with a dense accumulation of putrefied particles and neutrophils. In this period we find myositis, perichondritis and periostitis, with an initial disintegration of the bone.

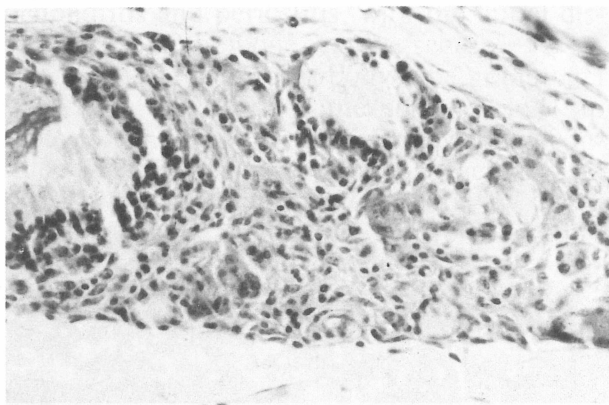


Figure 4. *Apexit*, 30 days, the foreign body granuloma in subcutaneous tissue (H & E, 400 X)

Slika 4. *Apexit*, 30 dana, granulom sa stranim tijelom u potkožnom tkivu (H & E, 400 x)

In the Diaket group, a dense inflammatory infiltration in the skin, subcutaneous tissue (Fig. 5), all the way to the periosteum (Fig. 6), was found over the same eight-day period. In the control group, resorption of the inflammatory infiltrate was noticed on the eight day, with only a few lymphocytes found.

After 30 days, in the Apexit group (Fig. 3), chronic inflammation was present, granuloma with foreign-body giant cells was formed (Fig. 4), and tiny necroses in the subcutaneous area were noticed. The injected material was no longer visible. In the Sealapex group, over the same thirty-day period, bone regeneration, resembling the initial calus, can be noticed. Necroses can be seen in the subcutaneous tissue.

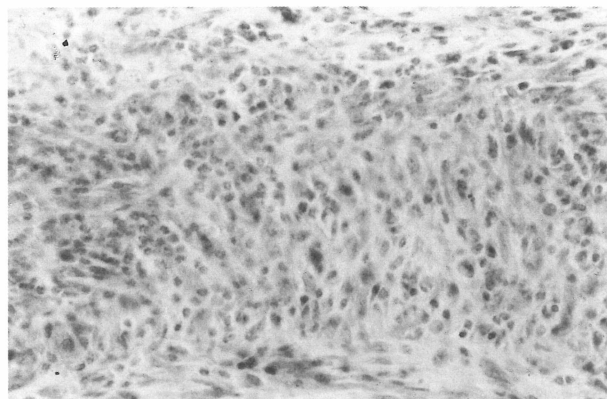


Figure 5. *Diaket*, 8 days, the strong inflammation in subcutaneous tissue (H & E, 400 X)

Slika 5. *Diaket*, 8 dana, jaka upala potkožnog tkiva (H & E, 400 x)

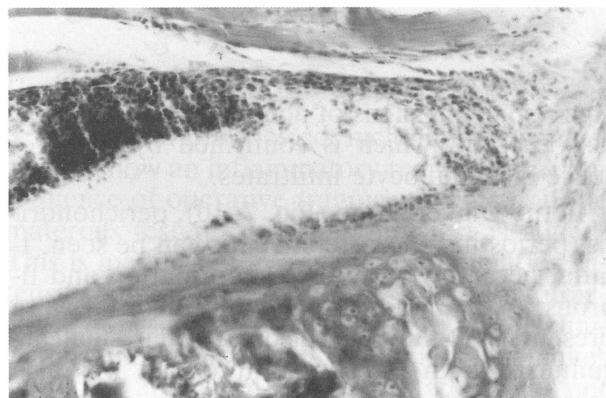


Figure 6. *Diaket*, 8 days, the inflammatory infiltration penetrates to the periosteum (H & E, 400 X)

Slika 6. *Diaket*, 8 dana, upalna infiltracija prodire do periosteuma (H & E, 400 x)

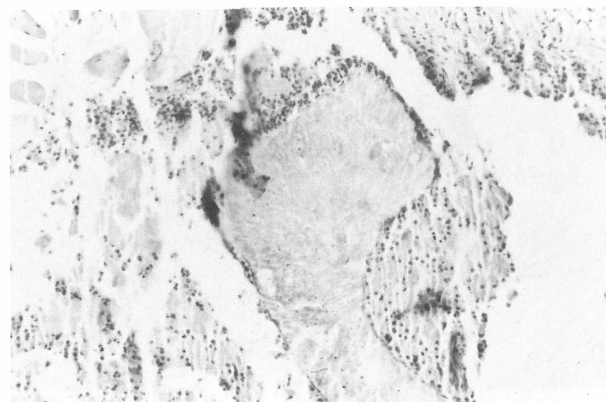


Figure 7. *Diaket*, 30 days, abscesses in subcutaneous and muscular tissue (H & E, 200 X)

Slika 7. *Diaket*, 30 dana, apscesi u potkožnom i mišićnom tkivu (H & E, 200 x)

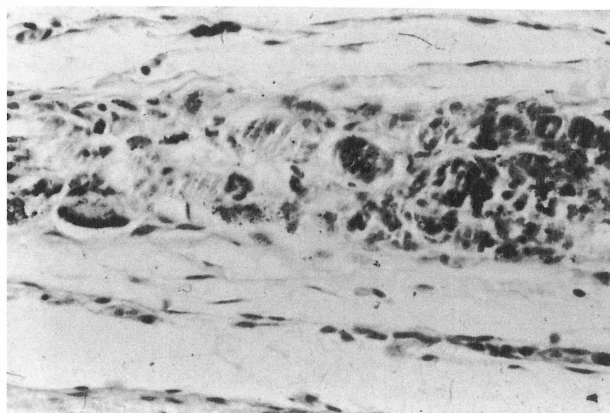


Figure 8. *Diaket, 30 days, the foreign body granuloma with the giant cells (H & E, 400 X)*

Slika 8. *Diaket, 30 dana, granulom sa stranim tijelom s divovskim stanicama (H & E, 400 x)*

Accompanying signs of acute inflammation are also present, which is confirmed by the presence of granulocyte infiltrates.

In the Diaket group (Fig. 7–10), perichondritis, periostitis and osteomyelitis can be seen. Initial necroses, with abscess formation and fibrous encapsulation around the material were present. The material was dispersed in small accumulations in the interstitium, but was also present in the giant cells' cytoplasm.

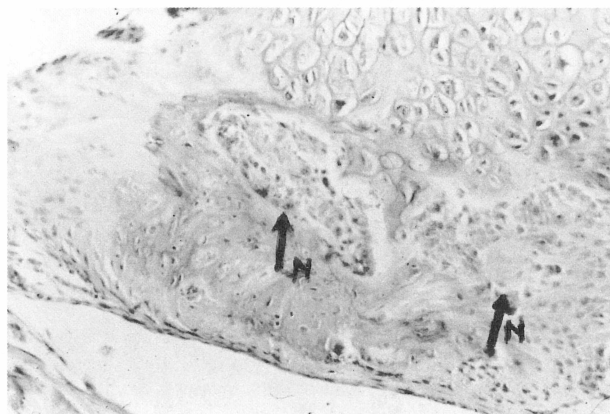


Figure 9. *Diaket, 30 days, the necrosis (N) of the cartilage with chondritis (H & E, 400 X)*

Slika 9. *Diaket, 30 dana, nekroza (N) hrskavice s kondritisom (H & E, 400 x)*




Figure 10. *Diaket, 30 days, periostitis and osteomyelitis (H & E, 200 X)*

Slika 10. *Diaket, 30 dana, periostitis i osteomijelitis (H & E, 200 x)*

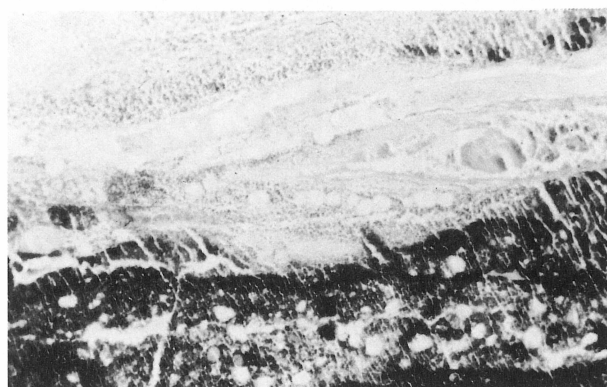


Figure 11. *Sealapex, 2 days, the necrosis of subcutaneous tissue with the accumulation of black material and inflammatory reaction (H & E, 200 X)*

Slika 11. *Sealapex, 2 dana, nekroza potkožnoga tkiva s nakupljanjem crnoga materijala i upalnom reakcijom (H & E, 200 x)*

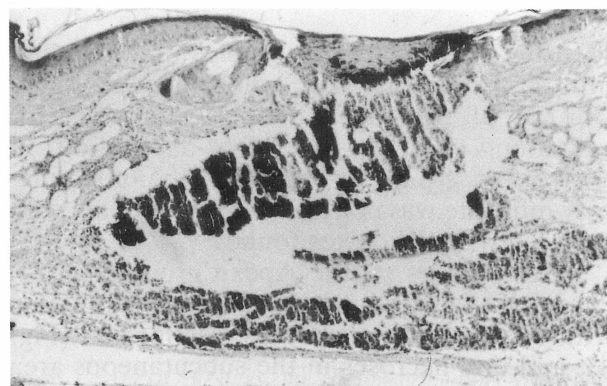


Figure 12. *Sealapex, 8 days, abscess and necrosis of the subcutaneous tissue (H & E, 200 X)*

Slika 12. *Sealapex, 8 dana, apsces i nekroza potkožnoga tkiva (H & E, 200 x)*

Discussion

Histological examination revealed inflammatory reactions of various degrees in all the specimens tested. The results indicated Apexit to be mildest irritant. Inflammation had developed in the skin, subcutaneous tissue, and the muscles. It had not penetrated into deeper layers of the tissue. In this material only tiny initial necroses of the tissue could be seen.

After a thirty-day period the material is not visible in the tissue and it can be reasonably claimed that it had been resorbed.

In Sealapex, a severe inflammation develops faster. After two days, severe inflammation is accompanied by necroses. Sealapex penetrates faster into deeper tissue layers, so myositis, perichondritis and periostitis, with the initial disintegration of the bone, can be seen.

After 30 days, foreign-body type granuloma is present. Since, after the same period, an acute inflammation is also found, we may conclude that Sealapex is continuously active as an irritant, even thirty days after injection.

In Diaket, the inflammation developed more slowly. Eight days after the injection, inflammation was found in the skin, in the subcutaneous tissue, all the way to the periostum. In this material, perichondritis, periostitis and osteomyelitis, but also fibrous incapsulation, can be found, however not before thirty days from the injection have elapsed. This results

differs from the results of Matsumoto et al (9, 10).

We suppose to have obtained the most intense tissue response in Sealapex due to its composition. Benetti-Neto et al (11) have noticed that the materials containing Titanium Dioxide provoke, in contact with the tissue, a strong foreign-body reaction. However, Zmener et al (12) have demonstrated that there was no improvement of the tissue compatibility of Sealapex after Titanium Dioxide had been removed from its composition. Smith et al (13) have noticed that Barium ions too are not biocompatible, because they had found a strong foreign-body reaction of the tissue. Merion and Jakeman (14) had demonstrated that various levels of Zinc concentrations have a high toxic impact on fibroblasts and macrophagi.

Conclusion

All the materials tested, including the control group, show an inflammatory reaction as a consequence of operative trauma, to which, in the materials tested, an irritation effect is added. This is manifested in a higher inflammation intensity and, in some materials, even in cytotoxicity, i.e. tissue necrosis. Therefore, in the clinical treatment, such root-canal filling techniques should be applied in which the material will not be propagated into the periapical region.

CITOTOKSIČNO DJELOVANJE Ca(OH)₂ MATERIJALA ZA PUNJENJE KORIJENSKOG KANALA NA VEZIVNO, KOŠTANO I MIŠIĆNO TKIVO

Sažetak

Među mnogim materijalima za punjenje korijenskih kanala danas se sve više upotrebljavaju oni na bazi kalcijevog hidroksida. Željeli smo ispitati mogući toksični učinak materijala na bazi kalcijevog hidroksida (Sealapex, Kerr i Apexit, Vivadent) i poliketona (Diaket ESPE) na vezivno tkivo, mišiće, kosti i hrskavicu.

U korijen repa 52 miša C-57 BL/6 inicirano je 0,5 ccm ispitivanog materijala. Kontrolnoj grupi iniciran je Hanks. Životinje su žrtvovane nakon 2, 8 i 30 dana i napravljeni su histološki preparati.

Rezultati pokazuju Apeksit kao najblaži iritans od ispitivanih materijala.

Ključne riječi: kalcijev hidroksid, materijali za punjenje korijenskih kanala, citotoksičnost.

Address for correspondence:
Adresa za korespondenciju:

Dr. Dunja Buntak-Kobler
Zavod za dentalnu patologiju
Stomatološkog fakulteta
Gundulićeva 5
41000 Zagreb, Croatia

References

1. RAPPAPORT H M, LILLY G Y, KAPSISMALLS P. Toxicity of endodontic filling materials. *Oral Surg* 1964; 18:785-802.
2. LANGELAND K, GUTTUSO J, LANGELAND L K, TOBON G. Methods in the study of biologic responses to endodontic materials. Tissue response to N 2. *Oral Surg* 1969; 27:622-42.
3. OLSSON B, SILLKOWSKI A, LANGELAND K. Subcutaneous implantation for the biological evaluation of endodontic materials. *J Endodon* 1981; 7:355-68.
4. GUGLIELMOTTI M B, ZMENER O, CABRINI R L. A radiographic, histological, and histometric study of endodontic materials. *J Endodon* 1989; 15:1-5.
5. GUTTLER J H, SAEZ E, JOFRE A, VILLENA F, AGUAYO P. Immune responses induced by root canal cements containing syntetic polymers. *Oral Surg* 1986; 61:388-91.
6. MURPHY V M. An in vitro model for testing biocompatibility of endodontic materials to bone. *Biomaterials* 1985; 6:427-30.
7. NAKAMURA H, SAKAKIBARA F, MATSUMOTO Y et al. Study on the citotoxicity of root canal filling materials. *J Endodon* 86; 12:156-60.
8. TAKAHARA K, ONODERA A, MATSUMOTO K. Toxicity of root canal sealers on rat bone cells in primary culture. *Endod Dent Traumatol* 1990; 6:200-7.
9. MATSUMOTO K, INOUE K, MATSUMOTO A. The effect of newly developed root canal sealers on rat dental pulp cells in primary culture. *J Endodon* 1989; 15:60-7.
10. KETTERING J D, TORABINEJAD M. Citotoxicity of root canal sealers: a study using HeLa cells and fibroblasts. *Int Endod J* 1984; 17:60-6.
11. BENATTI-NETO -C, BRAMANTE C M, BERBERT A, LIA R C C. Reacao do tecido conjuntivo subcutaneo de rato ante a implantacao dos materiais componentes do cimento AH-26. *Rev Bras Odontol* 1982; 39:11-20.
12. ZMENER O, GUGLIELMOTTI M B, CABRINI R L. Tissue response to an experimental calcium hydroxide based endodontic sealer: a quantitative study in subcutaneous connective tissue of the rat. *Endod Dent Traumatol* 1990; 6:66-72.
13. SMITH J W, LEEB I J, TORNEY D L. A comparison of calcium hydroxide and barium hydroxide as agents for inducing apical closure. *J Endod* 1984; 10:64-70.
14. MERYON S D, JAKEMAN K J. The effects in vitro of zinc released from dental restorative materials. *Int Endod J* 1985; 18:191-8.