

THREE DIMENSIONAL (3D) SONOGRAPHY IN THE EARLY DETECTION OF MORPHOLOGIC AND GENETIC DISORDERS

MILAN KOS¹, ASIM KURJAK¹

UDK: 376.36

¹ Medical School University of Zagreb, Department for Gynecology and Obstetrics, "Sveti Duh" General Hospital, Zagreb, Croatia

Over the past two decades, an ever increasing number of studies has appeared trying to predict fetal health in connection with morphological and functional development. Antenatal sonography is a method of choice in early detection of severe developmental disorders, genetic disease and malformation sequences before fetal viability. It enables us to avoid unnecessary damage and consecutive handicaps primarily related to these disorders.

Three dimensional sonography is the modest ultrasonic technology, offering respectable advantages comparing to the conventional two dimensional (B-mode) technology. Modern 3D systems are capable to generate surface and transparent views depicting the sculpture like reconstruction of fetal surface structures or the X-ray-like images of fetal skeletal anatomy. Main advantages of three dimensional technology in the early antenatal diagnosis include scanning in coronal plane, improved assessment of complex anatomic structures, surface scan-analysis of minor defects, "plastic" transparent imaging of fetal skeleton. With arbitrary sectional display in 3D-ultrasonography, the orientation of tomograms is unlimited, despite the limited probe manipulation or unadequate position of fetal structures. Multiple three dimensional reconstructions of stored images (surface and volume rendering) are the most impressive benefits of three dimensional scanning.

Embryonic developmental disorders related to the chromosomal and genetic disorders are at the top of interest within modern sonography. During the first trimester, three-dimensional "surface and sculpture like imaging" do include excellent morphological recognition and follow-up of physiological midgut herniation process and consecutive abdominal anterior wall visualisation. Following the possibilities of three-dimensional transparent mode imaging, the morphology related to nuchal translucency and cystic hygroma could be recognizable earlier than development of biometrically detectable nuchal thickening.

Besides impressive demonstrating of normal fetal structures, 3D ultrasonography is adding "new window" to the diagnosis of structural defects. Fetal face disorders such as cleft lip, dysplastic ear, facial dysmorphism, anophthalmia and proboscis are easier to depict with 3D surface mode. Facial deformities are one marker of chromosomal abnormalities, and 3D technology may be useful for increasing the selectivity of ultrasound screening and confirming normalcy. Similarly, the 3D surface mode enables sculpture like reconstructions of abdominal defects such as omphalocele or gastroschysis. Using this modality, the size and extension of the defect are precisely demonstrated. Surface rendering in 3D ultrasonography gives a clear display of normal extremities. Clubfoot, reversible or irreversible pathological angulation of the normal anatomical axis and other limb abnormalities are easy to define using 3D orientation. Three dimensional imaging is also helpful in assessing the precise relationship of the wrist, hand and fingers. Transparent mode of 3D ultrasonography allows imaging of internal structures, like the fetal skeleton, depicting its malformation in spatial orientation. Three dimensional sonography provides several advantages in evaluating fetal brain and neural tube defects. The level and the extent of defect can be more accurately determined by using simultaneous display of three orthogonal planes combined with volume rendered image. The spine may be evaluated along a curved line in order to evaluate the vertebral bodies in a transverse or axial plane. And finally, three dimensional neurosonography of neonatal brain represents one of the most practical benefits, enabling us detailed and repeated analysis of neonatal central nervous system.

Key words: Fetus, three-dimensional sonography, disorders

Introduction

The first generation of 3D technology, during the early 1980s, had provided a pseudo-3D image by the simultaneous display of the three orthogonal planes and offered some advantages over conventional 2D imaging (Baba 1989, Fredfelt 1984). Modern systems are capable to generate surface and transparent views depicting the sculpture like reconstruction of fetal surface structures or the transparent images of fetal inner anatomy. These are the most impressive products within the modern three dimensional ultrasound imaging. Main advantages of three dimensional technology in perinatal medicine and antenatal diagnosis include scanning in coronal plane, improved assessment of complex anatomic structures, surface analysis of minor defects, volumetric measuring of organs, "plastic" transparent imaging of fetal skeleton, spatial presentation of blood flow arborisation and finally, storage of scanned volumes and images (Merz 1995, Gregg 1993, Kossoff 1994, Kou 1992, Merz 1992, Chiba 1994). With arbitrary sectional display in 3D-ultrasonography, the orientation of tomograms is unlimited, despite the limited probe manipulation or inadequate position of fetal structures. These facts are extremely important in the first trimester of pregnancy, when the manipulation of the vaginal probe is restricted and obtainable ultrasound sections are limited (Feichtinger 1993). An additional progress is achieved owing to the permanent possibility of repeated analysis of previously saved three dimensional volumes and "cartesian" elimination of surrounding structures and artifacts (Fredfelt 1984, Chiba 1994, Baba 1997, Kirbach 1994). Three dimensional reconstruction of stored image is the most impressive benefit of three dimensional scanning. The region of interest (ROI) is first identified and manually delineated, followed by an automatic process of echo extraction. This way, the surface of the organ of interest is displayed in three dimensions. Transparency mode is another way of showing ultrasound images in three

dimensions. In this mode, only the strongest and lowest signals are displayed, so that the internal structure of the organ of interest can be analysed (Jurkovic 1994). A comparison of 2D and 3D techniques shows that 3D provides a diagnostic gain in a large percentage of cases owing to the possibility of surface and transparent mode imaging. Then, the accurate topographic depiction of desired image plane is much easier (Merz 1997, Merz 1995).

First trimester applications

Three dimensional ultrasonography is relatively new diagnostic imaging technique undergoing rapid advances in recent few years, particularly in the field of obstetrics and prenatal diagnosis. Three dimensional scanning offers advantages in assessing the embryonic morphology in the first trimester due to the ability to obtain multiplanar images through an endovaginal volume acquisition. Limitations of transducer movements prohibit obtaining many images on conventional two dimensional scanning. Three dimensional possibility of rotation of the scanned object and close analysis of the scanned volume has allowed more systematic review of embryonic and extra-embryonic anatomy.

Our experience confirms that the transvaginal 3D ultrasonography during the first trimester is related to the significant visualisation benefit, particularly because of an additional possibility for three dimensional morphological and "power-doppler" analysis of embryonic and extra-embryonic "static" structures, such as gestational sac and yolk sac. Embryonic developmental disorders related to the chromosomal abnormalities are at the top of interest within modern sonography. During the first trimester, three-dimensional "surface and sculpture-like imaging" include excellent morphological recognition and follow-up of physiological midgut herniation process, with consecutive abdominal anterior wall visualisation. Three dimensional depiction of retarded resolution of umbilical herniation

and development of omphalocele is possible during 11th and 12th week of gestational age. Following the possibilities of three-dimensional transparent mode imaging, the morphology related to nuchal translucency and cystic hygroma can be recognized earlier than the development of biometrically detectable nuchal thickening. Moreover, case reports such as one by Liang identifying ectopia cordis at 10th weeks gestational age are very encouraging (Liang 1997).

Second and third trimester evaluation

Various studies have already shown that the three dimensional ultrasound can detect or exclude not only major anomalies, but particularly subtle abnormalities. Besides impressive demonstrating of normal fetal structures, 3D ultrasonography is adding "new window" to the diagnosis of fetal malformations. During the second and third trimester, three dimensional sonography make possible a completely new way of visual perception of unborn baby. Reconstructions and sculpture like images, generated from surface rendering mode, are the most impressive presentations. Three-dimensional imaging of the fetal surface greatly refines and expands our capabilities in the evaluation of normal anatomy and in the detection of fetal anomalies (Pretorius 1995, Blaas 1995, Merz 1998, Benoit 1998). Fetal surface abnormalities can be selectively visualized, and the extent of a defect can be determined in all spatial dimensions.

Head and neck malformations

Fetal head is an essential part of routine sonographic examination. Even under optimal conditions, the position of fetal head makes it difficult to obtain adequate images with two dimensional ultrasonography, and many cross sectional images are required to imagine the complete impression of normal structure. Volume rendered three dimensional images of the fetal head are easily recognizable by both families and physicians. One of the most important

aspects of assessing the fetal head with 3D imaging is that fetal face can be depicted in a sculpture like appearance. Complete head can be rotated into various spatial positions. This allows evaluation of different projections of the head and face in a rapid and reproducible fashion from the earliest stage of pregnancy.

In evaluations of the fetal head, scanning with a 3-D probe can clearly demonstrate major anomalies, such as anencephaly or hydrocephaly (**Figure 1**). Dismorphic appearance of fetal anencephalia and acrania can be understood much better presenting the fetal head and neck in three dimensional volume scanning (Kurjak 1999). Dysplastic fetal brain is recognized as an area cerebrovasculosa covering the skull base, and orbits are recognizable as protuberancies on the top of the dysmorphic head. Fetal hydrocephaly is one of the most common malformations detected by ultrasonography, also assessed by three dimensional ultrasonography. Spatial reconstruction of intracranial contents offers "plastic" anatomic and topographic data about ventricle enlargement and consecutive brain tissue damage. If hydrocephalus or holoprosencephaly are present, 3-D surface images of CNS structures can be obtained by electronically eliminating the calvaria from the image. The extent and structure of intracranial tumors can also be evaluated.

Some defects, such as cleft lip, facial dysmorphism, anophthalmia and proboscis are easier to depict with 3D surface mode (Lee 1995, Benoit 1998). Facial changes such as profile abnormalities and facial tumors can be specifically detected or excluded as early as 24 weeks of gestation. These facial and head deformities are important markers of chromosomal abnormalities, and 3D-technology may be useful for increasing the selectivity of ultrasound screening and confirming normal anatomy (Shih 1998). Three dimensional ultrasound can demonstrate all of the mentioned abnormalities and the operator can rotate the image to gain even an impression of the depth of the defect. A simple cleft lip, for example, can be reliably

differentiated from a more severe cleft involving the lip, maxilla, and palate. Volume rendered data offer a real benefit for analysis of some "subsurface" structures inside the head. It is possible to obtain three orthogonal slices of palate, pharynx and soft tissues regardless of intrauterine head position. On the other hand, surface structures of face and head become visible despite significant shadowing or malpresentation from overlying structures.

Lateral head abnormalities such as auricular deformities and low-set ears can also be detected (Shih 1998). It is generally agreed that anomalous shape or size of fetal ears is associated with a number of known morphological and chromosomal syndromes. To recognize a congenital anomaly of fetal ear in-utero is generally difficult, possibly due to the complex shape of the ear and the inherent characteristics of conventional two dimensional ultrasound. Three dimensional surface-imaging of fetal ear offers complete analysis of the details related to phenotypic expression of some inherited syndromes (Kurjak 1998). Through the clues of the anomalous ear obtained from 3D imaging, we can diagnose some other, more subtle fetal anomaly that may be overlooked in a simple, two-dimensional ultrasound scanning.

In the neck region, 3-D transvaginal sonography can clearly demonstrate early changes, such as early nuchal translucency (Kurjak 1999). Transabdominal scanning can detect later changes: larger cystic hygromas, occipital cephalocele, thyroid tumors etc. (Bonilla-Musoles 1998).

Abdomen and thorax

3-D surface rendering in fetuses with dorsal cleft anomalies permits an accurate surface analysis that can clearly differentiate level and extent of protrusive lesion (Hata 1998, Kurjak 2000). Complete rachischysis, isolated spina bifida, myelomeningocele, and some other defects of the spinal column can be easily depicted. Moreover, in a case of myelomeningocele, the sac can be "electro-

nically-resected" to demonstrate the actual surface defect, even if the orifice is quite small. The transparent mode is more useful for detecting abnormalities of the fetal thorax, but in some conditions, such as a very narrow thorax, surface mode technique could be of great clinical importance. The animated rotating display is particularly useful for detecting significant thoracic disproportion relative to the abdomen.

In fetuses with ventral body clefts, 3-D ultrasound offers new capabilities for visualization of the defect and prolapsed organs. Although most of these defects are large and are well depicted by 2-D sonograms, the rotating display enables the defect to be viewed from multiple angles and often provides a better impression of severity of the anomaly. Surface mode enables sculpture like reconstructions of abdominal defects such as omphalocele or gastroschisis. Using this modality, the type and extension of the defect are precisely demonstrated, depicting the size of defect, involved organs consisted, umbilical cord position and amnioperitoneal coverage (Hata 1998). Even the structural changes of fetal skin surface can be evaluated, emphasizing the possibilities of visual demonstration of congenital ichthyosis (Benoit 1999).

Post-processing possibilities of picture offers a possibility for surface imaging of intra-abdominal structures. It is possible to construct any slice nearly parallel to the mother's abdominal wall in arbitrary section or orthogonal triple-section display, thus making it possible to observe the oesophageal-gastric junction and pylorus. The electronic pen or electronic rubber are used to "cut out" the overlying body segments, producing either a longitudinal or transverse section. Once this has been done, pathologic organ can be evaluated separately. Three-dimensional ultrasound confirms suspected multicystic dysplastic kidney as well as renal agenesis, and the pelvic-ureter junction and ureterovesical junctions are easily observable (Candiani 1998).

Extremities and skeleton

Surface rendering in 3D ultrasonography gives clear display of normal and abnormal extremities (Budorick 1998, Hata 1998). Using these techniques it is possible to assess malformations and deformations of fetal extremities and related skeletal structures. Surface-rendered images in 3D ultrasound give quite clear displays of malformations and distortions of the normal anatomical axis (**Figure 2**). With 3D ultrasound, two orthogonal sections can be displayed together. The section at the exact midpoint of the limb can thus be obtained with good reproducibility. Clubfoot, reversible or irreversible pathological angulation of the normal anatomical axis and other limb abnormalities are easy to define using available orientation. Three dimensional imaging is very helpful in assessing the precise topographic relationship between all of three segments of each limb, but also of the wrist, hand and fingers. Congenital deformities and contractures of limbs and joints, related either to the fetal position or to primary neurological damage, are recognizable synchronously in three orthogonal planes depicting their spatial relationship. It is important to note that there will be some fetuses in which it is not possible to scan adequate volumes of the hands and feet due to rapid movements of extremities. Significant disproportion and reduction of extremities associated with skeletal dysplasias can be clearly appreciated in the rotating volume display (Lee 1995). With 3D ultrasound, fingers are also very well observed. It is thus useful for detecting polydactyly, syndactyly and overlapping fingers. Anomalies of the hands and feet should be looked for in screening for chromosomal defects.

Particular importance is related to the visualisation of malformations and deformations of fetal skeleton by volume rendering using transparent mode, maximum mode and "x-ray-like" imaging (Lee 1998). This technique includes the volume rendered imaging possibilities between minimum

and maximum intensity method. Transparent mode of 3D-ultrasonography allows imaging of fetal skeleton, depicting its malformation in spatial orientation. The vertebral column is originally curved antero-posteriorly. If it is pathologically curved laterally, it is impossible to display the whole vertebral column in one two dimensional tomogram. The advantage of 3D ultrasound is the ability to visualize both curvatures at the same time. Anomalies such as scoliosis, kyphosis, lordosis and spina bifida may be overlooked by 2D ultrasound, but are easy to recognize using three dimensional maximum mode (**Figure 3**). Congenital malformations of fetal spine and ribs can be identified easier using 3D surface imaging and transparent mode reconstruction together. Specific vertebral body level may be accurately identified by simultaneous evaluating of axial planes of the spine within a volume rendered image or within the coronal plane image. It is difficult to acquire the entire spine in a single volume and thus multiple volumes are often necessary to evaluate the spine completely. The most impressive transparent mode reconstruction will result in complete skeletal "babygram".

Cardiovascular system

The heart is poorly displayed by 3D ultrasound, owing to its motion. However, there are some reports of its use in the fetal cardiovascular system (Zosmer 1997, Nelson 1998). Kou and colleagues (1992) noted the heart, valves and running of the great vessels to be easily understood on simultaneous orthogonal triple-section display, by scrolling the sections vertical to those corresponding to the four-chamber, five-chamber or short-axis views of the great vessels. Jurkovic and co-workers (1997) observed intra-cardiac anatomy by transparency display and obtained good cardiac images at 20 weeks' gestation. In 3D ultrasound examination of the adult heart with the regular rhythm, 3D data are generally acquired over a period of many heart beatings, monitored by an electrocardiogram (ECG). A 3D image at each

part of the cardiac cycle is constructed using data only for that particular part. For a fetus, an ECG for synchronization is not obtainable. Nelson and colleagues solved this problem by using the movement of a heart wall/valve instead of the ECG, and constructed 3D images of the fetal heart without distortion due to beating (Nelson 1996, Sklansky 1998, Nelson 1998). A four-dimensional (3D + movement) display of the fetal heart was possible by constructing many 3D images at many parts of the cardiac cycle and displaying them in sequence. These authors also measured the cardiac output based on volume change in the lumen of the heart. However, much time was required to obtain 3D data and fetal movements were a significant problem. Smith and associates developed a 2D array probe for obtaining 3D data in real time and applied it to the fetal heart and real-time 3D ultrasound with simultaneous multisection display (Zosmer 1997). Resolution is poor, but a real-time 3D probe with high resolution should become possible with new techniques such as a sparse array.

Fetal tumours

One of the most impressive patterns of 3D ultrasonography is surface rendering of fetal tumours. Fetal tumours alone represent a rare group of morphological disorders and ultrasound diagnosis is always a great challenge for operator. 3D ultrasonography provides accurate and quick detection, associated with instructive visual imaging. Cystic hygroma and sacrococcygeal teratoma are the most frequent fetal tumours easily recognisable by 3D surface mode (**Figure 4**).

Parents with malformed fetuses are provided with clear "photographic" images of the baby, sonographer can evaluate the malformation at the different angles, giving a clear "plastic" impression of the shape and severity of the defect to the parents (Maier 1997).

Three-dimensional neonatal neurosonography

Since its introduction about forty years ago, ultrasound has significantly improved diagnosis of many diseases and conditions in newborn infants, enabling better diagnostics, treatment and prognosis of sick newborns (12). Two-dimensional (2-D) real time ultrasonographic brain examination of newborns was a great diagnostic success in the late seventies (Fischer 1985). In comparison with radiological X-ray brain imaging techniques or magnetic resonance it was more convenient, because of unlimited examination frequency, and less costly, without need for sedation and transportation of infants. Introduction of Doppler studies was a new advancement in the assessment of neonatal brain circulation in the late eighties (Peng 1999). In the nineties, with the development of computer technology, a new and exciting technique of three-dimensional neurosonography was developed, depicting neonatal brain in the third dimension (Kampmann 1998, Nagdyman 1999).

Principles of 3-D neurosonography

Anterior fontanelle, which is open until the age of 18 months is an excellent acoustic window for 2-D and 3-D neurosonography. Three-dimensional neurosonography involves imaging of the distribution of ultrasonic echo information in 3-D space (Baba 1997, Merz 1999, Kurjak 2000). There are various methods for displaying 3-D data, all of which may be collectively referred to as volume visualization. Three dimensional high-resolution (5-8MHz) sector probe swings mechanically in a fan-like manner during volume acquisition, recording sets of tomograms of the brain at fixed angular increments, which are digitalized and saved to the computer memory. Using specialized software, the sonologist can generate orthogonal sets of images in any desired plane through the 3-D volume (construction of 3-D data sets). In addition to the standard

sagittal and coronal planes that are traditionally obtained through the anterior fontanelle when 2-D neurosonography is performed, during 3-D neurosonography the brain can be viewed in axial planes, which can not be obtained by conventional 2-D imaging through the anterior fontanelle. The obtained images are displayed in three orthogonal planes for multi-planar view analysis with the possibility of data manipulation. Once the volume data is acquired, it is possible to scroll through the multi-planar images from anterior to posterior and from left to right to determine if all of the brain has been imaged. After multi-planar analysis of neonatal brain, volume rendering of the region of interest can be performed, with direct projection of 3-D data on a 2-D plane. Depending on the location and the anatomy of the region of interest, either surface or transparent views can be used. The possibility of volumetric studies of the neonatal brain and power Doppler studies of the brain vessels are important parts of 3-D neonatal neurosonography assessment.

Indications for 3-D neonatal neurosonography

Due to a very limited availability of equipment for 3-D neurosonography, which is often connected with the necessity of the transportation of newborns, benefits and risks of 3-D assessment should be taken under consideration before referral for 3-D neurosonography examination. The benefits of the examination should always exceed the risks of deterioration of the newborn's condition. The indications for 3-D neurosonography in newborn period are the same as for 2-D and whenever 2-D is unreliable or doubtful, than 3-D is indicated: intracranial hemorrhage in high risk newborns, hypoxic ischemic brain damage, inflammatory disorders of the brain and its complications, ventriculomegaly and hydrocephaly, congenital brain defects, assesment of gestational age (*Figure 5*).

Benefits of 3-D neonatal neurosonography

Standard 2-D neurosonography often requires 15 to 30 minutes to perform, exposing the critically sick newborn to potentially significant stress. Conventional 2-D imaging of the neonatal brain is accomplished by real time scanning with a series of representative images at selected locations of the brain anatomy, captured for electronic or film archival. Only coronal and sagittal plain after repositioning of the transducer can be obtained, while acquisition of axial plane is impossible. Interpretation is based on this selection, and if questions arise with regard to diagnostic content of the exam, another exam session is necessary to provide additional views. 3-D volume acquisition, lasting 5 minutes in average, supplies adequate diagnostic information, and significantly decreases the examination time, thus exposing neonates to less stress and enabling return to neonatal intensive care unit as quick as possible. The 3-D method minimizes operator-dependent gaps in the information set. The digital data set is saved so that it can be recalled, examined, and interpreted off-line. Although 3-D images of the neonatal brain obtained by X-ray computed tomography (CT) and magnetic resonance imaging (MRI) are quite satisfactory, ultrasonic imaging is in wide use, being found to be highly efficient, economical and safe. In 3-D sonography the quantity of ultrasound irradiation is decreased with shortness of examination exposure. Ultrasonic equipment is much cheaper than X-ray, CT and MRI, requires little space and no special architectural accommodation, and can be operated easily. Therefore, we conclude that 3-D neurosonography will soon become a standard method of assessment of the neonatal and infant brain.

Figures

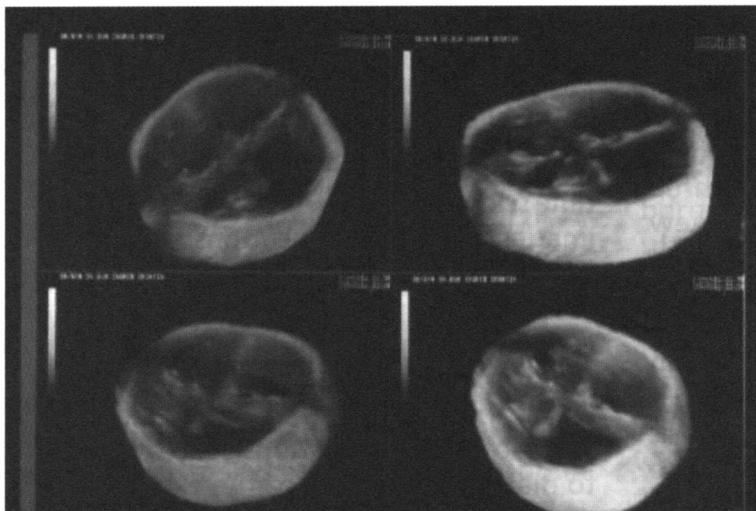


Figure 1. *Fetal hydrocephalus in 23rd week of pregnancy: three dimensional reconstructions from various projections depict inner structures and dilatation of ventricular system filled with increased amount of cerebrospinal liquid.*

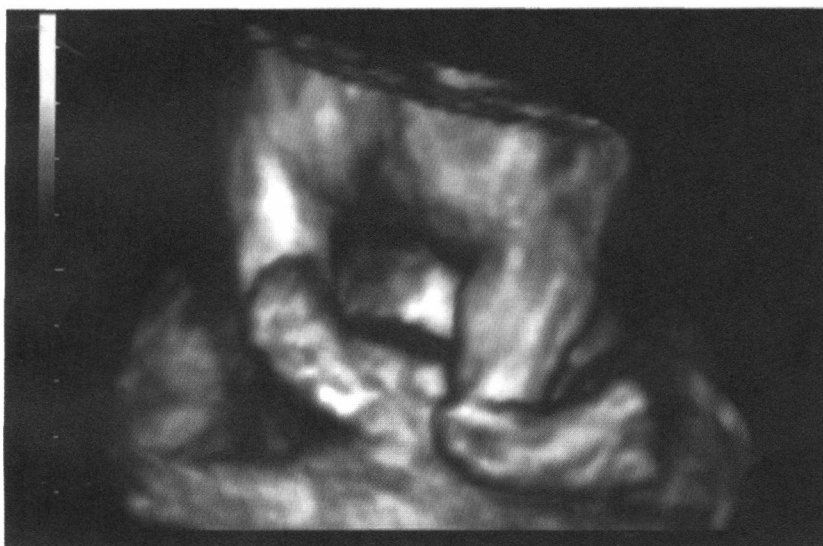
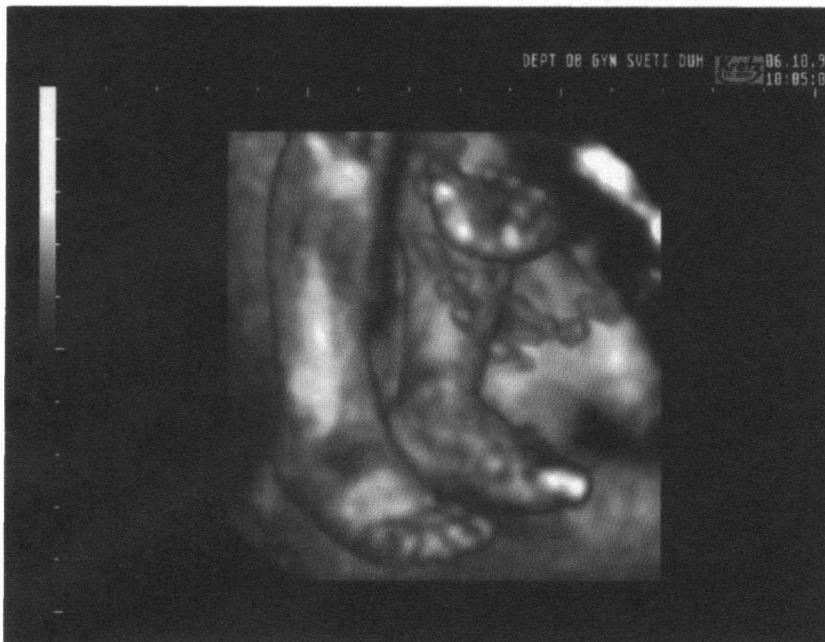
Figure 2.

Fetal legs in 22nd week of pregnancy: normal three dimensional appearance of legs (upper); comparable three dimensional reconstruction of fetal legs in a case of fetal osteochondrodysplasia depicting shortening and deformation of extremities (lower).

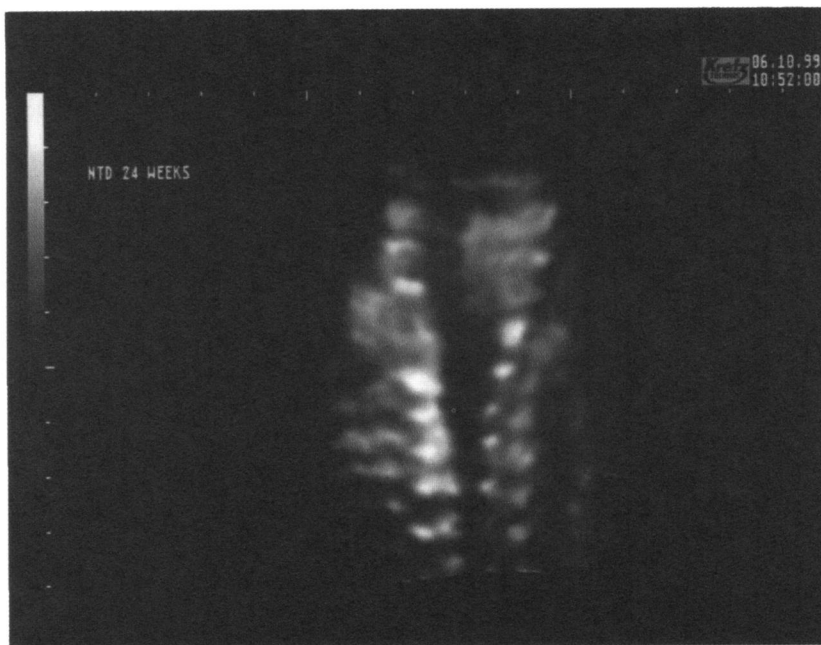


Figure 3.
Neural tube defect (NTD) : three dimensional reconstruction of open defect of fetal cervicothoracal spine (rahyschisis) in 20^h week of pregnancy

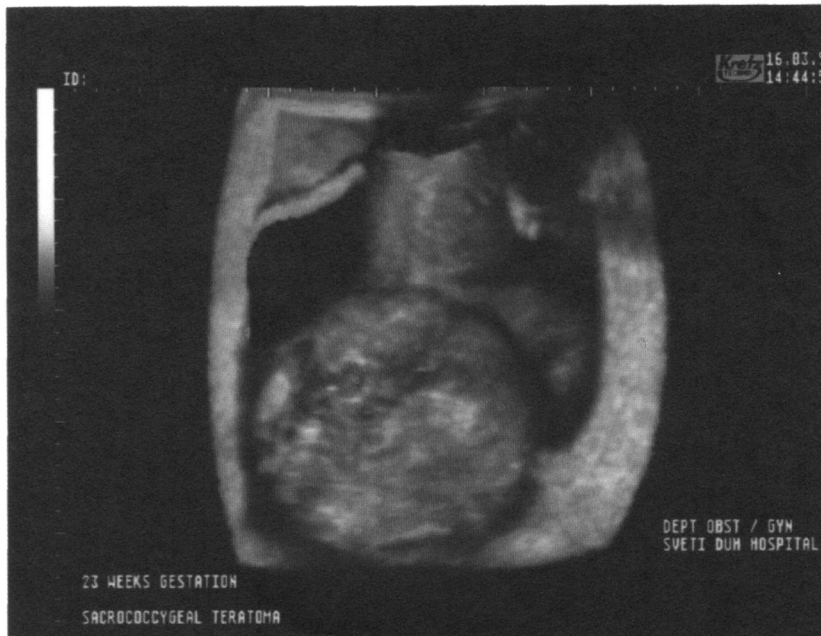

Figure 4.
Fetal tumours : three dimensional "surface mode" reconstruction of large sacrococcygeal teratoma in 21st week of pregnancy.

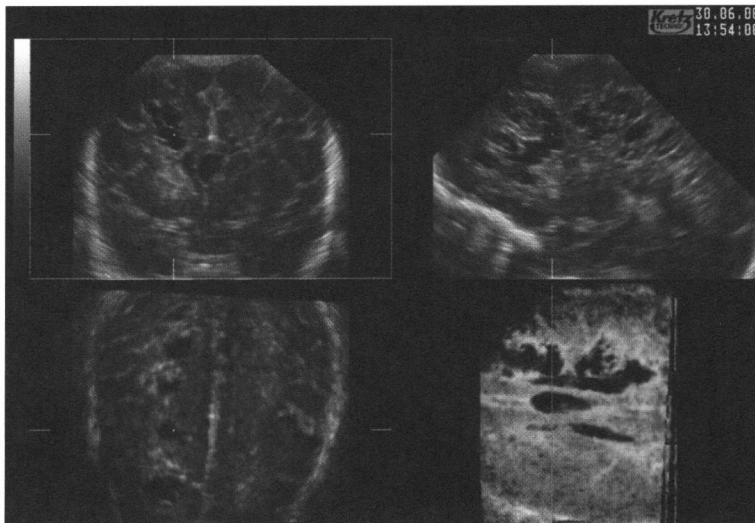


Figure 5.

Three dimensional multiplanar image of neonatal brain with reconstruction of periventricular leukomalacia.

REFERENCES

- Baba, K. & Okai, T. (1997). Clinical applications of three dimensional ultrasound in obstetrics. In: Baba, K. & Jurkovic, D. (ed.) *Three dimensional ultrasound in Obstetrics and Gynecology*, New York - London, The Parthenon Publishing Group.
- Baba, K. & Okai, T. (1997). Basis and principles of three-dimensional ultrasound. In: Baba, K. & Jurkovic, D. (ed.) *Three-dimensional ultrasound in obstetrics and gynecology*. NewYork-London, The Parthenon Publishing Group.
- Baba, K., Satch, K., Sakamoto, S., Okai, T. & Shiego I. (1989). Development of an ultrasonic system for three dimensional reconstruction of the fetus. *J Perinat Med* 17, 19-24.
- Benoit, B. (1998). Three dimensional surface mode for demonstration of normal fetal anatomy in the second and third trimester. In: Merz, E.(ed) *3D Ultrasound in obstetrics and gynecology*. Philadelphia, Lippincot Williams and Wilkins.
- Benoit, B. (1999). Three dimensional ultrasonography of congenital ichthyosis. *Ultrasound Obstet Gynecol* 13, 380-3.
- Blaas, H.G., Eik-Nes, S.H., Kiserund, T., Berg, S., Angelsen, B., & Olstad, B. (1995). Three-dimensional imaging of the brain cavities in human embryos. *Ultrasound Obstet Gynecol* ;5, 228-32.
- Bonilla-Musoles, F. (1998). First-trimester neck abnormalities: three-dimensional evaluation. *J Ultrasound Med* 17, 419-25.
- Budorick, N.E. (1998). Three dimensional ultrasound examination of fetal hands: normal and abnormal. *Ultrasound Obstet Gynecol* 12, 227-34.
- Candiani, F. (1998). The latest in ultrasound: three-dimensional imaging. *Eur J Radiol* 27(2), 179-82.
- Chiba, Y., Hayashi, K., Yamazaki, S., Takamizawa, K. & Sasaki, H. New techniques of ultrasound, thick slicing 3D imaging and the clinical aspects in perinatal field. *Ultrasound Obstet Gynecol* ; 4, 195-8.
- Feichtinger, W. (1993). Transvaginal three-dimensional imaging. Editorial. *Ultrasound Obstet Gynecol* 3, 375-8.
- Fischer, A.Q., Anderson, J.C., Shuman, R.M. & Stinson, W.(1985) *Pediatric neurosonography: Clinical, tomographic and neuropathologic correlations*. New York, Brisbane, Toronto, Singapore. A Wiley Medical Publication.
- Fredfelt, K.E., Holm, H.H. & Pedersen, J.F. (1984). Three dimensional ultrasonic scanning. *Acta Radiol Diagn* 25, 237-40.
- Gregg, A., Steiner, H., Staudach, A. & Weiner, C.P. (1993). Accuracy of 3D sonographic volume measurements. *Am J Obstet Gynecol* 168, 348 -55.
- Hata, T. (1998). Three-dimensional ultrasonographic assesment of umbilical cord during the 2nd and 3rd trimesters of pregnancy. *Gynecol Obstet Invest* 3,159-64.
- Hata,T. (1998). Three-dimensional ultrasonographic assesment of fetal hands and feet. *Ultrasound Obstet Gynec* 12, 235-9.
- Jurkovic, D., Jauniaux, E. & Campbell, S. (1994). Three dimensional ultrasound in obstetrics and gynecology. In: Kurjak, A. & Chervenak, F. (ed.) *Fetus as a Patient*. New York, Parthenon Publishing Group.
- Kampmann, W., Walka, M.M., Vogel, M. & Obladen M.(1998). 3-D sonographic volume measurement of cerebral ventricular system: in vitro validation. *Ultrasound Med Biol* 24,1169-74.
- Kirbach, D. & Whittingham, T.A. (1994). 3D ultrasound - the Kretz Voluson approach. *Eur J Ultrasound* 1, 85-9.
- Kossof, G., Griffiths, K.A., Warren, P.S., Nash, D. & Davis W. (1994). Three dimensional volume imaging in obstetrics. *Ultrasound Obstet Gynecol* 4, 196-200.
- Kou, H.C., Chang, F.M., Wu, C.H., Yao, B.L. & Liu CH. (1992). The primary application of three dimensional ultrasonography in obstetrics. *Am J Obstet Gynecol* 166, 880- 86.

- Kurjak, A. (1999). Three-dimensional transvaginal ultrasound improves measurement of nuchal translucency. *J Perinat Med* 27, 97-102.
- Kurjak, A., Hafner, T., Kos, M., Kupesic, S., & Stanojevic, M. (2000). Three-dimensional sonography in prenatal diagnosis: a luxury or necessity. *J Perinat Med* 28, 194-209.
- Kurjak, A. & Kos, M. (1999). Three dimensional ultrasonography in prenatal diagnosis. In: Chervenak, F.A. & Kurjak, A. (ed.) *Fetal Medicine*. New York, Parthenon Publishing Group.
- Kurjak, A., Kupesic, S., Di Renzo, G.C., Pooh, R., Kos, M. & Hafner, T. (1999) Recent advances in perinatal sonography. *Prenat Neonat Med* 3, 194-207.
- Lee, A., Deutinger, J. & Bernaschek, G. (1995). Three dimensional ultrasound: abnormalities of the fetal face in surface and volume rendering mode. *Br J Obstet Gynaecol* 102, 40-44.
- Lee, A., Kratochwil, A., Deutinger, J. & Bernaschek, G. (1995). Three dimensional ultrasound in diagnosing phocomelia. *Ultrasound Obstet Gynecol* 15, 238-40.
- Lee, A. (1998). Visualization of malformations of the fetal skeleton by volume rendering in three dimensional ultrasound. In: Merz, E. (ed.) *3D Ultrasound in obstetrics and gynecology*. Philadelphia, Lippincot Williams and Wilkins.
- Liang, R.I., Huang, S.E. & Chang, F.M. (1997). Prenatal diagnosis of ectopia cordis at 10 weeks of gestation using two-dimensional and three-dimensional ultrasonography. *Ultrasound Obstet Gynecol* 10, 137-9.
- Linney, A.D. (1999). Three dimensional morphometry in ultrasound-review. *Proc Inst Mech Eng* 213, 235-45.
- Maier, B., Steiner, H., Weinerroither, F. & Standach A. (1997). The psychological impact of three dimensional fetal imaging on the fetomaternal relationship. In: Baba, K. & Jurkovic, D. (ed.) *Three-dimensional Ultrasound in Obstetrics and Gynecology*. New York-London, Parthenon Publishing Group.
- Merz, E. (ed.) (1999). 3-D ultrazvuk u ginekologiji i porodništvu. Zagreb, Naprijed.
- Merz, E. (1997). Update technical applicaton of 3-D sonography in gynaecology and obstetrics. *Ultraschall Med* 18, 190-5.
- Merz, E. (1997). Three-dimensional ultrasound in the evaluation of fetal malformations. In: Baba, K. & Jurkovic, D., (ed.) *Three-dimensional ultrasound in obstetrics and gynaecology*. New York- London, Parthenon Publishing Group.
- Merz, E., Bahlmann, F. & Weber, G. (1995). Volume 3D scanning in the evaluation of fetal malformations - A new dimension in prenatal diagnosis. *Ultrasound Obstet Gynecol* 15, 222-7.
- Merz, E., Bahlaman, F., Weber, G. & Macchiella D. (1995). Three dimensional ultrasonography in prenatal diagnosis. *J Perinat Med* 23, 213-22.
- Merz, E., Bahlaman, F. & Weber, G. (1998). Fetal malformations-assessment by three dimensional ultrasound in surface mode. In: Merz E.(ed.) *3D Ultrasound in obstetrics and gynecology*. Philadelphia, Lippincot Williams and Wilkins.
- Merz, A., Macchiella, D., Bahlmann, F. & Weber, G. (1992). Three dimensional ultrasound for the diagnosis of fetal malformations. *Ultrasound Obstet Gynecol* 2, 137-45.
- Merz, E., Weber, G., Bahlmann, F. & Mirić-Tešanić D. (1997). Application of transvaginal and transvaginal three dimensional ultrasound for the detection or exclusion of malformations of the fetal face. *Ultrasound Obstet Gynecol* 9, 237-43.
- Nagdyman, N., Walka, M.M., Kampmann, W. & Stowver B. (1999).. 3-D ultrasound quantification of neonatal cerebral ventricles in different head positions. *Ultrasound Med Biol* 25, 895-900.
- Nelson, T.R. (1998). Three dimensional fetal echocardiography. *Prog Biophys Mol Biol* 69, 257-72.
- Nelson, T.R., Pretorius, D.H., Sklansky, M. & Hagen-Ansert, S (1996). Three dimensional echocardiographic evaluation of fetal heart anatomy and function: acquisition, analysis and display. *J Ultrasound Med* 15, 1-9.
- Nelson, T.R., Sklansky, M. & Pretorius, D.H. (1998). Fetal heart assessment using three dimensional ultrasound. In: Merz, E.(ed.) *3D Ultrasound in obstetrics and gynecology*. Philadelphia, Lippincot Williams and Wilkins.
- Peng, S.S., Lin, J.H. & Lee, W.T. (1999). 3-D power Doppler cerebral angiography in neonates and young infants : comparison with 2-D Doppler angiography. *Ultrasound Med Biol* 25, 947-51.
- Pretorius, D.H. & Nelson, R.T. (1995). Fetal face visualisation using three dimensional ultrasonography. *J Ultrasound Med* 14, 349-56.
- Shih, J.C. (1998). Antenatal depiction of fetal ear with three-dimensional ultrasonography. *Obstet Gynecol*; 91, 500-5.
- Sklansky, M. (1998). Three dimensional fetal echocardiography: gated versus non-gated techniques. *J Ultrasound Med* 17, 451-7.
- Zosmer, N., Gruboeck, K. & Jurkovic, D. (1997). Three dimensional fetal cardiac imaging. In: Baba. K. & Jurkovic, D. (ed.) *Three-dimensional ultrasound in obstetrics and gynaecology*. New York-London, Parthenon Publishing Group.

TRODIMENZIONALAN (3D) ULTRAZVUK U RANOM OTKRIVANJU MORFOLOŠKIH I GENETSKIH POREMEĆAJA

SAŽETAK

U posljednjih dvadeset godina sve je više istraživanja u kojima se nastoji predvidjeti zdravlje fetusa u vezi s morfološkim i funkcionalnim razvojem. Ultrazvučna dijagnostika metoda je odabira za rano otkrivanje ozbiljnih razvojnih poremećaja, genetskih oboljenja i niza malformacija prije nego što fetus postane sposoban za život. Time možemo izbjeći nepotrebna oštećenja i smetnje koje su prvenstveno povezane uz te poremećaje.

Trodimenzionalni ultrazvuk suvremena je tehnologija koja nudi značajne prednosti u usporedbi s konvencionalnom dvodimenzionalnom tehnologijom. Trodimenzionalnom tehnikom moguće je dobiti površinske prikaze fetusa ili njegovih dijelova nalik pravim fotografijama i prostornim "skulpturnim" prikazima. Osim toga, može se rekonstruirati i providne ili transparentne prikaze fetusa s prikazom unutarnjih organa i skeletne osnove u tri dimenzije.

U glavne prednosti trodimenzionalne ubraja se mogućnost koronarnog presjeka, bolja procjena složenih anatomskih struktura, površinska analiza manjih defekata te "plastični" transparentni prikazi kostura fetusa. Zahvaljujući mogućnosti trodimenzionalne ultrasonografije da se prikažu samo pojedini dijelovi, tomogrami nisu ograničeni u svojem usmjerenju usprkos ograničenjima u manipulaciji sondom ili neodgovarajućem položaju fetalnih struktura. Višestruke trodimenzionalne rekonstrukcije pohranjenih slika (koje prikazuju površinu i obujam) najimpresivnije su prednosti trodimenzionalnog skeniranja.

Razvojni poremećaji embrija koji su povezani s kromosomskim i genetskim poremećajima pobuđuju najviše zanimanja u suvremenoj sonografiji. Tijekom prvog tromjesečja, tridimenzionalne "površinske i skulpturalne slike" omogućuju odlično prepoznavanje morfologije i praćenje fiziološkog procesa hernijacije srednjeg crijeva. Trodimenzionalne transparentne slike omogućuju da se morfologija nugalnog nakupljanja tekućine prepozna prije nego što se može otkriti samom biometrijom.

Osim impresivnog prikazivanja struktura normalnog fetusa, trodimenzionalna ultrasonografija otvara "novi prozor" u dijagnosticiranju strukturalnih oštećenja. Oštećenja lica fetusa, poput zečje usne, displastičnog uha, dismorfije lica i anoftalmije lakše se mogu otkriti površinskim 3D snimanjem. Deformacije lica jedan su od znakova kromosomskih anomalija, pa bi se 3D tehnologijom mogla povećati selektivnost ultrazvučnog slikanja i potvrditi normalno stanje. Slično tome, površinsko 3D snimanje omogućuje skulpturalne rekonstrukcije abdominalnih oštećenja poput pupčane kile i rascjepa prednje trbušne stijenke. Primjenom ove tehnike može se precizno vidjeti veličina i proširenost oštećenja. Površinsko prikazivanje u 3D ultrasonografiji daje i jasniju sliku normalnih udova. Deformirano stopalo, reverzibilno ili ireverzibilno patološko iskrivljenje normalne anatomske osi i druge anomalije udova lako se mogu utvrditi primjenom ove tehnologije. Trodimenzionalno snimanje također pomaže u procjeni točnog odnosa između zapešća, šake i prstiju. Transparentna 3D ultrasonografija omogućuje dobivanje slika unutarnjih struktura, poput kostura fetusa, na kojima se vidi njegova malformacija u prostornoj orijentaciji. Trodimenzionalna sonografija ima nekoliko prednosti u procjenjivanju oštećenja mozga i defekata neuralne cijevi fetusa. Razina i veličina oštećenja može se preciznije odrediti simultanim prikazivanjem triju ortogonalnih ravnina u kombinaciji sa slikom koja prikazuje prostorni 3D snimak. Kralježnica se može promatrati duž njene zakrivljenosti kako bi se ocijenili pojedini kralješci u poprečnom i uzdužnom presjeku. Konačno, trodimenzionalna neurosonografija mozga novorođenčeta predstavlja jednu od najpraktičnijih prednosti jer nam omogućuje detaljnu i ponovljenu analizu središnjeg živčanog sustava novorođenčeta.