

## Pachyonychia Congenita Type 2 (Jackson-Lawler Syndrome) or PC-17: Case Report

Paulo Morais<sup>1</sup>, Lígia Peralta<sup>2</sup>, Manuela Loureiro<sup>1</sup>, Sónia Coelho<sup>1</sup>

<sup>1</sup>Department of Dermatology and Venereology, <sup>2</sup>Department of Pediatrics, Hospital Infante D. Pedro, Aveiro, Portugal

### Corresponding author:

Paulo Morais, MD  
Department of Dermatology and Venereology  
Hospital Infante D. Pedro  
Avenida Artur Ravara  
3814-501 Aveiro  
Portugal  
[paulomoraiscardoso@gmail.com](mailto:paulomoraiscardoso@gmail.com)

Received: February 10, 2012

Accepted: December 10, 2012

**SUMMARY** Pachyonychia congenita (PC) is a rare genodermatosis caused by mutations in any of the four genes *KRT6A*, *KRT6B*, *KRT16*, or *KRT17*, which can lead to dystrophic, thickened nails and focal palmoplantar keratoderma, among other manifestations. Although classically subdivided into two major variants, PC-1 (Jadassohn-Lewandowski syndrome) and PC-2 (Jackson-Lawler syndrome), according to the localization of the mutations in the *KRT6A/KRT16* or *KRT6B/KRT17* genes, respectively, a classification system based on the mutant gene (PC-6a, PC-6b, PC-16 and PC-17) has been recently proposed. We report a 2-year-old female patient with a history of thickened and discolored nails, small cystic papulonodules on the central face, dry, unruly and curly hair, slight palmoplantar hyperkeratosis, and natal teeth. Both her father and paternal grandfather presented onychodystrophy, palmoplantar keratoderma, and previous excision of "sebaceous" cysts. Molecular genetic analysis of the patient revealed a missense mutation (c.1163T>C) in heterozygosity in exon 6 of the *KRT17* gene, confirming the diagnosis of PC-2 (Jackson-Lawler type), or PC-17. We conclude that PC is a relatively easy and consistent clinical diagnosis, but a high index of suspicion is required if the diagnosis is to be made correctly. With this case, the authors intend to draw attention to this condition and the role of the dermatologist in the diagnosis.

**KEY WORDS:** pachyonychia congenita, nails, keratin, keratoderma

### INTRODUCTION

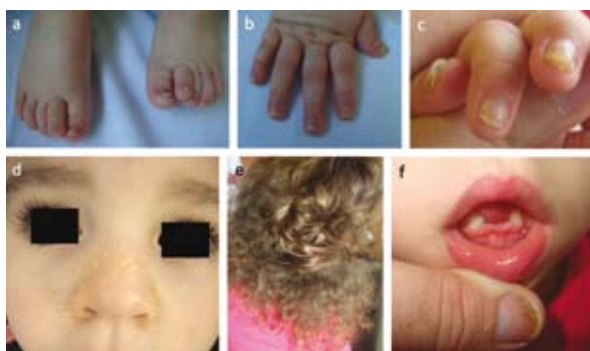Pachyonychia congenita (PC) describes a group of rare autosomal dominant skin disorders characterized predominantly by dystrophic, thickened nails, and painful and highly debilitating palmoplantar hyperkeratosis (1,2). It is caused by heterozygous mutations in any of the genes encoding the differentiation-specific keratins *KRT6A*, *KRT6B*, *KRT16*, or *KRT17* (1-4). PC was historically classified into at least two subtypes according to the clinical features: PC type 1 (MIM #167200, PC-1, or Jadassohn-Lewandowsky syndrome), the more common variant, is character-

ized mainly by nail changes, palmoplantar keratoderma (PPK), follicular keratosis and oral leukokeratosis, while PC type 2 (MIM #167210, PC-2, or Jackson-Lawler syndrome) includes the features of PC-1 plus natal teeth, epidermal inclusion cysts, pilosebaceous cysts such as steatocystomas and vellus hair cysts, and hair abnormalities, including alopecia, *pili torti* (twisted hair) and unruly hair (1,2). A third variant, PC *tarda*, has also been described and is characterized by a later onset that ranges from late childhood to middle age (5). Pathogenic mutations in the genes

encoding keratin 6A (*KRT6A*) or its expression partner keratin 16 (*KRT16*) are associated with the PC-1 phenotype, whereas mutations in PC-2 occur in *KRT6B* or its expression partner *KRT17* (1,2). These keratins are constitutively expressed in keratinocytes of the nail, palmoplantar skin, mucosa, and hair, leading to the manifestations of the disorder at these sites. However, as a considerable overlap between PC subtypes exists and distinct phenotypic differences can occur in the same variant (6), a new nomenclature based on genotyping has been proposed, as follows: PC-6a, PC-6b, PC-16 and PC-17 (1,7).

### CASE REPORT

A 2-year-old female born at term to non consanguineous parents was referred to our outpatient clinic for evaluation of thickened nails starting at the age of 3 months. She presented a history of natal teeth (both mandibular central incisors), and facial pinhead-sized yellowish papules noted at birth, that had slowly grown during the first year of age. Physical examination showed: 1) thickened and discolored nails on all of her fingers and toes, 2) multiple small cystic papulonodules measuring 2 to 10 mm in diameter over the nose and paranasal area, 3) dry, unruly and curly hair, and 4) slight palmoplantar hyperkeratosis (Fig. 1). Curiously, both teeth present at birth were missing in the deciduous dentition, which had meanwhile erupted. There were no lesions in the mucous membranes, hoarseness, follicular keratoses or palmoplantar hyperhidrosis. Her father also presented thickening and



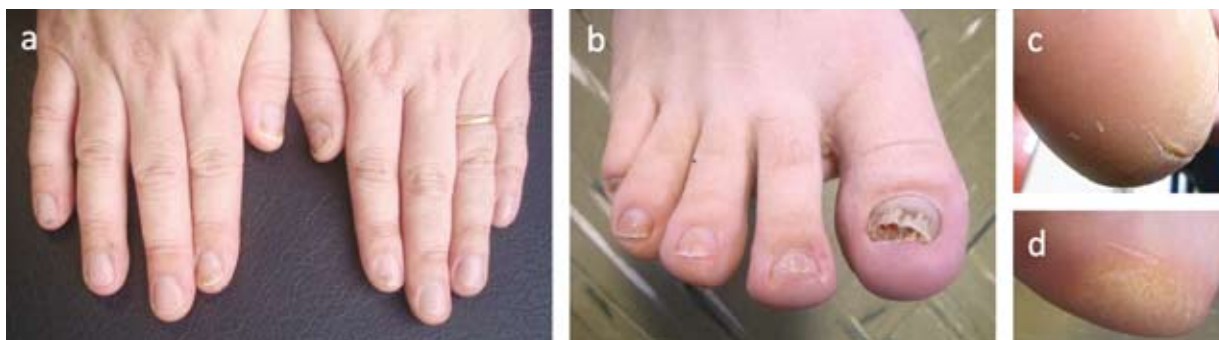
**Figure 1.** Clinical appearance of our patient: hypertrophic nail dystrophy (pachyonychia) with yellowish discoloration on the toenails (a) and fingernails (b,c); small yellowish cysts on the central face (d); dry, unruly and curly hair (e); and absence of both mandibular central incisor teeth, the teeth that were present at birth (f); note distal hyperpigmentation of the left thumbnail of the patient's father (f).

discoloration of nails that improved with age, PPK (Fig. 2), and reported a history of multiple "sebaceous" cysts excised on the trunk. A similar clinical picture was present in the paternal grandfather as well. None of the remaining features present in the girl were detected in her father and grandfather. Mutation analysis revealed a missense mutation (c.1163T>C) in heterozygosity in exon 6 of the *KRT17* gene, resulting in the substitution of leucine by proline at codon 388 (p.Leu388Pro), as the pathological cause of the disorder in the patient. Regular application of 40% urea cream under occlusion was started to soften thickened nails, with some clinical improvement.

### DISCUSSION

According to the new suggestions for nomenclature of PC, our patient fits the PC-17 subtype because a mutation in the *KRT17* gene (c.1163T>C) was detected. This genetic defect was previously identified in another family (3) and seems to include cases of natal teeth, as confirmed here. The occurrence of natal teeth was formerly considered diagnostic of PC-2 but, unfortunately, this feature is not fully penetrant, i.e. not all PC-2 patients present with natal teeth (2). Additionally, cysts are not specific of PC-2 and can also occur in PC-1. These and other reasons justify a genotype-based classification instead of the classic division into PC-1 and PC-2, based on subtly variable phenotypic features.

The majority of keratin mutations are heterozygous missense mutations; in some cases, small in-frame deletion/insertion mutations have been reported. Most mutations occur in the highly conserved helix boundary motifs of the keratin polypeptide, located at either the start or the end of the central keratin rod domain, and individually known as the helix initiation motif and the helix termination motif (8). In our patient, a missense mutation affecting the *KRT17* helix termination motif was identified. In the study by Wilson *et al.* (4) including 90 families with PC, approximately half of the kindreds had mutations in *KRT6A* (52%), 28% had mutations in *KRT16*, 17% in *KRT17*, and 3% of families had mutations in *KRT6B*. The variability of phenotype and incomplete penetrance seen in PC strongly suggest that genetic and/or environmental modifier effects are modulating the genotype-phenotype relationship (2). A strict genotype-phenotype correlation between mutations and clinical severity has not been established, and members of the same family or unrelated patients with the same mutation sometimes display different levels of severity and different clinical spectra (2). In our pedigree, evident onychodystrophy and natal teeth were



**Figure 2.** Clinical appearance of the patient's father: mild thickening of fingernails more evident in the thumb and index, where distal brownish discoloration can also be noted (a); roughness and yellowish discoloration of distal toenails, associated with onychomycosis of great toenail (b); and slight plantar hyperkeratosis with fissuring, more prominent on the heels (c,d).

detected in the girl, but only slight thickening of the nail plate and no history of natal teeth were found in her father and grandfather.

The frequency of clinical findings in PC was reviewed by Leachman *et al.* (2) using data from the International Pachyonychia Congenita Research Registry, the National Registry for Ichthyosis and Related Disorders, and case studies in the literature. The most common (90%-98%) and one of the earliest manifestations of PC was onychodystrophy, followed by plantar pain (91%-96%) and plantar keratoderma (91%-96%), which was more pronounced in weight-bearing or traumatized areas. Hyperkeratosis was less frequent on the palmar surface (60%-80%). Other clinical findings were oral leukokeratosis (75%-95%), follicular keratoses (65%-79%), hyperhidrosis (36%-79%), cysts of any type (35%-72%), laryngeal involvement or hoarseness (16%-70%), hair abnormalities (26%-53%), and natal or prenatal teeth (2%-50%), which are usually lost within the first few months of life, as observed in our patient. Blistering, hyperkeratosis with fissuring, and pain on the palms and soles are the main difficulties for many patients with PC. In the majority of cases (83%), the onset of clinical symptoms occurs within the first year of life (2). In the study by Eliason *et al.* (7), although the age of onset varied considerably among patients, a diagnostic triad of toenail thickening, plantar keratoderma and plantar pain was reported by 97% of individuals with PC by the age of 10 years. They also observed a higher likelihood of oral leukokeratosis in patients harboring *KRT6A* mutations, and a strong association of natal teeth and cysts in carriers of a *KRT17* mutation, as confirmed in our study. A comprehensive and thorough review of clinical features of PC is available elsewhere (1,2,7).

Diagnosis of PC is based on clinical examination and is confirmed by molecular genetic testing. PC

should be differentiated from other conditions characterized by nail dystrophy (e.g., traumatic thickening of nails, congenital onychogryphosis, onychomycosis, twenty nail dystrophy), focal PPK associated with oral leukokeratosis, focal non-epidermolytic PPK, striate PPK or other PPKs, psoriasis, and pityriasis rubra pilaris. Oral leukokeratosis may be mistaken for *Candida albicans* (thrush), leukoplakia and/or white sponge nevus if no other findings of PC are apparent. PC should be also distinguished from the curly hair-acral keratoderma-carries syndrome, Clouston syndrome, and congenital dyskeratosis (9). Most of these conditions lack the features of PC or have distinctive characteristics, making them easy to recognize, if detailed history and physical examination are performed. However, biopsy, microbiological studies, genetic testing and others may be necessary for a conclusive diagnosis.

Like most genodermatoses, no specific treatment or cure is known for PC-2. Therapy is generally directed towards symptomatic improvement of the most troublesome manifestations of the disease (10). Mechanical thinning of thick nails and calluses with a variety of hand tools such as pumice stones, emery boards, paring knives, razor blades, clippers, curettes, rasps, and files may be helpful. Some patients use electrical tools, such as grinders, polishers, and sanders, to reduce thickened nails. Softening of the nails and calluses can also be achieved with overnight application of topical keratolytics under occlusion, such as pastes of 20%-40% urea or 15%-20% salicylic acid (10). Systemic retinoids make the keratin more flexible and less pronounced without complete clearing. Although they can be effective in some patients with PC, treatment is generally unsatisfactory (11). Risk/benefit analysis favors lower retinoid doses ( $\leq 25$  mg/d) over a longer time period ( $> 5$  months). However, many patients discontinue medication

because adverse effects outweigh the benefits (11). In last instance, surgical avulsion and matrix destruction followed by scarification of the nail bed to prevent re-growth can be performed. Treatment of hyperhidrosis appears to be helpful in decreasing blistering and pain and can be achieved with agents such as aluminum chloride, oral administration of glycopyrrolate or plantar injections of botulinum toxin (10,12). Hickerson *et al.* (10) showed that the macrolide sirolimus (rapamycin) selectively blocks K6a expression in human keratinocytes. The improvement of symptoms in PC patients following this treatment, including reduction of painful plantar thromboses and keratoses suggests that rapamycin (or rapamycin analogs) may be a good future treatment option, particularly if topical formulations can be developed to avoid the unacceptable gastrointestinal and mucocutaneous side effects associated with systemic administration (13). Other authors found that simvastatin and other statins inhibit K6a promoter activity and K6a protein expression, opening the scene for further clinical trials with statins as a possible therapeutic option for PC patients (14). Finally, some studies revealed that small interfering RNAs (siRNAs) could specifically and very potently block expression of mutant K6a in the skin and support development of these inhibitors as potential therapeutic agents for the treatment of PC (15).

## CONCLUSION

Although PC does not endanger an individual's life, it may significantly impair the quality of life. Understanding the genetic basis of the disease allows better counseling for patients, creates new options for suitable therapeutic regimens, and even offers hope of curing such type of skin disease by means of gene therapy. Diagnosing and managing PC in early childhood are critical to help the affected children.

## References

1. McLean WH, Hansen CD, Eliason MJ, Smith FJ. The phenotypic and molecular genetic features of pachyonychia congenita. *J Invest Dermatol* 2011;131:1015-7.
2. Leachman SA, Kaspar RL, Fleckman P, Florell SR, Smith FJ, McLean WH, *et al.* Clinical and pathological features of pachyonychia congenita. *J Invest Dermatol Symp Proc* 2005;10:3-17.
3. Smith FJ, Liao H, Cassidy AJ, Stewart A, Hamill KJ, Wood P, *et al.* The genetic basis of pachyonychia congenita. *J Invest Dermatol Symp Proc* 2005;10:21-30.
4. Wilson NJ, Leachman SA, Hansen CD, McMullan AC, Milstone LM, Schwartz ME, *et al.* A large mutational study in pachyonychia congenita. *J Invest Dermatol* 2011;131:1018-24.
5. Paller AS, Moore JA, Scher R. Pachyonychia congenita tarda. A late-onset form of pachyonychia congenita. *Arch Dermatol* 1991;127:701-3.
6. Spaunhurst KM, Hogendorf AM, Smith FJ, Lingala B, Schwartz ME, Cywinska-Bernas A, *et al.* Pachyonychia congenita patients with mutations in K6a have more extensive disease compared to patients with mutations in K16. *Br J Dermatol* 2012;166:875-8.
7. Eliason MJ, Leachman SA, Feng BJ, Schwartz ME, Hansen CD. A review of the clinical phenotype of 254 patients with genetically confirmed pachyonychia congenita. *J Am Acad Dermatol* 2012;67:680-6.
8. Liao H, Sayers JM, Wilson NJ, Irvine AD, Mellerio JE, Baselaga E, *et al.* A spectrum of mutations in keratins K6a, K16 and K17 causing pachyonychia congenita. *J Dermatol Sci* 2007;48:199-205.
9. Smith FJD, Hansen CD, Hull PR, *et al.* Pachyonychia congenita. 2006 Jan 27 [Updated 2011 Dec 1]. In: Pagon RA, Bird TD, Dolan CR, *et al.*, editors. *GeneReviews™* [Internet]. Seattle (WA): University of Washington, Seattle; 1993. Available from: <http://www.ncbi.nlm.nih.gov/books/NBK1280/>
10. Milstone LM, Fleckman P, Leachman SA, Leigh IM, Paller AS, van Steensel MA, *et al.* Treatment of pachyonychia congenita. *J Invest Dermatol Symp Proc* 2005;10:18-20.
11. Gruber R, Edlinger M, Kaspar RL, Hansen CD, Leachman S, Milestone LM, *et al.* An appraisal of oral retinoids in the treatment of pachyonychia congenita. *J Am Acad Dermatol* 2012;66:e193-9.
12. Swartling C, Vahlquist A. Treatment of pachyonychia congenita with plantar injections of botulinum toxin. *Br J Dermatol* 2006;154:763-5.
13. Hickerson RP, Leake D, Pho LN, Leachman SA, Kaspar RL. Rapamycin selectively inhibits expression of an inducible keratin (K6a) in human keratinocytes and improves symptoms in pachyonychia congenita patients. *J Dermatol Sci* 2009;56:82-8.
14. Zhao Y, Gartner U, Smith FJ, McLean WH. Statins downregulate K6a promoter activity: a possible therapeutic avenue for pachyonychia congenita. *J Invest Dermatol* 2011;131:1045-52.
15. Smith FJ, Hickerson RP, Sayers JM, Reeves RE, Contag CH, Leake D, *et al.* Development of therapeutic siRNAs for pachyonychia congenita. *J Invest Dermatol* 2008;128:50-8.

