

Measuring of Corneal Thickness of Contact Lens Wearers with Keratoconus and Keratoplasty by Means of Optical Coherence Tomography (OCT)

Gustav Pöltner^{1,2,3,4}, Klaus Miller⁵, Andreas Berke⁶ and Wolfgang Sickenberger⁷

¹ Contactlinseninstitut Miller, Innsbruck, Austria

² HTL-Kolleg-Optometrie, Hall in Tirol, Austria

³ Fhg, Fachhochschule für Tiroler Gesundheitsberufe, Innsbruck, Austria

⁴ University of Applied Sciences Velika Gorica, Velika Gorica, Croatia

⁵ Facharztpraxis Dr. Klaus Miller, Innsbruck, Austria

⁶ HFA, Höhere Fachschule für Augenoptik, Köln, Germany

⁷ Fachhochschule Jena, Jena, Germany

ABSTRACT

To measure the corneal thickness and the depth of the precorneal tear film of contact lens wearers with keratoconus or keratoplasty and to reconfirm the identification and classification of the keratoconus with optical coherence tomography (OCT). The cornea and precorneal tear film of 123 eyes with keratoconus, of 39 eyes after keratoplasty and 8 eyes after LASIK were examined with an OCT (Zeiss Visante™) and a keratograph (Oculus). Visual acuity was determined. The mean age of all patients was 42.7 years ($\sigma=9$). There were 35% female patients and 65% were male patients. The central corneal thickness of 123 eyes with keratoconus was $467 \pm 73 \mu\text{m}$. The nasal and especially the inferior corneal periphery exhibit a 9% lesser thickness ($426 \pm 83 \mu\text{m}$). The cornea with keratoconus is thinner in the 90° meridian, than in the 180° meridian [$p<0.01$]. This could be a clinically relevant result for the reduction of astigmatism after keratoplastic surgery. The central corneal thickness of 39 eyes with keratoplasty was $555 \pm 65 \mu\text{m}$. These eyes showed peripheral parts with even less thickness. The thickness of the precorneal tear film of 114 contact lens wearers with keratoconus was $89 \pm 42 \mu\text{m}$ in the horizontal meridian, $113 \pm 56 \mu\text{m}$ in the vertical meridian. All the comparative results in case of keratoconus, keratoplasty and the depth of the precorneal tear film had high statistical significance ($p<0.001$). Optical coherence tomography is particularly suitable for the examination of eyes with keratoconus and keratoplasty. It delivers new insight into corneal thickness of eyes with keratoconus and keratoplasty.

Key words: keratoconus, keratoplasty, corneal thickness, precorneal tear film, optical coherence tomography

Introduction

In this study the exact measuring possibility by means of Zeiss Visante™ OCT is used to measure the corneal thickness and the tear film in cases of keratoconus and keratoplasty.

This is a prospective multiactive field study in which the measuring device Zeiss Visante™ OCT has been used to measure the contact lens wearers with keratoconus or keratoplasty.

Including and excluding criteria

All the test persons are keratoconus or keratoplasty lens candidates or wearers, patients of the Company

Institut Miller Contactlinsen GmbH, Meranerstr. 3, A-6020 Innsbruck. All the patients had agreed voluntarily to have their eyes measured with Zeiss Visante™ OCT device and had given their consent that their data could be used in the current study.

The test persons have been selected according to the following criteria:

- A) persons who had a keratoconus on one or both sides;
- B) persons who had keratoplasty on one or both sides.

Persons excluded from this study were the persons with »normal« corneal geometries.

Further in the text the identification and classification of keratoconus should be confirmed.

Material and Method

A total of 172 eyes with keratoconus (n=123), keratoplasty (n=39) or after LASIK (n=8) with an average age of 42.67 ($\sigma=9$) years were measured. (♀35% ♂65%). In all patients the Zeiss Visante™ OCT was used to measure the cornea and precorneal tear film and the subjective visibility was found. Furthermore, the corneal topography was calculated with the Oculus-keratograph. In all contact lens wearers the fluorescein picture was taken digitally.

Not every keratoconus customer could be measured, since the Institut Miller Contactlinsen GmbH has to realize a very strict schedule in customer management. Further, the patients with e.g. very short blinking frequency were not even addressed. Therefore, only about every third or fourth keratoconus customer could be included in the measuring data pool. Moreover, the measuring device could be leased for only eight weeks.

In Figure 1 you can see the distribution of the examined eyes examined eyes.

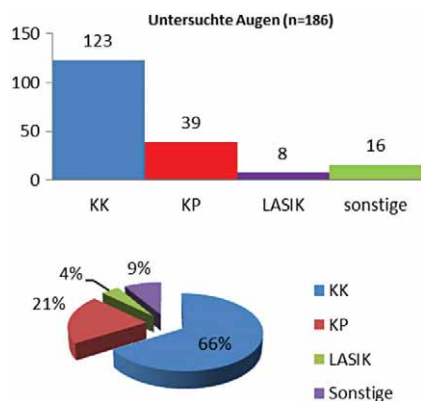


Fig. 1. Distribution of the examined eyes Examined eyes.

A total of 186 eyes could be included. A hundred and twenty-three eyes, i.e. 66% of all the examined eyes had a keratoconus, 39 eyes, that is 21% had after keratoconus also keratoplasty, 8 eyes, that is 4% got after LASIK again the contact lenses and 16 eyes (9%) were measured, because they wore e.g. a quite recently developed bifocal lens, or to solve other special characteristics. The following table shows this graphically.

Apart from OCT data the corneal geometry and astigmatism were studied for every eye with Oculus-keratograph, as well as Visus Vcc with eyeglasses and Visus Vcc with contact lens.

The used contact lens types were the lenses of the Company Hecht in Freiburg (D) or lenses of the Company FALCO in Tägerwilen from Switzerland.

Experimental Conditions

General conditions

In all patients the corneal geometry in both eyes was analyzed by means of Oculus®-keratograph. After that the Visucat® System was used to perform the refraction and to determine the visus. After successful contact lens fitting the fluorescein picture was taken by means of BON® Digital-slitlamp. Then the analysis was performed with Visante™ OCT of Zeiss Meditec. The OCT measurements were almost always done with the contact lens in the eye. Therefore, a previous dioptre compensation was not necessary. In case of measurements that were carried out without the contact lenses, in the majority of cases the dioptre compensation could not be performed since high astigmatism and extreme irregularity, which is common for the keratoconus cases, made the dioptre compensation impossible.

Optical Coherence Tomography (Visante™ OCT)

The implemented optical coherence tomography (OCT) was based on the principle of Michelson-Interferometry in combination with the Scheimpflug-procedure. Thus, high-resolution in-vivo sectional images are obtained that present the cornea in profile. The share of the light reflected from the tissue is analyzed by the device software and presented as a scaled grey and/or false-colour image.^{11,12}

The best known OCT application is the examination of the rear eye segment. For the retinal sectional images a wavelength of 820 nm is used. For the corneal sectional images a superluminescent-diode is used as the source of light, with wavelength of 1,310 nm. The optical performance of the diode on the cornea is below <6.5 mW. The light in the near infrared area allows higher water absorption and thus higher energy and scan speed. With this device it is possible, even in case of a blurred cornea, to obtain usable images.¹³ Depending on the tissue distance, it is possible to reach an axial resolution of 18 µm and an axial scan precision of ±15 µm. The value of 60 µm is given as the transversal resolution and the value of ±160 µm as the transversal scan precision.

The low coherence interferometry leads the light on two optical paths. The scanning path represents the path into the eye and the reference path is the light path through the interferometer. The superluminescent-diode emits at a wavelength of 1,310 nm and has therefore only a very small penetration depth into the eye. In the photo-detector the reference waves of the reference path are superimposed over the waves of the scanning path. The power of the superimposed signal is a measure for the reflex level of a relatively small tissue volume at the scanning point. If the optical length of the reference path is changed by means of the reference mirror, the interferometer can determine the axial depth of the tissue using the signal that returns from the scanning point. This procedure is similar to the procedure of Ultrasound-A-Scans. The device guides the scanning beam transversally over the eye. Similar to an Ultrasound-B-Scans,

two-dimensional images can be produced from several A-Scans recorded by the device. The obtained sectional images, i.e. tomograms, are analyzed and saved by the software within the device.

Figure 2 shows that the Optical Coherence Tomography (OCT) is based on the principle of Michelson-Interferometry.

The measurements are performed without contact and without local anaesthesia. With the help of the Scheimpflug procedure the OCT produces sharp sectional images and is extremely suitable for the measuring of the anterior chamber depth, corneal thickness, as well as the measuring of the safety distance between the phakia intraocular lens and the corneal endothelium.^[14]

The simpler procedures of measuring the corneal thickness, such as the manual pachimeter, an additional device to a slitlamp, or the measuring of the chamber depth according to Smith or the assessment of the depth of the chamber angle according to Van Herick, cannot compete with the measuring precision of an OCT.

Also, other image-producing devices, such as e.g. Ultrasound Biomicroscopy, in spite of having a higher penetration depth into the tissue, still have a significantly lower resolution than the OCT.

Results

The data were processed by means of Microsoft Excel and the statistical evaluation was performed by BIAS software for Windows. This is a program that has been designed specifically for the medical scientific area.

Apart from the mean values and the standard deviation, also the medians, regression coefficient and the correlation coefficient have been found.

Inference statistics was used to carry out the comparison of the measuring series with the Wilcoxon-Test.

The mean values have been presented graphically by BIAS Box&Bar-Plots. The points cloud with the subsequently marked equivalence lines were produced in Excel.

The frequency distribution has been presented with bar charts. Since they did not correspond to the curve of normal distribution, the Kolmogorov-Smirnov-Lilliefors Test was additionally also applied, thus representing also the sum frequency of the ideal normal distribution.

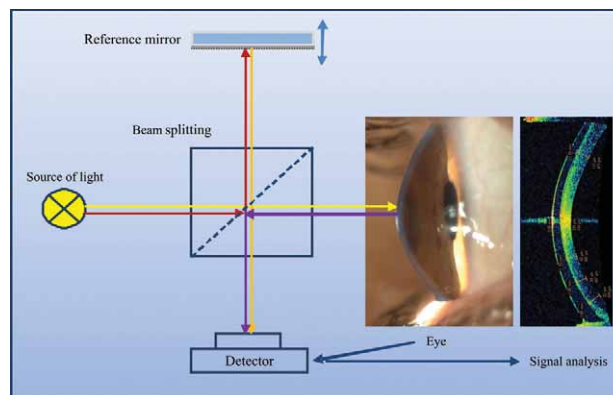


Fig. 2. Optical Coherence Tomography (OCT) based on the principle of Michelson-Interferometry.

In order to present separately the level of the deviation of the two measured values, the difference of the measured value was presented graphically in relation to the mean value of the measured values. Starting from the mean difference, it is possible to present an interval of two standard deviations of the differences above and below the mean difference. In this way it is easy to observe whether the deviations of the measured values are strongly dispersed or limited to a narrow area around the mean difference.

The following diagrams present only a small selection of the processed results. The result in 90° meridian in case of keratoconus with its thinnest point and the comparison of the total 180° and 90° meridians, are representatives for all the other obtained data.

Comparison of the thickness conditions in 90° meridian

The central and peripheral corneal thickness was measured in 123 eyes with keratoconus.

The mean values of standard deviation, minima and maxima of corneal thickness in 90° meridian, you see in Table 1.

See Figure 3 – Box-Plot Diagram of central and peripheral corneal thickness in 90° and Figure 4 you can see the difference of central and peripheral corneal thickness in 90° meridian. This presentation emphasizes that the difference between central and peripheral thickness is signif-

TABLE 1
MEAN VALUES, STANDARD DEVIATION, MINIMA AND MAXIMA OF CORNEAL THICKNESS IN 90° MERIDIAN

n=123	Central thickness 90°	Peripheral thickness 90°	Difference
Mean value	467 µm	551 µm	-84 µm
Standard deviation	73 µm	99 µm	-25 µm
Mean value + 2 σ	614 µm	749 µm	-135 µm
Mean value - 2 σ	320 µm	353 µm	-33 µm
Minimal value e	173 µm	141 µm	34 µm
Maximal value e	638 µm	733 µm	-95 µm

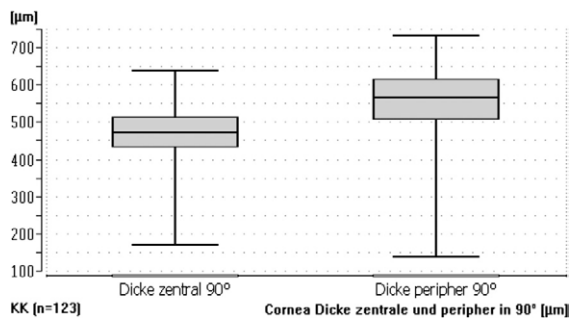


Fig. 3. Box-Plot Diagram of central and peripheral corneal thickness in 90°.

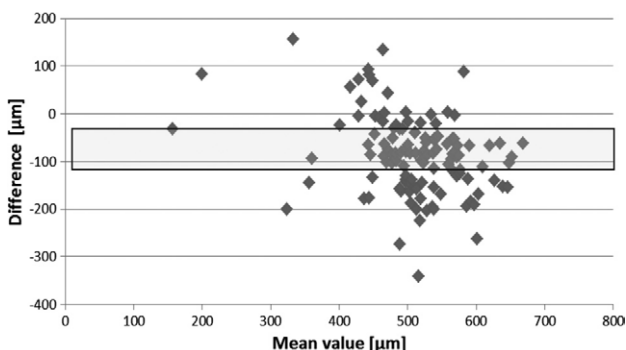


Fig. 4. Difference of central and peripheral corneal thickness in 90° meridian. This presentation emphasizes that the difference between central and peripheral thickness is significant. The majority of differences of central and peripheral corneal thicknesses lie outside the interval of the double standard deviation around the mean difference.

icant. The majority of differences of central and peripheral corneal thicknesses lie outside the interval of the double standard deviation around the mean difference.

The statistical evaluation of the measured values of the central and peripheral corneal thicknesses of all 123 examined eyes with the Wilcoxon-Test showed that the differences of both these thicknesses are statistically highly significant ($p < 0.001$).

Comparison of thickness relations of total 180° and 90° meridians in case of keratoconus (n=123)

The central and peripheral corneal thicknesses were measured in 123 eyes with keratoconus in 180° and 90° meridians.

Table 2 shows the mean values of the standard deviation, the minima and the maxima central and peripheral in 180° and 90°. The measured values of corneal thickness in central and peripheral meridians in 180° and 90° of 123 eyes with keratoconus were added for this comparison so as to provide a better presentation of the thickness differences of both meridians. In Table 3 you see the mean values of the standard deviation, the minima and the maxima of the total meridian in 180° and 90°. And in Figure 5 shows the fluctuating line of the Kolmogorov-Smirnov-Lilliefors Measurement of the en-

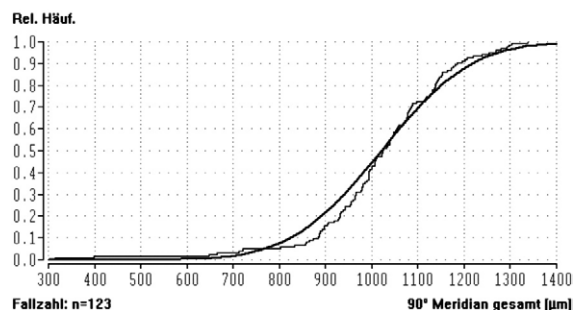
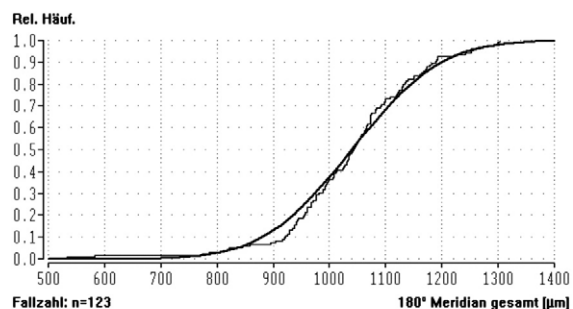


Fig. 5. The fluctuating line shows the Kolmogorov-Smirnov-Lilliefors Measurement – of the entire meridian thickness in 180° and 90°. The solid line shows the sum frequency of an ideal normal distribution. (KC n=123).

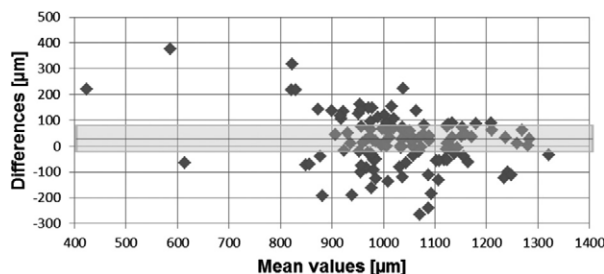


Fig. 6. Difference of the entire 180° and 90° meridians.

tire meridian thickness in 180° and 90°. The solid line shows the sum frequency of an ideal normal distribution. (KC n=123).

And in Figure 6 you see the difference of the entire 180° and 90° meridians. This presentation emphasises that the difference between 180° and 90° Meridian is significant. The majority of differences of the entire Meridian thickness lies outside an interval of the double

The statistical evaluation of the entire corneal meridians in 180° and 90° of all 123 examined eyes with the Wilcoxon-Test has shown that the differences of both these measurements in the centre at 180° and 90° are statistically significant ($p < 0.01$).

Discussion

The objective of the study was to use Zeiss Visante™ OCT in order to measure the corneas with keratoconus and keratoplasty, so as to find answers to the following questions:

TABLE 2
MEAN VALUES, STANDARD DEVIATION, MINIMA AND MAXIMA CENTRAL AND PERIPHERAL IN 180° AND 90°

n=123	Central thickness 180°	Peripheral thickness 180°	Central thickness 90°	Peripheral thickness 90°
Mean value	471 µm	567 µm	467 µm	551 µm
Standard-deviation	76 µm	70 µm	73 µm	99 µm
Mean value + 2 σ	623 µm	706 µm	614 µm	749 µm
Mean value – 2 σ	319 µm	427 µm	320 µm	353 µm
Minimal values	173 µm	361 µm	141 µm	173 µm
Maximal values	610 µm	707 µm	638 µm	733 µm

TABLE 3
MEAN VALUES, STANDARD DEVIATION, MINIMA AND MAXIMA OF THE TOTAL MERIDIAN IN 180° AND 90°

n=123	Corneal thickness in 180° meridian	Corneal thickness in 90° meridian	Difference
Mean value	1038 µm	1018 µm	19 µm
Standard deviation	125 µm	154 µm	29 µm
Mean value +2 σ	1287 µm	1326 µm	-39 µm
Mean value -2 σ	789 µm	711 µm	78 µm
Minimal value e	534 µm	314 µm	220 µm
Maximal value e	1304 µm	1338 µm	-34 µm

1. Is it possible to identify a keratoconus with an OCT device?
2. What are the interrelations between the thicknesses of individual meridians?

Is it possible to identify a keratoconus with an OCT device?

In no measured and observed eyes could keratoconus be identified by means of an OCT profile image. The presentation of apex by means of Oculus keratograph could not be confirmed in any of the cases. However, in all the keratoconus corneas a significantly thinner point outside the geometrical centre could be found. Whether this thinner point corresponds to the topography presented by the videokeratograph should be determined in further studies.

What is important for providing an answer regarding the possibility of identifying a keratoconus with OCT is the quality of presentation of all the visible details. Using the school grading system (1 = very good, ... 5 = insufficient) a subjective evaluation of the visibility was carried out and documented.

In the evaluation of 156 eyes with inserted keratoconus or keratoplasty – contact lenses the mean value of 2.2 ± 0.5 was reached in central visibility of the contact areas, whereas peripherally in the centre only 3.3 ± 0.9 could be obtained. The best values in the centre were a 1.0 and the worst a 4.0. The best values in the periphery were 1.8 and the worst results were 5.0 – which means very bad to not identifiable any more. This means that it is by an entire degree more difficult to identify the peripheral areas of the profile section than the central areas.

There may be three reasons why the sphere of the keratoconus itself could not be observed:

1. OCT – sections do not correspond to the keratoconus apex;
2. Pixel size;
3. Vertex depth (µm) – radius (mm).

OCT-section and apex position

The OCT-section almost never corresponds with the apex. The Visante OCT measures in the corneal Quad-modul Measurement in 180°, 90°, 45°, 135°. As can be concluded from the following presentation, no OCT measurement sections correspond to the apex itself. The OCT sections are more or less tangent to the apical zone. It may be assumed that it is precisely in the apex where the thinnest point of the cornea is found. In horizontal section in 180° the OCT-section runs further away from the apex than in 90° meridian. Since according to videokeratometry the apex in almost all the cases can be found in the bottom quadrants, the smaller corneal thicknesses can also be found on the thinnest point in 90° meridian.

A help would be OCT-scanning in all the 360 meridians. Then the apex should be determined and the thinnest point found. Whether in this meridian with OCT really the spherical form of the keratoconus can be seen and measured, this is the topic of another study.

In Figure 7 you see the simulation of OCT measurements in 180° and in 90° meridian superimposed over the corneal topography. Dotted line shows thus the meridian measurements in 45° and 135°. Below the profile image in horizontal and to the right the image in vertical meridian.

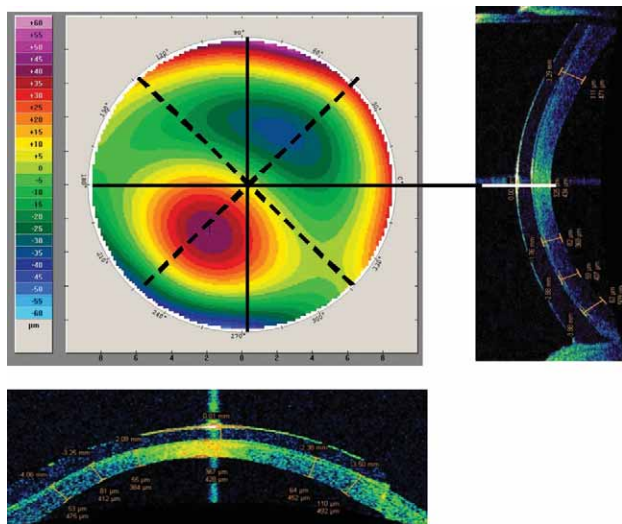


Fig. 7. Simulation of OCT measurements in 180° and in 90° meridian superimposed over the corneal topography. Dotted line shows thus the meridian measurements in 45°.

Pixel size

The precision of measurement and the precision of presentation depend on the applied OCT sensor and on the presentation of pixels. The Visante™ OCT has a sensor resolution of 15–20 μm. The pixel size and the line thickness on the screen are also ca. 20 μm. The measured values are expressed in μm; should an apex protrude 20 to 40 μm, this would correspond to only one or two pixel sizes and would be therefore very difficult to identify. In case of measurement precision of ± 20 μm, which means only one pixel size, then the assumed 40 μm high protrusion could be hardly seen any more.

What are the interrelations between the thicknesses of individual meridians?

The study confirms that the average corneal thickness in case of the measured 123 eyes with keratoconus amounts to an average $467 \pm 73 \mu\text{m}$. HAQUE¹⁹ has shown a mean value of $447 \pm 68 \mu\text{m}$ (n=20). This is significantly thinner than a healthy normal cornea. According to corneal topography the corneal apex can be found usually nasal, but primarily below the geometric mean of the cornea.

At this point, in the OCT profile image, a sphere-like protrusion would be expected. It could not be found, but at that point there was the thinnest point with an average of $425 \mu\text{m}$ with a standard deviation of $83 \mu\text{m}$. This means that the thinnest point by another 90% thinner is than the geometrical centre of the cornea. All the compared results have been highly significant ($p < 0.001$). The measured minimal value of $138 \mu\text{m}$ and the maximal value of $638 \mu\text{m}$ were the unexpected extreme values. The periphery of the corneas with keratoconus is significantly thicker ($p < 0.001$).

Also, HAQUE¹⁹ showed that a healthy cornea is the thickest in the superior area and the thinnest inferior. Thus it was confirmed that it is not only in case of keratoconus that the cornea is thinner downwards, but that this can also be measured in healthy eyes. Obviously, not to the same extent. This study has further determined that the thinnest point of keratoconus is rarely in the geometrical centre. The thinnest point was also in 90° meridian thinner than in 180° meridian.

The 90° meridian is thinner than the 180° meridian

In keratoconus the mean values were central in 180° meridian $471 \mu\text{m}$ ($\pm 76 \mu\text{m}$) (KK n=123) and peripheral $567 \mu\text{m}$ ($\pm 70 \mu\text{m}$). In 90° meridian the mean values were $467 \mu\text{m}$ ($\pm 73 \mu\text{m}$) and peripheral $551 \mu\text{m}$ ($\pm 99 \mu\text{m}$). The central difference between 180° and 90° measurements amounted to $4 \mu\text{m}$ in keratoconus cases and $16 \mu\text{m}$ peripheral.

The 39 keratoplasty cases showed quite similar results. Here, in 90° meridian, in the centre a little bit thicker values ($-5 \mu\text{m}$) and in the periphery somewhat smaller thicknesses ($13 \mu\text{m}$) could be measured. In keratoplasty cases the mean values were central in 180° meridian (KP n=39) $560 \mu\text{m}$ ($\pm 51 \mu\text{m}$) and peripheral $588 \mu\text{m}$ ($\pm 96 \mu\text{m}$). In 90° meridian the mean values were $555 \mu\text{m}$ ($\pm 65 \mu\text{m}$) and peripheral $575 \mu\text{m}$ ($\pm 97 \mu\text{m}$). The central difference between 180° and 90° measurement in keratoplasty cases amounted to $-5 \mu\text{m}$ and peripheral $+13 \mu\text{m}$. What is surprising is that the difference of $-5 \mu\text{m}$ in keratoplasty and $4 \mu\text{m}$ in keratoconus is very similar.

The standard deviation in keratoconus was in $180^\circ \pm 77 \mu\text{m}$ and in $90^\circ \pm 73 \mu\text{m}$, the difference $4 \mu\text{m} \pm 43 \mu\text{m}$, in cases of keratoplasty it amounted in 180° to $\pm 65 \mu\text{m}$ and in 90° $\pm 51 \mu\text{m}$ the difference amounted to $-5 \mu\text{m} \pm 13 \mu\text{m}$. It is surprising that in case of keratoplasty a smaller standard deviation could be calculated.

In keratoplasty cases this result can be interpreted by the fact that the thinner meridian, that lies by nature in 90°, during surgery lies somewhere only by accident. The thinner periphery in 90° is the peripheral meridian of the host cornea that has remained in the eye.

Conclusion

For the practice, these results could represent a constructive indication that the postoperative astigmatism could be lower if in case of corneal transplantation attention was paid to adjust the 90° meridian of the donor with the 90° meridian of the recipient. The smaller the differences in thickness between keratoplasty and the host cornea, the smaller the tension and compression forces and consequently better postoperative results. A lower level of astigmatism and a smaller aberration coefficient could be expected.

A further study could result in finding an even thinner meridian, if the meridian through the apex and thus

the assumed thinnest point were found. If one could take into account the axis of the thinnest meridian during surgery, even smaller irregularities might be expected.

Can OCT device be used to identify and measure the differences in corneal thicknesses between keratoplasty and keratoconus-host cornea?

In 39 measured eyes after corneal transplantation the mean thicknesses with average $555 \mu\text{m} \pm 65 \mu\text{m}$ were measured. Here also a thinner point outside the apical zone was found. The cornea was even thinner outside the keratoplasty. Almost all comparative results were highly significant ($p < 0.001$). The minimal value was $252 \mu\text{m}$ and it lied outside the keratoplasty in the host cornea.

Naturally, each of these measurements was only a snapshot. The changes in the corneal thickness during the day¹⁷ or after different activities¹⁷ were not specially considered or measured in this study, since these deviations are only marginal.

See Figure 8 – Left: Keratoconus with the thinnest point in the vicinity of the geometrical centre; Right: Keratoplasty with the thinnest point outside the transplant.

Is it possible to produce a classical fluorescein picture with the profile presentation of the cornea and the contact lens?

The measurement of the precorneal tear film thickness between the contact lens and the epithelium yielded 20 to 30 times higher values than measured in the literature^{9,10} in measuring the tear film under the soft lenses.

The average thickness of the tear film in case of 114 eyes with keratoconus with fitted contact lens is in 180° meridian $90 \pm 41 \mu\text{m}$. In 90° meridian of the same group the mean value of $113 \pm 56 \mu\text{m}$ can be found. The result is statistically highly significant ($p < 0.01$). The minimal measured value was $15 \mu\text{m}$, the maximal value was of a depth of $298 \mu\text{m}$.

The same picture, but with even higher values, showed the measurements of 29 eyes after keratoplasty with fitted contact lenses in 180° meridian – with $113 \pm 64 \mu\text{m}$, whereas in 90° meridian of the same group a mean value of $152 \pm 86 \mu\text{m}$ was found. The result is statistically highly significant ($p < 0.01$). It could be thus shown in both groups that the tear film must be thicker in 90° meridian, so as to guarantee the dynamic movement of the contact lens.

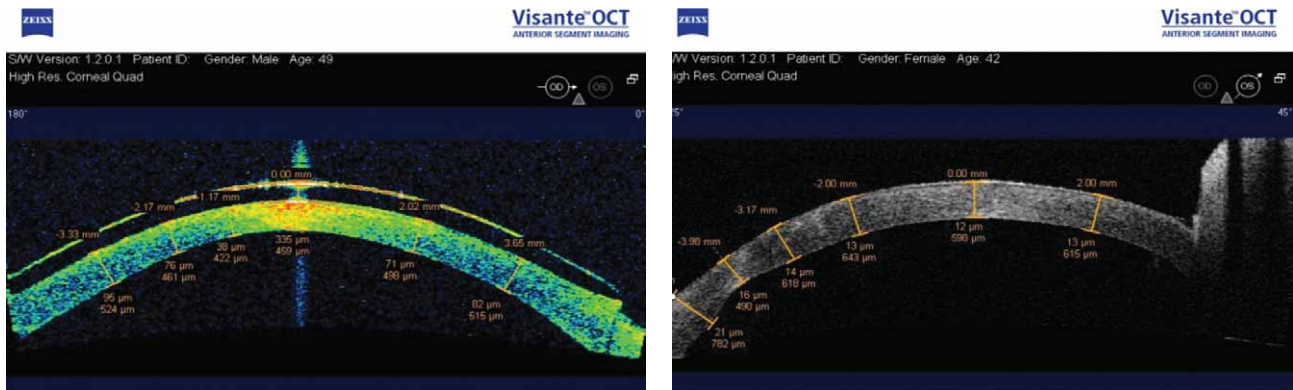


Fig. 8. Left: Keratoconus with the thinnest point in the vicinity of the geometrical centre; Right: Keratoplasty with the thinnest point outside the transplant.

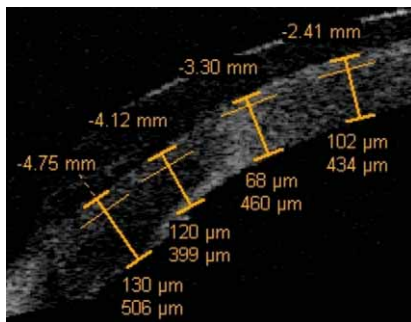


Fig. 9. On the left one can see the thickness measurements of the cornea and tear film with the Flap-module. The endothelium and the chamber water build the same as the contact lens and tear film a clearly seen contrast border. However, the border between the epithelium and the tear film is difficult to see.

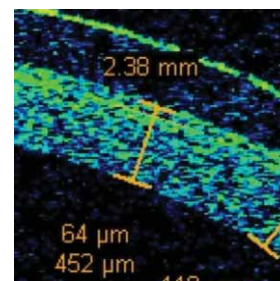


Fig. 10. The highly magnified picture shows the section of a keratoconus cornea. The One pixel corresponds to ca. individual pixels can be well seen. $20 \mu\text{m}$. The starting point of the measuring path already before or on the contrast border produces an imprecision of a minimum of $\pm 20 \mu\text{m}$.

The Zeiss Visante™ OCT is not a device that fulfils the requirement to present the fluorescein pictures. In this case the classical evaluation of the fluorescein picture and the calculation of the fluorescein picture have much better potential of expression using e.g. the Hecht-Expertprogram. What is interesting, however, is the measurement of the tear film thickness with the flap-module of OCT Visante.

Possible sources of error in implementation

In measuring with Zeiss Visante™ OCT it was already after a short time found that the measurement with flap-module is not possible quite precisely in all the areas.

On the one side there is the general visibility that was already mentioned in Item 6.1. The general visibility of the OCT picture was evaluated according to a school grading system. Centrally the mean value was 2.2 and peripherally 3.3. This means that the measuring precision decreases in measurements performed on the edge, whereas the contrast limits there were often worse than in the centre.

On the other hand, there was a problem in case of the measurement with the flap-module in finding the exact starting point for the measurements. The thickness of the tear film can be measured exactly only when previously an exact contrast margin is found, from which the measurement can be performed. The border area between contact lens and the tear film was almost always easy to see, as well as the limit between the endothelium and the chamber water. However, the contrast border between the tear film and the cornea was only very difficult to see.

In Figure 9 on the left one side you can see the thickness measurements of the cornea and tear film with the Flap-module. The endothelium and the chamber water build the same as the contact lens and tear film a clearly seen contrast border. However, the border between the epithelium and the tear film is difficult to see. The highly magnified picture in Figure 10 shows the section of a keratoconus cornea. The One pixel corresponds to ca. individual pixels can be well seen. 20 µm. The starting point of the measuring path already before or on the contrast border produces an imprecision of a minimum of ± 20 µm.

Clinical relevance of the study

The Visante™ OCT of Zeiss Meditec is at the moment one of the most precise measuring devices for determining the thickness of cornea, flap, tear film and the contact lens.

On the basis of the measured thickness differences within the corneal meridians, it is possible to clearly distinguish a normal cornea from a keratoconus, keratoglobule, and a pellucid marginal degeneration (PMD).

Subsequently it is necessary to evaluate as a relevant result the thickness difference of the keratoconus cornea in 180° and in 90° meridians. Since the cornea is always thinner in 90° meridian, it may be concluded that the postoperative astigmatism after keratoplasty would be smaller if during the transplantation attention was paid to match the 90° meridian of the donor with the 90° meridian of the recipient. The same should hold for the individual quadrants. It can be assumed that the smaller the thickness difference and the resulting tensile strength the smaller the postoperative astigmatism. The same should hold also for the level of irregularity of astigmatism.

Also, all the measurements were carried out in alert condition and with the available contact lens materials. The thickness changes¹⁸ based on the different oxygen transmissions through different contact lens materials, with open and closed eyes, were not possible on the basis of the large number of the measured eyes and the quantity of the necessary contact lenses with different materials.

The possibility of identifying a keratoconus with OCT has yielded different results than expected. The spherical form of the cornea could not be seen. However, in each keratoconus cornea a thinner point outside the geometrical centre could be detected. The minimal value was 138 µm that was found on the thinnest point. This corresponds to ca. one quarter of the average corneal thickness of all the measured keratoconus eyes (467 µm / ± 73 µm / n=123).

It could be observed that the thinner the cornea, the higher the astigmatism, the irregularity, and the worse the Visus cc. A statistical evaluation should be presented in a further study.

REFERENCES

1. SUNDMACHER R, Klinische Aspekte des Keratokonus (1. Freiburger Kontaktlinsenforum, 1984). — 2. MILLER K, Vortragsunterlagen, Astigmatismusprophylaxe und postoperatives Management bei Keratoplastik (2002). — 3. BERKE A, MÜNSCHKE P, Screening-Prüfmethoden der Optometrie (DOZ Verlag, 1996). — 4. PÖLTNER G, Spaltlampentechnik, Sonderdruck »die Kontaktlinse« (Konradin Verlag, 1996). — 5. PÖLTNER G, Kontaktlinsen-Anpassung bei Keratokonus, Sonderdruck »die Kontaktlinse« (Konradin Verlag, 2002). — 6. MÜLLER-TREIBER A, »Kontaktlinsen know how« (DOZ Verlag, 2009). — 7. EBEL J, BARON H, Kontaktlinsen (DOZ Verlag, 2009). — 8. WIDMER F, Vortrag »Mein Vorsprung« (Bezau, 2008). — 9. WANG J, FON D, SIMSON TL, JONES L, Investigative Ophthalmology & Visual Science, 44 (2003). — 10. WANG J, Investigative Ophthalmology & Visual Science, 47(10) (2006). — 11.

12. STRAUB W, KROLL P, Optische Kohärenztomographie. In: LANG GE (Eds.) Augenärztliche Untersuchungsmethoden. (3. Aufl, Georg Thieme Verlag, Stuttgart, 2008). — 13. KAMPIK A, GREHN F, Optische Kohärenz – Tomographie am Vorderabschnitt des Auges. In: HOERAUF H (Eds.) Augenärztliche Diagnostik. (1. Aufl, Georg Thieme Verlag, Stuttgart 2003). — 14. STRAUB W, KROLL P, Spezielle Untersuchungen der Hornhaut. In: SEKUNDO W (Eds.) Augenärztliche Untersuchungsmethoden. (3. Aufl. Georg Thieme Verlag, Stuttgart 2008). — 15. CARL ZEISS Meditec AG. <info@meditec.zeiss.de> ZEISS Meditec: Visante™ OCT Anterior Segment Imaging & Biometry. Der vordere Augenabschnitt im neuen Licht. URL: [http://www.zeiss.de/88256DE40004A9B4/0/B96CAB8E984943AD88257227000085C4/\\$file/visanteoct_dt.pdf](http://www.zeiss.de/88256DE40004A9B4/0/B96CAB8E984943AD88257227000085C4/$file/visanteoct_dt.pdf), Accessed 08.10.2008.

— 16. CARL ZEISS Meditec AG. Gebrauchsanweisung für Visante OCT (2006). — 17. READ SA, COLLINS MJ, Optometry and Vision Science, 86 (2009). — 18. WANG J, FON D, SIMSON TL, Invest Ophthalmol Vision Sci, 44 (2003) 1070. — 19. HAQUE S, JONES L, SIMPSON T, Optometry and Vision Science, 85 (2003). — 20. MILLER K, Kollagenvernetzung mit Riboflavin und UVA-Bestrahlung zur Behandlung des

Keratokonius (Crosslinking), Aufklärungsschrift für Patienten. — 21. LINDSTROM R, LAVERY W, Correction of Postkeratoplasty Astigmatism, Corneal Surgery (1986). — 22. MAYER D, Tissue Typing, Corneal Surgery (1986). — 23. KEECH A, SIMPSON T, FLANAGAN J, JONES L, Optometry and Vision Science, 86 (2009).

G. Pöltner

Contactlinseninstitut Miller, Meranerstr. 3, 6020 Innsbruck, Austria
e-mail: gpoeltner@gmail.com

MJERENJE DEBLJINE ROŽNICE POMOĆU OPTIČKE KOHERENTNE TOMOGRAFIJE (OCT) U PACIJENATA S KERATOKONUSOM I NAKON KERATOPLASTIKE KOJI NOSE KONTAKTNE LEĆE

SAŽETAK

Svrha ovog rada bila je mjerenje debljine rožnice i dubine prekornealnog suznog filma kod pacijenata s keratokonusom i keratoplastikom koji nose kontaktne leće. Mjerenje se provodilo s optičkim koherentnim tomografom (OCT) na 123 oka s keratokonusom, 39 oka nakon keratoplastike te 8 oka nakon LASIK. Prosječna dob svih pacijenata bila je 42,7 godina (35% žena i 65% muškaraca). Debljina središnje rožnice u 123 očiju s keratokonusom iznosila je $467 \pm 73 \mu\text{m}$. Nazalna, a posebice donja periferija rožnice pokazuje 9% manju debljinu ($426 \pm 83 \mu\text{m}$). Rožnica s keratokonusom je tanja u 90° meridijanu u odnosu na 180° meridijan. To je klinički relevantan rezultat za redukciju astigmatizma nakon keratoplastike. Debljina središnje rožnice u 39 očiju sa keratoplastikom iznosila je $555 \pm 65 \mu\text{m}$. Debljina prekornealnog suznog filma u 114 osoba s kontaktnim lećama i keratokonusom iznosila je $89 \pm 42 \mu\text{m}$ u horizontalnom, te $113 \pm 56 \mu\text{m}$ u vertikalnom meridijanu. Svi rezultati pokazuju statističku značajnost.