

Section for Interventional Radiology – sIRcro 10 Years of Existence and Organised Activities (2000–2010)

Slavko Šimunić¹, Krešimir Glavina¹, Josip Mašković² and Vinko Vidjak³

¹ »J. J. Strossmayer« University, School of Medicine, Clinical Institute of Diagnostic and Interventional Radiology and the University Hospital Center Osijek, Osijek, Croatia

² University of Split, School of Medicine, Clinical Institute of Diagnostic and Interventional Radiology and the University Hospital Center, Split, Croatia

³ University of Zagreb, School of Medicine, Clinical Institute of Diagnostic and Interventional Radiology and University Hospital »Merkur«, Zagreb, Croatia

ABSTRACT

Shortly after the Roentgen's discovery (1895), X-rays were applied for depicting vascular system (Lindenthal and Haschek 1896). But it took rather long time before another brilliant idea (Seldinger 1953) for percutaneous puncture and catheterization of superficial artery was developed instead of these previously performed and the surgical arteriotomy. The percutaneous puncture enabled another idea to emerge, i.e. percutaneous transluminal angioplasty – PTA (Dotter/Judkins 1964). Thus it was proved that catheter could be used not only in diagnostics but also in therapy, and the method was applied to other organs and organic systems. The application of interventional radiology in Croatia started in late 1970s and early 1980s. The number and type of procedures increased rapidly in the four largest hospitals and educational centres (Zagreb, Split, Rijeka, Osijek), so that the need was felt to establish a Section for Interventional Radiology of the Croatian Society of Radiology (2000).

Key words: radiology, Croatian Society of Radiology, interventional radiology, Section for Interventional Radiology, 10 years anniversary

Introduction

The Section for Interventional Radiology was founded in 2000, being one of the five Sections of the Croatian Society of Radiology (CSR), founded in 1928 (at the time under the name of the Society of Roentgenology).

CSR is a member of the European Society of Radiology (ESR), elected in Vienna (1993), and a member of the International Society of Radiology (ISR), elected in Singapore (1994). CSR is one of more than 120 professional societies, sections and clubs of the Croatian Medical Association (CMA) – a member of the World Medical Association (WMA) since 1992, the European Forum of Medical Associations (EFMA), and the European Union of Medical Specialists (UEMS).

Interventional Radiology – IR

The advent and development of interventional radiology, first vascular and later other organs and organ systems, came long after the discovery of Roentgen's X-Rays (1895), and after the development and improvement of

Prof. Jan Peregrin, CIRSE President, wrote in the IR News (3/2010), issued at the time of the Annual Meeting and Postgraduate Course of the Cardiovascular and Interventional Radiological Society of Europe – CIRSE 2010, held in Valencia, Spain, 2–6 October 2010, under the motto Innovation-Education-Intervention:

»BENVENUTI – DOBRO DOŠLI – WELCOME to our group members – ITALY–CROATIA–AUSTRALIA – to the CIRSE family«

At the same time, CIRSE celebrated the 25th anniversary under the motto: »Inspiring Growth and Great Community Spirit«, with 5603 participants who attended the largest Annual Congress¹.

radiological equipments, contrast agents and required various radiological devices (needles, introducers, guides, catheters, embolizing materials, coils, stents etc). It was common belief, until 17th century, that the air flows through the arteries, when an English physician William Harvey (1616) proved it was blood that flows through the arteries.

Haschek and Lindenthal (1896) took interest in blood vessels in humans, performing arteriography on an amputated hand with Teichman's mixture; Berberich and Hirsch (1923) showed arteries and veins of a living human with strontium bromide; Brooks (1924) showed lower extremities arteries of a living human with sodium iodide; Moniz (1927) developed cerebral angiography; Dos Santos (1929) introduced translumbar aortography; Castellanos, Pereiras and Garcia (1937) performed angiocardiology of the right heart; Robb and Steiner (1937) angiocardiology of the left heart and aorta; Farinas (1941) abdominal aortography; Radner (1945) thoracic aortography; Bierman (1951) coeliacography. While in Croatia, Lopašić (1933) performed cerebral angiography; Smokvina (1939) subdural haematoma; Gvozdanović (1950) cerebral angiography; Gvozdanović et al. (1951) angiocardiology; Gvozdanović et al. (1953) percutaneous splenic venography; Gvozdanović and Čečuk (1955) aortography; Gvozdanović and Vidović (1958) phlebography of the lower extremities; Gvozdanović, Novak, Vidović (1962) aortography using the transaxillary approach^{2,3}.

Until the Seldinger's method of percutaneous puncture and catheterization of the superficial arteries (1953) was developed, these and other arteriographies had to be performed after the surgical presentation of the artery and the arteriotomy⁴.

Interventional radiology, as a part of radiology, has rapidly expanded over the last two decades and it is important to be aware of it. Today it plays a crucial role in the treatment of many diseases.

When talking about interventional radiology, and about many deserving people in the field, one should primarily think of the pioneers among them:

Sven Ivar Seldinger (1921–1998) – Karolinska sjukhuset, Stockholm, »with three objects in his hands: a needle, a wire, a catheter – *he realised: needle in – wire in – needle off – catheter on wire – catheter in – catheter advance – wire off*«. This was a simple and ingenious way to simplify the performance of angiography, and therefore the performance of radiological interventional procedures in vascular organs, as well as in other organs and organic systems later on.

Charles Theodor Dotter (1920–1985) – the University of Oregon, Portland, USA; a vascular radiologist; »the father of interventional radiology«, responsible for the advent and development of the PTA (1964). Dotter was also involved in the liver biopsy by transjugular venous approach and transhepatic cholangiography; worked with P. Melvin Judkins; his angioplasty was accepted in Europe by Zeitler E. (Nuremberg); and he introduced it to A. Grüntzig (Zürich)⁵.

P. Melvin Judkins (1922–1985) – the University of Oregon, Portland, USA; »a legend in invasive/interventional cardiology«; a cofounder of the Society for Cardiovascular Angiography and Interventions (SCAI); collaborated with Dotter; introduced a catheter through the brachial artery for selective coronary arteriography; also had ideas about developing a device (a stent) for intracoronary installation that would preserve the performed coronary arteries dilatation.

Cesare Gianturco (1905–1995) – a radiologist; the Cancer Center, MD Anderson Hospital and Tumour Institute, the University of Texas, Houston, USA; researched balloon angioplasty technology, coiled springs, »wooly tails«, a vena cava filter, biliary and vascular stents, embolizing materials, and invented many interventional devices.

Roland Andreas Grüntzig (1939–1985) – a cardiologist; the Emory University Hospital, in Atlanta, Georgia, USA; »a medical legend«; »an extraordinary cardiologist«, »the founding father of percutaneous transluminal coronary angioplasty (PTCA)«; »a pioneer in the history of interventional cardiology«; emigrated from the German Democratic Republic to Heidelberg (the Federal Republic of Germany), and moved (in 1969) to the University Hospital Zürich; accepted an invitation from the Emory University Hospital in Atlanta, Georgia, USA (1980). Building upon the work Dotter and Judkins, Grüntzig developed a new technique for revascularization, thus establishing a new specialty – the interventional cardiology. He also created a double-lumen balloon catheter for coronary angioplasty, and carried out the first PTCA in Zürich (1977).

In the beginning of interventional radiology, there were given significant pioneering contributions and later further development and training by other radiologists, too, eg.: **Alexander R. Margulis**, USA – »coined« the term *interventional radiology* (1967); **Eberhard Zeitler**, Germany – nicknamed the »St. Paul of angioplasty«; **Anders Lunderquist**, Sweden – the Lunderquist wire, portal hypertension; **Friedrich Olbert**, Austria – the Olbert catheter and other devices; as well as many other radiologists.

»Medical dilatation is not new. References to crude instruments date back to the Egyptians and Romans who used reeds for dilating the urethra. Numerous mechanical devices for dilatation of the cervix, oesophagus, urologic tracts and blood vessels have existed for centuries.«⁶

At the time there were no CT angiography, MR angiography and US angiography. »In the early days, our work was quite different from what we do today. We were diagnostic angiographers and our goal was to define pathologic lesions so that referring physicians could select the proper therapy. Dotter changed this mindset. He stated that the diagnostic catheter can become a therapeutic tool and replace the surgical scalpel. However it took quite a while for us to change our diagnostic thinking and to develop interventional techniques and devices.«⁷

»Interest in the PTA in the USA began after Grüntzig created balloon dilatation catheter (1977). The cath-

eter was initially used for treatment of certain concentric proximal coronary lesions. Its usage quickly spread to the treatment of complex stenosis including occlusion, and was less invasive method for coronary arteries remodelling. The technique and the necessary accessories were continuously improved and began to be applied in other arteries, and later for non-vascular therapeutic interventions.«^{8–10}

»The cardiac catheterization laboratory is one of the most fascinating areas of medicine to work in. In these small procedure rooms, a team of physicians, nurses, and cardiovascular invasive specialists perform diagnostic examinations and therapeutic procedures on patients' hearts with tubes and wires.«¹¹

»Percutaneous transluminal angioplasty is one of the fastest growing and most exciting developments in interventional radiology.«⁶

The importance and practical benefits of interventional medicine can be seen in its application in other fields, such as in the veterinary medicine: »...an idea is a good one when it spreads even further than it was originally intended to, and that's exactly what is happening with IR. The results that IRs are obtaining in their patients has caused another profession to follow suit, leading to a whole new field – minimally invasive veterinary medicine.«⁽¹²⁾ »Most diagnostic radiological procedures are non-invasive and do not require anaesthetic interventions. However interventional procedures in general always need some help from anaesthesiologists for safety and comfort of patients and interventional radiologists. Anaesthesiology is well-recognized medical speciality whose interest is a continuum of patient care involving pre-operative evaluation, intra-operative and post-operative care and the management of systems and personnel that support these activities. In fact anaesthesiology includes different areas of expertise, like anaesthesia, intensive care, emergency medicine and pain treatment...«¹³

»Symposium on Percutaneous Transluminal Angioplasty / Therapeutic Angiography (Boston 1980) sparked a great interest in this, at the time, controversial topic, and which became reality. It has appeared 'balloon fever' (as earlier 'gold fever') not only among radiologists, but also among others specialities, particularly cardiologists and vascular surgeons.«¹⁴

»Access in high income countries to interventional radiology and other modern medical care is continually improving. But how can we ensure that others outside our own comfort zone feel the benefits that innovative medical science has to offer?«¹⁵

»Interventional radiologists are not only technical experts, they are also clinical practitioners. This section emphasises the importance of having dedicated staff and resources allocated to IRs in order to maintain good clinical practice.«⁶

All these and many other similar opinions confirm that intervention procedures give to radiology a new dimension and importance, as this traditionally diagnostic profession / science has become even more therapeutic, and therefore accepting that along with clinical professions, also radiologists actively participate and are re-

sponsible for success, complications and failures made by interventional therapeutic procedures.

Cardiovascular and Interventional Radiological Society of Europe – CIRSE

Henry Ford (1826–1947), American industrialist; Founder of Ford Motor Company:

»Coming together is a beginning, staying together is a progress, and working together is success.«¹³

CIRSE is today one of the ten subspecialty societies of the European Society of Radiology (ESR). In recent history of the interventional radiology in Europe, there were two societies: the European College of Angiography (ECA) and the European Society of Cardiovascular and Interventional Radiology (ESCVIR) – both founded in 1976. Between 1982 and 1984, the two societies organized joint annual meetings. The American Society of Cardiovascular and Interventional Radiology (SCVIR) was also invited to such joint meetings. It is to be noted that the greatest honour for I. Obrez and his collaborators (Ljubljana) in the former Yugoslavia was to have the privilege to organise and host a joint meeting of the ECA and ESCVIR (Dubrovnik, 1984), which was assessed a great success.

»Several leading European angiographers and interventional radiologists (F. Pinet, Paris; I. Obrez, Ljubljana; R. Passariello, Rome; P. Rossi, Rome; G. F. Feltrin, Padua; R. Günther, Aachen; E. Zeitler, Nuremberg; F. Olbert, Vienna) discussed the idea of merging the two societies (1981). Thus, at the joint meeting of the General Assembly of the ECA and ESCVIR, on 24 April 1985 in Vienna, the two societies merged, and the **Cardiovascular and Interventional Radiological Society of Europe (CIRSE)** was established. The first president of the CIRSE was elected F. Olbert (Vienna). The CIRSE Congress and Joint Meeting with the American SCVIR was held in Jerusalem (1986), under the presidency of Alex Rosenberger. Further annual meetings followed in various cities of Europe.«¹⁶

The last meeting was held in Valencia, Spain (2010). On that occasion, CIRSE celebrated the 25th Anniversary, with 5603 participants and 94 exhibitors who attended the biggest Annual Congress to date.

CIRSE and the publisher Springer signed a contract (1991) for publishing the official journal – the Cardiovascular and Interventional Radiology (CVIR).

The Foundation for Interventional Radiology in Europe was established (2000) as an »independent non-profit and tax-exempt body which is able to sponsor research, education, etc.«¹⁵

»In the 2008 annual meeting of the CIRSE, a group of IR experts, led by then society Presidents J. Reekers (CIRSE) and J. Kaufman (Society of Interventional Radiology – SIR, US), set out to create a form of mission statement for IR. The result was the 'Global Statement Defining Interventional Radiology' which was published in the August 2010 issues of the journal Cardiovascular and Interventional Radiology (CVIR), and the Journal of Vas-




Fig. 1. The Coat of Arms of the Croatian Society of Radiology.



Fig. 2. The Coat of Arms of the Section for Interventional Radiology.

cular and Interventional Radiology (JVIR). Endorsed by 42 societies in 39 countries around the world (also by the Croatian Society of Radiology), the Statement not only provides a concise definition of the discipline, it also stands as proof of IR's international importance. Interventional radiologists are not only technical experts, they are also clinical practitioners.«¹⁷

Section for Interventional Radiology of Croatia – sIRcro

The IR procedures started to be performed in Croatia in collaboration with the Institute of Radiology, the University Medical Center Ljubljana, Slovenia (I. Obrez et al.). Moreover, an informal Angiological Club (1979) was founded, which brought together interested radiologists from the former Yugoslavia. The Club was attended regularly on week-ends by members from Croatia: S. Šimunić, R. Gürtl, M. Klenkar (Zagreb); J. Mašković (Split); I. Lovasić (Rijeka), and occasionally by some other colleagues (Figure 1 and 2).

Long before the establishment of the Section for Interventional Radiology (2000) in Croatia, there were organized »Scientific Meetings of Croatian Radiologists« (Split, 1981; Osijek, 1982; Pula, 1985; Karlovac, 1986; Opatija, 1987; Sl. Požega, 1989; Zadar, 1990; Varaždin, 1992), with the IR topics regularly included in the agenda (Figure 3 and 4).

After Croatia has achieved independence in 1991, these meetings were raised to the level of a national congress (Opatija, 1994; Osijek, 1998; Split, 2002; Zagreb, 2006; Opatija, 2010), having also IR topics covered.

Wishing to spread these procedures in radiology as much as possible, and get even more radiologists interested in them, various events on IR were organized: Zagreb, 1980 (org. S. Šimunić): Round Table on IR; Zagreb, 1981 (org. S. Šimunić): Symposium on IR; Zagreb, 1983 (org. S. Šimunić, M. Šesto): Symposium on PTA, with E. Zeitler, Nuremberg, Germany, as a guest speaker; Zagreb, 1985 (org. S. Šimunić, I. Obrez): Symposium on Percutaneous Drainage, with Gy Vargha, Debrecen, Hungary; L. Horváth, Pécs, Hungary; and I. Vujić, Charleston, USA, as guest speakers; Split, 1986 (org. J. Mašković, S. Boschi, I. Stanić): Interventional Radiology, with Z. Barbarić, Los Angeles, USA; W.R. Castaneda-Zuniga, Minneapolis, USA; and L. Horváth, Pécs,

Hungary, as guest speakers; Ljubljana, 1989 (org. D. Pavčnik, M. Šurlan): IR in Oncology; Kopaonik, 1990 (org. T. Ivković, N. Govedarović, P. Bošnjaković): IR in Urogenital Tract.

The practical application of IR procedures in Croatia has begun in the late 1970s and early 1980s: I. Jakovac / M. Lovrenčić (Zagreb, 1979): Kidney embolization; Z. Kružić / S. Šimunić / R. Gürtl (Zagreb, 1980): Vena cava filter; S. Šimunić / R. Gürtl / I. Bradić (Zagreb, 1980): Wilms' tumor embolization; A. Hebrang (Zagreb, 1979): PTA of peripheral arteries; S. Šimunić / I. Obrez (Zagreb, 1980): PTA of renal arteries; S. Šimunić / R. Gürtl (Zagreb, 1981): Urinary bladder embolization; M. Šesto (Zagreb, 1980): PTA of coronary arteries; M. Šesto (Zag-

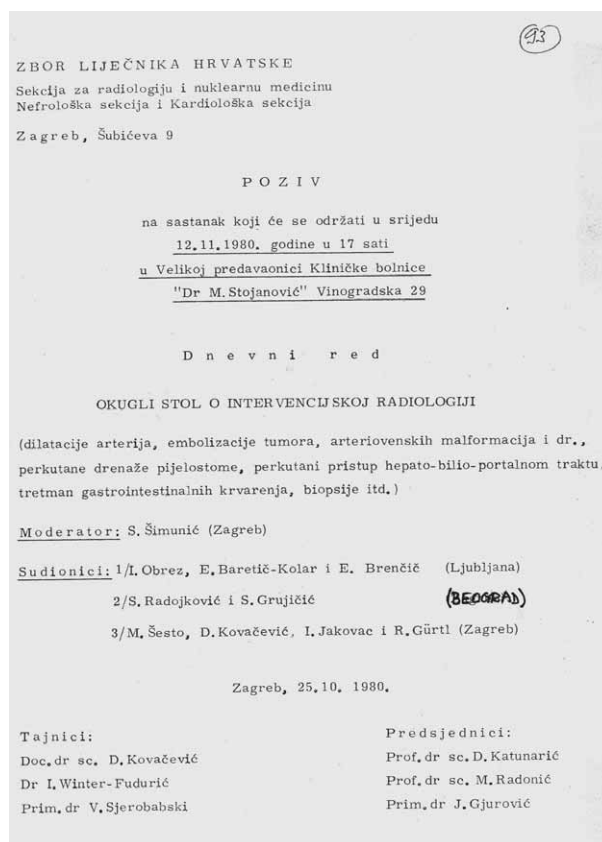


Fig. 3. Programme of the First Professional Meeting on Interventional Radiology (Zagreb, 12 November 1980).

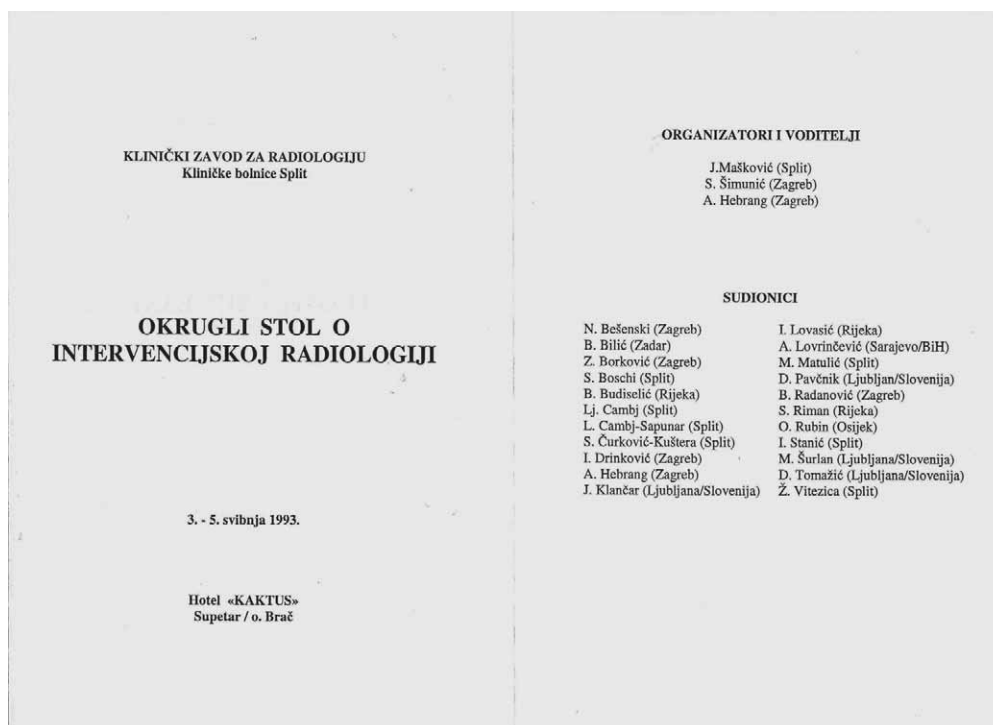


Fig. 4. Programme of the First Round Table on Interventional Radiology (Supetar, Island Brač, 3–5 May 1993).

reb, 1981): Selective intracoronary thrombolysis; I. Lovasić (Rijeka, 1981): Renal embolization; N. Bešenski (Zagreb, 1982): Lingual artery embolization in dental cyst; I. Drinković (Zagreb, 1982): Percutaneous pyelostoma with US; J. Mašković (Split, 1981/83): Renal embolization, Percutaneous evacuation of renal cyst, Renal drainage, PTA of peripheral arteries, Urinary bladder embolization, Biliary external/internal drainage, Peripheral local fibrinolysis, Embolization of meningiomas, Percutaneous abscess drainage, etc.; J. Mašković / I. Stanić (Split, 1983): Drainage of biliary ducts; S. Šimunić / K. Čavka / B. Radanović (Zagreb, 1984): Percutaneous non-surgical extraction of foreign body from the heart; V. Tkalec (Pula, 1985): Percutaneous nephrostoma; I. Stanić / Ž. Vitezica (Split, 1981-84): Percutaneous extraction of concrements from biliary system, Percutaneous puncture and sclerosing of renal cysts, Balloon dilatation of benign oesophagus stenosis, etc. As a result of everyday experience, the number and types of IR procedures performed in Croatia has been growing considerably.

Croatian radiologists attend national and international radiological events regularly. A professional peer and friendly cooperation has been developed in particular with the Slovenian Association of Radiology and the Hungarian Radiological Society. There are regularly held Croatian-Hungarian-Slovenian Symposia: Kőszeg (1999), Opatija (2000), Pécs (2001), Maribor (2002), Koprivnica (2003), Héviz (2004), Maribor (2005), Vukovar (2007), Kehidakustány (2009)¹⁷.

Moreover, there were held six Meetings of Croatian Interventional Radiologists with International Participations in Supetar, the Island of Brač, organised by J. Mašković (Split) and his associates: the First – Round

Table on IR (1993); the Second – Round Table on the Application of Stents in IR in Croatia (1999); the Third – IR in Croatia (2001); the Fourth – IR in Croatia (2003); the Fifth – IR in Croatia (2005); and the Sixth – IR in Croatia (2007). The Seventh Meeting was held in Zagreb, organized by the new president of the Section, Vidjak Vinko and his associates (2009), and the Eighth Meeting was held in Rab, the Island of Rab (2011).

These meetings, in addition to the radiologists from Croatia, were attended by the attendees from abroad: Austria – E. Klein, E. Günther; Belgium – L. Stockx; Czech Republic – M. Kocher, A. Krajina, J. Raupach; Bosnia and Herzegovina – V. Đurović, B. Gjikolli, Z. Merhamić, S. Vesnić, B. Hadžihasanović, D. Bulja, E. Hercegljija, A. Kordić; France – J. M. Idée; Germany – R. Langhoff, A. Schmidt; Hungary – L. Horvath, I. Battyany, B. Fornet, J. Hadijev, T. Rostas, I. Szikora, L. Engioner; Italy – H. Fusaro; Switzerland – P. Ransom, A. von Weimarn, C.I. Zollikofer; Slovenia – J. Matela, T. Ključevšek, M. Šurlan, P. Berden, D. Tomažić, J. Klančar, T. Šeruga, L. Salapura, T. Frangež, D. Kuhelj, D. Kulaš, M. Ruprecht, M. Vrtovec, I. Kocijančić, D. Šalinović, P. Popović, S. Breznik, Z. Milošević, M. Stanković; Turkey – Okan Akhan, Besim AYTEKIN; UK – R. Morgan; USA – I. Vujić, R. Uflacker.

The cooperation is also reflected in the reciprocal participation in the national radiological congresses of the Croatian, Slovenian, Bosnian-Herzegovinian and Hungarian radiological societies (Zagreb, Opatija, Tihany, Miskolc, Ptuj, Portorož, Sarajevo, Tuzla), with the IR presentations, among other topics, regularly included.

Radiologists – members of the Slovenian Association of Radiology, as guests gave occasionally interesting lec-

tures: M. Pocajt and J. Matela (Maribor), D. Pavčnik and M. Šurlan (Ljubljana).

The Section was founded by the Initiative Board, composed of Krešimir Glavina (Osijek), Andrija Hebrang (Zagreb), Josip Mašković (Split) and Slavko Šimunić (Zagreb/Osijek). The idea for the Section sprang up on a coffee break of the Multidisciplinary Endovascular Therapy (MET 2000) in Rome, 12–15 January 2000.

The Founding Assembly was held on 10 November 2000, in the Small Hall of the Croatian Medical Association in Zagreb. The Section was founded as one of the five affiliates of the Croatian Society of Radiology. The Management Board was elected: Josip Mašković, Split – the President, Liana Cambj-Sapunar, Split – the Secretary, Oto Rubin, Osijek – the Treasurer, and Berislav Budiselić, Rijeka, Krešimir Glavina, Osijek, Andrija Hebrang, Zagreb, and Slavko Šimunić, Zagreb/Osijek – the members^{18,19} (Figure 5)

In the period 2007–2009, instead of the current president J. Mašković, the acting president was V. Vidjak (Figure 6).

The new Management Board was elected for a 4-year period on the Election Meeting held in the HypoExpo Center premises in Zagreb, 7 June 2009, during the 7th Meeting of Croatian Interventional Radiologists – **sIRcro '09**, Zagreb, 4–7 June 2009, as follows: Vinko



Fig. 5. Professor Josip Mašković, MD, PhD, the first President (2000–2007).



Fig. 6. Assistant Professor Vinko Vidjak, MD, PhD, the current President (as of 2007).

Vidjak, Zagreb – the President, Karlo Novačić, Zagreb – the Secretary, Berislav Budiselić, Rijeka – a member, Liana Cambj-Sapunar, Split – a member, Josip Čurić, Zagreb – a member, Slavko Dobrota, Zagreb – a member, and Gordan Šarić, Osijek – a member.

REFERENCES

1. PEREGRIN J, IR news 3 (2010) 1. — 2. GVOZDANOVIĆ V, in Med. Encikl, I, Zagreb (1957) 357. — 3. ŠIMUNIĆ S, GÜRTL R, in LUETIĆ V, Angiologija, (Zagreb, 1979). — 4. SELDINGER SI, Acta Radiol, 39 (1953) 368. — 5. DOTTER CT, JUDKINS MP, Cir culation, 30 (1964) 654. — 6. ABEL JE, AJR, 135 (1980) 901. — 7. RÖSCH J, Intervention IQ, 3 (2010) 44. — 8. GRÜNTZIG AR, HOPFF H, Dtsch MedWochenschr 99 (1974) 2502. — 9. GRÜNTZIG A, RoeFo 124 (1976) 80. — 10. ZEITLER E, GRÜNTZIG A, SCHOOP W, (Springer, Berlin, 1978). — 11. WATSON S,

KENNET A, Invasive Cardiology (Jones & Bartlett, Sulbury, 2009). — 12. Intervention IQ 3 (2010) 40. — 13. PELOSI P, IRnews, 2 (2010) 21. — 14. ZOLLI-KOFER IC, IRnews, 2 (2010) 4. — 15. ATHANASOULIS CA, AJR, 135 (1980) 893. — 16. JOEKES E, Intervention IQ, 3 (2010) 36. — 17. Intervention IQ, 3 (2010) 36. — 18. ŠIMUNIĆ S, HORGY, LOVASIĆ I, Coll Antropol 2 (2003) 823. — 19. ŠIMUNIĆ S, GLAVINA K, BEŠENSKI N, KLARIĆ-ČUSTOVIĆ R, Radiol Oncol 45 (2011) 147.

S. Šimunić

Šubićeva 21, 10000 Zagreb, Croatia
e-mail: slavko.simunic@xnet.hr

ODJEL ZA INTERVENCIJSKU RADIOLOGIJU – sIRcro 10 GODINA POSTOJANJA I ORGANIZIRANIH AKTIVNOSTI (2000–2010)

SAŽETAK

Nije trebalo proći dugo vremena od Röntgenovog otkrića X-zraka (1895) pa do njihove praktične primjene prikaza vaskularnog sustava ljudskog tijela (Lindenthal i Haschek 1896). Ali, trebalo je dugo vremena dok se nije došlo do briljantne ideje perkutane punkcije i kateterizacije površne arterije umjesto dotadašnje kirurške arteriotomije. (Seldinger 1953). Ova mogućnost perkutane punkcije i kateterizacije dovela je do ideje (Dotter i Judkins 1964) da kateter ne mora služiti samo za dijagnostiku, nego i za terapiju pa je rođena perkutana transluminalna angioplastika (PTA) – a ubrzo i do spoznaje da je moguća i korisna ne samo na vaskularnom nego i na drugim organima i organskim sustavima ljudskog tijela. U Hrvatskoj su se metode intervencijske radiologije počele primjenjivati u kasnim 70-im i ranim 80-im godinama prošlog stoljeća. Broj i vrst ovih zahvata. naglo je porastao u velikim centrima i bolnicama edukacijskim ustanovama u Zagrebu, Splitu, Rijeci i Osijeku. Postignuti rezultati i sve veće potrebe doveli su do osnivanja Sekcije za radiologiju u sklopu Hrvatskog društva radiologa (2000) radi organiziranog i stručnijeg razvoja ovog segmenta radiologije koja je time dobila novu dimenziju, važnost i odgovornost.