

# Haemodynamic Changes in Patients with Whiplash Injury Measured by Transcranial Doppler Sonography (TCD)

V. Šerić, N. Blažić-Čop and V. Demarin

Department of Neurology, »Sestre Milosrdnice« University Hospital, Zagreb, Croatia

## ABSTRACT

*The daily increasing number of cervical whiplash injuries presents ever-greater requirement for vertebrobasilar diagnostics. A cervical spine injury, which is quite frequent injury, may occur during a fall, or industrial, traffic, sport or war injury. Transcranial Doppler (TCD) sonography with Transcan 3-D EME device and 2 MHz probe was used for the assessment of vertebrobasilar circulation in patients with a whiplash injury of the cervical spine, that occurred mostly in car accident. This study includes 47 patients with clinically verified cervical spine trauma with x-ray evidence of no bone lesion. The patients were examined by TCD within a month, and then six months following the accident. The obtained values were compared to normal blood flow velocities and correlated with the severity of clinical picture. During the first month after the injury, statistically significant disturbances in the vertebrobasilar circulation were recorded, such as the increase in mean blood flow velocities in AVL (68%), AVR (62%) and BA (51%) (mostly as spasms). Six months later, normal findings were obtained in about 50% of the vessels, whereas in rest of the patients vasospasm persisted in one, two or all examined blood vessels. TCD of the vertebrobasilar circulation was found to be a very useful method in the diagnostics and follow-up of patients with a whiplash injury.*

---

## Introduction

A cervical spine injury is a serious problem that results from a fall, or an industrial, traffic, sport or war injury. Spinal cord may suffer directly by penetrat-

ing wounds, for example by stabs or gunshot wounds or it may be penetrated by a shell or by fragments of a bone. In civil life, however, indirect spinal cord lesions due to injuries of the column, either by fractures, dislocations or fracture disloca-

tions are more common. Spinal cord may be injured as the result of a blow causing fracture at the site of impact, however, it is more frequently injured by a transmitted force. A whiplash injury is medical term introduced by Gay and Abbot in 1953<sup>1</sup>. The term has been adopted to describe hyperextension of the head and neck as the result of indirect force, most commonly inflicted in car accidents. For example a whiplash injury may occur when a vehicle standing still at red traffic lights is bumped in the back by another vehicle. The vehicle standing still is then suddenly thrown forward. The head of the driver and possible passengers in the car suffers a violent jerky backward movement with forward hyperextension of the neck induced by force of a much lesser effect. The final position of the head and neck is neutral<sup>2</sup>. By extension of the neck and retroflexion of the head, the neck muscles, ligaments and discs are stretched and injured. The oesophagus, larynx uncovertebral joints and masticatory ligaments are stretched which results in irritation of the cervical sympathetic system<sup>3</sup>. After the injury, the patients complain of the vertigo, unsteadiness while walking, nausea, vomiting, scintillations, pain in the neck, headaches and pain in the precordium<sup>4</sup>. The symptoms involving the central nervous system (CNS) are due to the backward movement of the brain<sup>4,5</sup>.

Common findings are brain contusions and commotions, with occult petechial haemorrhages in the frontal and temporal lobes. The movement of the cerebellum and brain stem produces a broad neurological event and even symptoms of brain oedema. The injured person can be unconscious for a short period of time, feeling discomfort, with pain and stiff neck<sup>6</sup>. Once acute symptoms are over, a further development of the cervical spine injury depends on a number of factors which are not of medical nature but are

related to the job type, family situation and socio-economic status of the injured person. The symptoms may also be concealed over the first few days, and occur a week or two after the injury as »late symptoms » presenting a serious problem to both the patient and physician. Even though the injured person is often young and healthy, after the injury he/she becomes dependent on long-term medical care and care of their families and social institutions<sup>7</sup>. Eventually, after medical treatment, more or less successful rehabilitation, they are usually incapable of returning to their previous job.

### Patients and Methods

We examined 47 out patients with whiplash injuries to cervical spine. The patients were recruited from Neurology Department of the University Hospital in Zagreb. There were 34 (72.3%) males and 13 (27.6%) females aged from 21 to 66 years. The mean age of the group was 37.1 years. Informative consents were obtained from all patients before entering the study. The following diagnostics criteria were used: standard usual neurological examination, Colour Doppler Flow Imaging (CDFI) of carotid arteries, Transcranial Colour Doppler (TCD), Computed Topography (CT) of the brain, electrocardiogram (ECG) and standard and functional cervical spine X-ray. The patients were analysed at one month and six months after the injury. TCD examination was performed by the use of a pulsed wave Doppler ultrasound device 3-D TCD scanner, with a 2 MHz probe, acoustic focusing. A real-time spectrum analysis blood flow velocity (BVF) was measured in standardised cycle-time intervals in terms of the time-mean value of the Doppler velocity spectrum outline<sup>9,10</sup>. Mean blood flow velocities (MBFV), systolic (SV) and diastolic (DV) velocities in the vertebrobasilar system were determined

at one month and six months from the injury in the standardised manner.

Normal values of transcranial Doppler velocities are 36.9 cm/sec for VA (vertebral artery) and 42.10 cm/sec for basilar artery (BA)<sup>10,11</sup>. The data are presented as means with standard deviations (SD) and as frequency tables. Comparison was made between the results obtained during the first month and six months after the injury. The data have been analysed by the chi-square test and variance analysis (ANOVA). A value of  $p < 0.05$  was considered as a level of statistical significance.

### Results

We evaluated 47 patients with whiplash injuries to cervical spine. There were 34 (72.3%) men and 13 (27.6%) women mean age 37.1 (age range 21–66 years). There were 29 (61.7%) drivers and 18 (38.2%) passengers. The proportion of particular subjective symptoms in patients with whiplash injury is illustrated in Figure 1. The most common complaint was cervical pain, reported by 92% and 46% of patients at one and six months after the injury, respectively. It was followed by a headache reported by 28% of patients at one month, and persisting as a cervicocephalic syndrome in 56% six months after the injury. The respective percentage for the symptom of vertigo as hallucinations of movement or turning was 20% and 8%. Tinnitus and dizziness were reported by 26% at one month, and disappeared at six months, whereas ataxia was present in 36% of patients. Limited movements, ante flexion, retroflexion, or rotation were found in 96% and 46% of patients one month and six months after injury, respectively.

Figure 2 shows data of patient CT scan. Two patients had multiple low-density lesions of the pons and in the left cerebellar hemisphere. Three patients had

hypodense lesions of the right cerebellar hemisphere, and two had previous ischemic lesions in the frontoparietal area. In 9 (19.1%) cases, CDFI showed a hypoplastic left or right vertebral artery. Asymmetrical vertebral arterial size suggests an abnormality. In 61.7% of cases, osseous deformities could have led to vascular insufficiency by limiting normal movements of the vertebral arteries, when moving the head relative to the neck. Four (8.5%) patients had chronic atrial fibrillation.

Results of TCD examinations of the left vertebral artery /AVL/ at one month and six months after injury (measurement 1 and 2) are presented in Figure 3. At one month the increase in mean blood flow velocity occurred in 32 patients (68.0%), and after six months in 24 pa-

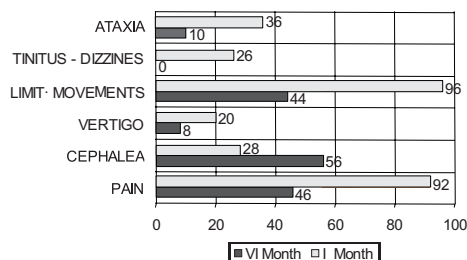


Fig. 1. Distribution of symptoms at one month and six months after whiplash injury.

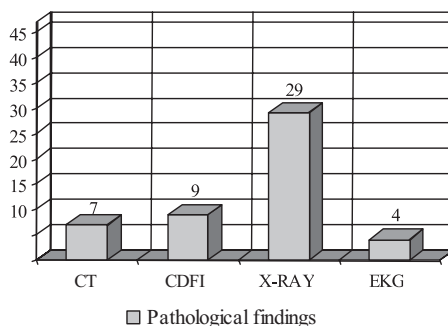


Fig. 2. Percent of pathologic findings according to the type of examination.

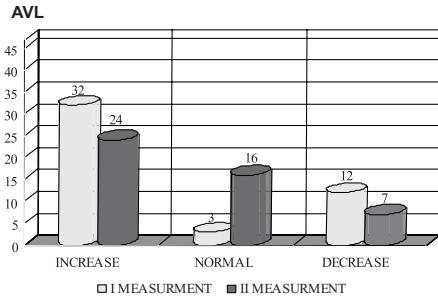


Fig. 3. Mean values of blood flow velocities – two AVL (left vertebral artery) measurements.

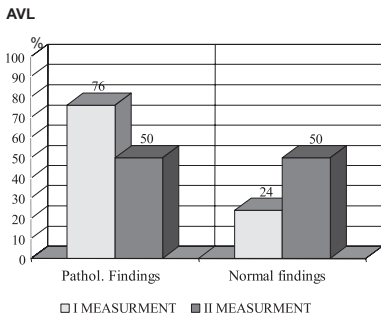


Fig. 4. Percent of pathologic findings – two AVL (left vertebral artery) measurements.

tients (51.0%), whereas the decrease during the first month occurred in 12 patients (25.5%) and six months later in 7 patients (14.85%). Normal mean blood velocity was recorded in only 3 patients (6.3%) and six months after the injury in 16 patients (34.0%). After one month pathological findings were recorded in 76% and at six months in 50% of the study patients. The difference between the two measurements was statistically significant ( $\chi^2 = 0.6368$ ;  $p < 0.05$ ) (Figure 4). During the recovery period, a statistically significant difference was recorded between the first and the second measurement in the right vertebral artery /AVR/.

Mean blood velocity in AVR increased in 30 patients (63.8%) during the first measurement and in 24 patients (51.0%)

during the second measurement, whereas it decreased in 5 patients (10.6%) after the first measurement and in 6 patients (12.7%) during the second one. The normal findings were recorded in 12 patients (25.5%) during the first measurement and in 17 patients (36.1%) during the second one (Figure 5).

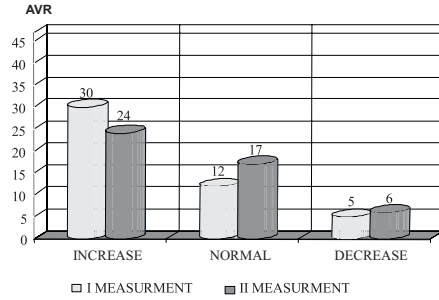


Fig. 5. Mean values of blood velocities – two AVR (right vertebral artery) measurements.

The percentage of pathological findings in the first and second measurement was 66% and 53%, and normal findings 34% and 47% respectively ( $\chi^2 = 0.6368$ ;  $p < 0.05$ ) (Figure 6).

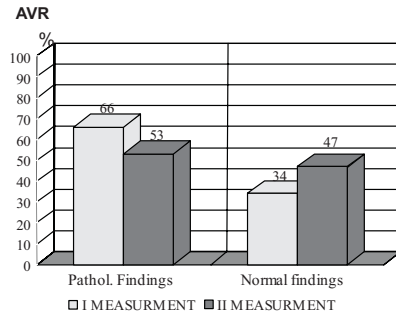


Fig. 6. Percent of pathologic findings – two AVR (right vertebral artery) measurements.

Results of TCD examination of basilar artery /BA/, including measurement 1 and 2, are presented in Figure 7. During

the first measurement we found mean blood velocity increase in 24 patients (54.1%), decrease 13 patients (27.6%) and normal findings in 10 patients (21.2%). During the second measurement the increase occurred in 16 patients (34.0%), decrease in 11 patients (23.4%) and normal findings were recorded in 20 patients (42.5%).

There were 62% and 38% of pathological and normal findings, whereas during the second measurement a reverse proportion (38 % and 62%) of pathological and normal findings was recorded ( $\chi^2 = 0.6368$ ;  $p < 0.05$ ) (Figure 8).

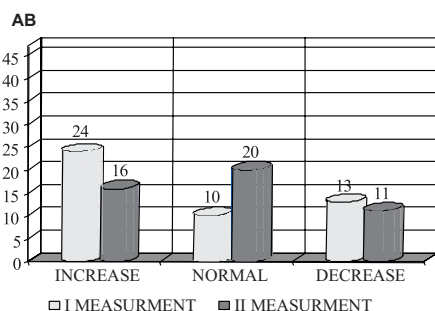


Fig. 7. Mean values of blood velocities – two BA (basilar arter) measurements.

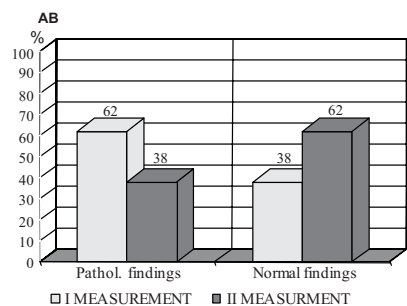


Fig. 8. Percent of pathologic findings – two BA (basilar arter) measurements.

## Discussion

In this study, the presence of symptoms and signs was assessed in the pa-

tients with whiplash injury. The importance of recovery period was statistically evaluated and reliability estimated comparing results obtained by the method of TCD.

The principles of hemodynamics are important for understanding transcranial Doppler results. Cerebral hemodynamics is a complicated process because many factors interact. For example, the blood flow in a specific brain region is influenced by: arterial pressure, intracranial pressure, blood hematocrit (viscosity), blood vessel stenosis and collateral circulation with cerebral autoregulation<sup>10–14</sup>.

The difficulties in VA visualisation by ultrasound are sometimes due to its anatomic variability. The course may be tortuous or aberrant, with V2 segment starting at the level of C2 vertebra. Visualisation of hypoplastic VA is particularly difficult and duplex findings may include poor colour flow opacification, low flow velocities and increased resistance<sup>15,16</sup>.

Hypoplasia of one vertebral artery was found in 9 (19.1%) right vertebral arteries and 3 (6.3%) of the left arteries. Percentage of about 20% corresponded to that obtained by Order et al<sup>19</sup>. Its hemodynamic effect should not be neglected, especially in younger patients. A lesion to the cervical spine soft tissues can affect the flow of the vertebral arteries that pass through the transverse processes of the cervical vertebrae, which can manifest as unilateral alterations of the blood flow velocity in the affected vertebral artery. However, it is well known from both arteriographic and doppler studies that vertebral arteries are very variable in diameter; there is often hypoplasia of the artery on one side, usually on the right, with considerable asymmetry in diameters between the left and right vertebral arteries, and consequently different blood flow velocity that are detectable by a duplex sonography<sup>17,18</sup>.

Oder et al.<sup>19</sup> suggested that VA hypoplasia associated with impaired blood rheology is a risk factor for symptomatic of vertebrobasilar disease. They analysed 48 patients exhibiting sonographic abnormalities of one VA and found 24 (50%) of them to have VA hypoplasia. Based on the results obtained in eight patients, Chaturvedi et al.<sup>20</sup> suggested that a hypoplastic basilar artery is frequently accompanied by VA hypoplasia, which can predispose adults to posterior circulation ischemia.

We can explain why whiplash injury symptoms can be continued six and more months after the injury. Among the pathologic results in whiplash injury BFV increased in all of three vessels during the first month over the 50% (AVL 68%, AVR 63.8%, BA 54.1%) and suggested vasoconstriction of resistance vessels.

A myogenic hypothesis (Baykiss effect) says that an intrinsic property of the vascular smooth muscle of resistance arteries responds to changes in transmural pressure with parallel changes in muscle tone<sup>21–23</sup>. Furthermore, isolated segments of cerebral arteries do react to the increase in transmural pressure by vasoconstriction<sup>24</sup>. During a cervical injury cervicoreceptors also send reflexive stimuli through the spinocervical reflex, which results in turning of the body in space on its axis<sup>25</sup>.

A factor that was also of importance in some instances is osteoarthritis of the cervical spine. When osteophytes protrude into the canal impinge on to the vertebral arteries or reduce the space in which it lies, the movement of the vertebra in relation of one to another can cause stretching or pinching.

Increase in velocity precedes clinical symptoms and can therefore be used as a prognostic factor for the management of the patients with whiplash injury. For evaluation of this problem 47 consecutive

patients admitted during the first month and later following whiplash injury were examined daily by TCD for six months. The velocities in both measurements were correlated with the clinical status and neurological signs. The comparison between the velocity and clinical status curves shows that in symptomatic vasospasm the increase in velocity occurs, as expected, before the manifestation of clinical symptoms. Therefore, Doppler findings can be used as prognostic factors.

The findings in our study that some of decrease of velocity (AVL 25.5%, AVR 10.6% and AB 27.6%) may be a function of lumen dimension of vessels or directly, so a lesion to the cervical spine soft tissues can affect the flow in the vertebral arteries that pass through the transverse processes of the cervical vertebrae.

## Conclusions

At present, it is still impossible to determine each particular site of the CNS lesion in the patients with a whiplash cervical spine injury. Accurate assessment of severity of a whiplash injury is difficult, due to the absence of the pathognomic sign or diagnostic test. Also, the data from the literature suffer from a selective sampling error between different specialists interested in the topic. However, there is considerable body of indirect and corroborative evidence that there is an appreciable physical accident even at relatively low velocities, and that patients have a genuine symptom with, however, considerable variation in the way they react to them.

Our results pointed to different cerebral hemodynamic changes in normal and pathologic findings following a whiplash injury due to a car accident. The high prevalence of vertebral artery pathologic findings could be attributed to injuries to the neck vessels and muscles. Doppler findings of vertebral arteries

should therefore be taken just as additional evidence in the series of diagnostic tests, after the whiplash injury sequels. An exception would be in the cases when the patient has normal doppler finding of vertebral arteries prior to the injury, and pathologic finding after the injury that could be attributed exclusively to the whiplash injury. TCD is a useful method

for a diagnose and a follow-up of the patients with whiplash injuries. In these patients, TCD should be routinely performed. Six months after the whiplash injury appears to be the critical point of recovery.

## REFERENCES

1. GAY, J. R., K. H. ABBOT, *Jama*, 152 (1953) 1698. — 2. PORTER, K. M., B. M. J., 298 (1988) 973. — 3. RADANOV, B. P., M. STURZENEGGER, G. Di STEFANO, A. SCHNIDRIG, *Br. J. Rheumatol.*, 33 (1994) 442. — 4. HINOKI, M., *Acta Otolaryngol. (Stockh.)*, 67 (1985) 1289. — 5. WATKINSON, A., M. F. GARGAN, G. C. BANNISTER, *Injury*, 23 (1991) 307. — 6. PETERSON, K., C. HILDINDSSON, G. TOOLANEN, M. FAGERLUND, J. BJOERNEBRINK, *Acta Orthop. Scand*, 65 (1994) 525. — 7. HOHL, M., *J. Bone Joint Surg.*, 56 (1974) 1675. — 8. BRKLJAČIĆ, B., S. MIŠKOV, *Acta Clin. Croat.*, 37 (1998) 269. — 9. DEMARIN, V.: Dopler sonography. In *Croat. In: DEMARIN, V. (Ed.): Brain blood circulation. (Naprijed, Zagreb, 1994)*. — 10. ALEXANDROV, A., V. DEMARIN, *Acta Clin. Croat.*, 38 (1999) 97. — 11. LOVRENČIĆ –HUZJAN, A., V. DEMARIN, M. BOSNAR, V. VUKOVIĆ, *Coll. Antropol.*, 23 (1999) 175. — 12. STANDGAARD, S., O. B. PAULSON, *Stroke*, 15 (1984) 413. — 13. KIMURA, K., M. YASAKA, H. MORIYASU, T. TSUCHIWA, T. YAMAGUCHI, *Stroke*, 25 (1994) 1006. — 14. LOVRENČIĆ –HUZJAN A., V. VUKOVIĆ, M. BOSNER-PURETIĆ, V. DEMARIN, *Acta Clin. Croat.*, 38 (1999). — 15. TRATTNIG, S., P. HUBSCH, H. SCHUSTER, D. POLZEITNER, *Stroke*, 21 (1990) 1222. — 16. REIS, S., W. STEINKE, G. DEVUYST, N. ARTEMIS, A. VALIKOVICS, M. HENNERICI, *J. Neuroimaging*, 8 (1998) 71. — 17. ZWIEBEL, W. J., *Am. J. Roentgenol.*, 158 (1992) 29. — 18. HENNERICI, M., A. AULICH, W. SANDAM, H. J. FREUND, *Stroke*, 12 (1981) 750. — 19. ODER, B., W. ODER, W. LANG, E. MARSCHNIGG, L. DEECKE, *Acta Neurol. Scand.*, 97 (1998) 398. — 20. CHATURVEDI, S., T. G. LUKOVITS, W. CHEN, P. B. GORELICK, *Neurology*, 52 (1999) 980. — 21. HALPERN, W., G. OSOL, *Biomed. Eng.*, 13 (1985) 287. — 22. JOHNSON, P. C.: *Handbook of physiology – The cardiovascular system II* 2 (1980). — 23. ŠERIĆ, V., *Acta Clin. Croat.*, 34 (1995) 205. — 24. OOSTERVELD, W. J., H. W. KORTSCHOT, G. G. KINGMA, H. A. de JONG, M. R. SATCI, *Acta Otolaryngol.*, 111 (1991) 201.

V. Šerić

*Department of Neurology, Vinogradska 29, »Sestre Milosrdnice« University Hospital, 10000 Zagreb, Croatia*

## HEMODYNAMSKE PROMJENE U BOLESNIKA S TRZAJNOM OZLJEDOM VRATA ISPITIVANE (TCD) TRANSKRANIJSKOM DOPLER SONOGRAFIJOM

### SAŽETAK

Sve veći broj trzajnih ozljeda vrata postavlja sve veće zahtjeve pred vertebrobazilarnu dijagonostiku. Ozljeda vratne kraljšnice značajna je u današnje vrijeme, a posljedica je pada, te industrijske, prometne, sportske ili ratne ozljede. U ovom je ispitivanju transkranijaska Dopplerova sonografija (TCD) pomoću uređaja Transscan 3-D EME sa

sondom od 2 MHz primjenjena za procjenu vertebrobazilarnog krvotoka u bolesnika koji su pretrpjeli trzajnu ozljedu vratne kralješnice u prometnoj nesreći. Pomoću TCD ispitali smo 47 bolesnika s klinički dokazanom ozljedom vratne kralješnice, bez radioloških znakova ozljede koštanog tkiva, i to u razdoblju od jednog i šest mjeseci nakon ozljede. Tako dobivene vrijednosti ispitivanih pokazatelja uspoređene su s normalnim vrijednostima brzine strujanja krvi dobivene pomoću TCD i kolerirane s težinom kliničke slike. Mjesec dana nakon ozljede zabilježeni su statistički značajni poremećaji vertebrobazilarnog krvotoka, registrira se povećana brzina strujanja krvi u AVL (68%) u AVR (62%) i u AB (51%) kao spazam. Šest mjeseci nakon ozljede normalne je nalaze imalo oko 50% bolesnika, dok je u preostalim spazam ustrajao u jednoj, dvjema ili svim ispitivanim krvnim žilama. TCD vertebrobazilarnog sustava važna je metoda u dijagnostici i praćenju bolesnika s trzajnom vratnom ozljedom.