

Bilateral dermoid on the bulbar conjunctiva of a Labrador retriever excised by electrocautery - a case report

Abhishek C. Saxena¹, Ninu A. Ravindran^{1*}, Swapan K. Maiti¹, Lokesh J. Venkataravanappa², Nitin P. Kurade², Sivanarayanan T. Balakrishnan¹, Arundeeep P. Sadanandan¹, Siddharth Khattri¹, and Malik M. S. Zama¹

¹*Division of Surgery, Indian Veterinary Research Institute, Izatnagar, India*

²*Division of Pathology, Indian Veterinary Research Institute, Izatnagar, India*

SAXENA, A. C., A. R. NINU, S. K. MAITI, J. V. LOKESH, N. P. KURADE, T. B. SIVANARAYANAN, P. S. ARUNDEEP, S. KHATTRI, M. M. S. ZAMA: Bilateral dermoid in the bulbar conjunctiva of a Labrador retriever excised by electrocautery - a case report. Vet. arhiv 83, 463-467, 2013.

ABSTRACT

A Labrador retriever pup with a bilateral dermoid in the eyes was treated successfully by the use of a unipolar hand held electrocautery unit.

Key words: bilateral dermoid, eye, Labrador retriever, electrocautery

Introduction

A dermoid is a congenital choristoma characterized as ectopic skin in the cornea and/ palpebral or bulbar part of the conjunctiva, (MAGGS, 2003; RENDER and CARLTON, 2001). It may also be located on the eyelids (palpebral or limbus edge) and on the third eyelid (BOŽINOVIĆ and MARINKOVIĆ, 2009). Dermoids have been reported in the English bulldog (BOŽINOVIĆ and MARINKOVIĆ, 2009), German Shepherd (JHALA et al., 2010; PAWDE et al., 2000) and Shih Tzu breeds (CHRISTMAS, 1992) of dogs. The hereditary nature of the disorder is not known, however a genetic cause has been suggested in Saint Bernards and Dachshunds (MAGGS, 2003). Resection is the suggested treatment for dermoids if the cornea is not involved (MAGGS, 2003).

*Corresponding author:

Dr. Ninu A. Ravindran, PhD Scholar, Division of Surgery, Indian Veterinary Research Institute, Izatnagar-243122, Uttar Pradesh, India, Phone: +91 581 2302 870; Fax: +91 581 2303 284; E-mail: ar.ninu@gmail.com

Materials and methods

A 5-month-old male Labrador retriever was referred to the Division of Surgery at the Referral Veterinary Polyclinic with the complaint of a hairy growth in the eyes, excessive lacrimation and mucopurulent discharge. On close examination, hairy growth was observed on bulbar conjunctiva in both the eyes (Fig. 1).

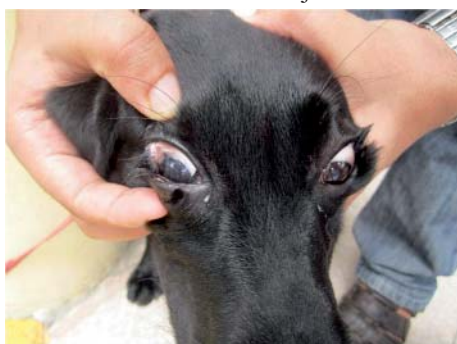

Fig. 1. Bilateral dermoids and mucopurulent discharge

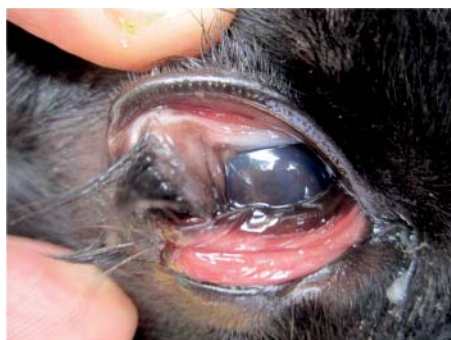

Fig. 2. The right eye with protruding hairy growth

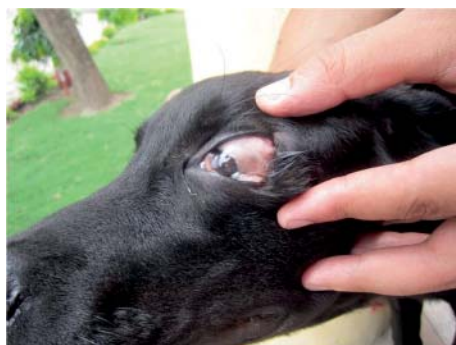

Fig. 3. The left eye with closely adherent hairy growth on the conjunctiva

In the right eye, the growth was seen near the lateral canthus and hairs were protruding from the growth through the palpebral fissure (Fig. 2). In the left eye, hairy small adherent growth was seen near the lateral canthus and this was contiguous with the eyelid (Fig. 3).

There was epiphora and mucopurulent discharge due to irritation caused by the hairs. The animal had normal feeding habits. Temperature, pulse and respiration were in the normal range. The growth was tentatively diagnosed as a congenital bilateral dermoid.

Since it was causing irritation to the eye and was protruding, it was decided to cauterise it. The owner was advised to fast the animal overnight, with withdrawal of water on the day of surgery. The animal was preanesthetized with atropine, at the dose rate of 0.04 mg/kg body mass (b.m.) subcutaneously, and diazepam at the dose rate of 0.3 mg/kg b.m. as a slow intravenous (i/v) injection. Induction and maintenance was done with thiopentone sodium at the dose rate of 10 mg/kg b.m. i/v (to effect). Both the eyes were washed with boric acid (1%) solution. After preparing the eyes aseptically for surgery, the growth in the right eye was cauterised using a unipolar hand-held electrocautery unit (Johnson & Johnson[®]). The closely adherent growth in the left eye was also cauterised in the same manner. The bleeding was effectively controlled by electro-coagulation. Post-operatively, Ciplox[®] (Ciprofloxacin) and Flur[®] (Flurbiprofen) eye drops were given at an interval of one hour three times daily for a week. Corneal opacity was one complication noticed in the right eye, which was successfully treated with Tab. Diamox[®] (Acetazolamide) at the dose rate of 5 mg/kg b.m. orally, twice daily for 3 days.

Results

Histopathology sections of the growth showed keratinised stratified squamous epithelium, deep to this layer, dense collagenous tissue with cross sections of hair follicles and sebaceous glands confirming ectopic skin/dermoid (Fig. 4 and Fig. 5) (H&E staining).

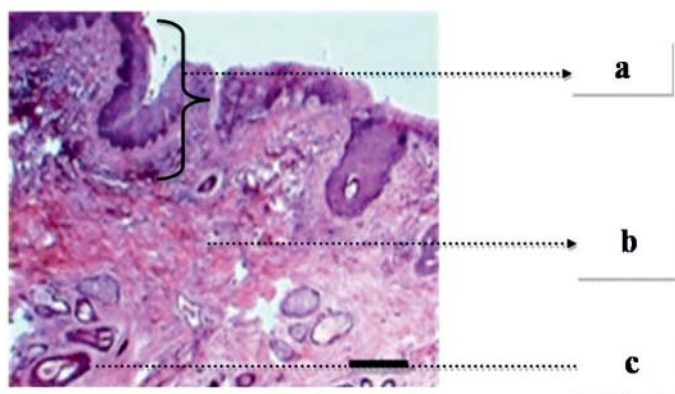


Fig. 4. Histopathology section showing keratinised stratified squamous epithelium (a), collagenous tissue (b) and cross section of hair follicle (c). H&E staining, scale bar = 50 µm

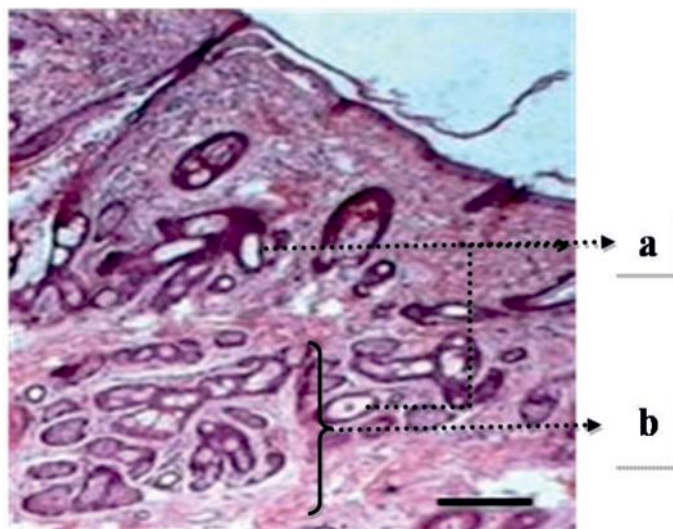


Fig. 5. Histopathology section showing cross section of hair follicles (a) and sebaceous glands (b). H&E staining, scale bar = 50 μ m.

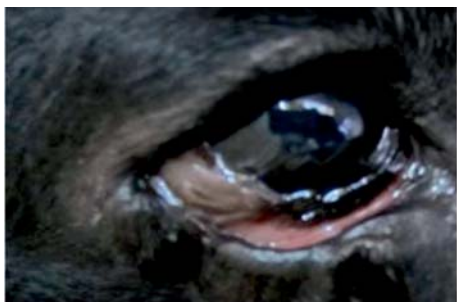

Fig. 6. The right eye showing recovery

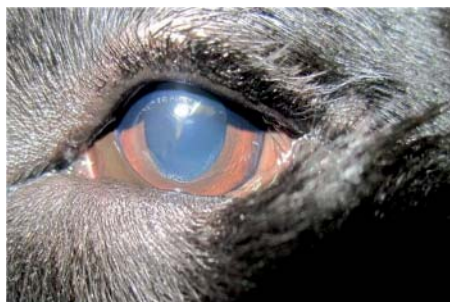

Fig. 7. The left eye showing recovery

Recovery was uneventful, the corneal opacity subsided in a week and the cosmetic appearance of the eyes was also appealing. The excessive lacrimation also ceased. The photos showing complete recovery are given in Fig. 6 and Fig. 7.

Discussion

Dermoids may be cauterized using silver nitrate sticks (VENUGOPALAN, 2000). JHALA et al. (2010) reported the use of ophthalmic cautery for controlling bleeding after surgical removal of a dermoid. Corneal opacity was one complication noticed in the

A. C. Saxena et al.: Bilateral dermoid on bulbar conjunctiva of a Labrador retriever excised by electrocautery

presented case, which was observed even in cases treated by surgical excision (SIMON et al., 2010). Bleeding could be very effectively controlled by electro-coagulation. Also it was possible to remove the closely adhered dermoid in the left eye, completely by electrocautery, which was difficult otherwise.

Bilateral dermoids in the eyes are rarely reported and there are no such reports in Labrador retrievers. The ease of excision, together with effective control of bleeding, could make electrocauterisation a choice of surgical technique for dermoids, which are seen closely adhered to the conjunctiva in the eye and which would be otherwise difficult.

References

- BOŽINOVIĆ, S., D. MARINKOVIĆ (2009): Surgical procedure for limbal dermoid and palpebral coloboma - dermoid in English bulldog puppy. *Vet. Glas.* 63, 125-133.
- CHRISTMAS, R. E. (1992): Common ocular problems of Shih Tzu dogs. *Canadian Vet. J.* 33, 390-393.
- JHALA, S. K., N. JOY, D. B. PATIL, P. V. PARIKH, N. H. KELAWALA, P. A. PATEL (2010): Removal of dermoid cyst in a German Shepherd dog. *Vet. World* 3, 339-339
- MAGGS, D. J. (2003): Conjunctiva. In: *Textbook of Small Animal Surgery*. 3rd ed., (Slatter, D., Ed.), Saunders, Philadelphia, pp: 1340-1348.
- PAWDE, A. M., N. KUMAR, P. KINJAVDEKAR (2000): Bilateral dermoid cyst in a German Shepherd pup: a case report. *Indian Vet. J.* 77, 729-730.
- RENDER, J. A., W. W. CARLTON (2001): The eye and ear. In: *Thomson's Special Veterinary Pathology*. 3rd ed. (Mc Gavin, M. D., W. W. Carlton, J. F. Zachary, Eds.), Mosby Inc., St. Louis, Missouri, pp. 653-707.
- SIMON, S., M. B. J. WILLIAM, VELAVAN, T. A. KANNAN, R. S. KUMAR (2010): Ocular dermoid in calves and its surgical management - a review of five cases. *Indian J. Field Vet.* 6, 69-70.
- VENUGOPALAN, A. (2000): *Essentials of Veterinary Surgery*. 8th ed., Oxford & IBH Publishing Co. Pvt. Ltd., New Delhi, pp. 398.

Received: 21 April 2012

Accepted: 17 April 2013

SAXENA, A. C., A. R. NINU, S. K. MAITI, J. V. LOKESH, N. P. KURADE, T. B. SIVANARAYANAN, P. S. ARUNDEEP, S. KHATTRI, M. M. S. ZAMA: Uklanjanje obostranog dermoida na bulbarnoj spojnici šteneta pasmine labrador retriever elektrokauterom - prikaz slučaja. *Vet. arhiv* 83, 463-467, 2013.

SAŽETAK

Štene pasmine labrador retriever s obostranim dermoidom u očima bilo je uspješno izliječeno upotrebom jednostranog ručnog elektrokautera.

Ključne riječi: obostrani dermoid, oko, labrador retriever, elektrokauterizacija
