



Transient paraplegia after esophagectomy in a patient with thoracic epidural analgesia

NINA SULEN
BARBARA PETANI
IVAN BAČIĆ
TATJANA ŠIMURINA

General Hospital Zadar,
Bože Peričića 5, 23 000 Zadar, Croatia

Correspondence:

Nina Sulen
General Hospital Zadar,
Bože Peričića 5, 23 000 Zadar, Croatia
E-mail: nina.sulen@zd.t-com.hr

Key words: epidural anesthesia, paraplegia,
perioperative hypotension, esophagectomy

Summary

Paraplegia is a rare but devastating complication in esophageal surgery. Epidural analgesia is considered essential in perioperative management of patients with esophageal cancer but carries a risk of causing neurologic deficit. We present a case of sudden postoperative paraplegia and numbness of lower extremities followed shortly after with hypotension and loss of consciousness in a 47-year old patient who underwent total esophagectomy and esophagogastroplasty with thoracic epidural analgesia. Paraplegia was short-lived and resolved with hemodynamic stabilization. We discuss possible causes of neurologic deficit in this patient and emphasise the importance of maintaining spinal cord perfusion pressure by avoiding perioperative hypotension.

INTRODUCTION

Paraplegia is a very rare complication in esophageal surgery. It is usually caused by ischemic insult to spinal cord. Epidural analgesia is considered essential in perioperative management of patients with esophageal cancer. It decreases incidence of respiratory complications which are the leading cause of perioperative morbidity and mortality and improves microcirculation in gastric conduit. Epidural analgesia can cause complications as vertebral canal haematoma and direct injury of spinal cord with neurologic deficit (1). We present a patient who underwent total esophagectomy with thoracic epidural analgesia and who suddenly developed postoperative paraplegia and numbness of lower extremities.

CASE REPORT

A 47-year old men underwent right thoracotomy, medial laparotomy and cervicotomy with total esophagectomy and esophagogastroplasty. His medical history revealed that he developed progressive dysphagia and was able to ingest only small amounts of liquids. He also complained of nausea, epigastric pain and loss of weight. Ulcerative lesion 30 cm from incisors noticed during gastroscopy was histologically diagnosed as cancer. He smoked 2 packs/cig/day but his spirometry showed only minor restriction. The only medication he was taking was pantoprazole. Thoracic epidural catheter was placed before anesthesia induction at Th10–11 level without technical difficulty and tested with 3ml of 2% lidocaine. Following anesthesia induction left double lumen tube was placed. Thereafter anesthesia was BIS guided combined general and epidural. It was maintained with sevoflurane and 5 ml bolus

doses of 0.25% levobupivacaine and fentanyl 5mcg/ml administered every hour. Cardiac index was monitored intraoperatively with LiDCO rapid monitor and was between 3,5–4,7 l/min/m². During anesthesia patient had four short episodes of hypotension with the lowest BP of 85/50 mmHg which were corrected with 2-mg bolus doses of ethylphenylephrine. Surgery lasted 5 hours and during that period patient received 2 units of red blood cells, 1500 ml of colloids and 4500ml of cristalloids. Patient was awakened and extubated in OR and was able to move his feet. Upon arrival to intensive care unit epidural analgesia was started with 0.1% levobupivacaine and fentanyl 2 mcg/ml at rate of 5 ml/h. His blood pressure dropped from 160/85 to 85/45 mmHg and he received another 2- mg bolus of ethylphenylephrine. Thereafter BP values were mostly 100/60 mmHg with adequate diuresis, postoperative acid base status and hemoglobin. Right chest drain was placed on suction of –20 cm H₂O and left chest drain was on valve. Postoperative chest X-ray showed minor pleural effusion on the left side. Eight hours after arrival in ICU patient developed paraplegia with numbness of lower extremities. Emergence of paraplegia was not preceded with gradual development of motor weakness and numbness but was rapid in onset. Since relatively low infusion rate of diluted local anesthetic was used for epidural analgesia it was considered that it was not the likely cause of paraplegia. Shortly after that patient became unresponsive and pale and his BP suddenly dropped to 76/52 mmHg. His breath-sounds were diminished on the left side. He received bolus of 500 ml of colloids and suction to his right thoracic drain was discontinued upon surgeons request. His BP rose to 140/70 mmHg and he became responsive again. CT angiography of thorax showed significant pleural effusion on the left side. CT scans of thoracic and lumbar spine were normal. During CT scanning patient begun to move his feet again. New thoracic drain was placed on the left and 650 ml of sanguinous effusion was drained initially and another 780 ml in next 5 hours. His hemoglobin value dropped from 100 to 90 g/L. He remained hemodynamically stable thereafter. Since neurologic impairment resolved within an hour during diagnostic evaluation formal neurologic examination was not

performed. Epidural analgesia was gradually reintroduced the next morning and was continued during next 3 days without complications.

DISCUSSION

The patient with thoracic epidural analgesia who develops paraplegia several hours after major esophageal surgery represents significant diagnostic dilemma. In the vast majority of cases motor weakness and numbness are due to accumulation or subarachnoid spread of local anesthetic which resolve on discontinuation of epidural analgesia but sudden appearance of paraplegia should raise suspicion, especially if low volumes of diluted local anesthetics were used. Careful evaluation should be performed before decision to simply discontinue infusion of local anesthetic and wait for resolution of its effect or to refer the patient for further diagnostic evaluation. Delay in establishing diagnosis or delayed surgical intervention in case of epidural haematoma significantly aggravates outcome (2, 3). The method of choice for imaging of spinal cord pathology is MRI but unfortunately in this case urgent MRI was not available.

Paraplegia after esophageal resections is rare. Only few case reports are cited in the literature. Lesions of spinal cord are caused by ischemic insult and occur in patients with atherosclerosis and diabetes mellitus. Proposed mechanisms are interruption of blood supply of spinal cord during tumor resection and mechanical manipulation of thoracic aorta with dislodgment of atherosclerotic plaques leading to occlusion of spinal arteries (4, 5).

Prolonged periods of hypotension during surgery or in the postoperative period pose significant risk of spinal cord hypoperfusion with resultant ischemic insult (6). Studies in patients with repair of thoracoabdominal aneurysms indicate that paraplegia mostly occurs postoperatively and that hypotension in postoperative period presents significant risk factor for its occurrence (7). Venous congestion also decreases spinal cord perfusion pressure. The combination of hypotension with raised venous pressure can lead to critical lowering of spinal cord perfusion pressure and produce neurologic deficit (8, 9, 10).

Since preoperative value of our patients BP was 140/80 and postoperative 100/60 mmHg he was relatively hypotensive in the postoperative period. He suddenly developed paraplegia with numbness of lower extremities followed shortly after with hypotension and loss of consciousness. Volume replacement and disconnection of the right thoracic drain from suction led to hemodynamic stabilization and gradual dissolution of paraplegia. Combined effects of pleural effusion on the left side and application of suction on the right thoracic drain after dissection of mediastinal pleura during tumor resection could cause mediastinal shift to the right with obstruction of venous return to the heart with venous congestion distally. We postulate that our patient developed transient paraplegia as a result of decrease in spinal cord perfusion

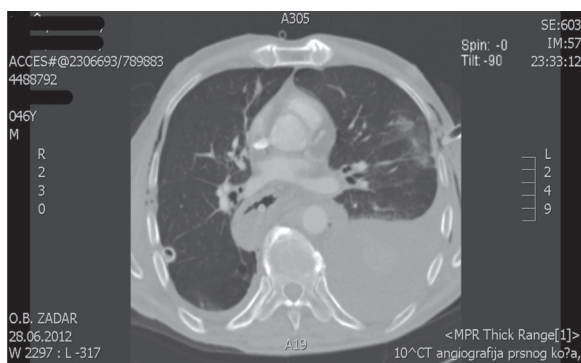


Figure 1. CT image shows pneumomediastinum, pleural effusion on the left side and gastric conduit in posterior mediastinum.

pressure due to combination of relative hypotension, hypovolemia and possibly venous congestion. Epidural analgesia contributed to development of hypotension and inhibited compensatory tachycardia. Although epidural anesthesia as a cause of his neurologic deficit can not be excluded, sudden appearance of paraplegia, use of low volumes of diluted local anesthetic, fast resolution and uneventful use of epidural analgesia afterwards makes this unlikely.

We recommend vigilant monitoring of patients with thoracic epidural analgesia after major thoracic surgery. Development of any kind of neurologic deficit should prompt careful evaluation. Hypotension in the perioperative period must be avoided to preserve spinal cord perfusion pressure.

REFERENCES

1. NG JM 2011 Update on anesthetic management for esophagectomy. *Curr Opin Anesthesiol* 24: 37–43
2. FREISE H, VAN AKEN H K 2011 Risk and benefits of thoracic epidural anaesthesia. *Br J Anaesth* 107: 859–68
3. WILDSMITH J A W 2012 Continuous thoracic epidural block for surgery: gold standard or debased currency? *Br J Anaesth* 109: 9–12
4. MASSAD M G, DONAHUE P E, RUBEIZ H 2001 Paraplegia after esophagectomy: who are patients at risk? *J Thorac Cardiovasc Surg* 121: 386–8
5. BUTTERWORTH J, DOUGLAS-AKINWANDE A 2007 Lower Extremity Paralysis After Thoracotomy or Thoracic Epidural: Image First, Ask Questions Later. *Anesth Analg* 104: 201–203
6. MONSEL S, RODESH G, LALOE PA 2007 Neurologic Dysfunction After Major Thoracic Surgery in a Patient with Severe Arteriosclerotic Disease Receiving Epidural Analgesia. *Anesth Analg* 104: 204–206
7. ETZ C D, LUEHR M, KARI F A 2008 Paraplegia after extensive thoracic and thoracoabdominal aortic aneurysm repair: does critical spinal cord ischemia occur postoperatively? *J Thorac Cardiovasc Surg* 135: 324–30
8. KOBAYASHI S, YOSHIZAWA H, SHIMADA S 2013 Changes of blood flow, oxygen tension, action potential and vascular permeability induced by arterial ischemia or venous congestion on the spinal cord in canine model. *J Orthop Res* 31: 139–46
9. AULER M A, AL-OKAILI R, RUMBOLT Z 2005 Transient Traumatic Spinal Venous Hypertensive Myelopathy. *Am J Neuroradiol* 26: 1655–1658
10. WILLIAMS A, LITTLE M, GIBBS J 2003 Spinal Cord Infarction Following Central-Line Insertion. *Renal Failure* 25: 327–329