

INTENSITY AND DISTRIBUTION OF IMMUNOHISTOCHEMICAL EXPRESSION OF GALECTIN-3 IN THYROID NEOPLASMS

Dubravka Mateša-Anić¹, Sandra Moslavac², Neven Mateša³, Hrvoje Čupić⁴ and Zvonko Kusić³

¹University Department of ENT and Head and Neck Surgery, Rijeka University Hospital Center, Rijeka; ²Department of Clinical Cytology, Sunce Polyclinic; ³University Department of Oncology and Nuclear Medicine, ⁴Ljudevit Jurak University Department of Pathology, Sestre milosrdnice University Hospital Center, Zagreb, Croatia

SUMMARY – The aim of the study was to assess the intensity and distribution of galectin-3 expression in benign and malignant thyroid neoplasms by immunohistochemical method. Immunohistochemical expression of galectin-3 was analyzed in surgical thyroid specimens from 82 patients with histopathologic diagnosis of follicular adenoma (n=32), Hürthle cell adenoma (n=10) and papillary carcinoma (n=40). Results of intracytoplasmatic and intranuclear expression of galectin-3 were scored using a semi-quantitative scale for intensity. Intracytoplasmatic expression of galectin-3 was positive in 18 (43%) benign neoplasms and in all 40 malignant neoplasms. The accuracy, sensitivity and specificity of intracytoplasmatic expression of galectin-3 as a malignant marker in thyroid neoplasms were 78.1%, 100% and 57.1%, respectively. Intracytoplasmatic expression of galectin-3 was positive in 10 (31%) cases of follicular adenoma and 8 (80%) cases of Hürthle cell adenoma. The accuracy, sensitivity and specificity of intranuclear expression of galectin-3 as a malignant marker in thyroid neoplasms were 84.1%, 100% and 69%, respectively. There was no strong intensity of either intracytoplasmatic or intranuclear expression of galectin-3 in benign thyroid neoplasms, and no weak intensity of either intracytoplasmatic or intranuclear expression of galectin-3 in malignant neoplasms. There was no statistically significant difference between intracytoplasmatic and intranuclear expression of galectin-3 in benign thyroid neoplasms. The results of our study indicate that the immunohistochemical expression of galectin-3 is a highly sensitive marker of malignancy, with low specificity in differentiating malignant from benign thyroid neoplasms. The analysis of intensity and distribution of galectin-3 expression could improve the specificity of the method.

Key words: *Galectin-3; Immunohistochemistry; Thyroid tumors*

Introduction

With the advent of the era of molecular pathology, some researchers believe that traditional evaluation of H&E-stained slides may be at the brink of extinction, while others believe that traditional H&E-staining

still is and will remain the 'gold standard' of diagnostic pathology¹⁻⁴. Molecules that may be expressed during the crucial steps in the development of malignancy are expected to have strong effects on clinical management^{5,6}.

Although postsurgical analysis of tumor architecture usually provides the current criteria for definitive evidence of malignancy in thyroid neoplasms, distinction of hyperplastic nodules from papillary carcinoma or follicular carcinoma can be difficult. In encapsulated neoplasms composed exclusively of follicles and

Correspondence to: *Dubravka Mateša-Anić, MD*, University Department of ENT and Head and Neck Surgery, Rijeka University Hospital Center, Krešimirova 42, HR-51000 Rijeka, Croatia
E-mail: *dmatasa@yahoo.com*

Received June 1, 2011, accepted May 23, 2012

lacking capsular and vascular invasion, distinction between follicular adenoma and follicular variant of papillary carcinoma rests on the pathologist's perception of nuclear characteristics of follicular cells. Furthermore, differentiation between follicular adenoma and follicular carcinoma may be difficult in cases of minimally invasive follicular carcinoma.

Several molecular markers have been reported to be helpful in distinguishing between benign and malignant follicular-patterned lesions of the thyroid. Among them, the most promising is a beta-galactoside-binding protein galectin-3⁷⁻¹³. Despite its high sensitivity, some authors have reported its expression in benign thyroid lesions, contributing to its lower specificity¹⁴⁻¹⁶.

In the current study, we used the immunohistochemistry method to study the intensity and distribution of galectin-3 expression in surgical material from benign and malignant thyroid neoplasms. Our aim was to evaluate the efficiency of galectin-3 expression as a molecular marker of malignancy.

Patients and Methods

The patients included in this study were assigned from University Department of ENT and Head and Neck Surgery, Sestre milosrdnice University Hospital Center, Zagreb, Croatia. We analyzed the immunohistochemical expression of galectin-3 in surgical thyroid specimens from 82 patients with histopathologic diagnosis of follicular adenoma (n=32), Hürthle cell adenoma (n=10) and papillary carcinoma (n=40).

For immunohistochemistry, mouse monoclonal antibody to galectin-3 (Novocastra, UK; 1:100) was prepared according to the manufacturer's instructions. Immunohistochemistry was performed using the indirect avidin-biotin complex immunoperoxidase method.

Results of intracytoplasmatic and intranuclear expression of galectin-3 were scored using a semi quantitative scale for intensity: negative (-), weak (+), moderate (++) or strong (+++).

Sensitivity, specificity, predictive value, and diagnostic accuracy were assessed to evaluate the efficiency of galectin-3 as a malignant marker in thyroid neoplasms.

Data analysis was performed using statistical χ^2 -test or Fisher exact test.

Results

Intracytoplasmatic expression of galectin-3

Intracytoplasmatic expression of galectin-3 was positive in 18 (43%) benign neoplasms and in all 40 malignant neoplasms (100%) (Fig. 1). There was a statistically significant difference in the intracytoplasmatic expression of galectin-3 between benign and malignant thyroid neoplasms ($p < 0.01$) (Table 1).

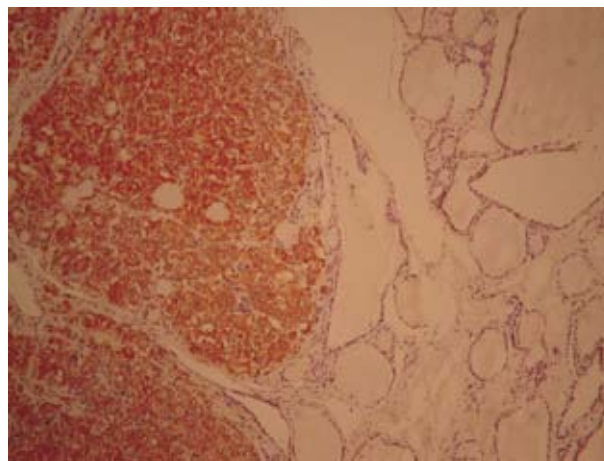


Figure 1. Strong intensity of intracytoplasmatic and intranuclear expression of galectin-3 in thyroid papillary carcinoma (H&E)

The accuracy, sensitivity and specificity of intracytoplasmatic expression of galectin-3 as a malignant marker in thyroid neoplasms were 78.1%, 100% and 57.1%, respectively. Positive and negative predictive values were 68.9% and 100%, respectively.

Intracytoplasmatic expression of galectin-3 was positive in 10 (31%) cases of follicular adenoma and 8 (80%) cases of Hürthle cell adenoma. There was a statistically significant difference in intracytoplasmatic expression of galectin-3 between follicular adenoma and Hürthle cell adenoma ($p < 0.01$) (Table 2).

Table 1. Intracytoplasmatic expression of galectin-3 in benign and malignant thyroid neoplasms

	Galectin-3 positive	Galectin-3 negative	Total
Benign neoplasms	18	24	42
Malignant neoplasms	40	0	40
Fisher exact test: $p < 0.01$			

Table 2. Intracytoplasmatic expression of galectin-3 in follicular adenoma and Hürthle cell adenoma

	Galectin-3 positive	Galectin-3 negative	Total
Follicular adenoma	10	22	32
Hürthle cell adenoma	8	2	10

Fisher exact test: $p < 0.01$

Table 3. Intranuclear expression of galectin-3 in benign and malignant thyroid neoplasms

	Galectin-3 positive	Galectin-3 negative	Total
Benign neoplasms	13	29	42
Malignant neoplasms	40	0	40

Fisher exact test: $p < 0.01$

Table 4. Intranuclear expression of galectin-3 in follicular adenoma and Hürthle cell adenoma

	Galectin-3 positive	Galectin-3 negative	Total
Follicular adenoma	7	25	32
Hürthle cell adenoma	6	4	10

Fisher exact test: $p < 0.05$

Table 5. Intensity of intracytoplasmatic expression of galectin-3 in benign and malignant thyroid neoplasms

	gal-3 +	gal-3 ++	gal-3 +++	gal-3 -	Total
Benign neoplasms	9	9	0	24	42
Malignant neoplasms	0	7	33	0	40

χ^2 -test: $p < 0.01$

Table 6. Intensity of intranuclear expression of galectin-3 in benign and malignant thyroid neoplasms

	gal-3 +	gal-3 ++	gal-3 +++	gal-3 -	Total
Benign neoplasms	6	7	0	29	42
Malignant neoplasms	0	7	33	0	40

χ^2 -test: $p < 0.01$

There was a statistically significant difference in intracytoplasmatic expression of galectin-3 in papillary carcinoma *vs.* follicular adenoma (Fisher exact test: $p < 0.01$), and in papillary carcinoma *vs.* Hürthle cell adenoma (Fisher exact test: $p < 0.05$).

Intranuclear expression of galectin-3

Intranuclear expression of galectin-3 was positive in 13 (31%) benign neoplasms and in all 40 malignant neoplasms (100%). There was a statistically significant difference in intranuclear expression of galectin-3 between benign and malignant thyroid neoplasms ($p < 0.01$) (Table 3). The accuracy, sensitivity and specificity of intranuclear expression of galectin-3 as a malignant marker in thyroid neoplasms were 84.1%, 100% and 69%, respectively. Positive and negative predictive values were 75.5% and 100%, respectively.

Intranuclear expression of galectin-3 was positive in 7 (22%) cases of follicular adenoma and 6 (60%) cases of Hürthle cell adenoma. There was a statistically significant difference in intranuclear expression of galectin-3 between follicular adenoma and Hürthle cell adenoma ($p < 0.05$) (Table 4).

Intensity of intracytoplasmatic and intranuclear expression of galectin-3

In 82 patients, the intensity of intracytoplasmatic and intranuclear expression of galectin-3 was analyzed separately. There was no strong intensity of either intracytoplasmatic or intranuclear expression of galectin-3 in benign thyroid neoplasms, and no weak intensity of either intracytoplasmatic or intranuclear expression of galectin-3 in malignant neoplasms. There was a statistically significant difference in the intensity of expression of galectin-3 between benign and malignant thyroid neoplasms ($p < 0.01$) (Tables 5 and 6).

Intracytoplasmatic vs. intranuclear expression of galectin-3

Intracytoplasmatic and intranuclear expression of galectin-3 was present in all malignant thyroid neoplasms. Intracytoplasmatic expression of galectin-3 was positive in 18 benign thyroid neoplasms, and intranuclear expression of galectin-3 was positive in 13 (72%) of these cases too. There were no cases of only intranuclear expression of galectin-3. We found

no statistically significant difference in intracytoplasmatic *vs.* intranuclear expression of galectin-3 in benign thyroid neoplasms (Fisher exact test: $p=0.8180$), follicular adenomas (Fisher exact test: $p=0.3204$) and Hürthle cell adenomas (Fisher exact test: $p=0.2380$).

Discussion

In this study, all malignant thyroid neoplasms were found to express galectin-3; however, a substantial number (43%) of benign thyroid neoplasms also expressed galectin-3. A few studies have reported negative galectin-3 expression in all benign thyroid lesions and high galectin-3 expression in common malignant thyroid neoplasms^{7-9,17}. Later studies produced conflicting results^{5,10,14-16}. The conflicting results reported by various authors may be because they chose to accept different thresholds of galectin-3 immunostaining as true positive staining, or used different galectin-3 antibodies. Besides, the interpretation of immunohistochemical staining is very subjective and can be technically difficult. Coli *et al.*¹⁸ and Martins *et al.*¹⁴ found immunohistochemical expression of galectin-3 in 63% and in 45% of follicular adenomas, respectively. Maruta *et al.* found positive immunostaining of galectin-3 in 25% of follicular adenoma FNA samples¹⁹. In our study, we found intracytoplasmatic and intranuclear immunohistochemical expression of galectin-3 in 31% and 22% of follicular adenomas, respectively.

Niedziela *et al.* found Hürthle cells present in 6 of 10 galectin-3 positive aspirates, of which 5 lesions were benign¹⁵. Mateša *et al.* found a statistically significant relationship between the presence of Hürthle cells and positive expression of galectin-3 in Hashimoto thyroiditis aspirates and a tendency of such a relationship in nodular goiter aspirates analyzed by RT-PCR method¹⁶. In this study, intracytoplasmatic and intranuclear immunohistochemical expression of galectin-3 was found in 80% and 60% of Hürthle cell adenomas, respectively. We found a statistically significant difference in the expression of galectin-3 between follicular adenomas and Hürthle cell adenomas.

Martins *et al.* found strong galectin-3 immunostaining in half of papillary carcinomas, and no weak or negative staining in this group. They also found strong galectin-3 immunostaining in only 2 (6%) of 31

follicular adenomas¹⁴. Hermann *et al.* found strong galectin-3 immunostaining in the majority of malignant lesions, and only focal reactivity in a few benign adenomatous lesions⁵. In our study, there was no strong intensity of either intracytoplasmatic or intranuclear expression of galectin-3 in benign thyroid neoplasms, and no weak or negative expression, intracytoplasmatic or intranuclear, of galectin-3 in malignant neoplasms.

Immunohistochemical analysis revealed galectin-3 to be distributed predominantly in the cytoplasm with occasional nuclear localization^{9,20}. Mills *et al.* found positive, both intracytoplasmatic and intranuclear, galectin-3 immunostaining in the cytoblocks of papillary carcinoma²¹. In our study, we found both intracytoplasmatic and intranuclear expression of galectin-3 in all malignant thyroid neoplasms. Intracytoplasmatic expression of galectin-3 was more often present in benign thyroid neoplasms than intranuclear expression of galectin-3, but the difference was not statistically significant. There were no cases of only intranuclear expression of galectin-3.

In conclusion, the results of our study indicate that the immunohistochemical expression of galectin-3 is a highly sensitive marker of malignancy, with low specificity in differentiating malignant from benign thyroid neoplasms. The analysis of intensity and distribution of galectin-3 expression could improve the specificity of the method.

References

1. ROSAI J. The continuing role of morphology in the molecular age. *Mod Pathol* 2001;14:258-60.
2. MURPHY WM. Human carcinogenesis, the new genetics, and the practicing pathologist. *Pol J Pathol* 2001;52:115-7.
3. SCULLY RE. One pathologist's reminiscences of the 20th century and random thoughts about the 21st: reflections at the millennium. *Int J Surg Pathol* 2002;10:8-13.
4. ASA SL. How familial cancer genes and environmentally induced oncogenes have changed the endocrine landscape. *Mod Pathol* 2001;14:246-53.
5. HERRMANN ME, TALPOS GB, MOHAMED AN, *et al.* Genetic markers in thyroid tumors. *Surgery* 1991;110:941-7.
6. FUSCO A, GRIECO M, SANTORO M, *et al.* A new oncogene in human thyroid papillary carcinomas and their lymph-nodal metastases. *Nature* 1987;328:170-2.
7. FERNANDEZ PL, MERINO MJ, GOMEZ M, *et al.* Galectin-3 and laminin expression in neoplastic and non-neoplastic thyroid tissue. *J Pathol* 1997;181:80-6.

8. ORLANDI F, SAGGIORATO E, PIVANO G, *et al.* Galectin-3 is presurgical marker of human thyroid carcinoma. *Cancer Res* 1998;58:3015-20.
9. INOHARA H, HONJO Y, YOSHII T, *et al.* Expression of galectin-3 in fine needle aspirates as diagnostic marker differentiating benign from malignant thyroid neoplasm. *Cancer* 1999;85:2475-84.
10. KAWACHI K, MATSUSHITA Y, YONEZOWA S, *et al.* Galectin-3 expression in various thyroid neoplasms and its possible role in metastasis formation. *Human Pathol* 2000;31:428-33.
11. BARTOLAZZI A, GASBARRI A, PAPOTTI M, *et al.* Application of an immunodiagnostic method for improving preoperative diagnosis of nodular thyroid lesions. *Lancet* 2001;357:1644-50.
12. NASCIMENTO MC, BISI H, ALVES VA, *et al.* Differential reactivity for galectin-3 in Hürthle cell adenomas and carcinomas. *Endocr Pathol* 2001;12:275-9.
13. BARONDES SH, COOPER DN, GITT MA, *et al.* Galectins: structure and function of a large family of animal lectins. *J Biol Chem* 1994;269:20807-10.
14. MARTINS L, MATSUO SE, EBINA KN, *et al.* Galectin-3 messenger ribonucleic acid and protein are expressed in benign thyroid tumors. *J Clin Endocrinol Metab* 2002;87:4806-10.
15. NIEDZIELA M, MACELUCH J, KORMAN E. Galectin-3 is not a universal marker of malignancy in thyroid nodular disease in children and adolescents. *J Clin Endocrinol Metab* 2001;87:4411-5.
16. MATEŠAN, ŠAMIJA I, KUSIĆ Z. Galectin-3 and CD44v6 positivity by RT-PCR method in fine needle aspirates of benign thyroid lesions. *Cytopathology* 2007;18:112-6.
17. XU XC, NI-NAGGARAK, LOTAN R. Differential expression of galectin-1 and galectin-3 in thyroid tumors: potential diagnostic implications. *Am J Pathol* 1995;147:815-22.
18. COLI A, BIGOTTI G, ZUCCHETTI F, *et al.* Galectin-3, a marker of well-differentiated thyroid carcinoma is expressed in thyroid nodules with cytological atypia. *Histopathology* 2002;40:80-7.
19. MARUTA J, HASHIMOTO H, YAMASHITA H, *et al.* Immunostaining of galectin-3 and CD44v6 using fine-needle aspiration for distinguishing follicular carcinoma from adenoma. *Diagn Cytopathol* 2004;31:392-6.
20. CVEJIC D, SAVIN S, PAUNOVIC I, *et al.* Immunohistochemical localization of galectin-3 in malignant and benign human thyroid tissue. *Anticancer Res* 1998;18:2637-41.
21. MILLS LJ, POLLER DN, YIANGOU C. Galectin-3 is not useful in thyroid FNA. *Cytopathology* 2005;16:132-8.

Sažetak

INTENZITET I RASPODJELA IMUNOHISTOKEMIJSKE EKSPRESIJE GALEKTINA-3 KOD NOVOTVORINA ŠTITNJAJE

D. Mateša-Anić, S. Moslavac, N. Mateša, H. Čupić i Z. Kusić

Cilj istraživanja bio je imunohistokemijskom metodom utvrditi intenzitet i raspodjelu ekspresije galektina-3 u malignim i benignim tumorima štitnjače. Analizirana je imunohistokemijska ekspresija galektina-3 u kirurškim materijalima 82 bolesnika od kojih je 32 imalo histopatološku dijagnozu folikularnog adenoma, 10 adenoma Hürthleovih stanica i 40 papilarnog karcinoma. Intenzitet intracitoplazmatske i intranuklearne ekspresije galektina-3 određivan je semikvantitativno. Intracitoplazmatska ekspresija galektina-3 bila je pozitivna u 18 (43%) benignih tumora i kod svih 40 malignih tumora. Pouzdanost, osjetljivost i specifičnost intracitoplazmatske ekspresije galektina-3 kao biljega malignosti bile su 78,1%, 100% i 57,1%. Intracitoplazmatska ekspresija galektina-3 bila je pozitivna u 10 (31%) folikularnih adenoma i u 8 (80%) adenoma Hürthleovih stanica. Pouzdanost, osjetljivost i specifičnost intranuklearne ekspresije galektina-3 kao biljega malignosti bile su 84,1%, 100% i 69%. Nije bilo jakog intenziteta ekspresije, bilo intracitoplazmatske ili intranuklearne, galektina-3 kod benignih tumora štitnjače, niti je bilo slabog intenziteta ekspresije, bilo intracitoplazmatske ili intranuklearne, galektina-3 kod malignih tumora. Nije nađena statistički značajna razlika između intracitoplazmatske i intranuklearne ekspresije galektina-3 kod benignih tumora štitnjače. Istraživanje je pokazalo da je imunohistokemijska ekspresija galektina-3 visoko osjetljiva kao biljeg malignosti, ali s niskom specifičnošću u odnosu na benigne tumore štitnjače. Analiza intenziteta i raspodjele ekspresije galektina-3 može poboljšati specifičnost ove metode.

ključne riječi: *Galectin-3; Imunohistokemija; Tumori štitnjače*

