

TORIC INTRAOCULAR LENS IMPLANTATION FOR ASTIGMATISM CORRECTION IN CATARACT SURGERY

Ivanka Petric Vicković¹, Valentina Lacmanović Lončar¹, Zdravko Mandić¹, Renata Iveković¹, Jelena Škunca Herman¹ and Antonio Sesar²

¹University Department of Ophthalmology, Sestre milosrdnice University Hospital Center, Zagreb, Croatia;

²University Department of Ophthalmology, Mostar University Hospital, Mostar, Bosnia and Herzegovina

SUMMARY – The aim of this study was to evaluate clinical outcomes after toric intraocular lens implantation for astigmatism correction in patients undergoing cataract surgery. This prospective observational study included eyes undergoing cataract surgery at Sestre milosrdnice University Hospital Center between February and September 2011. The study enrolled eyes that had visually significant cataract and preexisting regular corneal astigmatism of 1.50 D or greater. Phacoemulsification was performed and all eyes received an AT TORBI™ 709 M toric foldable intraocular lens. At 3 months, the uncorrected distance visual acuity was 0.8 or better in 9 of 10 eyes. At 3 months postoperatively, the median reduction in refractive cylinder was statistically significant ($P < 0.05$). The median intraocular lens axis rotation was 3.0 degrees interquartile range (2.0-4.0 degrees). Our results showed AT TORBI™ 709 IOL to be an effective surgical option to correct preexisting corneal astigmatism and spectacle dependence after cataract surgery.

Key words: *Preoperative astigmatism; Toric intraocular lens; Cataract surgery*

Introduction

Today, the goal of cataract surgery is to correct refractive errors at the time of surgery. To optimize visual outcomes and reduce postoperative spectacle dependence, corneal astigmatism as well as spherical component must be addressed. The prevalence of astigmatism increases with age. Up to 29% of patients with cataract have preexisting astigmatism of more than 1.50 diopters (D)^{1,2}. Preexisting corneal astigmatism can be reduced or eliminated by selective positioning of the phacoemulsification incision³⁻⁶, corneal or limbal relaxing incisions⁷⁻¹⁰, excimer laser keratectomy¹¹, and toric intraocular lens (IOL) implantation¹²⁻¹⁵. All these methods have limitations, advantages and disadvantages. Opposite clear corneal

incisions, single or paired, have a limited flattening effect and long term instability. Correction by corneal and limbal relaxing incisions is limited by the degree of astigmatism and long term mechanical instability. Toric IOL implantation is a predictable and safe procedure. The main problem associated with toric IOL implantation is rotation of the IOL¹²⁻¹⁵.

The aim of this study was to evaluate clinical outcomes after toric IOL implantation for astigmatism correction in patients undergoing cataract surgery.

Patients and Methods

Patients

This prospective observational study included eyes submitted to cataract surgery at Sestre milosrdnice University Hospital Center between February and September 2011. The study enrolled the eyes that had visually significant cataract and preexisting regular corneal astigmatism of 1.50 D or greater. The study

Correspondence to: *Ivanka Petric Vicković, MD, PhD*, University Department of Ophthalmology, Sestre milosrdnice University Hospital Center, Vinogradska c. 29, HR-10000 Zagreb, Croatia
E-mail: ivanka.petric@kbcsm.hr

Received February 22, 2012, accepted June 1, 2012

followed the tenets of the Declaration of Helsinki. All patients provided their written consent. Inclusion criteria were visually significant cataract, age over 40 years, and preoperative regular corneal astigmatism greater than 1.50 D. Exclusion criteria were eyes with a history of retinal detachment, glaucoma, corneal disease, macular degeneration, diabetic retinopathy, neuro-ophthalmic disease, ocular inflammation and previous ocular surgery.

Surgical technique

Preoperatively, reference landmarks on the limbus were marked at 0 degree and 180 degree with the patient seated at a slit lamp with a coaxial thin slit using a sterile marker. All surgeries were performed by the same experienced surgeon using topical anesthesia. The steep corneal axis was marked using a Mendez degree gauge with the patient lying on the surgical table. Phacoemulsification was performed through a 2.75-mm superior corneal incision. The target continuous curvilinear capsulorrhexis diameter was 5.5 mm to ensure overlap of the IOL border. A dispersive ophthalmic viscosurgical device (OVD) was used in all cases. After insertion of foldable toric IOL, the IOL was rotated to align the cylinder with inked reference. After complete removal of the OVD, correct alignment of the IOL was verified. Stromal hydration was used to seal the incisions. All patients were administered intracameral cefuroxime (1 mg in 0.1 mL saline) and subconjunctival dexamethasone at the end of surgery. Postoperative treatment consisted of topical dexamethasone 6 times a day tapered over 1.5 month.

Intraocular lens

All eyes received an AT TORBI™ 709 M toric foldable IOL (Carl Zeiss Meditec AG, Jena, Germany) with 25% water content. The AT TORBI™ 709 M is a single-piece hydrophobic acrylate IOL with bitoric design and square edged optic and haptic. Total diameter is 11.0 mm and optic diameter 6.0 mm. In all patients, spherical power was calculated using biometry measurements obtained with IOL Master biometer (Carl Zeiss Meditec AG, Jena, Germany) and calculated using the SRK/T formula (A-constant 118.3). The IOL is available in spherical powers ranging from -10.0 to +32.0 D in 0.5 D increments, and in cylinder powers ranging from +1.0 D to 12.0 D in 0.5

D increments. Power calculation and axis placement were performed using Z CALC™ program (available at <http://www.iolmaster-online.zeiss.com>).

Preoperative and postoperative examinations

Preoperatively, all patients underwent standard ophthalmic examination that included monocular uncorrected distance visual acuity (UDVA) and corrected distance visual acuity (CDVA) using Snellen charts, slit lamp evaluation, manifest and cycloplegic refraction, intraocular appplanation tonometry by Goldmann, and ophthalmoscopy through dilated pupils. Optical biometer (IOL Master, Carl Zeiss Meditec AG) was used to measure axial length, keratometry and anterior chamber depth.

Postoperative examinations were performed at 1 day, 1 month and 3 months. UDVA, CDVA, refraction and keratometry were recorded in all patients. IOL alignment was determined under mydriasis by slit lamp examination. Photographs of IOL alignment were taken at 1 month and 3 months with a digital camera (Canon PA 1183) (Fig. 1).

Statistical analysis

Age was expressed as median (min-max). All other variables were expressed as median and interquartile range (Q1-Q3). Differences in visual acuity and manifest refraction before and 3 months after AT TORBI 709 M IOL implantation were tested with Wilcoxon non-parametric test for paired observations. The level of significance was set at $P < 0.05$. Statistical analysis was done using MedCalc 12.1.4.0 statistical software (MedCalc Software, Mariakerke, Belgium).

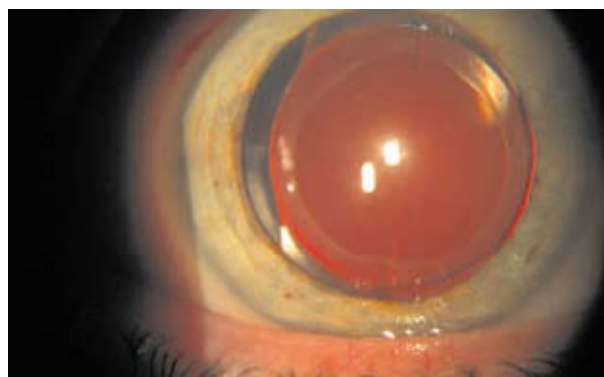


Fig. 1. AT TORBI intraocular lens 3 months postoperatively.

Table 1. Preoperative data

Characteristic	Value
Eyes (N)	10
Age (yrs)	64 (46-78)
Male/Female	3/7
Preoperative sphere (D)	-0.375 (-2.0-1.0)
Preoperative cylinder (D)	-3.0 (-3.5-2.5)
Keratometry (D)	
K1	42.7 (41.36-45.92)
K2	46.88 (44.18-49.71)
Axial length (mm)	24.03 (22.19-24.7)
Intraocular lens power (D)	
Sphere	16.0 (15.5-17.5)
Cylinder	4.0 (3.5-6.0)

Results

The study enrolled 10 eyes of 6 consecutive patients. The median age at the time of surgery was 64 (range 46-78) years. Demographic details of study patients are listed in Table 1. The median preexisting corneal astigmatism was -3.0 D interquartile range (-3.5-2.5 D) and median IOL cylinder power was 4.0 D interquartile range (3.5-6.0 D). Table 2 shows preoperative and postoperative UDVA and CDVA. At 3 months, UDVA was 0.8 or better in 9 of 10 eyes. At 3 months, 8 of 10 eyes achieved CDVA 1.0. The median reduction in refractive cylinder at 3 months postoperatively was statistically significant ($P < 0.05$). The median IOL axis rotation was 3.0 degrees interquartile range (2.0-4.0 degrees). One eye had IOL rotation 10 degrees, and 8 of 10 eyes had IOL rotation less than 5 degrees. No eye had secondary rotation of the toric IOL. There were no intraoperative or postoperative complications.

Discussion

Toric IOL implantation is a surgical option for astigmatism correction in cataract patients. To achieve the best postoperative surgical visual outcome, both astigmatism and spherical refractive errors should be addressed. Spectacle independence in patients with cataract and corneal astigmatism can be achieved with toric IOL implantation.

In our study, UDVA was 0.8 or better in 9 of 10 eyes at 3-month follow up. In a study by Mendicute *et al.*, 93.3% of patients achieved 20/40 or better UCVA using an AcrySof toric IOL¹². The mean refractive cylinder was -0.72 ± 0.43 D. Bauer *et al.* also evaluated AcrySof toric IOL implantation in 43 eyes. More than 90% of eyes achieved UDVA of 20/40 or better, and almost 80% achieved UDVA of 20/25 or better¹⁶. Residual refractive cylinder astigmatism of less than 0.75 D was achieved in 74% and less than 1.0 D in 91% of eyes. Alio *et al.* evaluated AcriComfort toric IOL implantation in 21 eyes¹⁴. Postoperative UDVA was 0.65 ± 0.22 , and 76% of eyes achieved UDVA of 20/40 or better. The mean residual refractive cylinder was -0.45 ± 0.63 D. In a study by Ruhswurm *et al.*, 67.5% of patients had UDVA of 20/40 or better after AA4203TF toric IOL (Staar Surgical Co) implantation¹⁷. Postoperatively, the mean refractive cylinder was 0.84 ± 0.63 D. Visser *et al.* recently evaluated AcrySof toric IOL implantation in 67 eyes with a mean preexisting corneal astigmatism of -4.02 ± 1.28 D. Postoperatively, the mean UDVA was 0.61 ± 0.26 . The mean residual refractive cylinder was -0.75 ± 0.49 D¹⁵.

The median residual cylinder in our study was -0.125 D interquartile range (0 to -0.5 D). Preoperatively, the median refractive cylinder was -3.0 D interquartile range (-3.5 to -2.5 D) and 3 months postoperatively the refractive cylinder decreased by 2.875 D, which was statistically significant.

Table 2. Visual acuity and manifest refraction preoperatively and 3 months postoperatively

Patient characteristic	Preoperatively	Postoperatively (3 months)	P
UDVA (D)	0.1 (0.08-0.20)	0.9 (0.8-0.9)	0.002
CDVA (D)	0.6 (0.6-0.7)	1.0 (1.0-1.0)	0.002
Refractive sphere (D)	-0.375 (-2.000-1.000)	0.0 (-0.5-0.0)	0.570
Refractive cylinder (D)	-3.0 (-3.5-(-2.5))	0.125 (0.000-0.500)	0.002

UDVA = uncorrected distance visual acuity; CDVA = corrected distance visual acuity

Rotation of the IOL after implantation is the main problem associated with toric IOL implantation. Rotation stability is crucial for toric IOL efficiency. Every degree of off axis rotation results in a loss of 3.3% of lens cylinder power, and there is complete loss of cylinder power at IOL rotation of 30 degrees¹⁸. Rotation is caused mainly by haptic compression resulting from capsular contraction. Most IOL rotation occurs in the early postoperative period^{19,20}. Once the anterior and posterior capsules fuse, IOL rotation is less frequent. This change mainly occurs in the first 3 postoperative months. IOL rotation is related to capsular bag size, capsulorrhexis size, IOL design and capsule fusion process. The model of toric IOL and its haptic design is a factor that can affect rotational stability. Shimizu *et al.*²¹ found that IOLs with C-loop haptic had the highest rate of postoperative rotation (41% >10 degrees). Plate haptic-toric IOLs have better rotational stability (2% to 50% >10 degrees). Alio *et al.* report mean IOL axis rotation of -1.65 ± 2.93 degrees (range 0 to 10 degrees)¹⁴. Patel *et al.* found that plate-haptic IOLs had a tendency to be less stable than 3-piece loop-haptic IOLs in the early postoperative period. In the late postoperative period, the plate-haptic IOLs had greater rotational stability²². Prinz *et al.* found that greatest rotation occurred within the first week postoperatively with both IOL types, whereas the loop-haptic IOL tended to rotate slightly less than the plate-haptic IOL²³. They found very good rotational stability (<3 degrees for plate-haptic IOLs and <4 degrees for loop-haptic IOLs) within 1 year postoperatively, with no significant difference between them. Chang used a plate-haptic IOL design and reports good early postoperative rotational stability of the longer (11.2 mm *vs.* 10.8 mm) toric IOL²⁴. The modified L-shaped haptic design of the AcrySof toric IOL showed good rotational stability. Mingo-Botin *et al.* report the mean toric IOL misalignment at 3 months of 3.65 ± 2.96 degrees (range 0 to 10 degrees) after AcrySof toric IOL implantation²⁵. In a study by Mendicute *et al.*, the mean toric IOL axis rotation was 3.63 ± 3.11 degrees (range 0 to 12 degrees) after AcrySof toric IOL implantation¹². Visser *et al.* report the mean IOL misalignment of 3.2 ± 2.8 degrees (range 0 to 16 degrees) with the same toric IOL model¹⁵.

The median misalignment in our study was 3.0 degrees interquartile range (2.0-4.0 degrees). Two of

ten eyes had IOL rotation of more than 5 degrees. No eye had secondary surgery for IOL repositioning. Our results are comparable with those reported by Alio *et al.*¹⁴ with plate haptic IOL and from the studies of AcrySof toric IOL. Our results show that AT TORBI is an effective surgical option to correct preexisting corneal astigmatism and spectacle dependence after cataract surgery.

References

1. HOFFER KJ. Biometry of 7500 cataractous eyes. *Am J Ophthalmol* 1980;90:360-8; correction 890.
2. GRABOW HB. Intraocular correction of refractive errors. In: KERSHNER RM, editor. *Refractive keratotomy for cataract surgery and the correction of astigmatism*. Thorofare, NJ: Slack, 1994;79-115.
3. AKURA J, KANEDA S, HATTA S, MATSUURA K. Controlling astigmatism in cataract surgery requiring relatively large self-sealing incisions. *J Cataract Refract Surg* 2000;26:1650-9.
4. WANG J, ZHANG EK, FAN WY, MA JX, ZHAO PF. The effect of micro-incision and small-incision coaxial phacoemulsification on corneal astigmatism. *Clin Exp Ophthalmol* 2009;37:664-9.
5. OZKURT Y, ERDOGAN G, GUVELI AK, ORAL Y, *et al.* Astigmatism after superonasal and superotemporal clear corneal incisions in phacoemulsification. *Int Ophthalmol* 2008;28:329-32.
6. MASNEC PAŠKVALIN S, ČIMA I, IVEKOVIĆ R, MATEJČIĆ A, NOVAK LAUŠ R, MANDIĆ Z. Comparison of preoperative and postoperative astigmatism after superotemporal or superonasal clear corneal incision in phacoemulsification. *Coll Antropol* 2007;31:199-202.
7. GANEKAL S, DORAIRAJ S, JHANJI V. Limbal relaxing incisions during phacoemulsification: 6-month results. *J Cataract Refract Surg* 2011;37:2081-2.
8. OUCHI M, KINOSHITA S. Prospective randomised trial of limbal relaxing incisions combined with microincision cataract surgery. *J Refract Surg* 2010;26:594-9.
9. CARVALHO MJ, SUZUKI SH, FREITAS LL, BRANCO BC, SCHOR P, LIMA AL. Limbal relaxing incisions to correct corneal astigmatism during phacoemulsification. *J Refract Surg* 2007;23:499-504.
10. POLL JT, WANG L, KOCH DD, WEIKERT MP. Correction of astigmatism during cataract surgery: toric intraocular lens compared to peripheral corneal relaxing incisions. *J Refract Surg* 2011;27:165-71.
11. NOROUZI H, RAHMATI-KAMEL M. Laser in situ keratomileusis for correction of induced astigmatism from cataract surgery. *J Refract Surg* 2003;19:416-24.

12. MENDICUTE J, IRIGOYEN C, RUIZ M, ARAMBERRI J, MONTES-MICO R. Foldable toric intraocular lens for astigmatism in cataract patients. *J Cataract Refract Surg* 2008;34:601-7.
13. MENDICUTE J, IRIGOYEN C, RUIZ M, ILLARRAMENDI I, FERRER BLASCO T, MONTES-MICO R. Toric intraocular lens *versus* opposite clear corneal incisions to correct astigmatism in eyes having cataract surgery. *J Cataract Refract Surg* 2009;35:451-8.
14. ALIO JL, AGDEPPA MC, PONGO VC, EI KADY B. Microincision cataract surgery with toric intraocular lens implantation for correcting moderate and high astigmatism: pilot study. *J Cataract Refract Surg* 2010;36:44-52.
15. VISSER N, RUIZ-MESA R, PASTOR F, BAUER NJ, NUIJTS RM, MONTES-MICO R. Cataract surgery with toric intraocular lens implantation in patients with high corneal astigmatism. *J Cataract Refract Surg* 2011;37:1403-10.
16. BAUER NJC, de VRIES NE, WEBERS CAB, HENDRIKSE F, NUIJTS RMMA. Astigmatism management in cataract surgery with the AcrySof toric intraocular lens. *J Cataract Refract Surg* 2008;34:1483-8.
17. RUHSWURM I, SCHOLZ U, ZEHETMAYER M, HANSELMAYER G, VASS C, SKORPIK C. Astigmatism correction with a foldable toric intraocular lens in cataract patients. *J Cataract Refract Surg* 2000;26:1022-7.
18. NOVIS C. Astigmatism and toric intraocular lenses. *Curr Opin Ophthalmol* 2000;11:47-50.
19. OHMI S. Decentration associated with asymmetric capsular shrinkage and intraocular lens size. *J Cataract Refract Surg* 1993;19:640-3.
20. STRENN K, MENAPACE R, VASS C. Capsular bag shrinkage after implantation of open-loop silicone lens and a poly(methyl methacrylate) capsule tension ring. *J Cataract Refract Surg* 1993;23:1543-7.
21. SHIMIZU K, MISAWA A, SUZUKI Y. Toric intraocular lenses: correcting astigmatism while controlling axis shift. *J Cataract Refract Surg* 1994;20:523-6.
22. PATEL CK, ORMONDE S, ROSEN PH, BRON AJ. Postoperative intraocular lens rotation; a randomized comparison of plate and loop haptic implants. *Ophthalmology* 1999;106:2190-5; discussion by APPLE DJ, 2196.
23. PRINZ A, NEUMAYER T, BUEHL W, VOCK L, MENAPACE R, FINDL O, GEORGOPOULOS M. Rotational stability and posterior capsule opacification of a plate-haptic and an open-loop-haptic intraocular lens. *J Cataract Refract Surg* 2011;37:251-7.
24. CHANG DF. Early rotational stability of the longer Staar toric intraocular lens; fifty consecutive cases. *J Cataract Refract Surg* 2003;29:935-40.
25. MINGO-BOTIN D, MUNOZ-NEGRETE FJ, WON KIM HR, MORCILO-LAIZ R, REBOLLEDA G, OBLANCA N. Comparison of toric intraocular lenses and peripheral corneal relaxing incisions to treat astigmatism during cataract surgery. *J Cataract Refract Surg* 2010;36:1700-8.

Sažetak

UGRADNJA INTRAOKULARNE LEĆE ZA KOREKCIJU ASTIGMATIZMA TIJEKOM OPERACIJE KATARAKTE

I. Petric Vicković, V. Lacmanović Lončar, Z. Mandić, R. Iveković, J. Škunca Herman i A. Sesar

Cilj rada bila je analiza poslijeoperacijskih rezultata nakon operacije katarakte kod bolesnika s prijeoperacijskim astigmatizmom i implantiranom toričnom intraokularnom lećom. Ova studija provedena je u KBC Sestre milosrdnice, a bolesnici su operirani u razdoblju od veljače do studenoga 2011. godine. Svi bolesnici uključeni u studiju imali su vizualno značajnu kataraktu i prijeoperacijski rožnični astigmatizam veći od 1,5 D. Nakon operacije katarakte učinjene metodom fakoemulzifikacije kod svih bolesnika ugrađena je savitljiva intraokularna leća AT TORBI. Tri mjeseca nakon operacijskog zahvata nekorrigirana poslijeoperacijska vidna oštrina bila je 0,8 ili bolja kod 9 očiju. Smanjenje cilindrične vrijednosti (medijan) 3 mjeseca nakon operacijskog zahvata bilo je statistički značajno ($P < 0,05$). Poslijeoperacijska rotacija intraokularne leće (medijan) iznosila je 3 stupnja, interkvartilni raspon (2 do 4 stupnja). Rezultati naše studije pokazuju da je implantacija torične intraokularne leće AT TORBI nakon operacije katarakte učinkovita kirurška metoda za korekciju prijeoperacijskog rožničnog astigmatizma.

Ključne riječi: Prijeoperacijski astigmatizam; Torična intraokularna leća; Operacija katarakte

