

Leser-Trélat Sign: Does It Really Exist?

Enver Turan¹, Yavuz Yesilova¹, Nurdan Yurt², Sezen Koçarslan³

¹Department of Dermatology, Faculty of Medicine, University of Harran, Sanliurfa; ²Dermatology Clinic, Gumushane Government Hospital, Gumushane, ³Department of Pathology, Faculty of Medicine, University of Harran, Sanliurfa, Turkey

Corresponding author:

Assist. Prof. Enver Turan, MD
Department of Dermatology
Faculty of Medicine, University of Harran
63200-Sanliurfa
Turkey
enverturan@gmail.com

Received: July 5, 2012

Accepted: February 26, 2013

SUMMARY Leser-Trélat sign is a rare cutaneous disorder that manifests with sudden emergence of seborrheic keratoses and increase in their numbers and size within weeks or months. Its concurrence with many types of malignancies, especially adenocarcinoma and lymphoma, has been reported in the literature. In this case report, a patient having Leser-Trélat sign, without any detected malignancy in spite of detailed examination and 18 months of follow up, is presented. Current literature is reviewed in relation to the debate whether Leser-Trélat is a paraneoplastic syndrome or not.

KEY WORDS: Leser-Trélat sign, seborrheic keratoses, paraneoplastic syndrome

INTRODUCTION

A great number of skin manifestations have been related to the underlying internal malignancy (1). Skin changes can often be the first sign of a serious problem. A relationship of some dermatoses with malignancy has been frequently determined and the associated dermatoses are accepted as paraneoplastic. The clinical manifestations of these dermatoses may precede, coincide with or follow the diagnosis of internal malignancy. In the current literature, many cases are presented with sudden appearance of multiple pruritic seborrheic keratoses related to the underlying internal malignancy (2-7). Although some authors have accepted that the sign of Leser-Trélat is a cutaneous marker of internal malignancies, it is still a matter of debate whether the syndrome is a paraneoplastic disorder or not (8-13). A patient with the sign of Leser-Trélat presented to our clinic, but no

internal malignancy could be determined despite detailed examination.

CASE REPORT

A 37-year-old female patient was admitted to our clinic because of serpigo on her neck that had appeared less than a month before and increased in number rapidly. Her past medical history and family history were unremarkable. On dermatological examination, 2-10 mm sized brown and slightly verrucous papules were observed on the neck and upper chest (Fig. 1). Histopathology of the lesion showed acanthosis, hyperkeratosis and papillomatosis (Fig. 2).

The patient was examined for internal malignancy. Laboratory analyses for liver and kidney function, electrolytes, protein electrophoresis, blood and urine

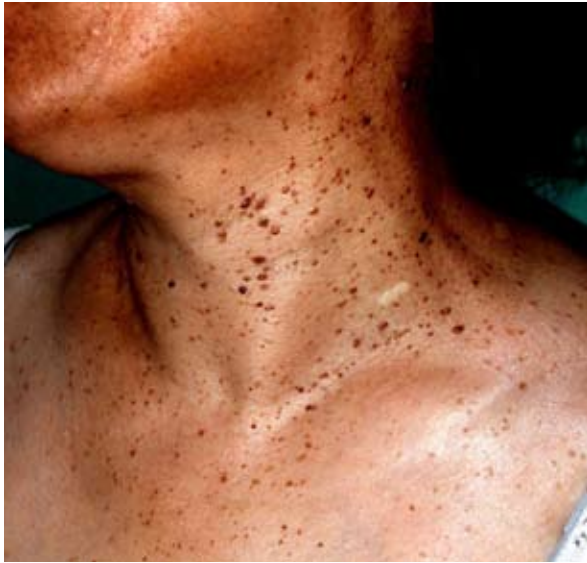

Figure 1. Multiple seborrheic keratoses on the neck scattering to the upper chest.

tests were all within the normal range. Chest x-ray and abdominal ultrasonography revealed no pathologic signs. Erythrocyte sedimentation rate was 30 mm/hour and tests for viral hepatitis, HIV and syphilis were negative. No abnormality was detected on abdominal, cranial and thorax tomography. Otolaryngological examination was normal. Esophagogastroduodenoscopy and colonoscopy were also normal. The patient was healthy and no change was observed on seborrheic keratoses during one-year follow up.

DISCUSSION

Paraneoplastic syndromes are a group of clinical manifestations that are associated with a malignancy and can progress without being related to a primary tumor or metastases. Characteristically, their progressions show parallelism with tumor progresses. Although their mechanism is not fully known, bioactive substances (such as polypeptide hormones, hormone-like peptides, antibodies or immune complexes, cytokines, or growth factors), which are released by the tumor or as a response to tumor, are considered responsible (1).

The sign of Leser-Trélat is characterized by the progression of new seborrheic keratoses in an eruptive way, or increase in their size within weeks or months. According to some researchers, this cutaneous disorder is a paraneoplastic syndrome (2). The most frequently reported malignancies associated with Leser-Trélat sign are stomach cancer, gastrointestinal adenocarcinoma and lymphoma. In the literature, leukemia, lymphoma, mycosis fungoides, Sezary syndrome, and breast, lung and prostate carcinomas and

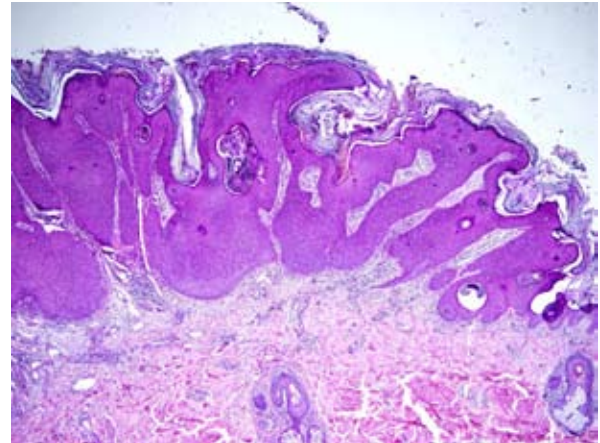


Figure 2. Marked acanthosis of predominantly basaloid cells, papillomatosis, hyperkeratosis and horn cysts (HE; x40)

sarcomas (neurofibrosarcoma) associated with Leser-Trélat sign have also been reported (14).

The sign of Leser-Trélat has been reported even in situations where no malignancy was detected, such as in heart transplant recipients, erythrodermic pityriasis rubra pilaris, and HIV infection (15-17). Leser-Trélat sign was defined separately by Edmund Leser and Ulysse Trélat and was first described together with eruptive cherry angiomas in patients having internal malignancy (14). However, Holländer was the first to show the relationship of seborrheic keratoses and cancer (18,19), but the name of Leser-Trélat was given to this sign.

The criteria for Leser-Trélat sign defined by Ronchese are rapid increase in seborrheic keratoses on lesion-free skin, pruritus and an accompanying internal malignancy (20). Heaphy *et al.* have suggested to use the term of Leser-Trélat syndrome to describe the cases with accompanying internal malignancy (21).

The pathomechanism of the sign of Leser-Trélat is unknown. The cause of the increase in size and number of seborrheic keratoses is thought to be an induction of epidermal proliferation associated with a growth factor that originates from the tumor and is swept into the circulation (22).

Schwengle *et al.* studied 36 cancer patients, many of whom had adenosarcomas, and they found that the sizes and numbers of seborrheic keratoses in the cancer patient group were not different from those in the control group (12). Grob *et al.* determined the sign of Leser-Trélat in only one patient out of 82 patients with solid organ cancers and again in only one

patient in the control group consisting of 82 patients (11). Similar findings were obtained in another study of 150 oncology patients compared with 150 healthy people (13). These researchers suggested that this sign was coincidental (11-13).

For the Leser-Trélat sign, even if the term "paraneoplastic" is used widely, we think that it is controversial because the incidence of both seborrheic keratoses and cancer is increased in old-aged population and the probability of this concurrence being coincidental is pretty high, as stated by Schwengle *et al.* (12) and Fink *et al.* (13).

Remission of paraneoplastic dermatosis should be expected after the tumor has been cured if malignancy and paraneoplastic dermatosis show parallel progression (23). A real paraneoplastic dermatosis reappears when cancer recurs or metastasizes. In the literature, this fact is not introduced clearly, and after treatment of primary cancer, recession is observed only in one-third of seborrheic keratoses (21).

A sudden increase of seborrheic keratoses is completely based on subjective evaluation of the patient, and it is hardly reliable. This sudden increase can be related with the consciousness/awareness level of the patient who had cancer diagnosis, as mentioned by Schwengle *et al.* (12). Additionally, Brauer states that there is no plausible definition of distinction between eruptive seborrheic keratosis and common seborrheic keratosis (24).

CONCLUSION

By reviewing literature data, the results of studies on the relation between Leser-Trélat sign and malignancy are inconsistent and there is no strong evidence for the presence of the sign. Almost all publications that claim coincidence of this sign with malignancy consist of case reports. Studies investigating the etiopathogenesis could not show any substance released by or in response to tumor. In our opinion, eruptive seborrheic keratoses do not require searching for an underlying internal malignancy. However, to be able to understand whether the Leser-Trélat sign really exists, the presence of malignancy should be searched in a broad case series consisting of patients with eruptive seborrheic keratoses.

References

1. Cohen PR. Paraneoplastic dermatopathology: cutaneous paraneoplastic syndromes. *Adv Dermatol* 1996;11:215-52; discussion 253.
2. Schwartz RA. Acanthosis nigricans, florid cutaneous papillomatosis and the sign of Leser-Trelat. *Cutis* 1981;28:319-22, 326-317, 330-311 *passim*.
3. Holdiness MR. On the classification of the sign of Leser-Trelat. *J Am Acad Dermatol* 1988;19:754-7.
4. Yavasoglu I, Kadikoylu G, Bolaman Z. The Leser-Trelat sign is associated with acute myeloid leukemia. *Ann Hematol* 2011;90:363.
5. Cohn MS, Classen RF. The sign of Leser-Trelat associated with adenocarcinoma of the rectum. *Cutis* 1993;51:255-7.
6. Barth JH, Dawber RP. Leser-Trelat sign associated with Sezary syndrome. *Cutis* 1986;38:42.
7. Dasanu CA, Alexandrescu DT. Bilateral Leser-Trelat sign mirroring lung adenocarcinoma with early metastases to the contralateral lung. *South Med J* 2009;102:216-8.
8. Halevy S, Feuerman EJ. The sign of Leser-Trelat. A cutaneous marker for internal malignancy. *Int J Dermatol* 1985;24:359-61.
9. Rampen HJ, Schwengle LE. The sign of Leser-Trelat: does it exist? *J Am Acad Dermatol* 1989;21:50-5.
10. Chung VQ, Moschella SL, Zembowicz A, Liu V. Clinical and pathologic findings of paraneoplastic dermatoses. *J Am Acad Dermatol* 2006;54:745-62; quiz 763-746.
11. Grob JJ, Rava MC, Gouvernet J, Fuentes P, Piana L, Gamerre M, *et al.* The relation between seborrheic keratoses and malignant solid tumours. A case-control study. *Acta Derm Venereol* 1991;71:166-9.
12. Schwengle LE, Rampen FH, Wobbes T. Seborrheic keratoses and internal malignancies. A case control study. *Clin Exp Dermatol* 1988;13:177-9.
13. Fink AM, Filz D, Krajnik G, Jurecka W, Ludwig H, Steiner A. Seborrheic keratoses in patients with internal malignancies: a case-control study with prospective accrual of patients. *J Eur Acad Dermatol Venereol* 2009;23:1316-9.
14. Schwartz RA. Sign of Leser-Trelat. *J Am Acad Dermatol* 1996;35:88-95.
15. Inamadar AC, Palit A. Eruptive seborrheic keratosis in human immunodeficiency virus infection: a coincidence or 'the sign of Leser-Trelat'? *Br J Dermatol* 2003;149:435-6.
16. Gleeson CM, Chan I, Griffiths WA, Bunker CB. Eruptive seborrheic keratoses associated with