

ILEUS FOLLOWING SPONTANEOUS JEJUNUM INTRAMURAL HEMATOMA: CASE REPORT AND REVIEW OF THE LITERATURE

Gabriele Spinelli¹, Giuseppe Damiano¹, Vincenzo Davide Palumbo^{1,2}, Antonino Sammartano², Carolina Maione¹, Antonio Marrazzo^{1,3}, Maurizio Bellavia³, Rita Barone², Giuseppe Buscemi^{1,2,3,4} and Attilio Ignazio Lo Monte^{1,3}

¹Facoltà di Medicina e Chirurgia, ²Dottorato di Ricerca in Biotecnologie Chirurgiche, ³Dipartimento DiChirOn, Università degli Studi di Palermo, Palermo; ⁴Consorzio InterUniversitario per i Trapianti d'Organo, Rome, Italy

SUMMARY – Anticoagulant therapy may cause the onset of a spontaneous intramural hematoma of the small bowel, in the jejunum, ileum or duodenum. A 53-year-old woman on therapy with heparin for previous pulmonary embolism was admitted for abdominal pain and vomit. Computed tomography scan visualized an intramural hematoma of the jejunum causing subtotal obstruction of the intestinal lumen. The patient underwent resection of a part of the jejunum, securing intestinal continuity by a mechanical side-to-side anastomosis. The postoperative course was regular, but the initial anticoagulant therapy was reduced to prevent recurrence. In conclusion, spontaneous hematoma of small bowel can occur as a complication of anticoagulant therapy. The clinical picture and rapid diagnosis indicate medical or surgical therapy.

Key words: *Spontaneous intramural hematoma; Anticoagulant therapy; Bowel obstruction*

Introduction

Spontaneous intramural small bowel hematoma is a rare event and is favored by heparin or oral anticoagulant therapy, or by genetic predisposition to bleeding. In such circumstances, spontaneously or after a trauma, blood extravasation inside the small bowel wall can occur, particularly in the jejunum, followed by ileum and duodenum.

The clinical picture can be variable, such as sub-occlusive or occlusive symptoms and signs (pain and abdominal distention, nausea and vomiting) or gastrointestinal bleeding (macroscopic, or more often

detectable by occult blood in stools and anemia). The diagnosis is supported by imaging techniques such as computed tomography (CT), which shows thickening of the intestinal wall with hyperdensity, luminal narrowing and distention of loops proximal to the obstruction¹. Few cases are reported in the literature, confirming the low frequency of this disease. We report a case of a 53-year-old patient with a massive jejunal hematoma due to heparin therapy.

Case Report

A case is reported of a 53-year-old woman who underwent left radical nephrectomy for clear cell carcinoma one month before, now on anticoagulant therapy with calcium nadroparin 5700 IUx2/day for previous pulmonary embolism. The patient was admitted to the hospital after the onset of abdominal pain and several episodes of vomiting after meals. CT scan of the abdomen was performed, which revealed jejunal

Correspondence to: *Prof. Attilio Ignazio Lo Monte*, Director of PhD Course of Surgical Biotechnology and Regenerative Medicine, Dipartimento di Discipline Chirurgiche ed Oncologiche, Università degli Studi di Palermo, Facoltà di Medicina e Chirurgia, Via del Vespro, 129, 90127 Palermo, Italy
E-mail: attilioignazio.lomonte@unipa.it

Received November 17, 2011, accepted April 25, 2012

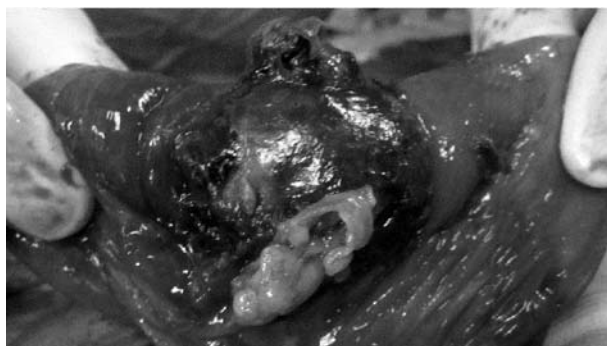


Fig. 1. Intraoperative image showing a jejunal loop obstructed by a voluminous intramural hematoma.

intraparietal neof ormation of about 5 cm in size, with signs of intestinal obstruction and overdistention of the loops proximal to it.

Laboratory tests showed a slight drop in hemoglobin, an increase in circulating reticulocytes and a modest rise in ALT and LDH, without leukocytosis. The patient was urgently admitted to the Department of General Surgery, in good general clinical condition, afebrile and eupneic; cardiopulmonary examination was negative, the abdomen appeared distended, tender to light and deep palpation, with signs of gaseous overdistention (tympany and hyperperistalsis). We proceeded with surgery. After a median xiphopubic incision and exploration of the abdominal cavity, widespread adhesions were observed that required delicate debridement of the intestinal loops. In this context, there was a jejunal loop with a voluminous

intramural hematoma of several centimeters that completely occluded the lumen, with the proximal loops visibly dilated (Fig. 1). At the pouch of Douglas, a fair amount of serous-hematic fluid was found, which was aspirated. Resection of about 10-cm loop containing the hematoma and a wedge-shaped part of the related mesentery was made (Figs. 2 and 3). Then we performed latero-lateral anisoperistaltic anastomosis using a GIA 75 stapler with a “cut and sew” mechanism. After placement of a double drain in the Douglas and intestinal anastomosis, we proceeded with interrupted suture of all layers of the abdominal wall. Histologic diagnosis confirmed the presence of a hemorrhagic area of 4.5x2.5 cm involving almost full thickness of the bowel wall, covered with extensively necrotic mucosa. Multiple clots were also detected in the segment of epiploon resected with the jejunal loop. The postoperative course was normal, except for a transient further drop in hemoglobin 24 hours after surgery (from 10.7 to 8.3 g/dL) requiring transfusion of a unit of red blood cell concentrate. Heparin therapy, already suspended at admission, was given on postoperative day 6, drastically reducing the initial dose (reviparin sodium 1750 IU/day). The patient was discharged in good clinical condition.

Discussion

Intramural bowel hematoma was observed for the first time in 1838 by McLouchlan during autopsy of a man who died of bowel obstruction.

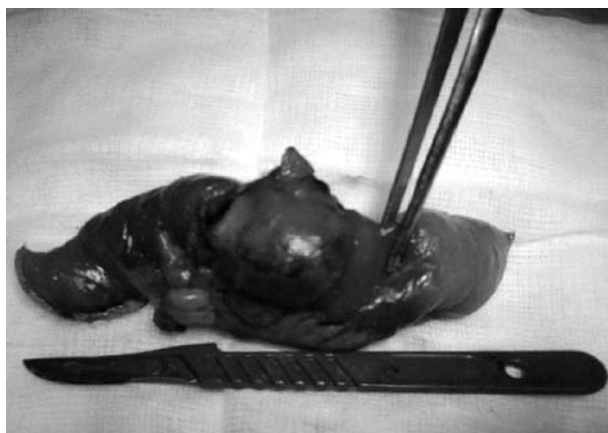

Fig. 2. Jejunal resection including the hematoma of 4.5x2.5 cm in size.

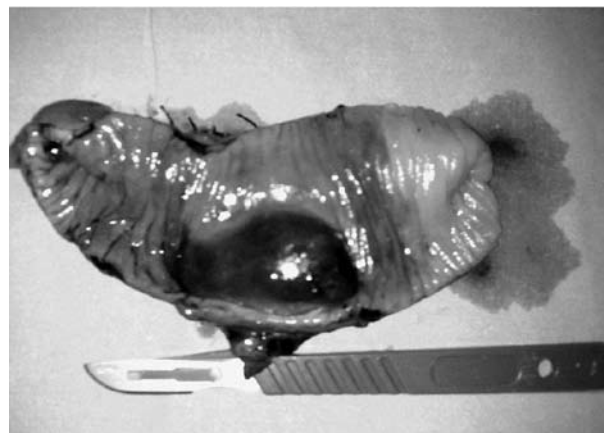


Fig. 3. Longitudinal section of the jejunal loop showing the intramural hematoma that caused bowel obstruction.

tion and dehydration; at that time, the cause of the hematoma was attributed to abdominal trauma². In fact, in the literature there are many cases of intraparietal hematoma due to a traumatic injury³⁻⁵, but in these cases the duodenum is generally involved since it is relatively fixed to the adjacent organs and can be crushed against the spine. In these cases, it is possible to find, rarely though, a visible and palpable mass in the epigastrium, mobile and soft, which can cause complete obstruction over time ranging from several hours to several days. Even duodenal biopsy during endoscopy can cause intramural effusion⁶⁻⁸. Anticoagulant therapy certainly is a risk factor for traumatic hematoma, but the most particular aspect of intramural hematoma in anticoagulated patients is its spontaneous formation without any trauma. Most authors report cases of patients treated with warfarin, with a ratio of warfarin to heparin approximately 50:1 and the incidence of hematoma in these patients estimated at 1:2500. The sections of bowel most often affected are jejunum and ileum, but also the large intestine may be involved, although in these cases traumatic insults were described as triggering events, and a lesion of the small intestine is always associated. In all cases, it seems that the common pathogenetic factor is the injury of end arteries at the point where they leave the mesentery to penetrate the muscle layer, with consequent bleeding inside the wall⁹⁻¹². About the diagnosis, until the 1980s, barium x-ray imaging was the method of choice for the evaluation of this condition. Instead, CT with intravenous contrast is currently the gold standard, thus eliminating oral barium because of the possible presence of intestinal perforation. However, an investigation without contrast is often preferred due to the critical condition of patients. The images show thickening of the intestinal wall with hyperdensity during the first ten days; later, an area of hypodensity is visualized, mimicking an intramural cystic lesion; in a few weeks, there is complete resolution of the hematoma with restitution *ad integrum*. If CT scan is not available, many authors use ultrasound as a rapid method to identify the hematoma and any peritoneal or retroperitoneal effusion^{5,9,11}. The crucial point in the management of this disease is the choice between conservative treatment and surgical approach. It is widely accepted that in the absence of complications the patient can be treated

with medical therapy alone (suspension of the anti-coagulant, administration of vitamin K, fresh frozen plasma, proton pump inhibitors, correction of electrolyte imbalances, nasogastric tube, total parenteral nutrition), with marked improvement in symptoms within 4-6 days. We also want to emphasize the cautious use of vitamin K because it may precipitate the hypercoagulable state, as a rebound effect, which would lead to thrombotic diathesis^{5,9,11,13-15}. The complications that require surgical approach include bowel obstruction, ischemia, necrosis, perforation, peritonitis, hemoperitoneum, retroperitoneal hemorrhage (duodenum), rarely jejuno-jejunal or colocolic intussusceptions, and protein losing enteropathy^{2,11,12}.

The surgical treatments include several techniques, depending on the specific case and the experience of the surgeon. It is possible to do simple incision and evacuation of the hematoma if the conditions of the organ permit; in some cases of wide duodenal damage, it is possible to bypass it through gastrojejunostomy; when the hematoma is localized, as in our patient, resection of a part of the bowel may be necessary, followed by intestinal anastomosis; in a few cases, in the duodenum, endoscopic treatment can be used employing an electrical needle knife to puncture and incise the hematoma¹³. Besides, a laparoscopic approach is also possible to drain the hematoma¹⁶. In our case, it was not possible to manage the patient with a conservative and "wait and see" approach because the initial clinical picture was intestinal obstruction. However, many authors report a range of signs and symptoms that may indicate the early onset of the hematoma. In the order of frequency these are abdominal pain, nausea, vomiting, intestinal bleeding (melena, hematemesis, hematochezia), fever and anorexia. In case of recto-sigmoid localization, there also are tenesmus and soft and palpable mass on anorectal exploration. Moreover, for the coagulation deficit, it is possible to observe concomitant hemorrhagic manifestations in other areas, such as epistaxis, hematuria, ecchymosis of the face and upper limbs, and conjunctival bleeding^{2,5,10,11}. Finally we must remember that, despite anticoagulants are the main responsible factors for a hemorrhagic state, there are several other conditions in which patients are constantly exposed to the risk of

intramural hematoma and other hemorrhagic manifestations, e.g., hepatic failure, hemophilia, thrombotic thrombocytopenic purpura, leukemia, lymphoma, myeloma, chemotherapy, vasculitis, pancreatitis, and pancreatic cancer. In all these conditions, or if anticoagulant therapy is not suspended, hematomas can be multiple or recurring^{5,11}.

Conclusions

We report a case of a woman receiving heparin in massive doses for pulmonary embolism, which caused the onset of a spontaneous intramural hematoma of the jejunum with a clinical picture of intestinal obstruction. Few cases have been reported in the world, and among all patients on anticoagulant treatment only 2% were treated with heparin¹⁰. The suspicion of intramural hematoma should always arise when we are dealing with rectal bleeding or intestinal obstruction in a patient treated with anticoagulants⁹. The diagnosis is made by imaging techniques such as CT scan, supported by laboratory and clinical findings. Still debated is the initial therapeutic approach, for it may be medical, surgical, or sometimes endoscopic¹³. Accordingly, our final consideration is that, in the evaluation of patients receiving anticoagulants, the fine balance between the benefits and risks of this therapy must always be respected using, wherever possible, the minimum dose required for antithrombotic purpose, thus avoiding exposure to hemorrhagic complications that are often difficult to manage.

References

- HUGHES CE 3rd, CONN J Jr, SHERMAN JO. Intramural hematoma of the gastrointestinal tract. *Am J Surg* 1977; 133(3): 276-9.
- SORBELLO MP, UTIYAMA EM, PARREIRA JG, BIRROLINI D, RASSLAN S. Spontaneous intramural small bowel hematoma induced by anticoagulant therapy: review and case report. *Clinics* 2007;62:785-90.
- INOUE MR, WATANABE LM. Duodenal obstruction due to intramural hematoma: review of the literature and report of a case. *Calif Med* 1956;85:254-6.
- JONES WR, HARDIN WJ, DAVIS JT, HARDY JD. Intramural hematoma of the duodenum: a review of the literature and case report. *Ann Surg* 1971;173:534-44.
- ASKEY JM. Small bowel obstruction due to intramural hematoma during anticoagulant therapy, a non-surgical condition. *Calif Med* 1966;104:449-53.
- DAVIS DR, THOMAS CY. Intramural hematoma of the duodenum and jejunum: a cause of high intestinal obstruction – report of three cases due to trauma. *Ann Surg* 1961;153:394-8.
- SIMI S, ANOOP TM, GEORGE KC. Spontaneous intramural duodenal hematoma – a rare cause of upper gastrointestinal obstruction. *Am J Emerg Med* 2010;28:642.e1-2.
- CHANG CW, CHEN MJ, SHIH SC, WANG HY, TSAI CH, WANG TE, CHANG WH. Clinical images. Delayed duodenal intramural hematoma with obstruction. *Am J Surg* 2010;199:e77-8.
- POLAT C, DERVISOGLU A, GUVEN H, KAYA E, MALAZGIRT Z, DANACI M, OZKAN K. Anticoagulant-induced intramural intestinal hematoma. *Am J Emerg Med* 2003;21:208-11.
- BATTAL B, KOCAOGLU M, ORS F, AKGUN V, TASAR M. Obstructive rectal intramural hematoma caused by a foreign body. *Emerg Radiol* 2009;16:75-7.
- ABBAS MA, COLLINS JM, OLDEN KW. Spontaneous intramural small-bowel hematoma: imaging findings and outcome. *AJR Am J Roentgenol* 2002;179:1389-94.
- JARRY J, BISCAY D, LEPRONT D, RULLIER A, MIDY D. Spontaneous intramural haematoma of the sigmoid colon causing acute intestinal obstruction in a haemophiliac: report of a case. *Haemophilia* 2008;14:383-4.
- KWON CI, KO KH, KIM HY, HONG SP, HWANG SG, PARK PW, RIM KS. Bowel obstruction caused by an intramural duodenal hematoma: a case report of endoscopic incision and drainage. *J Korean Med Sci* 2009;24:179-83.
- ABBAS MA, COLLINS JM, OLDEN KW, KELLY KA. Spontaneous intramural small-bowel hematoma: clinical presentation and long-term outcome. *Arch Surg* 2002;137:306-10.
- HALE JE. Intramural intestinal haemorrhage: a complication of anticoagulant therapy. *Postgrad Med J* 1975;51(592):107-10.
- MAEMURA T, YAMAGUCHI Y, YUKIOKA T, MATSUDA H, SHIMAZAKI S. Laparoscopic drainage of an intramural duodenal hematoma. *J Gastroenterol* 1999;34:119-22.

Sažetak

ILEUS NAKON SPONTANOG INTRAMURALNOG HEMATOMA JEJUNUMA: PRIKAZ SLUČAJA
I PREGLED LITERATURE

G. Spinelli, G. Damiano, V.D. Palumbo, A. Sammartano, C. Maione, A. Marrazzo, M. Bellavia, R. Barone, G. Buscemi
i A.I. Lo Monte

Antikoagulantna terapija može uzrokovati spontanu pojavu intraparijetalnog hematoma tankog crijeva na razini jejunuma, ileuma ili duodenuma. Prikazuje se klinički slučaj 53-godišnje žene na terapiji heparinom zbog ranije plućne embolije, koja je zadržana na bolničkom liječenju zbog bolova u trbuhu i mučnine. Tomografija abdomena potvrdila je prisutnost intraparijetalnog hematoma jejunuma koji je uzrokovao gotovo potpuno zakrčenje crijevnog lumena. Izvedena je resekcija zahvaćenog dijela jejunuma i rekonstrukcija crijevnog nastavka posredstvom "mehaničke latero-lateralne anastomoze". Poslijeoperacijski tijek je bio uredan, ali je smanjena početna antikoagulantna terapija kako bi se izbjegao recidiv bolesti. U zaključku, spontani intraparijetalni hematom tankog crijeva može biti rezultat komplikacija antikoagulantne terapije. Klinička slika i brzo postavljanje dijagnoze upućuju na medicinsku ili kiruršku terapiju.

Ključne riječi: *Spontani intraparijetalni hematom; Antikoagulantna terapija; Crijevna okluzija*

