

DIFFICULT AIRWAY IN ADVANCED BECHTEREW'S DISEASE: CASE REPORT

Zdenko Novotny, Aleksandra Gvozdenović and Branka Maldini

Department of Anesthesiology, Resuscitation and Intensive Medicine, Sestre milosrdnice University Hospital Center, Zagreb, Croatia

SUMMARY – Advanced Bechterew's disease presents with increasing ossification of spinal column, from lower lumbar segments upwards, first causing impossibility to place spinal block in lumbar region, and later, due to stiffness of cervical spine, difficult intubation because of inability to extend and/or flex the neck during direct laryngoscopy and intubation. Mask ventilation, on the other hand, usually is possible. We report a case of a 77-year-old man scheduled for elective hernioplasty, with recently advanced Bechterew's disease. According to the recently accepted Mainz algorithm, we first intended to perform awake intubation through the nose by fiber bronchoscope. The bronchoscope passed easily down to tracheal bifurcation, but placing the endotracheal tube was unexpectedly impossible due to the consequences of broken nose the patient had suffered at the age of 8. Fiber bronchoscope was therefore retracted, and we used the Bonfils rigid fiberscope after induction of general anesthesia, achieving intubation in first attempt.

Key words: *Spondylitis, ankylosing; Intubation, intratracheal; Bronchoscopy; Bonfils rigid fiber bronchoscope; Fiberoptic intubation*

Introduction

Bechterew's disease (ankylosing spondylitis) is a progressive inflammatory disease associated with certain alleles of HLA-B27 antigen. Pathological process first causes inflammation of the ligaments and joints around the spine, then formation of syndesmophytes, and finally fusion of vertebral bodies occurs. At that point, spinal anesthesia becomes impossible, and persistent multiple attempts to introduce the spinal needle into subdural space are connected with a significant risk of producing spinal-epidural hematoma, and cervical spine becomes fixed making extension of the neck impossible, most often in a flexed position, which makes direct laryngoscopy very difficult; due to poor

visualization, placing the endotracheal tube is also difficult. Additionally, affected temporomandibular joints with limited mouth opening are present in 10% of early cases and up to 40% of fully developed disease cases¹, thus decreasing the interincisor gap and possibility of mandibular protrusion. Even cricoarytenoid arthritis² has been described. Due to osteoporosis that follows complete stiffness of the spine, there may be fractures of cervical spine, especially at C5-6 after little or no trauma; one should not try to extend the neck during intubation when it is not possible. There is significant atlantoaxial subluxation in 20% of cases. When such a patient presents for anesthesia, it is of utmost importance to find out how long he/she has been diagnosed with ankylosing spondylitis because in the first stage, they can be both normally intubated and easily given spinal anesthesia. If the patient is in the final stage of disease, the protocol for the expected difficult airway should be followed, which means awake flexible fiberoptic intubation.

Correspondence to: Zdenko Novotny, MD, Department of Anesthesiology, Resuscitation and Intensive Medicine, Sestre milosrdnice University Hospital Center, Vinogradska c. 29, HR-10000 Zagreb, Croatia

E-mail: zdenko.novotny@kbcsm.hr

Received May 30, 2012, accepted August 23, 2012

Case Report

A 77-year-old man with a known history of ankylosing spondylitis was scheduled for left inguinal hernia repair. Speaking with the anesthesiologist the day before operation, he admitted that the disease had progressed considerably during the last 5 years. He also mentioned the broken nose at the age of 8, but denied any problems breathing through either of the nostrils. On examination, his actual body weight was 75 kg, height 178 cm, yielding body mass index of 23.67; Mallampati score was 2, neck circumference was 41 cm, interincisor gap (distance between upper and lower incisor teeth) was 3.4 cm, and when asked to perform upper lip bite test, grade 3 was recorded, i.e. he was unable to place lower teeth in the same plane with upper teeth. In sitting position, maximal extension of cervical spine was measured as 25 degrees (Fig. 1), while maximal flexion was only 15 degrees (Fig. 2). Although not completely fixed, the ability of the neck to flex or extend was thought to be rather small, so we proceeded with the algorithm for the expected difficult intubation. Although there have been reports of various techniques such as intubating laryngeal mask with Cook exchanger³ and GlideScope videolaryngoscope⁴, we nevertheless decided to stick to the golden standard of flexible fiberoptic awake intubation.

The patient was premedicated with atropine 0.5 mg and midazolam 5 mg i.m. On arrival to the operating theater, the i.v. cannula was placed in a peripheral vein and 1 mL of 2% lidocaine and 1 mL of

0.25% ephedrine was administered into the left nostril for anesthesia and decongestion of nasal mucosa. Pre-oxygenation with 100% oxygen was started. Then the patient was instructed to gargle the solution sprayed into his mouth, which was 60 mg lidocaine in spray. After that, the nasal dose was repeated. Bronchoscopic procedure started in normal way. The nostril was easily passed through, arriving into the pharynx and further to just outside the larynx, which was then sprayed twice with 5 mL of 2% lidocaine to achieve laryngeal and tracheal anesthesia. After 2 minutes waiting for the anesthetic to take effect, the bronchoscope tip passed easily through the vocal cords into the trachea and down to tracheal bifurcation. However, when we tried to pass the tube, it could not pass the nostril, which proved to be too narrow due to previous nose fracture. At this point, since the patient was not in any way endangered because he was breathing spontaneously, and mask ventilation seemed easy because of good fit during pre-oxygenation, we decided to induce anesthesia by propofol and rocuronium, and as now it was unexpected difficult airway, to change to Bonfils rigid fiber bronchoscope. After some suction to clear the mouth from saliva and some blood, the intubation *via* Bonfils succeeded in the first attempt.

Discussion

Advanced cases of Bechterew's disease are not rare at our hospital, and some have been very hard to intubate. The problem can be really hard when the opera-

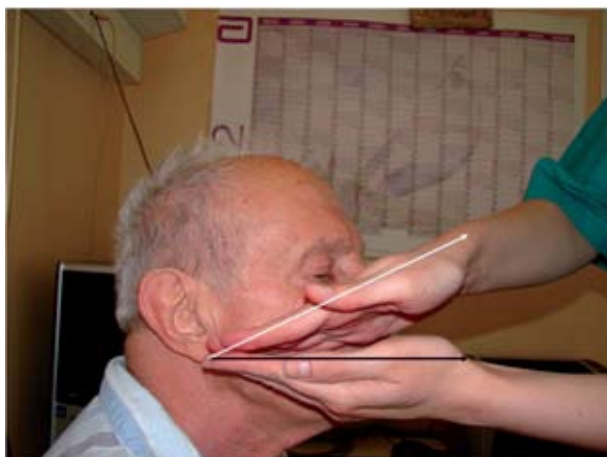


Fig. 1. Extension of the neck.

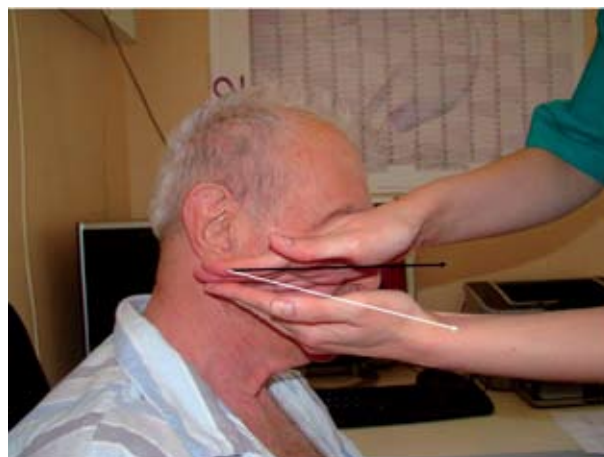

Fig. 2. Flexion of the neck.

tion is urgent and the patient vomits due to high intestinal obstruction. This patient was elective, though, and we had all the time in the world. Recently, with acquisition of the new apparatus, e.g., C-MAC videolaryngoscope, Bonfils rigid fiberscope and flexible fiber bronchoscope, we also accepted the Mainz algorithm⁵ for dealing with difficult airway. This algorithm requires flexible fiberoptic intubation on awake patient for expected difficult airway and Bonfils for unexpected difficult airway. After performing numerous fiber bronchoscopic intubations on awake patients successfully, we were sure we could pass the tube once the bronchoscope was in place; this, however, proved impossible due to the narrow nostril, probably consequential to the broken nose in childhood. The choice at that moment was to anesthetize the other nostril and try there, or try through the mouth, which was presumably enough anesthetized already by gargling, or turn to other choices like Bonfils, which we believe was the right one in this case. If the patient was with full stomach or intestinal obstruction, it would be right to try the other nostril, keeping the patient awake, this time with a smaller endotracheal tube. But, since there was no danger of aspiration, it was obvious that general anesthesia would not put the patient into greater risk. We did not try awake intubation with Bonfils because it is not yet established procedure at our hospital, and besides, our Bonfils is without a working channel through which it would be possible to administer additional local anesthetic.

To avoid this kind of problems, there is the possibility to use a set of nasal airways, lubricated with local anesthetic gel, passing one after another from

smallest toward wider, and thus either to widen the nostril enough to pass the endotracheal tube, or to know in advance that such passing is impossible and go for the other nostril or another option instead.

Conclusion

Awake nasal flexible fiberoptic intubation is a safe solution for expected difficult airway. Even when it unexpectedly failed, there was no danger to the patient. Bonfils rigid fiberscope is very useful in unexpected difficult airway. Widening the nostril by progressively bigger and wider nasal airways lubricated with local anesthetic gel might provide additional benefit of knowing in advance whether the nostril will be large enough for endotracheal tube.

References

1. WOODWARD LJ, KAM PCA. Ankylosing spondylitis: recent developments and anaesthetic implications. *Anaesthesia* 2009;64:540-8.
2. LIBBY DM, SCHLEY WS, SMITH JP. Cricoarytenoid arthritis in ankylosing spondylitis. *Chest* 1981;80:641-2.
3. HSIN ST, CHEN CH, JUAN CH, TSENG KW, OH CH, TSOU MY, *et al.* A modified method for intubation of a patient with ankylosing spondylitis using intubating laryngeal mask airway (LMA-Fastrach) – a case report. *Acta Anaesthesiol Sin* 2001;39:179-82.
4. LAI HY, CHEN IH, CHEN A, HWANG FY, LEE Y. The use of the GlideScope for tracheal intubation in patients with ankylosing spondylitis. *Br J Anaesth* 2006;97:419-22.
5. PIEPHO T, NOPPENS R. The Bonfils intubation endoscope in clinical and emergency medicine. Tuttingen, Germany: EndoPress, 2010.

Sažetak

OTEŽANI DIŠNI PUT KOD UZNAPREDOVALE BEHTEREVLJEVE BOLESTI: PRIKAZ SLUČAJA

Z. Novotny, A. Gvozdenović i B. Maldini

Značajke uznapredovale Behterevljeve bolesti (ankilozirajući spondilitis) su sve veća osifikacija kralježnice od donjih, lumbalnih dijelova prema višim, cervikalnim što uzrokuje prvo nemogućnost izvođenja spinalnog bloka u lumbalnoj regiji, a kasnije, zbog ukočenosti vratnog dijela kralježnice, otežanu intubaciju zbog nemogućnosti ekstenzije i/ili fleksije vrata u tijeku direktne laringoskopije i intubacije. S druge strane, ventilacija na masku je obično izvediva. Ovdje prikazujemo 77-godišnjeg bolesnika koji je bio predviđen za elektivnu operaciju ingvinalne hernije, a čiji je ankilozirajući spondilitis u posljednje vrijeme jako uznapredovao. U skladu s nedavno prihvaćenim "Mainz algoritmom" najprije smo pokušali intubirati fleksibilnim fiberbronhoskopom na budnom bolesniku. Bronhoskop je lako prošao sve do bifurkacije traheje, ali je neočekivano postavljanje endotrahealnog tubusa zapelo na preuskoj nosnici zbog prijeloma nosa koji je bolesnik zadobio u dobi od 8 godina. Zato smo izvukli fiberbronhoskop i nakon indukcije opće anestezije uspjeli intubirati u prvom pokušaju rigidnim fiberskopom po Bonfilsu.

Ključne riječi: *Ankilozirajući spondilitis; Endotrahealna intubacija; Bronhoskopija; Rigidni fiberbronhoskop po Bonfilsu; Fiberoptička intubacija*