

DIFFICULT AIRWAY AND ONE LUNG VENTILATION

Mojca Drnovšek Globokar and Vesna Novak-Jankovič

Clinical Department of Anesthesiology and Intensive Therapy, University Medical Centre Ljubljana, Ljubljana, Slovenia

SUMMARY – The number of indications for lung collapse during different procedures is rising. Difficult upper airway is more often encountered with the need for single lung ventilation. In patients with difficult airway, the safest approach is by placing a single-lumen endotracheal tube with the aid of a flexible fiberoptic bronchoscope. Lung isolation in these patients is then achieved by means of a bronchial blocker. An alternative technique is exchanging the single-lumen for a double-lumen tube using an airway exchange catheter. When there is a tracheostomy in place, an independent bronchial blocker is recommended.

Key words: *Difficult airway; One lung ventilation; Double lumen tube; Endobronchial blocker; Airway exchange catheter*

Introduction

Many different operations (lung and esophageal resection, heart and thoracic spine surgery), open thoracotomy and “closed” thoracoscopic procedures, make the anesthesiologist face with the main concern of good lung isolation technique¹⁻³.

Widening indications for one lung ventilation (OLV) lead to a higher incidence of difficult airway with coincident request for lung separation. It is estimated that between 5% and 8% of patients with primary lung carcinoma also have a carcinoma of the pharynx, usually in the epiglottic area².

At the moment of lung isolation in the patient with difficult airway, many different issues are to be discussed:

1. Is lung isolation strictly recommended (absolute indication)?

2. What lung isolation technique to use?
3. Which laryngoscopic device could facilitate best the double/single lumen tube insertion?

Absolute Indications for Lung Isolation

There are few absolute indications for OLV⁴:

1. protecting the healthy lung from contamination with massive hemorrhage (blood), infection (pus) and lung lavage (water),
2. prevention of wasting ventilation (bronchopleural fistula),
3. protective ventilation (avoiding excessive pressure and rupture of the lung or unilateral cyst), and
4. video assisted thoracoscopic (VATS) procedures.

Other indications for OLV are relative and part of better surgical field exposure. Patient safety and need for lung ventilation should be discussed in a difficult airway situation (Fig. 1).

Lung Isolation Techniques

One lung ventilation is usually achieved with:

- double lumen tube (DLT)
- bronchial blocker (BB).

Correspondence to: *Prof. Vesna Novak-Jankovič, MD, PhD*, Clinical Department of Anesthesiology and Intensive Therapy, University Medical Centre Ljubljana, Zaloška 7, 1000 Ljubljana, Slovenia

E-mail: vnovakjankovic@gmail.com

Received June 23, 2012, accepted August 23, 2012

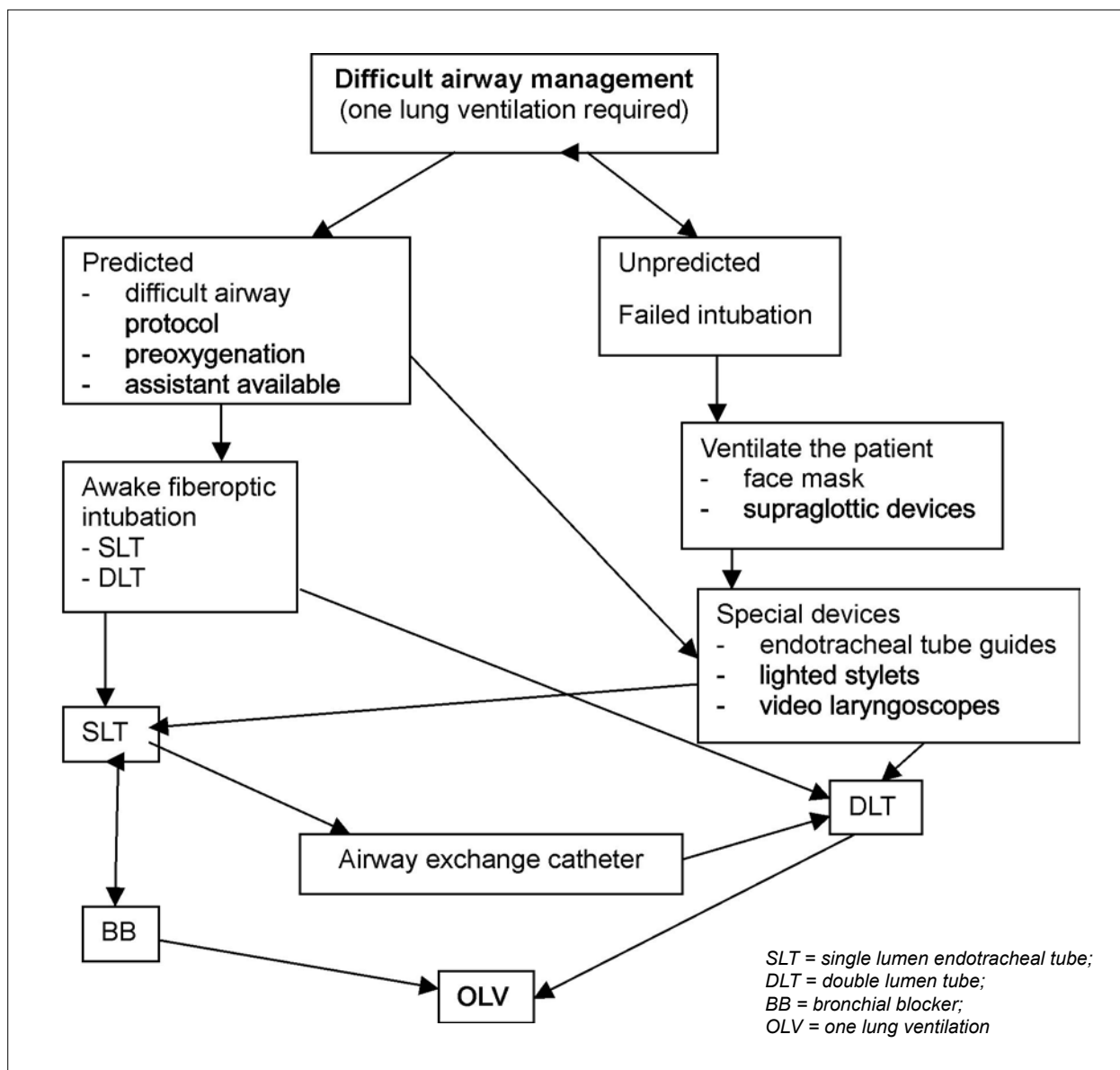


Fig. 1. Algorithm for difficult airway management when one lung ventilation is required.

In patients with normal upper airway, the choice between the listed options for lung isolation is part of personal skill and the reason for lung isolation. However, in difficult airway, one technique (BB) can be better than another one (DLT)⁵ (Fig. 2).

For anesthesiologists with limited experience in thoracic anesthesia cases, none of the devices has been shown to provide any advantage while in use due to a high incidence of unrecognized malpositions. DLT can be positioned without bronchoscopy, although

malposition occurs in more than 35% of blind intubations⁶.

For successful DLT intubation, upper airway evaluation is of great vitality. Intubation with DLT can be more difficult than intubation with a single lumen endotracheal tube (SLT). DLT has larger diameter compared with SLT, special shape and lack of bevel in the tip. Placing DLT, even in the grade II Cormack-Lehane direct laryngeal view, might be challenging for the anesthesiologist. When tracheal intubation

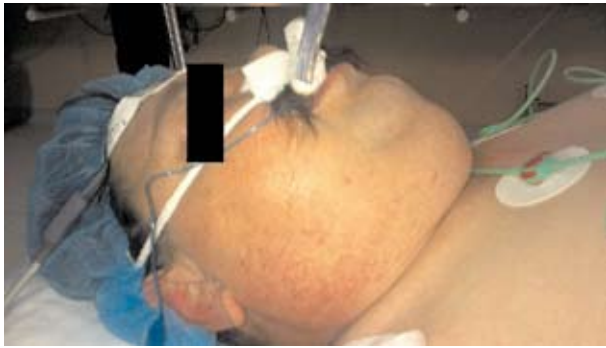

Fig. 2. A single lumen tube with bronchial blocker placed in an extremely obese patient requiring one lung ventilation.

has already been successfully performed, lung separation can still be a problem.

Since it is impossible to prioritize one technique as best without knowing their specialties, each of them will be considered separately.

Double Lumen Tube

Only DLT provides reliable protection of healthy lung from blood and pus. With DLT collapsed, the lung can be easily deflated and reinflated (Fig. 3).

Continuous positive airway pressure (CPAP) could be easily applied to the non ventilated lung. Both lungs are prone to bronchoscopy through both lumens of DLT. DLT is positioned more rapidly and has fewer instances of dislodgement than BB.

Left and right DLT are available. We should be aware of the anatomic airway asymmetry inside the tracheobronchial tree. For most thoracic procedures



Fig. 3. Mallinckrodt double lumen tube, left sided, with carinal hook.

(left or right), a left DLT is preferable, since it has a great margin of safety¹. Indications for a right DLT are limited to specific case needs^{1,7}.

One of the difficulties is proper size of DLT to select. Smaller DLT moves easily inside the airway. The largest DLT, which the endobronchial lumen enters the intended bronchus without any resistance, should be used (less prone to malposition, less airflow resistance, easy suction)^{1,8}.

The most accurate method to select a left DLT is to measure the left bronchus width (LBW) from the anterior-posterior chest radiograph. But, the left bronchus can only be seen in 50% of chest radiographs¹. Gender, height and weight have limited correlation in predicting DLT size, especially in adult patients with short stature (under 170 cm). Selecting an undersized or oversized DLT has led to serious airway complications.

Depth of DLT insertion is another issue to discuss, since inadvertent deep insertion could cause serious complications (rupture of the left main stem bronchus). On the other hand, too shallow position could be a reason for ventilation problems.

There is a limitation in DLT for pediatric population under 6.0 mm ID diameter of conventional tracheal tube or 26 Fr of smallest DLT. BB remains the technique of choice in pediatric population.

Carlens (Robertshaw) designed double D-shaped lumen tubes in 1950. The currently disposable DLTs (Portex, Mallinckrodt, Sheridan) have low pressure, high volume cuffs, reducing exaggerated ischemic pressure to the airway. Clear material allows observation of secretions in either lumen and adequate aspiration of both lungs.

It has become obvious that an alternative to the DLT is needed for the following reasons: DLTs are non-friendly and, being bulky, are often difficult to insert and position. The use of DLTs is associated with the need to change the tube to a single tube if the patient requires postoperative ventilatory support. A patient airway that is considered easy for insertion of SLT may represent a challenge for DLT insertion.

Bronchial Blockade

Lung tissue distal to the blockade will collapse. Different concepts of bronchial blockade are available (Arndt wire guided, Univent torque control blocker,



Fig. 4. Coopdech endobronchial blocker tube with multi-port adapter.

Cohen flexitip blocker). Bronchial blockers (BB) have the same disadvantages compared with DLT in the lung separation approach. Nevertheless, they are indispensable in specific clinical situations (Fig. 4).

BB use is recommended for one lung ventilation when tracheal tube is already in place (oral, nasal), in tracheostomy, in pediatric thoracic anesthesia, and in cases of difficult intubation¹.

BB also allows for selective lobar blockade.

BB can be used intraluminally or alongside tracheal tube or tracheostomy. BB could be used intraluminally in 7.0 mm ID tube at least (manufacturer recommends 8.0 mm ID). Endotracheal tube should stop at least 2 cm above the tracheal carina, to allow for BB manipulation. The outer, fully inflated blue edge balloon should be positioned at least 10 mm below the carina to facilitate lung isolation. The surgeon must consider the presence of BB in the main stem bronchus to avoid inadvertent simultaneous BB resection with stapler.

Bronchoscopy of the blocked lungs is impossible during operation.

Arndt-Endobronchial Blocker (Cook Critical Care, Bloomington, IN, USA, 1999) of three different sizes (9, 7, 5 (pediatric) Fr and 65 or 78 cm long) has a flexible wire in the lumen, which creates a wire loop at the distal end for coupling with the bronchoscope. After positioning of the Arndt BB, wire loop is withdrawn into the catheter and the balloon is inflated.

BBs require longer time for placement. The overall time for lung collapse is prolonged using BB, lung collapse could be inadequate and assisted suction is required (1-2 mm suction channel of BB *versus* 4.3 mm in 35 Fr tube)⁹. More frequent dislodgement of

the BB occurs and fiber bronchoscopy is the only way to choose.

Cohen Flexitip Endobronchial Blocker is 65 cm long and comprises a 3-cm soft nylon tip. The soft, flexible tip can be deflected more than 90 degrees achieved by a counter clockwise rotation of the wheel positioned at the proximal end of the blocker.

Arndt, like Cohen BB needs Arndt Multi-Port Adaptor (Cook Critical Care, Bloomington, IN, USA) for insertion through a conventional single lumen endotracheal tube that permits simultaneous ventilation, fiberoptic bronchoscopy, and manipulation of the BB with an airtight seal.

Torque Control Blocker (TCB) Univent Inoue Tube (Fuji System Corp., Tokyo, Japan) consists of a single lumen tube, enclosed flexible bronchial blocker with soft tip, and high torque control for smooth endobronchial position. Suction channel is 2 mm wide, allowing time for lung deflation comparable to DLT, with less need for assisted suction. Different sizes from 6.0 to 9.0 ID are available, although external diameter is wider than conventional endotracheal tube because of elliptic shape and added blocker.

Fogarty Embolectomy Catheter (Edwards Lifesciences, Irvine, CA, USA) as a BB should be used except for emergency situations (airway bleeding). Their balloon exerts very high pressure with potential harm to the bronchial wall. Fogarty catheters also lack a directing mechanism or suction lumen^{1,10}.

Evidence strongly suggests that auscultation alone is unreliable for confirmation of proper DLT or BB placement. Position of the DLT and BB should be confirmed with fiberoptic bronchoscopy in supine and lateral position of the patient.

Airway Management Devices

When direct laryngoscopy with Macintosh blade becomes a problem, switching to video laryngoscopy may prove helpful.

Airtraq DL

Airtraq DL is accustomed for DLT intubation (Fig. 5).

Generally, all sizes of DLT, from 35, 37, 39 to 41 French, could be used, left- or right-sided, hooked or without hook. Minimal mouth opening of 19 mm is recommended. Airtraq DL has a wider guiding chan-



Fig. 5. Airtraq DL laryngoscope.

nel compared with conventional Airtraq, with some modifications of its tip and yellow indication mark.

Airtraq DL appears to be an alternative approach to fiberoptic intubation with DLT in difficult airway cases with normal mouth opening.

Other known video laryngoscopes (GlideScope, C-Mac Karl-Storz, Wu-scope, Bullard laryngoscope, McGrath, Pentax Airway Scope) are designed to facilitate tracheal intubation without alignment of the oral, pharyngeal and tracheal axes. In DLT intubation fear from tracheobronchial trauma exists, when DLT is advancing without direct optical supervision. Wide and clear glottic view is vital for atraumatic DLT placement. Video laryngoscopes could be of great value, where poor laryngeal view limits DLT insertion. Each video-laryngeal technique requires some practice to become familiar to the anesthesiologist.

Video laryngoscopes have place in already anesthetized patients with failed direct laryngoscopy and good face mask ventilation. Insisting upon DLT intubation is part of debate. Before hypoxemia, bleeding or edema appears, change to SLT should be done. In already paralyzed patient with unrecognized difficult airway access, our efforts are oriented to establish some form of airway patency (SLT, LMA, ProSeal, FastTrach).

Airway Exchange Catheter

Single lumen tube can then be replaced with DLT using an airway exchange catheter (Fig. 6).

The commercially available exchange catheters are designed specifically for this purpose, with adequate length (at least 83 cm long), size (11-14 Fr), and soft-tip. Direct laryngoscopy or video laryngoscopy is



Fig. 6. Double lumen tube exchange catheter, Cook Critical Care.

advised during the tube exchange maneuver to avoid patient trauma or tube damage. Do not perform tube exchange in un-anesthetized patient¹. For a tube exchange catheter to function, it must have a hollow center channel and universal adapters to insufflate oxygen. The airway Aintree tube exchanger (Cook Critical Care) has a large internal diameter that allows fiberoptic bronchoscopy guidance. Frova from Cook is a promising catheter for DLT insertion. A 14Fr exchange catheter can be used to facilitate insertion of 39 and 41 Fr DLTs. For a 35 or 37F DLT, a single or double airway exchange catheter can be used.

Fiber Bronchoscope and Awaked Intubation

In cases of poor mouth opening and difficult mask ventilation prediction, the alternative is to intubate the patient's trachea with a single-lumen endotracheal tube during awaked fiberoptic bronchoscopy. Once the airway is established (oral or transnasal), independent BB can be advanced. An alternative is the use of a laryngeal mask in conjunction with an independent BB or performing laryngeal mask exchange with Aintree tube exchanger together with fibroscope guidance³.

Awaked fiberoptic intubation with DLT or Univent tube is nowadays rarely performed and barely recommended since BBs have become available. Both DLT and Univent tube appear bulky and rude for awaked insertion. Finally, it has to be stressed that visualization with thin fiber bronchoscope (LF-DP, Olympus 3.1 mm diameter) is poor. Also bronchoscope, coupled with long, bulky DLT has only short part of free flexible end for manipulation during efforts for awaked intubation^{1,3}.

References

1. BRODSKY JB. Lung separation and the difficult airway. *Br J Anesth* 2009;103(1):i66-i75.
2. CAMPOS JH. Lung isolation techniques for patient with difficult airway. *Curr Opin Anaesthesiol* 2010;23:12-7.

3. COHEN E, BENUMOF JL. Lung separation in the patient with a difficult airway. *Curr Opin Anaesthesiol* 1999;12:29-35.
4. SLINGER PD, editor. Principles and practice of anesthesia for thoracic surgery. New York, Dordrecht, Heidelberg, London: Springer, 2011.
5. COHEN E. The Cohen Flexitip Endobronchial Blocker: an alternative to a double-lumen tube. *Anesth Analg* 2005;101:1877-9.
6. CAMPOS JH. Which device should be considered the best for lung isolation: double-lumen endotracheal tube *versus* bronchial blockers. *Curr Opin Anaesthesiol* 2007;20:27-31.
7. MERLI G, GUARINO A, Della ROCCA G, FROVA G, PETRINI F, SORBELLO M, COCCIA C. Recommendations for airway control and difficult airway management in thoracic anesthesia and lung separation procedures. *Minerva Anesthesiol* 2009;75:59-96.
8. AMAR D, DESIDERIO DP, HEERDT PM, KOLKER AC, ZHANG H, THALER HT. Practice patterns in choice of left double-lumen tube size for thoracic surgery. *Internet Anesth Res Soc* 2008;106(2):379-83.
9. CAMPOS JH, KEMP HK. A comparison of left-sided Broncho-Cath with the torque control blocker Univent and the wire-guided blocker. *Anesth Analg* 2003;96:283-9.
10. CAMPOS JH. An update on bronchial blockers during lung separation techniques in adults – review article. *Anesth Analg* 2003;97:1266-74.

Sažetak

OTEŽANI DIŠNI PUT I VENTILACIJA JEDNOG PLUĆA

M. Drnovšek Globokar i V. Novak-Jankovič

Broj indikacija za kolaps pluća tijekom različitih kirurških postupaka je u porastu. Otežani gornji dišni put je češće povezan s potrebom ventilacije jednog pluća. U bolesnika s otežanim dišnim putom najsigurniji pristup zbrinjavanja dišnog puta je postavljanje jednolumenskog endotrahealnog tubusa pomoću fleksibilnog fiberoptičkog bronhoskopa. Izolacija jednog plućnog krila se u tim slučajevima postiže postavljanjem bronhijalnog blokatora. Alternativna tehnika je izmjena jednolumenskog u dvolumenski endotrahealni tubus pomoću specijalnog katetera, tzv. "izmjenjivača". Kada je prisutna traheostoma preporuča se postavljanje neovisnog bronhijalnog blokatora.

Ključne riječi: *Otežani dišni put; Ventilacija jednog pluća; Dvolumenski tubus; Endobronhijalni blokator; Kateter "izmjenjivač"*