

THE PREVALENCE OF IDIOPATHIC OSTEOSCLEROSIS AND CONDENSING OSTEITIS IN ZAGREB POPULATION

Željko Verzak¹, Branka Čelap², Vesna Erika Modrić³, Pjetra Sorić¹ and Zoran Karlović¹

¹School of Dental Medicine, University of Zagreb, ²Private Dental Practice, ³Zagreb Dental Clinic, Zagreb, Croatia

SUMMARY – The aim of this study was to determine the prevalence of idiopathic osteosclerosis (IO) and condensing osteitis (CO) in Zagreb patient population sample according to age and sex, localization in the jaw, as well as dental relationship between IO and CO lesions. A retrospective study was performed using orthopantomograms of 1200 patients who underwent dental treatment. Descriptive characteristics of radiopacities, including the size and information concerning the tooth involved, were recorded and processed using χ^2 -test. A total of 114 radiopacities were identified, 34 IO in 29 subjects (16 female and 13 male, mean age 35), and 80 CO in 69 subjects (38 female and 31 male, mean age 37). There were no significant sex differences. Both CO and IO showed greater predilection for occurrence in the premolar to molar region of the mandible. Our results indicated a low prevalence of IO and CO in the population of Zagreb. Our findings support the theory that IO lesions should be considered developmental variants of normal bone architecture unrelated to local stimuli, whereas CO lesions could be considered reactive formations related to teeth with deep caries, large restoration, or pulpitis.

Key words: *Osteosclerosis; Osteitis; Dental pulp diseases – epidemiology; Radiography*

Introduction

Idiopathic osteosclerosis (IO) of the jaw and condensing osteitis (CO) are asymptomatic localized radiopaque jaw lesions that are usually incidentally discovered on radiographs taken for some other reason¹. These conditions may cause changes in tooth position or problems during orthodontic treatment². Marques Silva *et al.*³ have reported a case of tooth resorption due to ectopic eruption route caused by IO.

Condensing osteitis or focal sclerosing osteomyelitis represents local reaction to a low-grade inflammatory stimulus⁴, which could be inflamed pulp in the case of chronic pulpitis or microorganisms from either necrotic pulp or from inadequately treated root canals,

in individuals with a high level of tissue resistance⁵, in whom osteoblast activity predominates, which results in bone apposition⁶⁻⁸. Radiologically, it is seen as a radiopaque lesion with well defined margins, which blends in with the surrounding bone⁵.

Idiopathic osteosclerosis cannot be attributed to any inflammatory, dysplastic, neoplastic or systemic disorder^{3,5}. It is generally separated from the teeth but it can be located around the apices of intact teeth or teeth with shallow caries or small restorations^{3,9,10}. Based on their longitudinal study, Halse and Molven¹¹ consider it a normal anatomic bone variation.

Differential diagnosis of IO and CO includes cementoblastoma or hypercementosis. Root remnants of deciduous and permanent teeth can also appear as radiopaque lesions¹².

Mixed radiopaque-radiolucent periapical lesions could be periapical cemental dysplasia, cementing fibroma, ossifying fibroma, or diffuse sclerosing osteomyelitis. Radiopacities in edentulous regions, after

Correspondence to: Zoran Karlović, DDM, PhD, School of Dental Medicine, University of Zagreb, Gundulićeva 5, HR-10000 Zagreb, Croatia
E-mail: karlovic@sfzg.hr

Received February 13, 2012, accepted June 4, 2012

tooth extraction, may represent residual CO, or they could be excessively ossified regions that have formed after surgery^{7,10}.

Patients and Methods

A total of 1200 orthopantomograms from 612 women and 588 men were randomly selected at the Department of Endodontics and Restorative Dentistry, School of Dental Medicine, University of Zagreb. A single examiner analyzed the radiographs.

The objectives of this study were to determine the prevalence, size and location of the CO and IO of the jaw in Zagreb population and to investigate the relationship between the findings with age and sex. For CO, we tried to determine the offending tooth pulpal status.

Periapical opaque lesions were considered to be CO if they had diffuse margins and they surrounded the apices of the teeth with severe caries or the teeth with large restorations or endodontically treated teeth, so it was likely that they were associated with chronic pulpitis or necrotic pulp^{5,9}. Periapical radiopacities adjacent to abutment teeth for fixed bridges or removable dentures as well as malpositioned teeth are indicative of occlusal overload or traumatic occlusion, or they can represent compensatory osteosclerosis^{1,12}.

The criteria for diagnosing IO were as follows: well defined homogeneous radiopacity of more than 3 mm in size, round, elliptical or irregular in shape, without radiolucent rim, which did not show any obvious connection to inflamed pulp^{9,12}. Radiographically, IO is usually better defined and less diffuse than CO^{3,7}.

Lesions that could not be interpreted as either CO or IO were excluded from the study, as well as osteosclerotic lesions surrounded by radiolucent rim, mixed radiopaque-radiolucent lesions, radiopacities interpreted as tori or exostoses, and clearly identifiable remnants of deciduous or permanent teeth. Orthopantomograms of patients with familial adenomatous polyposis were also excluded from the study⁹.

After radiological finding interpretation as either CO or IO, we recorded the age and sex of each patient as well as the number of lesions in a person. The size of the lesion was determined by measuring the largest diameter on the panoramic radiograph with a millimeter scale on a transparent foil. The location of

the lesion was classified first as mandibular or maxillary, then further by region of the jaw, and finally the relationship to the teeth.

We also assessed the condition of the tooth as intact, carious or restored, as well as the quality of endodontic treatment. The root canal treatment was considered to be adequate when the obturation material was 0-2 mm short from the radiographic apex with no voids, according to the criteria published by the European Society of Endodontology in 1994¹³. We assessed teeth in the vicinity of osteosclerotic lesion by looking for occlusal trauma signs: tooth malposition, overloaded tooth due to the loss of adjacent teeth, overloaded abutment of long span bridge or overloaded abutment of cantilever bridge. Periapical pathosis in combination with status of the tooth associated with bone lesions allowed us to detect the correlation between CO and its causal factors.

The χ^2 -test and variance analysis were used to determine the potential differences in the distribution of radiopacities when stratified by sex, age, number, size, localization and relation to the teeth. A p value of <0.05 was considered statistically significant.

Results

There were 80 CO lesions in 69 orthopantomograms (patients) and 34 IO lesions in 29 orthopantomograms. Table 1 shows distribution of IO and CO lesions by sex as well as localization of lesions.

We found that 44.93% of CO lesions were diagnosed in men and 55.07% in women. Idiopathic osteosclerosis was in 55.17% observed in male patients and in 44.83% in female patients (Table 1). Condensing osteitis occurred in patients aged between 15 and 69 years, while IO occurred in patients aged between 12 and 58 years. The mean age of patients with CO was 37, as compared with age 35 in patients with IO, which was not statistically significant.

Ninety percent of patients had one CO lesion, 9% had two and 1% exhibited six lesions. Idiopathic osteosclerosis appeared as only one lesion in 83% of cases, while in 17% of cases it appeared as two lesions (Table 1). The size of CO lesions ranged from 2 to 12 mm in diameter, while the size of IO lesions ranged from 2 to 13 mm in diameter. The mean size of CO lesions was 4.8±2.1 mm and the mean size of IO lesions was

6.4±2.8mm, so the IO lesions were significantly larger than the CO lesions. Condensing osteitis lesions were in 91.25% of cases identified in the mandible and in 8.75% in the maxilla. In 97.06% of cases, IO appeared in the mandible, and in 2.94% in the maxilla. Figure 1 shows dental localization of CO and Figure 2 dental localization of IO.

Thirty-nine percent of CO lesions were associated with teeth that had severe caries, large restorations or crown, and 24% of lesions were associated with non-vital teeth, which is suggestive that chronic pulpitis and pulp necrosis are the most common causes of CO. Teeth were considered nonvital if they had the pulp

Table 1. Distribution of condensing osteitis and idiopathic osteosclerosis lesions according to sex and localization

	Condensing osteitis	Idiopathic osteosclerosis
Male	31	13
Female	38	16
1 lesion on panoramic radiograph	62	24
2 lesions on panoramic radiograph	6	5
6 lesions on panoramic radiograph	1	0
Mandible	73	33
Maxilla	7	1
Molar region of the mandible	51	19
Between mandibular premolar and molar region	0	4
Premolar region of the mandible	20	6
Between mandibular intercanine and premolar region	0	3
Intercanine region of the mandible	2	1
Molar region of the maxilla	5	0
Premolar region of the maxilla	2	1

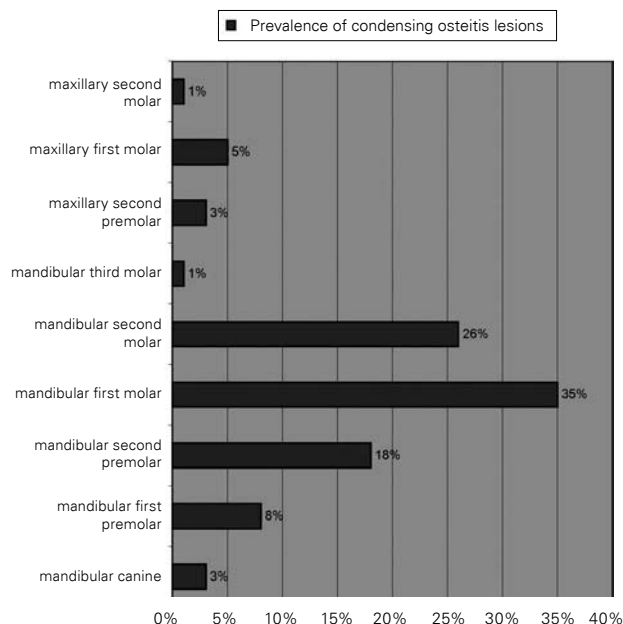


Fig. 1. Condensing osteitis dental localization.

chamber filled with radiopaque material and empty root canals, if they had destroyed crown and radiologically apparent broadly exposed pulp chamber, or if they had intracanal posts and empty root canals, and it was observed that 47.34% of nonvital teeth were overloaded. In 17% of CO lesions root canal treatment was considered to be inadequate and 42.86% of those

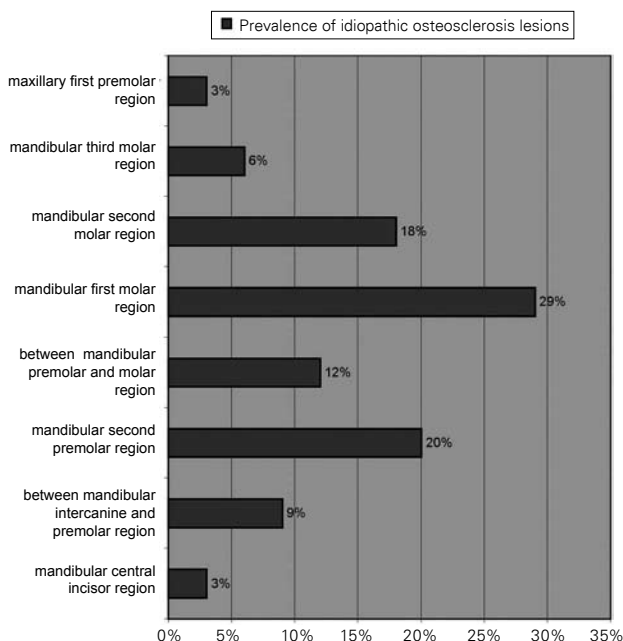


Fig. 2. Idiopathic osteosclerosis localization.

teeth were overloaded. Five percent of CO lesions were discovered in the place of extracted teeth, so it can be assumed that these teeth were either nonvital, untreated or inadequately treated. Well endodontically treated teeth made 5% of CO lesions, so we presume that bone healing resulted in sclerozation or that not enough time had elapsed after endodontic treatment, so CO lesions did not completely resolve. Forty-four percent of teeth with CO were overloaded.

Discussion

In our study, osteosclerotic lesions were observed in 98 (8.17%) of 1200 orthopantomograms examined. In contrast to this finding, Avramidou *et al.*¹⁴ report that 69 (1.96%) out of 3513 orthopantomograms exhibited radiopaque lesions. Condensing osteitis was identified in 6.7% and IO in 2.8% of orthopantomograms, more than in a study by Miloglu *et al.*⁹, who found 2.44% of IO lesions and 0.81% of CO lesions. Williams and Brooks⁶ found IO in 5.7% and CO in 4.5% of radiographically examined cases. Yonetsu *et al.*¹⁰ report the prevalence of IO to be 6.1%, the same as Sisman *et al.*¹², while Halse and Molven¹¹ found a prevalence of 7.6%.

In the present study, there was no significant sex difference in the incidence of CO, so this finding agrees with Miloglu *et al.*⁹ and also with Williams and Brooks⁶. However, Avramidou *et al.*¹⁴ found that women were more likely to have CO than men. No significant sex predilection was noted for IO lesions. This finding is in agreement with the results reported by Williams and Brooks⁶ and also by Halse and Molven¹¹. No sex differences were found in the cross-sectional studies by Yonetsu *et al.*¹⁰ and Sisman *et al.*¹². According to the studies by Avramidou *et al.*¹⁴ and Miloglu *et al.*⁹, female patients were more likely to have IO lesion than male patients.

In our study, the mandible proved to be the most affected site with 91.25% of CO lesions and 97.06% of IO lesions, which was statistically significant. Similarly, Miloglu *et al.*⁹ report that all CO lesions and 98.9% of IO lesions were located in the mandible. Yonetsu *et al.*¹⁰ also found only 2 of 73 IO lesions to be located in the maxilla. Avramidou *et al.*¹⁴ found only one radiopaque lesion in the maxilla. Complete reasoning for the frequent localization in the mandible remains

unclear, but it has been attributed to differences in bone anatomy and blood supply and also, owing to the anatomy of the bone and the common overlap, lesions in the maxilla are harder to view¹⁴.

The majority of CO lesions were detected in the mandibular molar region, especially around the lower first molar, as in the study by Miloglu *et al.*⁹, which may be attributed to caries, occlusal stress and traumatic infection of the pulp, all factors that are more likely to occur on molar than premolar teeth¹⁵. Miloglu *et al.*⁹ observed more IO lesions in the premolar region than in the molar region, while our study showed the opposite (Table 2). Avramidou *et al.*¹⁴ found no difference between the molar and premolar region. In our study, neither IO nor CO lesions showed any age predilection, unlike some other studies^{9-11,14,16}.

In their longitudinal study in adult patients, Williams and Brooks⁶ concluded that IO lesions were stable in size, while only 4% of CO lesions increased during the study period. If a well defined asymptomatic radiopaque lesion is observed on oral radiographs, the dentist must determine the diagnosis and treat it appropriately. Condensing osteitis will exhibit rebuilding of bone structures to normal appearance after successful endodontic therapy on the radiograph⁸. Once IO is diagnosed in an adult patient, neither treatment nor radiographic follow-ups are indicated in asymptomatic patients. It is a developmental lesion that can therefore change size in young patients, and that is why periodic radiographic examinations are recommended in children until their growth has completed and the lesion is stabilized^{4,6}.

In conclusion, CO and IO have low prevalence in Zagreb population. Our results support the view that IO lesions are developmental variations of normal bony architecture unrelated to local stimuli. On the other hand, CO lesions can be defined as a reaction of bone to an infection, often the result of a carious tooth, heavily restored tooth or tooth with pulpitis.

References

1. ARAKI M, MATSUMOTO N, MATSUMOTO K, OHNISHI M, HONDA K, KOMIYAMA K. Asymptomatic radiopaque lesions of the jaws: a radiographic study using cone-beam computed tomography. *J Oral Sci* 2011;53:439-44.
2. BAUMGAERTEL S. Socket sclerosis – an obstacle for orthodontic space closure? *Angle Orthod* 2009;79:800-3.

3. MARQUES SILVA L, GUIMARAES AL, DILASCIO ML, CASTRO WH, GOMEZ RS. A rare complication of idiopathic osteosclerosis. *Med Oral Patol Oral Cir Bucal* 2007;12:233-4.
4. KAPLAN I, NICOLAOU Z, HATUEL D, CALDERON S. Solitary central osteoma of the jaws: a diagnostic dilemma. *Oral Surg Oral Med Oral Pathol Oral Radiol Endod* 2008;106:22-9.
5. HOLLY D, JURKOVIC R, MRACNA J. Condensing osteitis in oral region. *Bratisl Lek Listy* 2009;110:713-5.
6. WILLIAMS TP, BROOKS SL. A longitudinal study of idiopathic osteosclerosis and condensing osteitis. *Dentomaxillofac Radiol* 1998;27:275-8.
7. BOONYAPAKORN T, SUPANCHART C, REICHART PA. Radiopaque lesion with peripheral radiolucency of the mandible. *Oral Surg Oral Med Oral Pathol Oral Radiol Endod* 2006;102:713-8.
8. INGLE JI, BAKLAND LK. *Endodontics*. 5th ed. Hamilton: BC Decker Inc., 2002.
9. MILOGLU O, YALCIN E, BUYUKKURT MC, ACEMOGLU H. The frequency and characteristics of idiopathic osteosclerosis and condensing osteitis lesions in a Turkish patient population. *Med Oral Patol Oral Cir Bucal* 2009;14:640-5.
10. YONETSU K, YUASA K, KANDA S. Idiopathic osteosclerosis of the jaws: panoramic radiographic and computed tomographic findings. *Oral Surg Oral Med Oral Pathol Oral Radiol Endod* 1997;83:517-21.
11. HALSE A, MOLVEN O. Idiopathic osteosclerosis of the jaws followed through a period of 20-27 years. *Int Endod J* 2002;35:747-51.
12. SISMAN Y, ERTAS ET, ERTAS H, SEKERCİ AE. The frequency and distribution of idiopathic osteosclerosis of the jaw. *Eur J Dent* 2011;5:409-14.
13. European Society of Endodontology. Consensus report of the European Society of Endodontology on quality guidelines for endodontic treatment. *Int Endod J* 1994;27:115-24.
14. AVRAMIDOU FM, MARKOU E, LAMBRIANIDIS T. Cross-sectional study of the radiographic appearance of radiopaque lesions of the jawbones in a sample of Greek dental patients. *Oral Surg Oral Med Oral Pathol Oral Radiol Endod* 2008;106:38-43.
15. CHUNG MP, CHEN CP, SHIEH YS. Floating retained root lesion mimicking apical periodontitis. *Oral Surg Oral Med Oral Pathol Oral Radiol Endod* 2009;108:63-6.
16. BADEL T, SAVIĆ-PAVIČIN I, ZADRAVEC D, MARROTTI M, KROLO I, GRBEŠA D. Temporomandibular joint development and functional disorders related to clinical otologic symptomatology. *Acta Clin Croat* 2011;50:51-60.

Sažetak

UČESTALOST IDIOPATSKE OSTEOSKLEROZE I KONDENZIRAJUĆEG OSTITISA U ZAGREBAČKOJ POPULACIJI

Ž. Verzak, B. Čelap, V. E. Modrić, P. Sorić i Z. Karlović

Cilj ovoga istraživanja bio je ispitati učestalost idiopatske osteoskleroze (IO) i kondenzirajućeg ostitisa (KO) u zagrebačkoj populaciji s obzirom na spol i dob stanovništva, lokalizaciju u čeljusti i status zuba u blizini kojeg se pojavljuju lezije IO i KO. Retrospektivna studija provedena je pomoću ortopantomograma 1200 pacijenata podvrgnutih stomatološkom liječenju. Zabilježene su opisne značajke radiopaknih oštećenja uključujući veličinu i povezanost sa zubom uzročnikom. U analizi podataka rabio se χ^2 -test. Otkriveno je ukupno 114 radiopaknih oštećenja, od kojih su 34 dijagnosticirana kao IO u 29 ispitanika (16 žena, 13 muškaraca, srednja dob 35 godina), a 80 kao KO u 69 ispitanika (38 žena, 31 muškarac, srednja dob 37 godina). Nije pronađena razlika među spolovima u pojavljivanju ovih oštećenja. Oštećenja IO i KO češće su zabilježena u premolarnoj i molarnoj regiji donje čeljusti. Naši rezultati ukazuju na nisku učestalost IO i KO u zagrebačkoj populaciji. Uz to, naši rezultati podupiru teoriju da je IO razvojna varijacija normalne koštane arhitekture neovisna o lokalnim stimulantima, dok se KO može smatrati reaktivnom tvorbom koja se pojavljuje uza zube s dubokim karijesom, dubokim ispunima ili pulpitisom.

Ključne riječi: *Osteoskleroza; Ostitis; Bolesti zubne pulpe – epidemiologija; Radiografija*

