

Migraine due to intraparenchymal hemorrhage during a blast crisis

ROBERTO LA ROCCA • FIORANGELA MARLETTA •
DENISE P COMINA • NGAMBE M PRESTON • CHIARA MERLO •
MICHELE VOLPI • MATTEO BRAMBATI

MATTEO BRAMBATI (✉)
Facoltà di Medicina e Chirurgia
Università Statale di Milano
Via Kennedy 18, San Donato Milanese
20097, Milano, Italy
Phone: +393288028910
E-mail: brambati@hotmail.it

ROBERTO LA ROCCA •
FIORANGELA MARLETTA •
DENISE P COMINA
Ngambe M Preston, Chiara Merlo
Michele Volpi
Emergency Department, IRCCS Policlinico
San Donato, Milano, Italy

ABSTRACT

Background. Hyperleukocytosis is defined as a white blood cell (WBC) count in excess of 100,000 per mm³. Hyperleukocytosis can cause leukostasis syndrome, the accumulation of leukemic blast cells within the capillary lumen, resulting in neurologic and pulmonary manifestations that can lead to intracranial haemorrhage and respiratory failure.

Objective. Identify a correct diagnostic approach, as the diagnosis of leukostasis in a patient suffering from acute leukemia with hyperleukocytosis is made only clinically. A full blood cell count and a peripheral blood smear are essential for diagnosing leukostasis.

Case report. A 19 year old girl presented to the emergency department reporting onset of headache, absence of regression of symptoms after taking painkillers (non steroidal anti inflammatory drugs (NSAIDs)), intense fatigue and absence of fever. On examination, modest hypotension and anisocoria (with reactive pupils) were evidenced. A brain computed tomography (CT) scan was performed. Several, large areas of parenchymal haemorrhage were identified. A chest and abdomen CT scan was requested. The images demonstrated the presence of splenomegaly. The laboratory findings confirmed the suspected diagnosis, with a leukocyte count equal to 980,000 units per mm³ and a platelet count of 24,000 units per mm³.

Conclusion. Given the clinical case and its evolution, no report of recent onset of headache, especially in young patients, should be underestimated.

Key words: intraparenchymal hemorrhage, hyperleukocytosis, leukostasis, leukaemia, emergency department

Introduction

Hyperleukocytosis is defined as a white blood cell (WBC) count in excess of 100,000 per mm³. Hyperleukocytosis can cause leukostasis syndrome, the accumulation of leukemic blast cells within the capillary lumen, resulting in neurologic and pulmonary manifestations that can lead to intracranial haemorrhage and respiratory failure. The main objective of this article consists of identifying a correct diagnostic approach, as the diagnosis of leukosta-

sis in a patient suffering from acute leukemia with hyperleukocytosis is made only clinically.

Case report

A 19 year old girl presented to the emergency department reporting onset of headache, absence of regression of symptoms after taking non steroidal anti inflammatory drugs (NSAIDs), intense fatigue and absence of fever. On examination, modest hypotension, anisocoria (with reactive pupils), numerous ecchymosis on several parts of the body (legs and lower abdominal quadrants) and a slight deterioration of sensorium were evidenced. A brain CT was performed. Several, large areas of

parenchymal haemorrhage (the largest being 11 mm in diameter) were identified (figure 1). A chest and abdominal computed tomography (CT) scan was requested. The images demonstrated the presence of splenomegaly (diameter 15 to 22 cm) (figure 2) and numerous pathological lymph nodes (the largest of 2.8 cm) in the iliac, axillary and aortic regions. These findings were identified as indicative of acute leukemia by the radiologist. Given the mental deterioration of the patient (Glasgow coma scale [GCS] 10/11), an emergency blood transfusion was started (two units of blood and one unit of platelets). The laboratory confirmed the suspicion with a leukocyte count

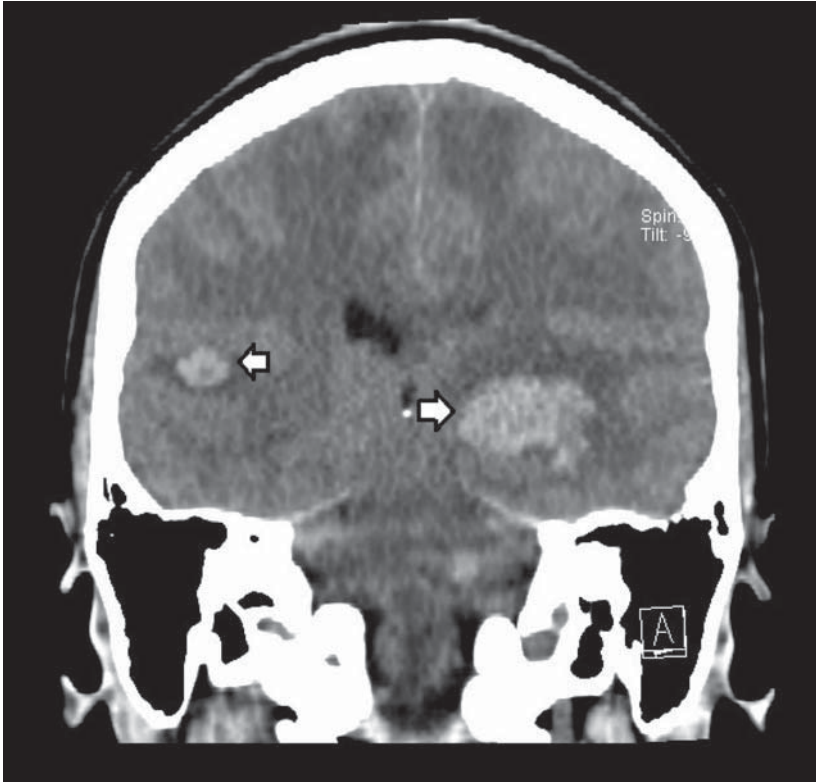


Figure 1. Brain computed tomography scan without contrast enhancement. Two large areas of intraparenchymal haemorrhage are evidenced.

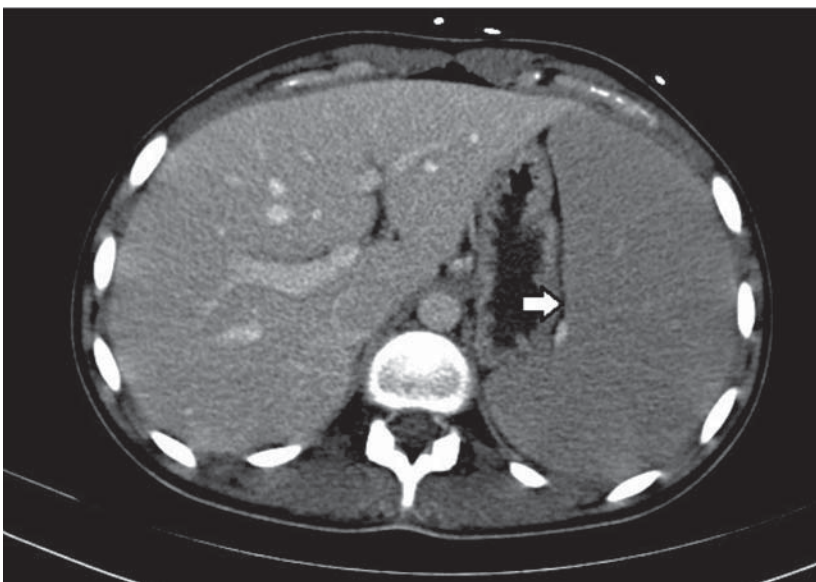


Figure 2. Abdomen computed tomography scan with arterial contrast enhancement. Demonstration of splenomegaly.

equal to 980,000 units per mm^3 and a platelet count of 24,000 units per mm^3 . The peripheral blood exam confirmed the presence of numerous lymphoid

leukemic blasts in all microscopic fields (figure 3). The patient was first orally intubated and then admitted to the neurosurgery department.

Discussion

Pathophysiology

Hyperleukocytosis is defined as a WBC count in excess of 100,000 per mm^3 . (1) Hyperleukocytosis is a relevant prognostic factor in several types of leukaemias. (2) In acute leukaemia it carries a high early mortality rate. (3) Hyperleukocytosis can cause leukostasis syndrome, the accumulation of leukemic cells within the capillary lumen, resulting in neurological and pulmonary manifestations that can lead to intracranial haemorrhage and respiratory failure. (4) Hyperleukocytosis has been found to occur in 7.3% of paediatric patients with acute leukaemia. The conventional theory relates leukostasis to increased blood viscosity in microcirculation. More recent evidences suggest that adhesive interactions between leukemic blasts and endothelium result in endothelial damage. This is thought to be mediated by cytokines that trigger a chemotactic migration of blast cells. Adhesion molecules in leukemic cells play a relevant role. Hyperleukocytosis can occur in patients with acute promyelocyte leukaemia treated with all-trans retinoic acid. It appears that the drug induces changes in adhesion receptors. The incidence of leukostasis is greater and occurs at a lower WBC count in acute myeloid leukaemia (AML) than in acute lymphoid leukaemia (ALL). (5) In ALL, intracerebral haemorrhage does not typically occur unless the WBC count exceeds 400,000 per mm^3 . (6) The viscosity of leukocytes is related to their fractional volume. Leukemic myeloblasts are roughly twice the size of leukemic lymphoblasts; myeloid blasts are also less deformable than lymphoid blasts and have a greater tendency to adhere to each other and to vascular endothelium, resulting in more capillary sludging. (7) Leukostasis incidence in leukaemia is as follows: AML, chronic myeloid leukaemia (CML), ALL and chronic lymphoid leukaemia (CLL). (7) Clinically evident leukostasis does not seem to occur during the chronic phase in CML and CLL, despite exceedingly high WBC counts. It can occur during blast crisis at much lower WBC counts. (8)

Patient presentation

Symptoms of leukostasis are related to vascular damage of involved parenchy-

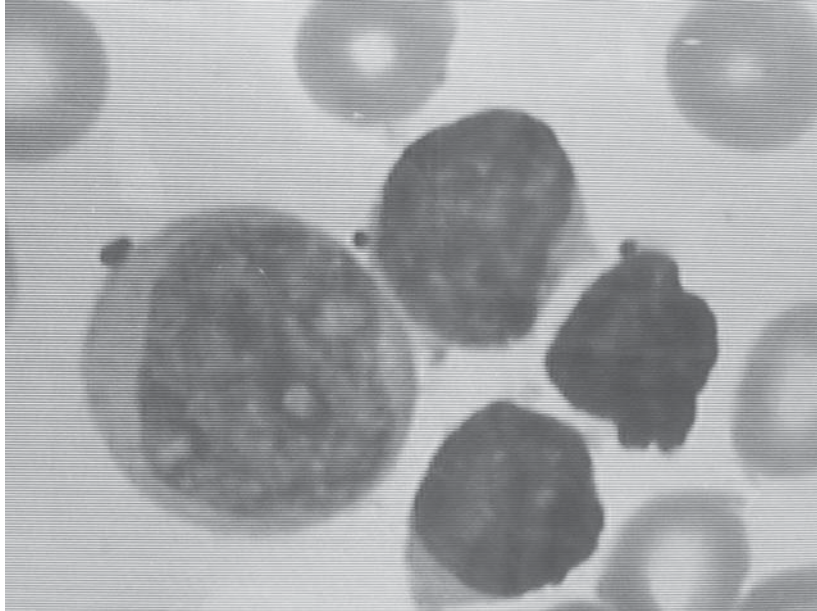


Figure 3. Peripheral blood smear. Demonstration of lymphoid leukemic blasts.

mas. Hypoxemia and pulmonary infiltrates are the most common pulmonary symptoms. Consequences of leukocyte infiltration into brain parenchyma may lead to altered mental status, headache and visual field defects. Onset of fever is common. Other reported manifestations include myocardial ischemia, renal vein thrombosis, bowel infarction and priapism. Disseminated intravascular coagulation (DIC) and thrombocytopenia can be found often. Automated laboratory

tests may underestimate the degree of thrombocytopenia as leukocyte fragments could be counted as platelets.

Diagnostic methods

Diagnosis of leukostasis is made clinically. Main symptoms have been listed previously. The presence of pulmonary or cerebral symptoms should always suggest a blast crisis in patients with leukemia. A full blood cell count and a peripheral blood smear are essential for diagnosing leukostasis.

Treatment

Cytoreduction by leukapheresis is the most indicated therapy. The maintenance of a low value of blood viscosity is mandatory. Heparin and NSAIDs should be avoided since they can aggravate clotting ability. If the platelet count is below 20,000 to 25,000, a platelet transfusion should be set-up. (9) Kidney failure is a risk associated with blast crises. (9) The presence of more than one million leukocytes is associated with a poor prognostic outcome. The infusion of crystalloids is indicated to maintain a low level of blood viscosity. It is mandatory after eliminating the risk of hemorrhage. Transfusion should be avoided in asymptomatic patients since it is possible to increase the risk of bleeding. (10)

Conclusion

Given the low incidence of hyperleukocytosis and the possibility of confusing it with other acute conditions, it is necessary to emphasize the importance of a correct diagnostic procedure. Given the presenting symptoms and outcome of our patient, no case of headache should be underestimated. The blood count should be performed in all suspected cases of leukostasis. This study emphasizes the importance of brain CT examination in patients with drug resistant migraine.

REFERENCES

1. Lowe EJ, Pui CH, Hancock ML, Geiger TL, Khan RB, Sandlund JT. Early complications in children with acute lymphoblastic leukemia presenting with hyperleukocytosis. *Pediatr Blood Cancer* 2005 Jul;45(1):10-5.
2. Ganzel C, Becker J, Mintz PD, Lazarus HM, Rowe JM. Hyperleukocytosis, leukostasis and leukapheresis: practice management. *Blood Rev* 2012 May;26(3):117-22.
3. Cortes JE, Kantarjian HM. Acute lymphoblastic leukemia. A comprehensive review with emphasis on biology and therapy. *Cancer* 1995 Dec 15;76(12):2393-417.
4. Wald BR, Heisel MA, Ortega JA. Frequency of early death in children with acute leukemia presenting with hyperleukocytosis. *Cancer* 1982 Jul 1;50(1):150-3.
5. Litchmann MA, Heal J, Rowe JM. Hyperleukocytic leukemia: rheological and clinical features and management. *Baillieres Clin Haematol* 1987 Sep;1(3):725-46.
6. Bunin NJ, Pui CH. Differing complications of hyperleukocytosis in children with acute lymphoblastic or acute nonlymphoblastic leukemia. *J Clin Oncol* 1985 Dec;3(12):1590-5.
7. Lee L. Leukostasis and intravascular tumors. In: Richard Lee G, Foerster J, Lukens J, Paraskevas F, Greer JP, Rodgers GM, editors. *Wintrobe's clinical hematology*, 10th edition. Philadelphia (PA): Lippincott Williams & Wilkins; 1999. p. 2040-4.
8. Blumenthal DT, Glenn MJ. Neurologic manifestations of hematologic disorders. *Neurol Clin* 2002 Feb;20(1):265-81.
9. Baer MR. Management of unusual presentations of acute leukemia. *Hematol Oncol Clin North Am* 1993 Feb;7(1):275-92.
10. Harris AL. Leukostasis associated with blood transfusion in acute myeloid leukaemia. *Br Med J* 1978 May 6;1(6121):1169-71.