

## Onychomatricoma Masquerading as Candidal Onychomycosis and Paronychia

Emel Öztürk Durmaz<sup>1</sup>, Engin Sezer<sup>1,2</sup>, Emel Dikicioğlu Çetin<sup>2</sup>, Sedef Şahin<sup>1</sup>

<sup>1</sup>Department of Dermatology, <sup>2</sup>Department of Pathology, Acıbadem University School of Medicine, İstanbul, Turkey

### Corresponding author:

Professor Emel Öztürk Durmaz, MD  
Acıbadem Maslak Hospital  
Büyükdere Caddesi 40  
Maslak 34457  
İstanbul  
Turkey  
emelerkek@yahoo.com

**SUMMARY** – Onychomatricoma is a benign slow-growing fibroepithelial tumor arising from the nail matrix. The tumor was described as a new entity almost two decades ago. Although the clinical appearance is typical, most cases are probably misdiagnosed by physicians because of unfamiliarity with the condition. Herein we describe a case of onychomatricoma masquerading as candidal onychomycosis and paronychia and treated erroneously as such.

**KEY WORDS:** onychomatricoma, onychomatrixoma, nail tumor, onychomycosis

Received: January 8, 2013

Accepted: June 1 2013

### INTRODUCTION

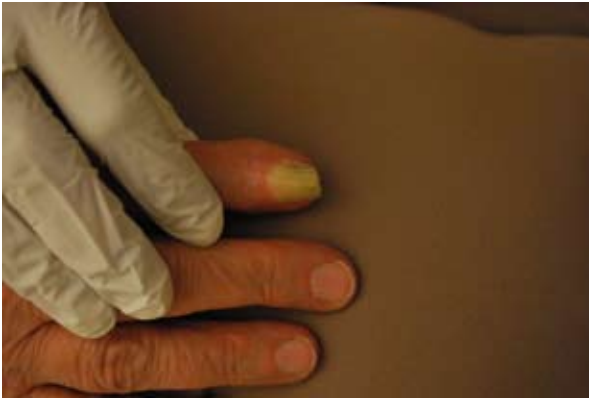Onychomatricoma (OM) is a rare benign slow-growing fibroepithelial tumor arising from the nail matrix (1). The tumor was described as a new entity by Baran and Kint in 1992, and was initially termed as “onychomatrixoma” (2). The most widely used term, “onychomatricoma”, was first coined by Haneke and Fränken in 1995 (3). Up to now, fewer than 70 cases have been reported (4).

Herein we describe a case of OM previously misdiagnosed as candidal onychomycosis and paronychia and erroneously treated as such. We believe that OM is still an unrecognized entity and probably more common than cited in the relevant literature (5). Awareness of the condition may preclude the long-term use of unnecessary and potentially toxic oral antifungal medications.

### CASE REPORT

A 72 year-old Caucasian woman presented with a 15-year history of nail plate discoloration and deformity involving the right index finger. There was no complaint apart from cosmetic unsightly appearance. She had received various oral antifungal medications beforehand for 2 years based on a presumptive clinical diagnosis of candidal onychomycosis and paronychia, but without apparent benefit. Her personal medical history was remarkable for hypertension, lumbar disk hernia and total hip arthroplasty. There was no previous history of nail trauma or avulsion.

Dermatological examination revealed thickening, longitudinal ridging, yellowish discoloration and transverse overcurvature confined to the index fingernail of the right hand (Figs.1 and 2). Bulbous swelling and mild erythema of the proximal nail fold was



**Figure 1.** Thickening, longitudinal ridging, yellowish discoloration and transverse overcurvature of the nail plate. Note bulbous swelling and mild erythema of the proximal nail fold.

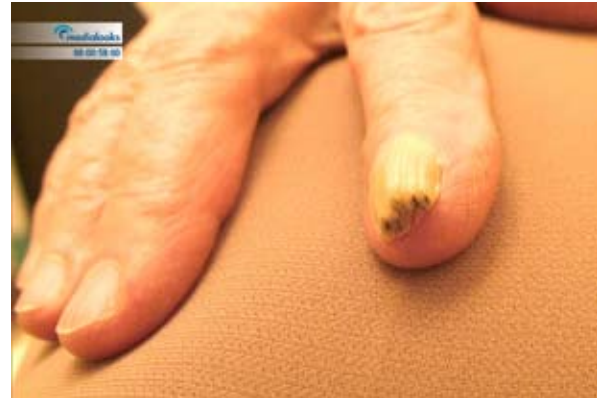observed. Green to gray holes with irregular sizes and shapes were noted at the distal free border of thickened nail plate. A potassium hydroxide examination of nail scrapings was negative. Dermoscopy of the nail plate surface demonstrated longitudinal yellowish lines and splinter hemorrhages, whereas that of the free border of the nail offered closer inspection of the woodworm-like gray to green irregular cavities (Fig. 3). Initial tentative clinical diagnosis was onychomatricoma.

The patient was referred to the Department of Orthopedics and Traumatology for nail avulsion, complete excision of the tumor and total matrix destruction. Histopathologic examination revealed a thick funnel-shaped nail plate, perforated by woodworm-like cavities (Fig. 4). The matricial fibroepithelial tumor was characterized by deep epithelial invaginations and a fibrillar stroma at the proximal zone, and multiple "glove finger" fibrokeratogenous digitations along its connective tissue axes at the distal zone (Figs. 5 and 6).

Based on histologic findings, the diagnosis was firmly established as OM. There was no disease recurrence at the one-year postoperative follow up.

## CONCLUSION

Onychomatricoma is a relatively recently described fibroepithelial tumor of the nail matrix. The median age of reported cases is 50 years (6,7). The tumor is usually confined to adult population (8), although a pediatric case has recently been reported (9). Sex distribution is almost equal (5,9). It is much more frequent in Caucasians and most cases reported hitherto were from Europe (5,6,8,10).

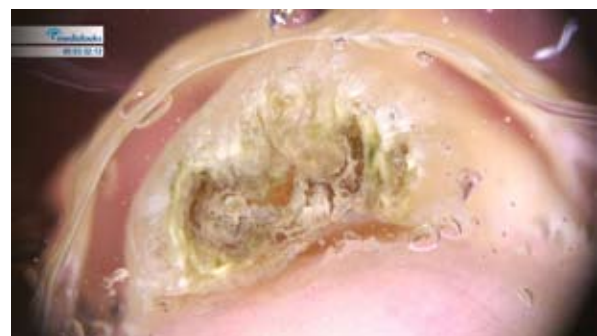

**Figure 2.** Green to gray irregular holes at the distal free border of the nail plate.

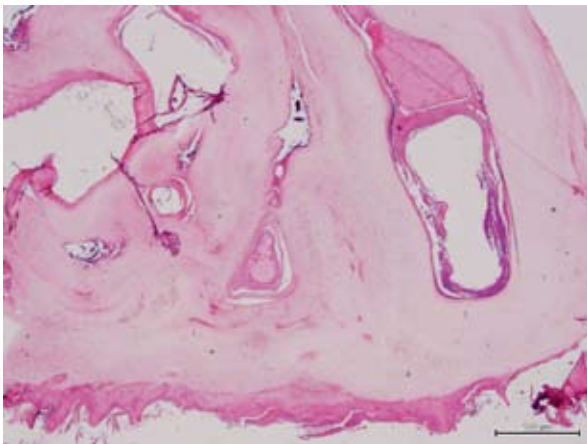
The etiology is skeptical. A history of preceding trauma may seldom be elicited (6,8,10,11). Nail clippings for mycology are usually negative and radiology shows no bony abnormalities (4,5,10,12).

Onychomatricoma is clinically characterized by a diffusely thickened, longitudinally ridged and yellowish nail plate with transverse overcurvature (1,8). There may be proximally located splinter hemorrhages and proximal nail swelling (6,8,12,13). Longitudinal hollows may be visualized as holes at the distal free border of the nail (woodworm-like or honeycomb-like cavities) (5,8,14,15). Sometimes only a portion of the nail apparatus is involved in the form of a longitudinal yellowish band of variable width (5,12,14). Onychomatricoma is more commonly reported on fingernails (75-80 %), particularly index fingernail, then on toenails. The tumor is typically asymptomatic, although pain due to compression by footwear has been elicited in OM of toenails (4,8). Bleeding might occur upon clipping the free margin of the nail (12).

Onychomatricoma appears to be the only tumor that actively produces nail plate deformity by its filiform fibrokeratogenous projections that macroscopically resemble an "anemone" and perforate the nail



**Figure 3.** Dermoscopy of the free border of the nail revealing woodworm-like irregular cavities.



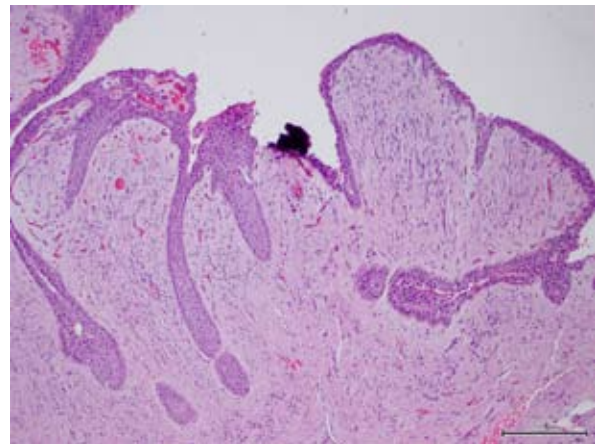
**Figure 4.** Thickened funnel-shaped nail plate with the woodworm-like cavities. (H&E, X10).

plate (4,5,8-10,15). Nail avulsion exposes a tufted villous tumor originating from the nail matrix epithelium and emerging through the proximal nail fold (14). The nail plate appears as a thickened funnel, storing filamentous fibroepithelial digitations from the matrix fitting into the holes visible at its proximal aspect (14,16).

Unusual variants of OM comprise pterygium-like, onychogenic Bowen's disease-like, fibrokeratoma-like, cutaneous horn-like and melanonychia-like (pigmented) variants (1,7,8,11,14,16,17). Unlike the classical OM where the tumor is confined to the ventral matrix, unusual clinical variants have been ascribed to the involvement of the ventral aspect of proximal nail fold (7,14,16).

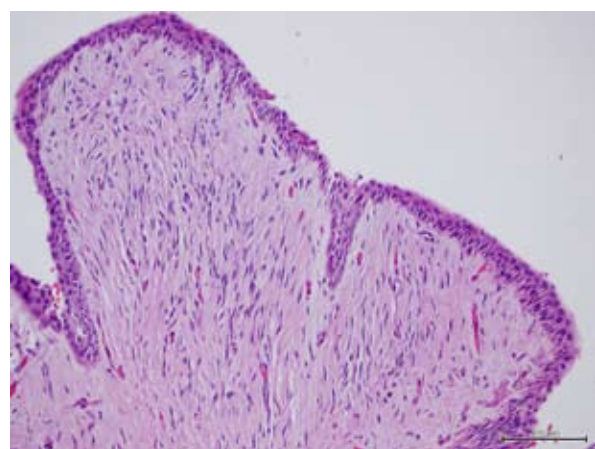
Dermatoscopy shows thick nail with linear longitudinal yellowish to whitish lines (corresponding to nail plate hollows) and splinter hemorrhages (4,9,12). In our case, typical dermatoscopic features were present on the upper surface of the nail plate. In addition, dermatoscopy of the free border of the nail assisted us in spotting the irregular holes in the nail plate created by the tumor itself. Other fast and minimally invasive techniques that may aid in making a correct diagnosis include nail clipping (a thick nail plate having lacunae of varying sizes and shapes filled with serous fluid and lined by a thin layer of epithelium), high-resolution variable frequency ultrasonography and magnetic resonance imaging (pathognomonic Y-shape at the proximal portion of the nail plate longitudinally and holes transversely) (4,8,14,15).

Histologically, the diagnosis is confirmed by the presence of 3 features: (a) a fibroepithelial tumor consisting of 2 portions: the proximal zone (under



**Figure 5.** Fibroepithelial villous tumor of the matrix with multiple 'glove finger' digitations along its connective tissue axes (distal zone). (H&E, X10)

the proximal nail fold corresponding to the root of the nail and cuticle, characterized by deep epithelial invaginations and a fibrillar and fibrocytic stroma), and a distal zone (corresponding to the lunula, characterized by multiple "glove finger" digitations along its connective tissue axes); (b) a matricial tumor typified by a thick keratogenous zone; and (c) a thick nail plate, perforated by cavities (1,12,17). However, histologic spectrum is broader than previously recognized (7). Immunohistochemical analysis is a helpful diagnostic tool; however, it is neither specific nor mandatory (6-8,10). On electron microscopy, the basal cells of OM contain apparently decreased numbers of tonofilaments and desmosomes of nonuniform evolution (8).



**Figure 6.** Multiple 'glove finger' digitations (the same area as in Figure 5, close up) (H&E, magnification is illustrated in the figure).

## CONCLUSION

The prognosis of OM is good, despite the lack of series with long-term follow-up (8). Although recurrence and malignant transformation have not been reported, dysplasia may be encountered (6). Some authors consider OM as a premalignant lesion (4,12).

Treatment of choice is complete surgical excision (4,8). Surgery should entail the entire matrix proximal to the tumor to avoid recurrences (5,12). The cosmetic and functional outcome of the surgery should be discussed with the patient preoperatively (10).

## References

1. Baran R, Perrin C. Bowen's disease clinically simulating an onychomatricoma. *J Am Acad Dermatol* 2002;47:947-9.
2. Baran R, Kint A. Onychomatricoma: filamentous tufted tumor in the matrix of a funnel-shaped nail: a new entity (report of three cases). *Br J Dermatol* 1992;126:510-5.
3. Haneke E, Fränken J. Onychomatricoma. *Dermatol Surg* 1995;21:984-7.
4. Becerro de Bengoa R, Gates JR, Losa Iglesias ME, Alija Martinez B. Rare toenail onychomatricoma: surgical resolution of five cases. *Dermatol Surg* 2011;37:709-11.
5. Tosti A, Piraccini BM, Calderoni O, Fanti PA, Cameli N, Varotti E. Onychomatricoma: report of three cases, including the first recognized in a colored man. *Eur J Dermatol* 2000;10:604-6.
6. Fernández-Sánchez M, Saeb-Lima M, Charli-Joseph Y, Méndez-Flores S, Sánchez-Hernández C, Carbajosa-Martinez J. Onychomatricoma: an infrequent nail tumor. *Indian J Dermatol Venereol Leprol* 2012;78:382-3.
7. Perrin C, Baran R, Balaguer T, Chignon-Sicard B, Cannata GE, Petrella T, *et al.* Onychomatricoma: new clinical and histological features. A review of 19 tumors. *Am J Dermatopathol* 2010;32:1-8.
8. Cañueto J, Santos-Briz Á, García JL, Robledo C, Unamuno P. Onychomatricoma: genome-wide analyses of a rare nail matrix tumor. *J Am Acad Dermatol* 2011;64:573-8.
9. Piraccini BM, Antonucci A, Rech G, Starace M, Misciali C, Tosti A. Onychomatricoma: first description in a child. *Pediatr Dermatol* 2007;24:46-8.
10. Estrada-Chavez G, Vega-Memije ME, Toussaint-Caire S, Rangel L, Dominguez-Cherit J. Giant onychomatricoma: report of two cases with rare clinical presentation. *Int J Dermatol* 2007;46:634-6.
11. Goettmann S, Zaraa I, Moulounguet I. Onychomatricoma with pterygium aspect: unusual clinical presentation. *Acta Derm Venereol* 2006;86:369-70.
12. Khelifa E, Tschanz C, Masouyé I, Kerl K, Borradori L. A rare tumour of the nail apparatus: onychomatricoma. *J Eur Acad Dermatol Venereol* 2008;22:1127-8.
13. Nandedkar-Thomas MA, Scher RK. An update on disorders of the nails. *J Am Acad Dermatol* 2005;52:877-87.
14. Perrin C, Baran R. Onychomatricoma with dorsal pterygium: pathogenic mechanisms in 3 cases. *J Am Acad Dermatol* 2008;59:990-4.
15. Miteva M, de Farias DC, Zaiac M, Romanelli P, Tosti A. Nail clipping diagnosis of onychomatricoma. *Arch Dermatol* 2011;147:1117-8.
16. Perrin C, Langbein L, Schweizer J, Cannata GE, Balaguer T, Chignon-Sicard B, *et al.* Onychomatricoma in the light of the microanatomy of the normal nail unit. *Am J Dermatopathol* 2011;33:131-9.
17. Perrin C, Goettmann S, Baran R. Onychomatricoma: clinical and histopathologic findings in 12 cases. *J Am Acad Dermatol* 1998;39:560-4.

