

DERMATITIS ARTEFACTA: CASE REPORT

Teodora Gregurek Novak¹, Tomislav Duvančić¹ and Majda Vučić²

¹Clinical Department of Dermatovenereology, ²Ljudevit Jurak Clinical Department of Pathology, Sestre milosrdnice University Hospital Center, Zagreb, Croatia

SUMMARY – Automutilating behavior is becoming ever more frequent in patients seeking dermatologic care. Psychocutaneous disorders encompass a wide range of dermatologic conditions, all of which have in common the important role of psychological factors. Dermatitis artefacta syndrome is characterized by unconscious self-injury behavior, while dermatitis para-artefacta syndrome is labeled with manipulation of an existing specific dermatosis. Consciously stimulated injuries with the purpose of obtaining material gain is known as malingering. Here we present a 20-year-old female patient with a sudden pain and an oval, yellowish skin defect on her left lower leg, 3x3.5 cm in diameter, with an erythematous, clearly defined border, surrounded by erythematous, painful skin resembling pyoderma gangrenosum. The patient had a clinically typical skin presentation but with atypical therapeutic outcome. The diagnosis of dermatitis artefacta was made. Liaison psychiatry can reaffirm the diagnosis of dermatitis artefacta and provide necessary psychopharmacotherapy and psychotherapy.

Key words: *Dermatitis artefacta; Pyoderma gangrenosum; Liaison psychiatry*

Introduction

Factitious disorders fall into the category of psychocutaneous syndromes due to the importance of psychological factors in these dermatologic conditions¹. The primary psychiatric disorder is the background of such patient's behavior, which can be conscious/semi-conscious or non-conscious. In dermatitis artefacta syndrome, the patient self-inflicts skin lesions unconsciously of their motive, mimicking a wide range of dermatoses¹⁻⁸. An important differential diagnosis to dermatitis artefacta is malingering, which is referred to as conscious self-injury for the purpose of obtaining a material gain¹. Indeed it depends on the creativity and imaginativeness of patients. In 1922, Sir Norman Walker pointed out that "neither rank, education, intelligence, devotion to duty, nor the most exemplary

character exclude the possibility of self infliction"⁹. Manipulation of an already existing skin lesion to the point of a more serious clinical finding is also sometimes referred to as dermatitis para-artefacta¹⁰.

Here we present a case of a young woman with clinically typical pyoderma gangrenosum on her lower left leg but with atypical disease course. Pyoderma gangrenosum is a rare chronic skin disease of unknown etiology¹¹. Diagnosis of pyoderma gangrenosum can be difficult to make^{12,13}. Moreover, the histopathologic finding is not pathognomonic.

Case Report

A 20-year-old female patient, medical nurse by occupation, was referred to our dermatology clinic for an ulcer-like lesion on her left lower leg. The lesion was an oval, yellowish skin defect, 3x3 cm in diameter, with an erythematous, sharply defined border, with partly necrotic base, surrounded by erythematous, painful skin. Our first clinical diagnosis was pyoderma gangrenosum. The patient was denying any trauma at the

Correspondence to: *Tomislav Duvančić, MD*, Clinical Department of Dermatovenereology, Sestre milosrdnice University Hospital Center, Vinogradska c. 29, HR-10000 Zagreb, Croatia
E-mail: tom.mioc@yahoo.com

Received December 12, 2011, accepted March 27, 2013

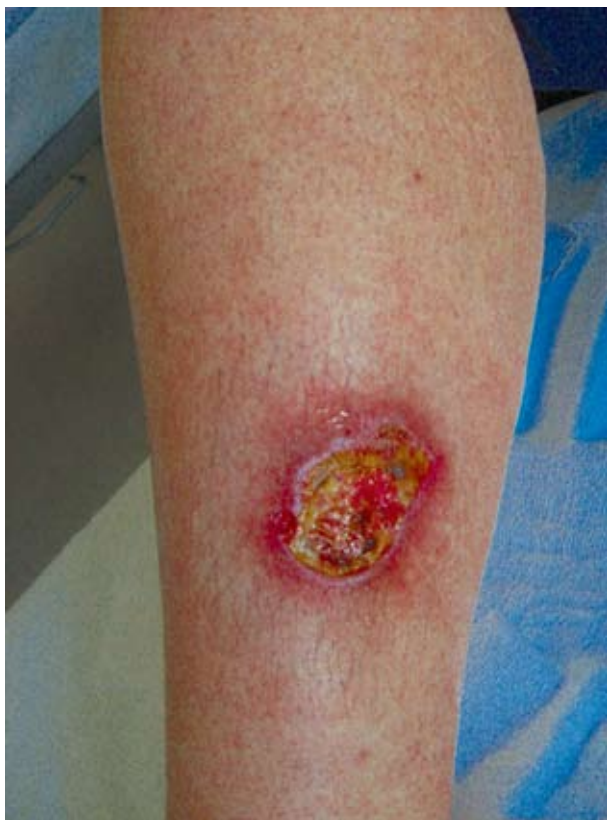

Fig. 1. Shallow ulcer on the lateral side of the patient's left lower leg.

site of the lesion and otherwise could not explain the lesion. She was hospitalized 10 months before for hypertension, hyperlipoproteinemia, hyperuricemia, and abnormal serum glucose levels. Metabolic syndrome was diagnosed in the patient 10 months before and the patient was on antihypertensive therapy. Diagnostic procedures included a swab taken from the lesion, which was sterile and a skin biopsy performed on the lesion with a nonspecific histopathologic finding of a crust. She was treated with systemic oral antibiotics and topical ointments. The patient's follow up was assigned in 7 days but the patient came a month later with an enlarged skin lesion, measuring 5x3.5 cm, with a yellowish-brown non-secernating sediment, clinically still appearing as a typical pyoderma gangrenosum (Fig. 1).

The well marked borders of the lesion and the surrounding skin were erythematous and very painful. After long persuasion, the patient was admitted to the hospital. Repeat skin biopsy from the edge of the le-

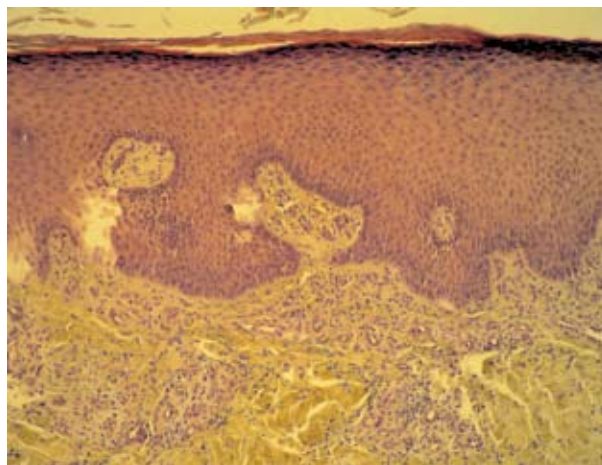


Fig. 2. Hyperplastic epidermis on the surface of the lesion and inflammatory infiltrate of mononuclears in the dermis. (hematoxylin-eosin, X100)

sion revealed hyperplastic epidermis on the surface of the lesion, a well vascularized papillary dermis, and inflammatory infiltrate of mononuclears and neutrophils throughout the dermis (Fig. 2).

Repeat swab culture from the lesion was also sterile. Duplex ultrasonography of pelvic and lower limb arteries and veins showed no signs of vascular illness or trauma. Erythrocyte sedimentation rate and C-reactive protein were within the reference range. The levels of IgE and anti-streptolysin O titers were increased. In addition, chest x-ray, spirometry, x-ray of the left lower limb and abdominal ultrasound were performed, showing no abnormalities. This outcome of clinical tests raised our suspicion of a factitious

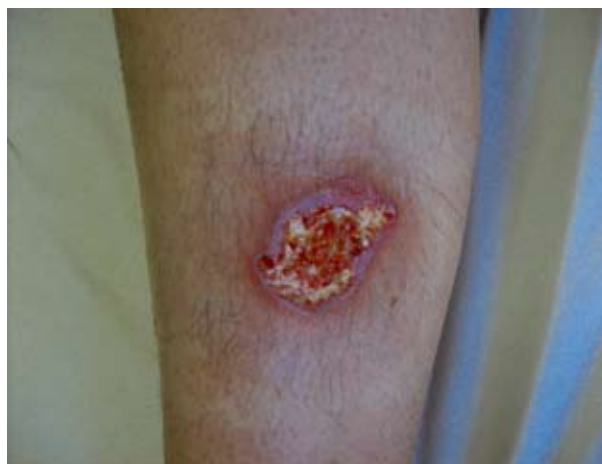

Fig. 3. Wound improvement after occlusive bandaging.

disorder. As for therapy, we therefore used a marked occlusive bandaging impregnated with normal saline. Within a few days, the wound showed signs of improvement (Fig. 3).

The patient was still unable to explain how the lesion had occurred. Noticeable to us was that during the patient's hospital stay there were no visiting family members or friends despite her being in hospital for 14 days. Psychiatric examination was undertaken, which revealed a primarily neurotic personality structure and further psychological testing and psychiatric follow-up was advised to the patient. The diagnosis of dermatitis artefacta was supported by the patient partly admitting self-injury to the psychiatrist. On the follow up at two weeks after hospitalization, the patient came with a wrapped left leg. She was bragging that she facilitated herself not to 'pick' the skin by having a wrapped leg almost the whole time. Merely erosion in a dimension of a big coin was yet present on her left lower leg.

Discussion

In the literature, the prevalence of factitious disorders varies from 0.05% to 0.4%¹⁰. Self-injury behavior is more typical in women, especially during puberty and in young women, as in our patient. Being a medical nurse by profession certainly played an important role in choosing the means and localization of self-injuries in our patient. Patient skin damages occur in dissociative states, after which they do not remember or they repress the event¹⁴. When they picture the beginning of the skin change, they cannot remember how the skin change started. Patients seem emotionally uninvolved while they describe the history of the disease. Our patient reported severe pain but during biopsy procedure she was calm and without pain grimace. Furthermore, during hospital stay she never asked for analgesics. Usually the family of a patient with factitious disorders is annoying, always trying and complaining about the medical care taken and the physician, which was not the case in our patient.

A primarily neurotic personality structure revealed by the psychiatrist and the patient's partly admitting self-injury point to the diagnosis of dermatitis artefacta syndrome¹⁵. Psychiatric consultation is essential for an accurate diagnosis and therapy of various types of factitious disorders. No intention of committing suicide

is a very important axiom of factitious disorders. The underlying psychiatric diagnoses such as impairment of impulse control or other psychiatric conditions like depressive and anxiety disorders are characteristic of dermatitis artefacta syndrome¹⁶. The most common disorder is skin-picking syndrome in which patients scratch, 'pick' and destroy their skin. Psychovegetative lability is an attribute of those patients who are unable to resist impulses and feel pleasure or relaxation after repeated auto-mutilating acts. In this way, they relieve acute emotional tension or stress. Behavior therapy, relaxation techniques and psychological education of patients or their parents are required in the therapeutic approach in patients with dermatitis artefacta.

In conclusion, 'having a third eye or a sixth sense' is necessary to impeach dermatitis artefacta. It is a rare disorder but probably often unrecognized. Clinical and histopathologic findings are crucial pathways for making the diagnosis of dermatitis artefacta. It is also very important for the clinician to learn to use a classification system for psychodermatologic disorders, since such conditions are diverse and quite prominent in any dermatologic practice, ranging from rare psychotic delusions of parasitosis to much more often unrealistic expectations in patients undergoing corrective dermatologic treatments¹⁷. Liaison psychiatry, through its multidisciplinary approach involving usually the dermatologist, psychiatrist and the patient's family physician, can reaffirm the diagnosis of dermatitis artefacta and provide necessary psychotherapy. In case of defined underlying psychiatric disorders such as anxiety disorders, depression or psychosis, additional psychopharmacological therapy, including anxiolytics, antidepressants, anti-psychotics and mood stabilizers, will be helpful¹⁸.

References

1. KOO JYM, HAN A. Psychocutaneous diseases. In: BOLOGNIA JL, JORIZZO JL, RAPINI RP, editors. *Dermatology*. Edinburgh: Mosby, 2003;111-21.
2. GATTU S, RASHID RM, KHACHEMOUNE A. Self-induced skin lesions: a review of dermatitis artefacta. *Cutis* 2009;84:247-51.
3. CHOUDHARY SV, KHAIRKAR P, SINGH A, *et al.* Dermatitis artefacta: keloids and foreign body granuloma due to overvaluated ideation of acupuncture. *Indian J Dermatol Venerol Leprol* 2009;75:606-8.
4. FEILY A, NAMAZI MR, SABOKTAKIN M, *et al.* Self-

- inflicted non-healing genital ulcer: a rare form of factitious disorder. *Acta Dermatoven APA* 2009;18:83-5.
5. SOO JK, MARSDEN RA. A hand in the diagnosis of persistent facial ulceration. *Clin Exp Dermatol* 2005;30:729-30.
 6. OBASI OE, NAGUIB M. Dermatitis artefacta: a review of 14 cases. *Ann Saudi Med* 1999;19:223-7.
 7. ILTERN, ADISEN E, GURER MA, *et al.* Dermatitis artefacta masquerading as pyoderma gangrenosum. *Int J Dermatol* 2008;47:975-7.
 8. HARRIES MJ, McMULLEN E, GRIFFITHS CEM. Pyoderma gangrenosum masquerading as dermatitis artefacta. *Arch Dermatol* 2006;142:1509-10.
 9. SNEDDON IB. Dermatitis artefacta. *Proc R Soc Med* 1977;70:754-5.
 10. HARTH W, GIELER U, KUSNIR D, TAUSK FA. Primarily psychogenic dermatoses. In: HARTH W, GIELER U, KUSNIR D, TAUSK FA, editors. *Clinical management in psychodermatology*. Berlin-Heidelberg: Springer-Verlag, 2009;9-30.
 11. MILLER J, YENTZER BBA, CLARK A, *et al.* Pyoderma gangrenosum: a review and update on new therapies. *J Am Acad Dermatol* 2009;62:46-54.
 12. WOLFF K, JOHNSON RA, SUURMOND D. Miscellaneous epidermal disorders: pyoderma gangrenosum. In: WOLFF K, JOHNSON RA, SUURMOND D, editors. *Fitzpatrick's color atlas and synopsis of clinical dermatology*, 5th edn. New York: McGraw-Hill Medical Publishing Division, 2005;152-5.
 13. AHMADI S, POWELL FC. Pyoderma gangrenosum: uncommon cases. *Clin Dermatol* 2005;23:612-20.
 14. MOFFAERT MV. The spectrum of dermatological self mutilation and self destruction including dermatitis artefacta and neurotic excoriations. In: KOO JYM, LEE CS, editors. *Psychocutaneous medicine*. New York: Marcel Dekker Inc., 2003;169-90.
 15. HARTH W, TAUBE KM, GIELER U. Factitious disorders in dermatology. *J Dtsch Dermatol Ges* 2010;8:361-72.
 16. HARTH W, MAYER K, LINSE R. The borderline syndrome in psychosomatic dermatology. Overview and case report. *JEADV* 2004;18:503-7.
 17. LIPOZENČIĆ J, BUKVIĆ-MOKOS Z. Corrective dermatology today. *Acta Clin Croat* 2010;49:519-23.
 18. BASAVARAJ KH, NAVYA MA, RASHMI R. Relevance of psychiatry in dermatology: present concepts. *Indian J Psychiatry* 2010;52(3):270-5.

Sažetak

ARTEFAKTNI DERMATITIS: PRIKAZ SLUČAJA

T. Gregurek Novak, T. Duvančić i M. Vučić

Samoozljeđivajuće ponašanje postaje učestalije kod bolesnika koji traže dermatološku skrb. Psihokutani poremećaji obuhvaćaju širok raspon dermatoloških stanja kojima je zajednička važna uloga psiholoških čimbenika. Sindrom artefaktnog dermatitisa je obilježen nesvjesnim samoozljeđivanjem, dok sindrom paraartefaktnog dermatitisa označava manipulaciju određene postojeće dermatoze. Svjesno izazivanje ozljede u svrhu stjecanja materijalne koristi smatra se simuliranjem. Ovdje prikazujemo slučaj 20-godišnje bolesnice s iznenadnom boli i ovalnim, žučkastim defektom kože na lijevoj potkoljenici, 3x3,5 cm u promjeru, s eritematoznim, jasno ograničenim rubom, okruženim eritematoznom, bolnom kožom, što podsjeća na piodermu gangrenozum. Bolesnica je imala klinički tipičan prikaz kože, ali s atipičnim terapijskim ishodom. Postavljena je dijagnoza artefaktnog dermatitisa. Liason psihijatrija može potvrditi dijagnozu artefaktnog dermatitisa i omogućiti potrebnu psihofarmakološku terapiju i psihoterapiju.

Ključne riječi: *Artefaktni dermatitis; Pioderma gangrenozum; Liason psihijatrija*