

Influence of Hydrogenecalcium Salts of Oxidized Cellulose on MMP-2, MMP-9 and TNF- α Production and Wound Healing in Non-Healing Wounds

Jana Frankova, Dominika Diamantova², Jana Vrbkova³, Jitka Ulrichova¹

¹Department of Medical Chemistry and Biochemistry, Faculty of Medicine and Dentistry, Palacky University Olomouc; ²Department of Dermatovenerology, Olomouc Military Hospital; ³Department of Mathematical Analysis and Applications of Mathematics, Faculty of Science, Palacky University Olomouc, Olomouc, Czech Republic

Corresponding author:

Jana Frankova, PhD
Department of Medical Chemistry and Biochemistry
Faculty of Medicine and Dentistry, Palacky
University Olomouc
Hnevotinska 3
Olomouc 775 15
Czech Republic
frankova0@seznam.cz

Received: October 30, 2012

Accepted: November 15, 2013

SUMMARY Levels of matrix metalloproteinase-2 (MMP-2), matrix metalloproteinase-9 (MMP-9) and tumor necrosis factor- α (TNF- α) may influence wound healing and wound closure in non-healing wounds. The aim of the study was to test the hypothesis that hydrogenecalcium salts of oxidized cellulose change the production of matrix metalloproteinases (MMPs) and TNF- α , wound size and number of bacterial strains in non-healing wounds. We analyzed MMP-2, MMP-9 and TNF- α in the wound fluid from 20 patients by ELISA every fourteen days over six weeks. Wound size, pain, wound closure and bacterial strains in the wound were also investigated. The wound size was reduced in 14 patients and pain in 16 patients. Bacterial contamination of the wound decreased significantly after treatment. The level of MMP-2 correlated with TNF- α production. The level of MMP-9 was unchanged during the healing period. We conclude that hydrogenecalcium salts of oxidized cellulose have a favorable effect on the reduction of bacterial contamination, wound size and pain.

KEY WORDS: MMP-2, MMP-9, TNF- α , chronic wound, oxidized cellulose

INTRODUCTION

The wound healing process can be divided into phases of inflammation, proliferation and remodeling (1). During the inflammatory phase, neutrophils and macrophages, phagocytes, bacteria and debris secure proper function of the immune system. In the proliferation phase, fibroblasts begin to produce collagen into the extracellular matrix (ECM), new blood vessels are formed, and the provisional ECM controls the migration of cells. During the remodeling phase, fibroblasts reorganize and synthesize the collagen matrix, modu-

late into myofibroblasts, and the wound begins to contract (2). The formation of new collagen is controlled by matrix metalloproteinases (MMPs) (3). The balance between the activities of MMPs and tissue inhibitors of MMPs is also critical to wound repair and remodeling. Several cytokines like interleukin 1 (IL-1) and tumor necrosis factor- α (TNF- α) are inducers of MMPs (4). Although the presence of MMPs is essential for wound maturation, the presence of MMPs may also be responsible for the inability of chronic wounds to heal.

Typical non-healing wounds are of four types: pressure ulcers, diabetic ulcers, ischemic ulcers and venous ulcers (5). The ulcers of venous etiology arise as a result of chronic venous insufficiency. The prevalence of this diagnosis is around 1% of the population of European countries (6). The ulcers of arteriovenous etiology, apart from venous insufficiency are also caused by ischemia. Trophic changes of the skin and skin adnexa arise, as well as non-healing ulcers. Ischemic changes are mostly observed on the sacral parts of the body. Decubitus ulcers, i.e. wounds caused by local pressure on the tissue, are usually found in the so-called endangered areas.

The aim of the study was to evaluate changes in the matrix metalloproteinase-2 (MMP-2), matrix metalloproteinase-9 (MMP-9) and TNF- α production during the process of wound healing in non-healing wounds after treatment with hydrogencalcium salts of oxidized cellulose.

PATIENTS AND METHODS

Hydrogencalcium salts of oxidized cellulose

Twenty patients with non-healing wounds were treated with gauze hydrogencalcium salts of oxidized cellulose (Traumacel Biodress, Bioster, a.s., Veverska Bítýska, Czech Republic) at Department of Dermatovenerology, Military Hospital in Olomouc. An informed consent was obtained from the patients and the study was approved by the Military Hospital Ethics Committee. Exclusion criteria were decompensated diabetes mellitus, decompensated ischemic heart disease, excessive anemia, excessive hypoproteinemia, cancer; abuse of prescription and nonprescription drugs and alcohol, immunosuppressive treatment, use of other medications and/or substances for wound treatment, known allergy to the preparation tested, size of ulcer smaller than 2 cm, and participation in clinical tests within the last 30 days.

The wound was treated with gauze of hydrogencalcium salt of oxidized cellulose. Before dressing, the wound was treated with physiological solution for 10 minutes. The surrounding area was treated with a neutral cream or paste and dressing was cut to the shape of the wound and inserted in the wound. Then

Table 1. Patient characteristics

Patients (N)	20
Age (mean \pm SD; yrs)	65.7 \pm 7.1
Gender M/F	10/10
Disease (n)	Venous leg ulcers, 15 Arteriovenous leg ulcers, 3 Decubitus ulcer, 1 Trophic leg ulcer, 1

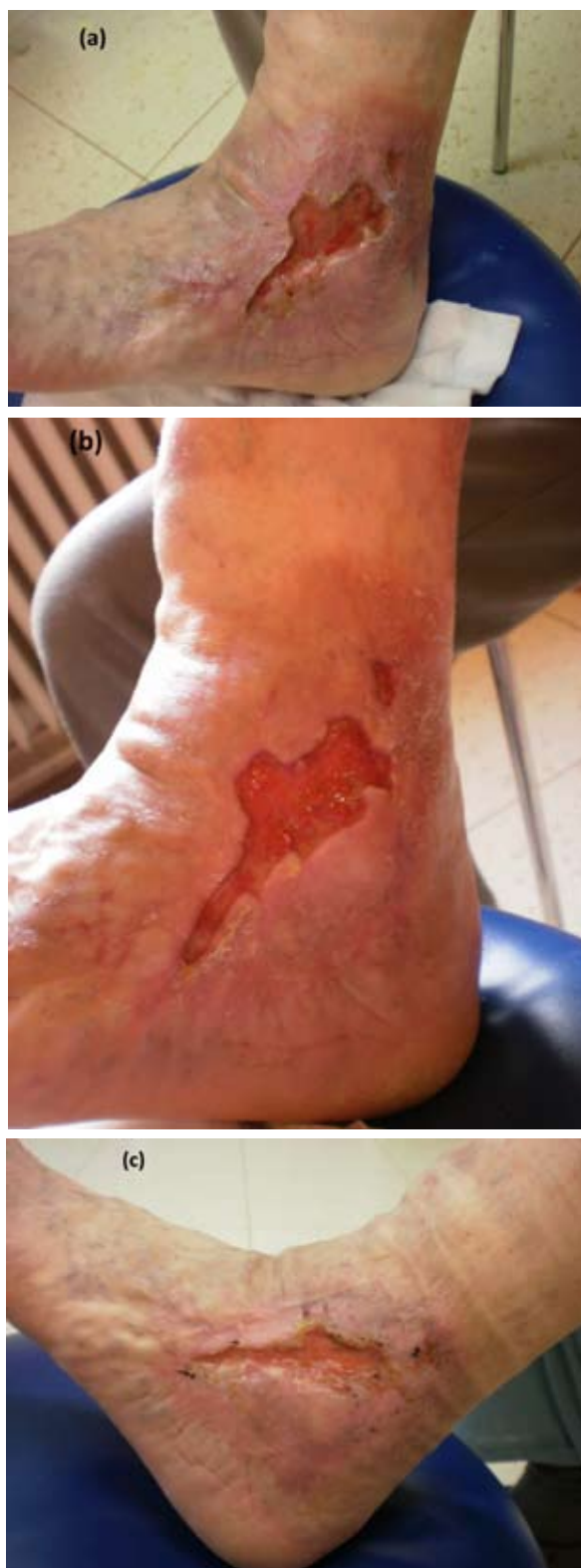

Figure 1. A 53-year-old man had a painful ulcer of venous etiology on the outer ankle of the left lower extremity for 7 months. The ulcer was photographed before treatment (a); 14 days after treatment initiation (b); and 6 weeks after treatment (c).

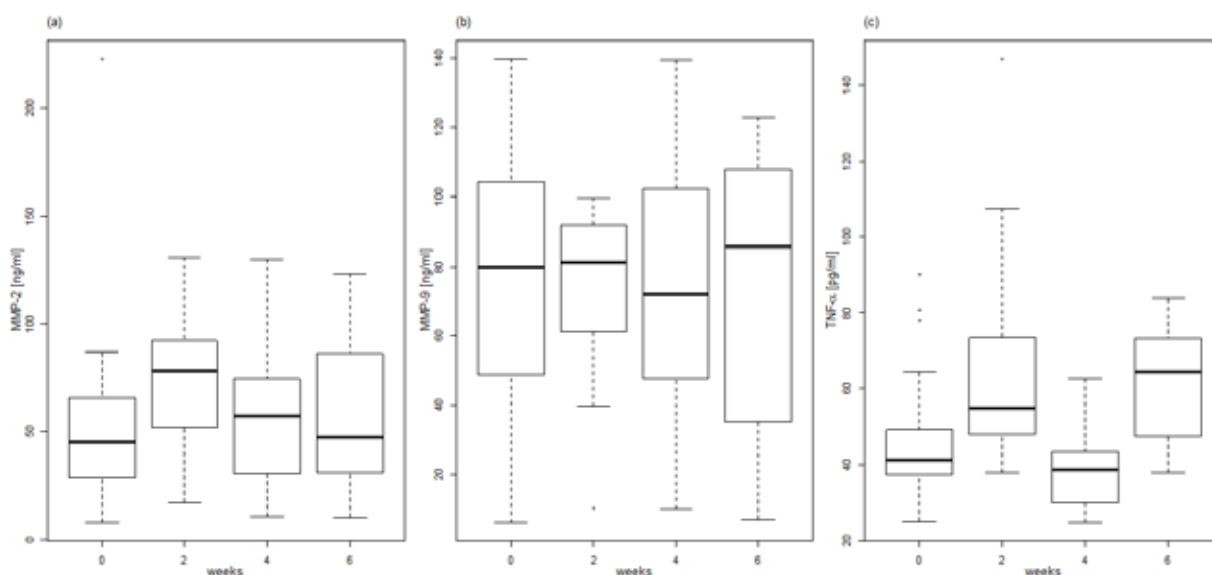


Figure 2. Production of MMP-2 (a), MMP-9 (b), and TNF- α (c) during treatment.

the wound was dressed with a secondary dressing and compressed according to wound type. Redressing was carried out after 24, 48 or 72 hours, according to dressing saturation.

Four examinations were performed in each patient, the first one at the beginning of the study. During each check-up, the condition of the wound was examined and a square centimeter of the tested dressing was cut out from the middle and placed into a labeled test tube. Each wound was photographed and skimming of the wound was taken for microbiological examination. All patients were allowed to use their general medication such as vasopharmaceutical therapy and analgesics. No antibiotics were used.

Sample collection and preparation

Wound fluid was collected from patients with non-healing wounds by absorption onto a piece of gauze hydrogencalcium salts of oxidized cellulose, which was placed directly on the wound. Gauze samples were collected every 14 days during bandage and were frozen at -80°C in RIPA buffer with protease inhibitors (Sigma-Aldrich, USA). Before measurement, the gauze was eluted in 1 mL of RIPA buffer with protease inhibitors and diluted according to the protocol for MMP and TNF- α detection.

Table 2. Pain level and wound size

Therapy time	Week 0	Week 6
Pain level (mean \pm SD)	5 \pm 2.2	1.9 \pm 1.7
Wound size (mean \pm SD), cm ²	40.9 \pm 45.9	33.9 \pm 47.6

MMPs and TNF- α determination

Total MMP-2 (pro-, active- and TIMP complexed MMP-2), total MMP-9 (pro-, active- and TIMP complexed MMP-9) and TNF- α in supernatants were determined by sandwich ELISA according to the manufacturer's protocol for MMP-2 (total), MMP-9 (total) and TNF- α (RD system, USA). The color product is measured at 450 nm with a reference wavelength of 570 nm, using a microplate reader (Sunrise Remote, Tecan, Austria).

Statistical analysis

Changes in the production of TNF- α , MMP-2 and MMP-9 in time were statistically evaluated by the nonparametric two-tailed one sample Wilcoxon test for differences in time with the level of significance. Absolute values of the TNF- α , MMP-2 and MMP-9 parameters are graphically presented by boxplots (Fig. 2).

RESULTS

The study included twenty patients (10 men and 10 women) and 16 patients completed the study. The patients with non-healing wounds (venous leg ulcers 15, arteriovenous leg ulcers 3, decubitus ulcer 1, trophic leg ulcer 1) were treated with gauze hydrogencalcium salts of oxidized cellulose over 6 weeks (Table 1). The median age was 65.7 (SD \pm 7.1) years. Wound size was reduced by about 46.5% (SD \pm 36.1); in 14 patients, wound size was reduced during the healing period and two patients showed no changes in wound size (Table 2). A representative photo shows

Table 3. Aerobic bacterial strains in the wound

Week 0		Week 6	
<i>Enterococcus faecalis</i> , n	8	<i>Proteus mirabilis</i> , n	3
<i>Staphylococcus aureus</i> , n	7	<i>Enterococcus faecalis</i> , n	2
<i>Proteus mirabilis</i> , n	6	<i>Staphylococcus aureus</i> , n	2
<i>Pseudomonas aeruginosa</i> , n	5	<i>Enterococcus</i> sp., n	2
<i>Escherichia coli</i> , n	4		
<i>Morganella morganii</i> , n	4		
<i>Klebsiella oxytoca</i> , n	2		
<i>Proteus vulgaris</i> , n	2		
<i>Streptococcus beta-hemol.</i> , n	2		

n = number of patients

wound size reduction and wound healing (Fig. 1). The level of pain was determined on a 10-point scale (10 meaning maximum pain). Pain level decreased in all 16 patients. All patients were examined for the presence of aerobic and anaerobic bacterial strains (Tables 3 and 4). The presence of aerobic bacterial strains was reduced after 6-week treatment. In 55% of patients, bacterial strains changed, in 15% they were the same, in 10% of patients only some bacterial strains were changed, and 10% of patients dropped out. In 15 patients, the wounds were free from anaerobic bacterial strains.

Wound fluid was extracted from gauze from all patients for MMP-2, MMP-9 and TNF- α determination. The production of TNF- α was significantly increased in patients after 2 weeks ($p=0.03528$) and 6 weeks ($p=0.01099$) of treatment. As shown in Figure 2, significant results were also obtained for MMP-2 production after 2 weeks of treatment ($p=0.02026$), although MMP-2 production was not significant in the rest of the study period. The production of MMP-9 was unchanged throughout the healing period.

DISCUSSION

Non-healing wounds are defined as those wounds that last for more than 6 weeks (7). Standard therapy for non-healing wounds, mainly ulcers, is compression and topical dressing. The selection of dressing

is complicated (8). The treatment of non-healing wounds is aimed at reducing the levels of proteolytic enzymes in the wound bed. This should decrease tissue destruction and prevent growth factor degradation, leading to an overall increase in granulation tissue formation and faster wound repair. In our study, we used a dressing of hydrogencalcium salt of oxidized cellulose that supports decrease in MMP production. The mechanism by which this material reduces protease activity is unclear. Studies comparing wound fluid from healing and non-healing wounds have found that non-healing wounds have a high concentration of proinflammatory cytokines (IL-1 and TNF- α) and MMPs, and low levels of protease inhibitors and growth factors (9). The level of MMP activity in wound fluid samples collected from patients has been shown to decrease significantly as healing progresses (10). Falanga reports that fluid collected from non-healing wounds blocks cellular proliferation and angiogenesis and contains excessive amounts of MMPs (11). Some studies found the levels of MMP-2 and MMP-9 to be higher in non-healing wounds than in acute wounds. Of interest in inflammatory models are MMP-2 and MMP-9, which degrade type IV collagen, a major component of basement membrane (12). However, changes in the production of cytokines, growth factors and MMPs in wound fluid during the wound healing process are not described.

Table 4. Anaerobic bacterial strains in the wound

Week 0		Week 6	
<i>Veillonella</i> sp., n	1	<i>Bacteriodes fragilis</i> , n	1
<i>Bacteriodes</i> sp., n	1	<i>Bacteriodes capillosus</i> , n	1
<i>Peptococcus anaerobius</i> , n	1	<i>Bacteriodes</i> sp., n	1
<i>Acidaminococcus</i> sp., n	1		
<i>Fusobacterium ureolyticus</i> , n	1		
<i>Bacteriodes ureolyticus</i> , n	1		
<i>Bacteriodes capillosus</i> , n	1		
<i>Eubacterium lentum</i> , n	1		

n = number of patients

All wounds become contaminated by bacteria from the surrounding skin, local environment, etc. (13). Non-healing wounds have a complex colonizing flora that changes over time. Hence, non-healing infected wounds are polymicrobial and of mixed aerobic/anaerobe populations. The first is the interplay between the aerobic and anaerobe species within wounds. Open wound pathogens are commonly considered to be aerobic, essentially staphylococci and streptococci species (14). A recent *in vitro* research has shown how anaerobic species cause healing delay by inhibiting fibroblast and keratinocyte proliferation, keratinocyte wound repopulation and endothelial tubule formation (15). One study evaluated the occurrence of new bacterial groups in wounds after treatment (16). Debats *et al.* found, like us, the following species in non-healing wounds: *Staphylococcus aureus*, *Pseudomonas aeruginosa*, *Escherichia coli*, and *Proteus mirabilis* (17).

CONCLUSION

The results presented here show that hydrogen-calcium salt of oxidized cellulose change the production of MMP-2 and TNF- α , wound size, bacterial contamination, and pain.

ACKNOWLEDGMENT

This work was supported by the grant MSM 6198959216.

References

1. Kondo T, Ishida Y. Molecular pathology of wound healing. *Forensic Sci Int* 2010;203:93-8.
2. Li J, Chen J, Kirsner R. Pathophysiology of acute wound healing. *Clin Dermatol* 2007;25:9-18.
3. Valenti DMZ, Silva J, Teodoro WR, Velosa AP, Mello SB. Effect of topical clay application on the synthesis of collagen in skin: an experimental study. *Clin Exp Dermatol* 2012;37:164-8.
4. Eming S, Smola H, Hartmann B, Malcau G, Wegner R, Krieg T, *et al.* The inhibition of matrix metalloproteinase activity in chronic wounds by a polyacrylate superabsorber. *Biomaterials* 2008;29:2932-40.
5. Jaul E. Non-healing wounds: the geriatric approach. *Arch Gerontol Geriatr* 2009;49:224-6.
6. Klode J, Stoffels I, Weindorf M, Weindorf M, Dissemond J. Relationship between the seasonal onset of chronic venous leg ulcers and climatic factors. *J Eur Acad Dermatol Venereol* 2011;25:1415-9.
7. Reichenberg J, Davis M. Venous ulcers. *Sem Cutan Med Surg* 2005;24:216-26.
8. Kantor J, Margolis DJ. Management of leg ulcers. *Sem Cutan Med Surg* 2003;22:212-21.
9. Charles AC, Romanelli P, Martinez ZB, Roberts B, Kirsner RS. Tumor necrosis factor- α in non-healing venous leg ulcers. *J Am Acad Dermatol* 2009;60:951-5.
10. Mwaura B, Mahendran B, Hynes N, Defreitas D, Avalos G, Adegbola T, *et al.* The impact of differential expression of extracellular matrix metalloproteinase inducer, matrix metalloproteinase-2, tissue inhibitor of matrix metalloproteinases-2 and PDGF-AA on the chronicity of venous leg ulcers. *Eur J Vasc Endovasc Surg* 2006;3:306-10.
11. Falanga V. The chronic wound: impaired healing and solutions in the context of wound bed preparation. *Blood Cells Mol Dis* 2004;32:88-94.
12. Jang YH, Sim JH, Kang HY, Kim YC, Lee ES. Immunohistochemical expression of matrix metalloproteinases in the granulomatous rosacea compared with non-granulomatous rosacea. *J Eur Acad Dermatol Venereol* 2011;25:544-8.
13. Siddiqui AR, Bernstein JM. Chronic wound infection: facts and controversies. *Clin Dermatol* 2010;28:519-26.
14. Kingsley A. The wound infection continuum and its application to clinical practise. *Ostomy Wound Manag* 2003;49:S1-7.
15. Stephens P, Wall I, Wilson M, Hill KE, Davies CE, Hill CM, *et al.* Anaerobic cocci populating the deep tissues of chronic wounds impair cellular wound healing responses *in vitro*. *Br J Dermatol* 2003;148:456-66.
16. Trengone N, Stacey M, McGeachie D, Mata S. Qualitative bacteriology and leg ulcer healing. *J Wound Care* 1996;5:277-80.
17. Debats IBJG, Booi D, Deutz NEP, Buurman WA, Boeckx WD, van der Hulst RR. Infected chronic wounds show different local and systemic arginine conversion compared with acute wounds. *J Surg Res* 2006;134:205-14.