

Omenn Syndrome: Two Case Reports

**Nadia Siala¹, Ons Azzabi¹, Hakima Kebaier¹, Ridha Mrad², Olfa Rebah¹,
Ridha Barbouche³, Mohamed Bejaoui⁴, Sonia Halioui¹, Ahmed Maherzi¹**

¹Department of Pediatrics, Mongi Slim Hospital, La Marsa; ²Department of Genetics, Charles Nicolles Hospital, ³Department of Immunology, Pasteur Institute, ⁴Department of Pediatric Hematology, Transplant Center, Tunis, Tunisia

Corresponding author:

Nadia Siala, MD
Department of Pediatrics
Mongi Slim Hospital
Sidi Daoud 2046-La Marsa
Tunisia
sialanad@yahoo.com

Received: August 21, 2012

Accepted: July 18, 2013

SUMMARY Omenn syndrome is a variant of combined severe immunodeficiency due to mutations in RAG genes. It is characterized by polymorph symptoms and lethal outcome. We report on two cases of Omenn syndrome. Infants were aged 50 and 46 days. The clinical and biological signs were typical and complete in the first case. In the second case, only the cutaneous signs were present. Diagnosis was confirmed by genetic study. The Rag1 T631 mutation was found in these two patients. Hematopoietic stem cell transplantation could not be done and the evolution was fatal in both cases because of severe infectious episodes. Prenatal diagnosis was performed in the two families and each family has currently a healthy child. In conclusion, early diagnosis of Omenn syndrome may avoid infectious complications responsible for delay in therapeutic management. Genetic study confirms the diagnosis. The treatment usually consists of hematopoietic stem cell transplantation in association with immunosuppressive drugs. Prenatal diagnosis is very important to allow parents to have healthy children.

KEY WORDS: Omenn syndrome, severe combined immunodeficiency, bone marrow transplantation, RAG mutations

INTRODUCTION

Omenn syndrome (OS) is an autosomal recessive combined immunodeficiency (1). It is characterized by a diffuse erythematous scaly rash, recurrent severe infections, protracted diarrhea, lymphadenopathy, hepatosplenomegaly, lymphocytosis, eosinophilia and lymphocytic infiltration in the skin, gut, liver, and spleen (2). Immune defects are very diverse including different degrees of eosinophilia and IgE levels, hypogammaglobulinemia with B cell deficiency, thymic hypoplasia and reduced proliferative responses to mitogens (3-5). We report on two cases of OS occurring in infants aged 50 and 46 days.

CASE 1

A. D. was a 50-day-old male infant when admitted to the hospital. He was the first child to first-degree consanguineous parents. There was no family history of early death or immunodeficiency. The pregnancy and delivery were uneventful with birth weight of 4 kg. A few days after birth, he developed therapy-resistant dermatitis with generalized desquamative eruption and alopecia (Figs. 1 and 2). The parents brought the child for consultation to our department, when huge axillary lymphadenopathy appeared after BCG vaccination. Physical examination revealed no fever, weight 4100 g, height 56.5 cm, oral mucosal

candidiasis, diffuse and erythematous dermatitis with fistulized scalp abscess, alopecia, feet edema, lymphadenopathy and splenomegaly. Laboratory investigations revealed anemia (7.8 g/dL), leukocytosis (34 000/mm³), lymphocytosis (20 400/mm³), eosinophilia (1670/mm³), low serum protein (33 g/L), and low gammaglobulins (0.3 g/L) with high IgE (134 UI/L). Chest x-ray was normal, thymus was present. Transfontanellar brain and abdominal ultrasounds were also normal. Blood and abscess culture grew *Staphylococcus aureus*. The infant was isolated, treated with oxacillin and fluconazole, and transfused with irradiated blood.

Immunologic evaluation showed no humoral response immunity, abnormal cellular response immunity, abnormal response to mitogens and no response to antigens. OS was suspected. The infant received intravenous immunoglobulins. HLA typing showed compatibility between the patient and his father. The child was then scheduled for bone marrow transplantation. Molecular analysis revealed homozygous Rag1 Del T631 mutation. Unfortunately, the patient died from severe sepsis before marrow transplantation at the age of 93 days. Prenatal diagnosis was performed and the parents now have a healthy 2-year-old girl.

CASE 2

E. C. was a 46-day-old female infant when admitted to the hospital. She was the first child to consanguineous parents with no particular family history. At birth, she weighed 3400 g and presented diffuse erythroderma. She was BCG vaccinated at birth with no complications. From the first week of age, she developed recurrent otitis, bronchitis and gastroenteritis. She was admitted to the hospital at the age of 46 days to manage a failure to thrive. Clinical examination showed weight of 3 kg, diffuse ichthyosiform erythroderma, alopecia and absent eyebrows (Fig. 3). Blood cell count revealed microcytic hypochromic anemia (7.2 g/dL), leukocytosis (15 000/mm³) with lymphocytes (4400/mm³) and normal eosinophil rate. Weight gain was initially favorable with enteral nutrition. However, during hospitalization, she developed two episodes of severe sepsis treated with antibiotics. Control biologic parameters revealed leukocytosis (57 000/mm³) with lymphocytosis (34 000/mm³) and moderate eosinophilia (750/mm³). Chest x-ray showed absence of thymic shadow. Protein electrophoresis revealed a low serum protein concentration (38 g/L) and agammaglobulinemia.

The study of cell mediated immunity revealed complete absence of B lymphocytes with normal number of T lymphocytes. The latter showed normal

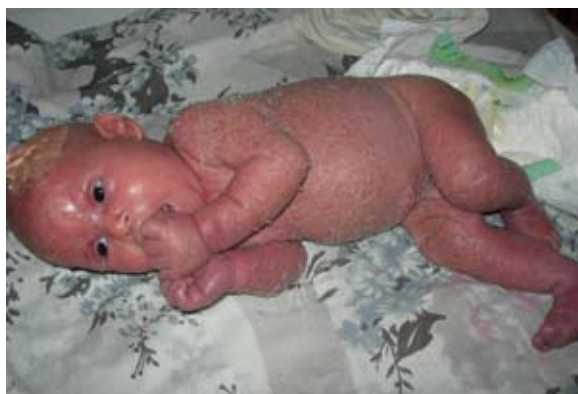

Figure 1. Generalized exfoliative dermatitis and absent eyebrows.

response to phytohemagglutinins and anti CD3, but no response to tuberculin. The diagnosis of OS was established and the infant was treated with cotrimoxazole, itraconazole and gammaglobulin infusions. Genetic study revealed homozygous Rag1 Del T631 mutation. The infant was scheduled for bone marrow transplantation, but she died at the age of four months from severe pneumonia. Prenatal diagnosis was performed and the parents now have a healthy 3-year-old girl and the mother is pregnant with a healthy fetus.

DISCUSSION

In 1965, Omenn described 12 infants in whom the major features were the onset of severe skin eruption followed by hepatosplenomegaly, lymphadenopathy, hypogammaglobulinemia, and eosinophilia in the first month of age (6). Failure to thrive and recurrent febrile illnesses progressed to a fatal outcome within six months in all cases. In our first patient, clinical findings were all typical of OS, whereas in our second patient only cutaneous manifestations were present and biologic findings were important to reveal the diagnosis.

The gradual onset of severe dermatitis, lymphadenopathy and hepatosplenomegaly as well as eosinophilia during the first and second month of life suggest that antigenic stimulation may play a central role in the clinical and immune manifestations of this disease. In our patients, immunological investigations showed severe immunodeficiency. Serum immunoglobulins were very low except for the IgE level, which was high in the first case. Lymphocyte proliferative response to mitogens was markedly depressed despite the presence of a normal number of T lymphocytes and their subsets. This is due to an intrinsic defect of their activation after antigen or

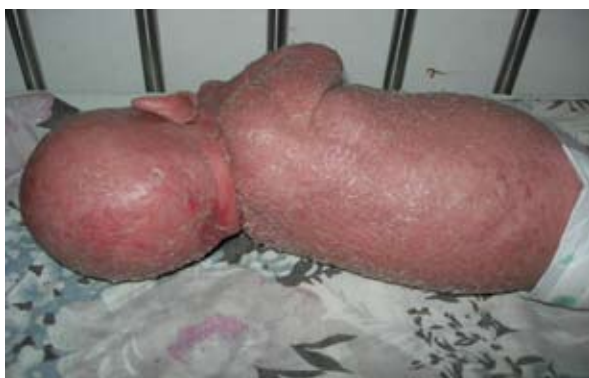

Figure 2. Alopecia associated with generalized exfoliative dermatitis.

mitogen stimulation. This can be seen in combined immunodeficiency patients as well as in other syndromes such as ataxia-telangiectasia and DiGeorge syndrome (7). OS is differentiated from severe combined immunodeficiency by additional autoimmunity and atopy (erythroderma, eosinophilia and high IgE level), which signify substantial immune dysregulation (8). OS is associated with a severe disturbance in both T- and B-cell development.

The best-characterized defects leading to OS are homozygous or compound heterozygous mutations in either recombinase-activating gene (RAG) 1 or 2, which encode RAG1 and RAG2 enzymes. Normally, RAG1 and RAG2 enzymes, which are restricted to immature lymphocytes, initiate a V(D)J (Variable, Diversity, Joining) recombination that leads to both T- and B-cell development. In fact, OS is caused by hypomorphic mutations in RAG that impair but do not abolish the process of VDJ recombination and may differentially impact on VDJ recombination activity and hence lead to a variable ability to sustain T and B cell lymphopoiesis. It is characterized by the presence of only a small number of T cell clones, which infil-

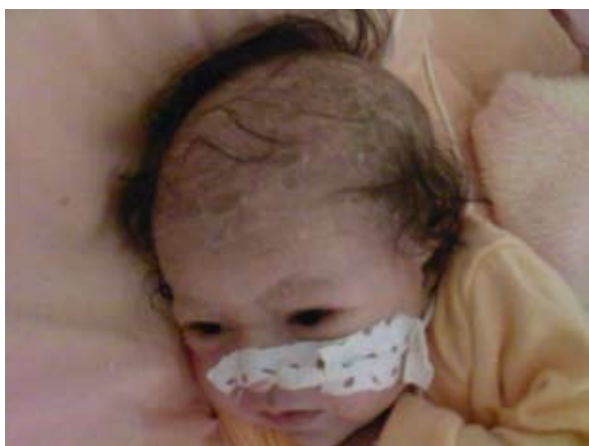


Figure 3. Alopecia and absent eyebrows.

trate the skin, gut, liver, and spleen leading to clinical manifestations. The number of peripheral blood lymphocytes can be decreased, normal, or increased with variable B cell counts and hypogammaglobulinemia (9,10).

Mutations in RAG1 or RAG 2 are found in most OS patients (11), as seen in our patients. However, other mutations have been reported, such as IL7RA gene, ARTEMIS, and RNA component of RNase mitochondrial RNA processing and DNA ligase IV mutations (12-17). The study by Wada *et al.* suggests that RAG mutation may be a genetic abnormality unique to OS and that all other mutations are associated with a variation of OS or related disorders representing a different type of immunodeficiency (18).

The prognosis of patients with OS has been improved since hematopoietic stem cell transplantation (SCT) has been introduced, although the rate of complications is high because of poor clinical status, malnutrition and infection prior to SCT in most patients (3). Immunosuppressive therapy has been used to control activation of auto reactive T lymphocytes using cyclosporin A alone or in association with topical or systemic steroids or using interferon γ in association with anti-infectious prophylaxis to improve the clinical signs while waiting for allogeneic SCT (19). Using tacrolimus has little effect in improving the symptoms (20). Therapeutic options include bone marrow transplantation or more recently cord blood stem cell transplantation; however, the mortality is still 46%. Early diagnosis of OS is very important to initiate appropriate treatment because life threatening infections can occur when bone marrow transplantation is delayed (2,21).

CONCLUSION

Severe erythroderma and alopecia are early and constant symptoms in OS. These clinical findings must indicate immunologic investigations in order to confirm this diagnosis. Early diagnosis may avoid failure to thrive and infectious complications responsible for delay in therapeutic management. Genetic study can differentiate between OS and different types of immunodeficiency and allow for prenatal diagnosis. OS is usually treated with hematopoietic stem cell transplantation along with immunosuppressive drugs. Cord blood transplantation is a successful therapeutic option in patients without a suitable donor.

ACKNOWLEDGMENT

The authors wish to thank Jean-Pierre de Villartay, INSERM U768, from Necker Hospital in Paris, who performed molecular analyses for the two children.

References

1. Montalbano M, Harville T, Dziadzio L. Early immunologic findings in Omenn syndrome. *J Allergy Clin Immunol* 2002;118:188.
2. Postigo Llorente C, Ivars Amorós J, Ortiz de Frutos FJ, Regueiro JR, Llamas Martín R, Guerra Tapia A, *et al.* Cutaneous lesions in severe combined immunodeficiency: two case reports and a review of the literature. *Pediatr Dermatol* 1991;8:314-21.
3. Junker AK, Chan K, Massing G. Clinical and immune recovery from Omenn syndrome after bone marrow transplantation. *J Pediatr* 1989;114:596-600.
4. Gruber TA, Shah AJ, Hernandez M, Crooks GM, Abdel-Azim H, Gupta S, *et al.* Clinical and genetic heterogeneity in Omenn syndrome and severe combined immune deficiency. *Pediatr Transplant* 2009;3:244-50.
5. Martinez-Martinez L, Vazquez-Ortiz M, Gonzalez-Santesteban C, Martin-Nalda A, Vicente A, Plaza AM, *et al.* From severe combined immunodeficiency to Omenn syndrome after hematopoietic stem cell transplantation in a RAG1 deficient family. *Pediatr Allergy Immunol* 2012;23:660-6.
6. Dyke MP, Marlow N, Berry PJ. Omenn's disease. *Arch Dis Child* 1991;6:1247-8.
7. Businco L, Di Fazio A, Ziruolo MG, *et al.* Clinical and immunological findings in four infants with Omenn's syndrome: a form of severe combined immunodeficiency with phenotypically normal T cells, elevated IgE, eosinophilia. *Clin Immunol Immunopathol* 1987;44:123-33.
8. Wong S, Roth B. Murine models of Omenn syndrome. *J Clin Invest* 2007;117:1213-6.
9. Cavadini P, Vermi W, Facchetti F, Fontana S. AIRE deficiency in thymus of two patients with Omenn syndrome. *J Clin Invest* 2005;115:728-32.
10. MacCuskea C, Hotte S, Le Deist F, Hirschfeld AF. Relative CD4 lymphopenia and a skewed memory phenotype are the main immunologic abnormalities in a child with Omenn syndrome due to homozygous RAG1-C2633T hypomorphic mutation. *Clin Immunol* 2009;131:447-55.
11. Marrella V, Poliani PL, Casati A, Rucci F. A hypomorphic R229Q RAG2 mouse mutant recapitulates human Omenn syndrome. *J Clin Invest* 2007;117:1260-9.
12. Gennery RA, Hodges E, Williams PA, Harris S. Omenn's syndrome occurring in patients without mutations in recombination activating genes. *Clin Immunol* 2005;116:246-56.
13. Villa A, Notarangelo LD, Roifman CM. Omenn syndrome: inflammation in leaky severe combined immunodeficiency. *J Allergy Clin Immunol* 2009;122:1082-6.
14. Giliani S, Bonfim C, De Saint Basile G, Lanzi G. Omenn syndrome in infant with IL7RA gene mutation. *J Pediatr* 2006;148:272-4.
15. Ege M, Ma Y, Manfras B, Kalwak K. Omenn syndrome due to ARTEMIS mutations. *Blood* 2005;105:4179-86.
16. Roifman MC, Gu Y, Cohen A. Mutations in the RNA component of RNase mitochondrial RNA processing might cause Omenn syndrome. *J Allergy Clin Immunol* 2006;117:897-903.
17. Kim VHD, Grunebaum E, Bates A, Roifman CM. Omenn syndrome is associated with mutations in DNA ligase IV. *J Allergy Clin Immunol* 2009;123: S14.
18. Wada T, Takei K, Kudo M, Shimura S. Characterisation of immune function and analysis of RAG gene mutation in Omenn syndrome and related disorders. *Clin Exp Immunol* 2000;119:148-55.
19. Meyer-Bahlburg A, Haas JP, Haas R, Eschrich U. Treatment with cyclosporin A in a patient with Omenn's syndrome. *Arch Dis Child* 2002;87:231-4.
20. Rego S, Kemp A, Wong M, Knight P. Omenn syndrome: therapeutic effects of cyclosporin. *J Paediatr Child Health* 2006;42:319-20.
21. Chia-Chi Hsu, Julia Yu-Yun Lee, Sheau-Chiou Chao. Omenn syndrome: a case report and review of literature. *Derm Sinica* 2011;29:50-4.