

# Palisaded Neutrophilic and Granulomatous Dermatitis in Association with Subcutaneous Nodular and Systemic Sarcoidosis

Zrinjka Paštar<sup>1</sup>, Jaka Radoš<sup>2</sup>, Ivan Pavić<sup>3</sup>, Suzana Kovačević<sup>4</sup>, Anamarija Vukasović<sup>5</sup>, Višnja Milavec-Puretić<sup>2</sup>, Jasna Lipozenčić<sup>2</sup>

<sup>1</sup>Ministry of Defense; <sup>2</sup>Department of Dermatology and Venereology, University Hospital Center Zagreb and University of Zagreb School of Medicine; <sup>3</sup>Zagreb Children's Hospital, Zagreb; <sup>4</sup>Department of Ophthalmology, Zadar General Hospital, Zadar; <sup>5</sup>Department of Nuclear Medicine, Dubrava University Hospital, Zagreb, Croatia

## Corresponding author:

Zrinjka Paštar, MD, PhD  
Ministry of Defense  
Av. Gojka Šuška 6  
HR-10000 Zagreb  
Croatia  
zpastar@hi.htnet.hr

Received: March 13, 2012

Accepted: November 10, 2013

**SUMMARY** Palisaded neutrophilic granulomatous dermatitis (PNGD) is a rare entity that has been clearly defined neither clinically nor histopathologically. PNGD has been associated with some immune-mediated disorders such as rheumatoid arthritis, systemic lupus erythematosus, systemic vasculitis, Behçet's disease, as well as with lymphoproliferative conditions, bacterial endocarditis, sarcoidosis, and various drugs. We present a 44-year-old Caucasian woman with roundish erythematous-livid plaque and erythematous papules on the left calf that were present for three months. Histopathology of plaque lesion showed palisading neutrophilic and granulomatous dermatitis. Subsequently, she developed a firm and tender nodule on the right calf. Histopathology of the nodule showed typical naked sarcoid granulomas in the dermis and subcutis. Additionally, the patient developed non-tender subcutaneous nodules on the cheeks, submandibular region and left breast with normal overlying skin, which were histopathologically diagnosed as sarcoid granuloma. Red eyes and lower visual acuity on the right eye were diagnosed as anterior uveitis. Therefore, systemic sarcoidosis was established. This is a case of PNGD described in an adult patient with sarcoidosis with cutaneous, breast, eye and lung involvement established by clinical, radiographic, laboratory, and histopathologic criteria.

**KEY WORDS:** palisaded neutrophilic granulomatous dermatitis, sarcoidosis, systemic sarcoidosis

## INTRODUCTION

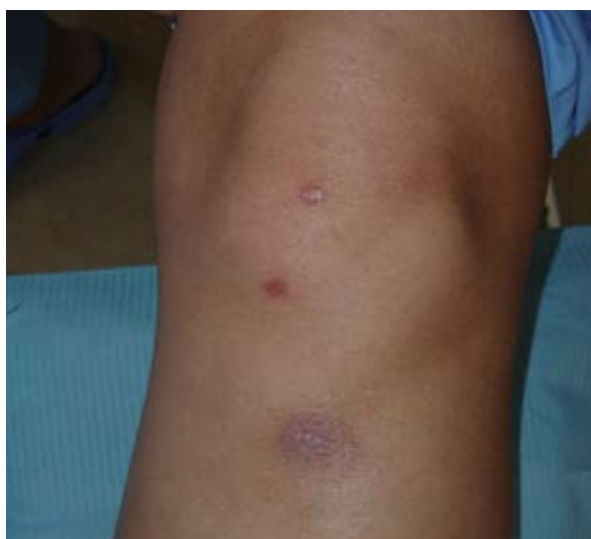Palisaded and neutrophilic granulomatous dermatitis (PNGD) is a rare inflammatory dermatosis (1). Synonyms are Churg Strauss granuloma, interstitial granulomatous dermatitis with arthritis, linear subcutaneous bands, rheumatoid papules, linear granuloma annulare, rheumatoid granuloma, superficial ulcerating rheumatoid necrobiosis, necrobiotic granuloma, palisading granuloma, and

cutaneous extravascular necrotizing granuloma (2,3). PNGD is associated with immune-mediated disorders such as rheumatoid arthritis, systemic lupus erythematosus, systemic vasculitis, Behçet's disease, as well as with lymphoproliferative conditions, bacterial endocarditis, diabetes mellitus and coeliac disease, sarcoidosis, and drugs such as allopurinol (1-12).

We present the clinicopathologic findings in a 44-year-old Caucasian woman with a newly diagnosed systemic sarcoidosis, who presented with non-ulcerating plaque and papular lesion on the left calf. Based on the histopathologic findings, the patient was diagnosed with PNGD in association with systemic and subcutaneous sarcoidosis.

### CASE REPORT

A 44-year-old Caucasian woman with no history of taking any drugs presented for evaluation of roundish erythematous-livid plaque and erythematous papule on the left calf that had been present for three months (Fig. 1). Therapy with topical corticosteroids did not lead to regression. Histopathology of the plaque lesion indicated PNGD (Fig. 2a,b). Subsequently she developed a firm and tender nodule on the right calf (Fig. 3). Histopathology of the nodule showed typical naked sarcoid granulomas in the dermis and subcutis (Fig. 4). Additionally, the patient developed non-tender subcutaneous nodules on the cheeks, submandibular region and left breast, with normal overlying skin. Mammography and ultrasonography showed a nodular lesion localized in the left breast. Biopsy microscopy of the breast and cheek revealed sarcoid granuloma. Additionally, the patient reported red eyes and lower visual acuity on the right eye. Ophthalmologic slit lamp examination revealed small granulomatous precipitation on the endothelia of the right eye cornea, diagnosed as anterior uveitis. Laboratory tests revealed normal calcium level in serum and urine, normal angiotensin converting enzyme and lysozyme, and normal x-ray of long bones. PPD test was hyperergic. Interferon-gamma release assay (performed by

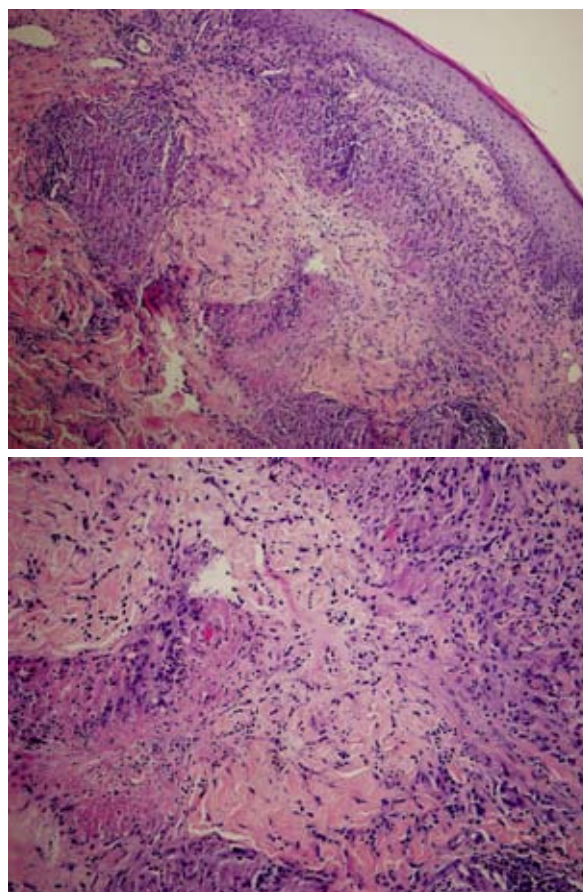


**Figure 1.** Roundish erythematous-livid plaque and two erythematous papules on the left calf. The plaque was biopsied.

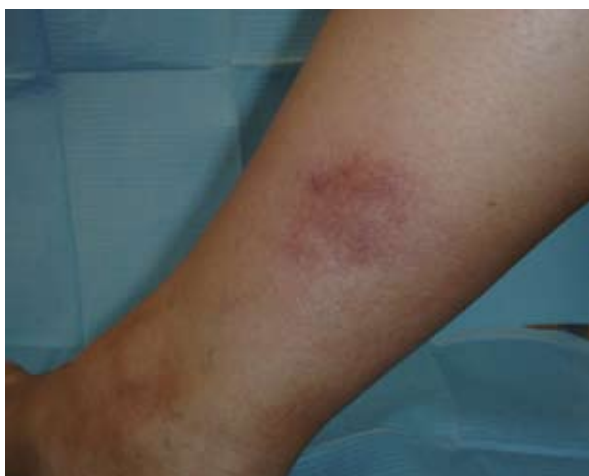using QuantiFERON-TB®-Gold In tube test, Cellestis Ltd., Carnegie, Australia) was negative. Chest x-ray revealed bilateral hilar lymphadenopathy. Spirometry was normal. The test of diffusing capacity of the lungs for carbon monoxide revealed reduced diffusion capacity at the alveocapillary membrane level.

Gallium-67 citrate scintigraphy of the whole body showed increased uptake in bilateral hilar region and in both breasts, more expressed in the right one (Fig. 4a,b). Therefore, the diagnosis of systemic sarcoidosis was established. Immune-mediated disorders, rheumatoid arthritis, systemic lupus erythematosus and systemic vasculitis were excluded.

Oral therapy with 40 mg prednisone was administered for 4 weeks with dose tapered by 5 mg every seven days until the dose of 15 mg was reached and continued for the next 4 months. Incipient regression



**Figure 2.** Histopathology of the plaque: palisaded neutrophilic and granulomatous dermatitis. Features of granuloma annulare-like lesions with the added features of vasculitis and no increased mucin (H&E; x40) (a); close-up view showing necrobiosis, histiocytes and neutrophils associated with karyorrhexis (H&E; x100) (b).

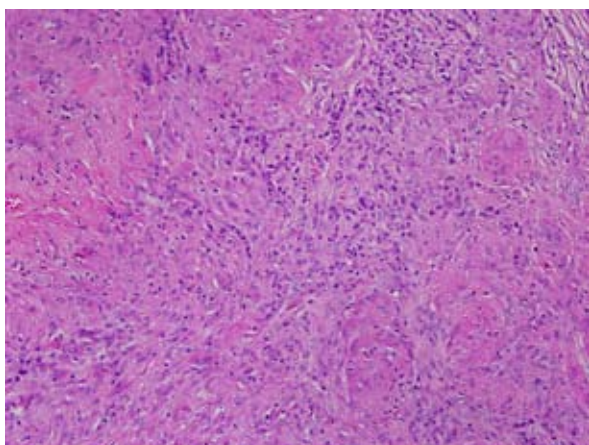


**Figure 3.** Firm and tender nodule on the right calf; clinically tender nodule.

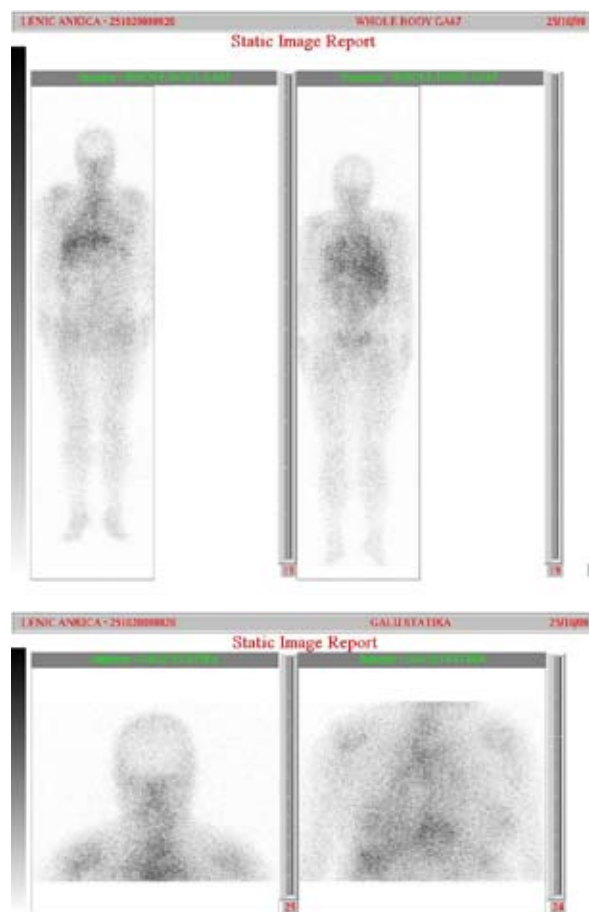
of the cutaneous lesions was seen during the fourth week of therapy and complete clinical cutaneous remission during the sixth week. Complete clinical cutaneous remission along with subcutaneous and systemic sarcoidosis and laboratory remission was seen after 4 months of therapy.

### DISCUSSION

PNGD is a term that has been applied to a reaction pattern of necrobiotic and granulomatous inflammation encountered in the setting of systemic disease. Clinically, PNGD presents with asymptomatic, rarely tender, skin-colored to erythematous and violaceous papules, nodules, plaques and annular plaques with or without central ulceration and crusting on the extensor parts of extremities, medial thighs, trunk, and



**Figure 4.** Histopathology of the nodule: numerous typical well formed, non-caseating granulomata of 'naked' type consisting of epithelioid histiocytes and giant cells of both foreign body and Langerhan's type throughout the dermis, lobule and in fat septa (H&E; x100).



**Figure 5.** Gallium-67 citrate scintigraphy of the whole body showing increased uptake in bilateral hilar region and in both breasts (a), more expressed in the right one (b).

hands, sometimes linearly arranged (1-12). The clinical course of PNGD in most cases appears to be self-limited. Often, the appearance of these lesions coincides with worsening of the underlying systemic disease (10). The etiology and etiopathogenesis of PNGD are unknown. Almost all systemic diseases associated with PNGD include formation of immune complexes and therefore the immune mechanism probably plays a role. A variety of histologic patterns have been described. Histopathology of PNGD shows a spectrum of findings dependent on the duration of lesions: early lesions display leukocytoclastic vasculitis, dense neutrophilic infiltrate and degenerated collagen; later or fully developed lesions appear as palisaded granulomas with neutrophils, and eventually, dermal fibrosis can be seen; resolving lesions show palisaded granulomas with dermal fibrosis and scant neutrophilic debris (3,13).

A common denominator is the presence of necrobiosis associated with histiocytic response similar to granuloma annulare or necrobiosis lipidica. In fact,

some would label these lesions as falling within the spectrum of granuloma annulare (14). Superimposed on this background of granuloma annulare-like features is a neutrophilic infiltrate with karyorrhexis (14). The precise terminology preferred by dermatopathologists is probably not important. More significant than any nosologic nuances is issuing a report that alerts the clinician to the possibility that the patient may have underlying systemic disease and that when such lesions are encountered, appropriate clinical evaluation is necessary.

In our adult female patient with asymptomatic, unilateral lesions on the extensor part of the knee based on the histopathologic findings and after thorough searching of literature, the diagnosis of PNGD in association with systemic and subcutaneous sarcoidosis was established. PNGD in association with sarcoidosis is rarely described. A review of the literature revealed one case of PNGD described so far in association with sarcoidosis in a pediatric patient and two in adult patients (1,4,15).

The uniqueness of this case is the localization of sarcoidosis as subcutaneous lesions, which are rare findings, especially on the face (16). However, cutaneous sarcoidosis in childhood sarcoidosis can involve any region of the body but has a predilection for the face, especially the nostrils, nasolabial folds, and eyelids (15).

Furthermore, breast involvement is extremely rare and it might be a pitfall in the diagnosis, as it may be confused with a neoplasm, as in our patient (17). Therefore, to exclude breast neoplasm in our patient, breast surgery and biopsy microscopy were necessary. Moreover, the eye can be the first site for presentation of sarcoidosis, as intermediate, posterior or anterior uveitis, as in our patient (18,19).

Improvement of the PNGD has been reported with topical corticosteroids, low-dose prednisone, and dapsons, which is known to help in various neutrophilic dermatoses, although it is unclear whether such treatments caused resolution of the eruption or the lesions resolved spontaneously (5,10). Furthermore, treatment is focused on the underlying disorder and variable responses have been reported to cyclosporine, methotrexate, cyclophosphamide, colchicine, hydroxychloroquine, nonsteroidal inflammatory agents and infliximab, as these medications cause stabilization of the underlying disease (3,10,13).

Treatment of cutaneous sarcoidosis can be frustrating because some of them may be refractory to treatment or may recur after treatment has been successfully finished (20). The most effective treatments for cutaneous sarcoidosis are corticosteroids (21,22). Top-

ical or intralesional steroids are used for localized involvement, while for widespread involvement, severe lesions or those that impair function, systemic steroids are reserved. Nonsteroidal anti-inflammatory drugs, methotrexate, hydroxychloroquine, dapsons, allopurinol, minocycline, clofazamine and potassium iodide are reported for treatment with various responses (21,23-26). Our patient had complete response after 4 months of therapy with oral prednisone for PNGD and cutaneous and systemic sarcoidosis, with no relapse during the 4-year follow up.

Furthermore, sarcoidosis may precede the development of a neoplastic process, mainly internal malignancy, by months or years (27-29). The pathogenic mechanism includes inflammation, intrinsic immune dysfunction, cytokines and interleukins, angiogenic factors, and epigenetic changes. Therefore, close patient follow up is necessary. In our patient, no neoplasm has been diagnosed in the 4-year follow up.

## CONCLUSION

It is important that all patients with suggestive symptoms of PNGD are screened for associated autoimmune, lymphoproliferative, or malignant states. This case describes PNGD occurring in the adult patient with systemic and subcutaneous sarcoidosis, and with complete remission on systemic corticosteroid therapy.

## References

1. Mahmoodi M, Ahmad A, Bansal C, Cusack CA. Palisaded neutrophilic and granulomatous dermatitis in association with sarcoidosis. *J Cutan Pathol* 2011;38:365-8.
2. Finan MC, Winkelmann RK. The cutaneous extravascular necrotizing granuloma (Churg-Strauss granuloma) and systemic disease: a review of 27 cases. *Medicine (Baltimore)* 1983;62:142.
3. Sangueza OP, Caudell MD, Mengesha YM, Davis LS, Barnes CJ, Griffin JE, *et al.* Palisaded neutrophilic granulomatous dermatitis in rheumatoid arthritis. *J Am Acad Dermatol* 2002;47:251-7.
4. Gordon EA, Schmidt AN, Boyd AS. Palisaded neutrophilic and granulomatous dermatitis: a presenting sign of sarcoidosis? *J Am Acad Dermatol* 2011;65:664-5.
5. Bremner R, Simpson E, White CR, Morrison L, Deodhar A. Palisaded neutrophilic and granulomatous dermatitis: an unusual cutaneous manifestation of immune-mediated disorders. *Semin Arthritis Rheum* 2004;34:610-6.
6. Kim SK, Park CK, Park YW, Jun JB, Yoo DH, Bae SC.

- Palisaded neutrophilic granulomatous dermatitis presenting as an unusual skin manifestation in a patient with Behçet's disease. *Scand J Rheumatol* 2005;34:324-7.
7. Germanas JP, Mehrabi D, Carder KR. Palisaded neutrophilic granulomatous dermatitis in a 12-year-old girl with systemic lupus erythematosus. *J Am Acad Dermatol* 2006;55:S60-2.
  8. Asahina A, Fujita H, Fukunaga Y, Kenmochi Y, Ikenaka T, Mitomi H. Early lesion of palisaded neutrophilic granulomatous dermatitis in ulcerative colitis. *Eur J Dermatol* 2007;17:234-7.
  9. Muscardin LM, Cota C, Amorosi B, Ferraro C. Erythema elevatum diutinum in the spectrum of palisaded neutrophilic granulomatous dermatitis: description of a case with rheumatoid arthritis. *J Eur Acad Dermatol Venereol* 2007;21:104-5.
  10. Biswas A, Chittari K, Gey van Pittius D, Stephens M, Tan BB. Palisaded neutrophilic and granulomatous dermatitis in a child with type I diabetes mellitus and coeliac disease. *Br J Dermatol* 2008;159:488-9.
  11. Misago N, Shinoda Y, Tago M, Narisawa Y. Palisaded neutrophilic granulomatous dermatitis with leukocytoclastic vasculitis in a patient without any underlying systemic disease detected to date. *J Cutan Pathol* 2010;37:1092-7.
  12. Gordon K, Miteva M, Torchia D, Romanelli P. Allopurinol-induced palisaded neutrophilic and granulomatous dermatitis. *Cutan Ocul Toxicol* 2012;31:338-40.
  13. Chu P, Connolly K, LeBoit PE. The histopathologic spectrum of palisaded neutrophilic and granulomatous dermatitis in patients with collagen vascular disease. *Arch Dermatol* 1994;130:1278.
  14. Magro CM, Crowson AN, Regauer S. Granuloma annulare and necrobiosis lipoidica tissue reactions as a manifestation of systemic disease. *Hum Pathol* 1996;27:50-6.
  15. Kwon EJ, Hivnor CM, Yan AC, Forbes B, Elenitsas R, Albert D, *et al.* Interstitial granulomatous lesions as part of the spectrum of presenting cutaneous signs in pediatric sarcoidosis. *Pediatr Dermatol* 2007;24:517-24.
  16. English III JC, Patel PJ, Greer KE. Sarcoidosis. *J Am Acad Dermatol* 2001;44:725-43.
  17. Fiorucci F, Conti V, Lucantoni G, Patrizi A, Fiorucci C, Giannunzio G, *et al.* Sarcoidosis of the breast: a rare case report and a review. *Eur Rev Med Pharmacol Sci* 2006;10:47-50.
  18. Herbort CP, Rao NA, Mochizuki M; members of Scientific Committee of First International Workshop on Ocular Sarcoidosis. International criteria for the diagnosis of ocular sarcoidosis: results of the first International Workshop on Ocular Sarcoidosis (IWOS). *Ocul Immunol Inflamm* 2009;17:160-9.
  19. Heiligenhaus A, Wefelmeyer D, Wefelmeyer E, Rösel M, Schrenk M. The eye as a common site for the early clinical manifestation of sarcoidosis. *Ophthalmic Res* 2010;46:9-12.
  20. Marchell RM, Judson MA. Chronic cutaneous lesions of sarcoidosis. *Clin Dermatol*. 2007;25:295-302.
  21. Tchernev G. Cutaneous sarcoidosis: the "great imitator": etiopathogenesis, morphology, differential diagnosis, and clinical management. *Am J Clin Dermatol* 2006;7:375-82.
  22. Tchernev G, Patterson JW, Nenoff P, Horn LC. Sarcoidosis of the skin – a dermatological puzzle: important differential diagnostic aspects and guidelines for clinical and histopathological recognition. *J Eur Acad Dermatol Venereol* 2010;24:125-37.
  23. Braverman IM. Sarcoidosis. In: Freedberg IM, Eisen AZ, Wolff K, Austen KF, Goldsmith LA, Katz SI, editors. *Fitzpatrick's Dermatology in General Medicine*. 6<sup>th</sup> edn. New York (NY): McGraw Hill, 2003. pp.1777-83.
  24. Ahmed I, Harshad S. Subcutaneous sarcoidosis: is it a specific subset of cutaneous sarcoidosis frequently associated with systemic disease? *J Am Acad Dermatol* 2006;54:55.
  25. Voelter-Mahlknecht S, Benez A, Metzger S, Fierlbeck G. Treatment of subcutaneous sarcoidosis with allopurinol. *Arch Dermatol* 1999;135:1560.
  26. Senet P, Cadranel J, Kaoukhov A, Dubertret L. The use of tetracyclines for the treatment of sarcoidosis. *Arch Dermatol* 2001;137:69.
  27. Alexandrescu DT, Kauffman CL, Ichim TE, Riordan NH, Kabigting F, Dasanu CA. Cutaneous sarcoidosis and malignancy: an association between sarcoidosis with skin manifestations and systemic neoplasia. *Dermatol Online J* 2011;17:2.
  28. Alexandrescu DT, Riordan NH, Ichim TE, Kauffman CL, Kabigting F, Dutton CT, *et al.* On the missing link between inflammation and cancer. *Dermatol Online J* 2011;17:10.
  29. Tchernev G, Ananiev J, Cardoso JC, Wollina U, Verma SB, Patterson JW, *et al.* Sarcoidosis and molecular mimicry – important etiopathogenetic aspects: current state and future directions. *Wien Klin Wochenschr* 2012;124:227-38.