

# COMBINED SLEEVE GASTRECTOMY AND MINI-GASTRIC BYPASS IN A NEW BARIATRIC PROCEDURE OF MINI-GASTRIC BYPASS AND PROXIMAL SLEEVE GASTRECTOMY

Ana Car Peterko<sup>1</sup>, Branka Mazul-Sunko<sup>2</sup>, Gorana Mirošević<sup>3</sup> and Miroslav Bekavac-Bešlin<sup>4</sup>

<sup>1</sup>Department of General Surgery, Urology and Orthopedics, Virovitica General Hospital, Virovitica; <sup>2</sup>Department of Anesthesiology, Sveti Duh University Hospital; <sup>3</sup>Department of Endocrinology, <sup>4</sup>Department of Surgery, Sestre milosrdnice University Hospital, Zagreb, Croatia

**SUMMARY** – Surgery is the most effective method for the treatment of morbid obesity. Beneficial effects of bariatric surgery are due to both changed anatomy and consequential alterations in hormonal and metabolic status. Based on the experience with former standard bariatric procedures, the idea came out of a new combined bariatric procedure that could provide better control of glucose level and weight loss. The procedure is a hybrid of sleeve gastrectomy and mini-gastric bypass, therefore uniting advantages of both procedures: one anastomosis, achieved effects of restriction and malabsorption and affection of both dominant endocrine systems that result in an increase in incretin level and a decrease in ghrelin level. However, the procedure is yet a novel one and these hypotheses are about to be examined in the already announced research project.

**Key words:** *Bariatric surgery; Obesity; Sleeve gastrectomy; Mini-gastric bypass*

## Introduction

In the World Health Organization report from the year 2000, obesity was recognized and declared as a global, worldwide epidemic. Due to serious comorbidities such as diabetes mellitus type 2 and atherosclerotic disease, it poses a considerable epidemiologic and economic problem for developed countries but also for developing ones<sup>1,2</sup>. In Croatia, nowadays, it is a major health problem.

In contrast to conservative treatment, which has proved to be ineffective in these patients, bariatric or metabolic surgery offers substantial results in weight loss and reduction of associated comorbidities. Nowa-

days, it is evident that beneficial effects of bariatric procedures are not exclusively the consequence of gastric restriction and intestinal malabsorption but are also caused by the gastrointestinal system restructuring and altered hormonal and metabolic status.

## Methods

The beginnings of bariatric or metabolic surgery date from 1950, but the expansion started with the introduction of minimally invasive surgical methods. This development has brought numerous methods that are currently used in distinct alternatives.

According to the declaration of the American Health Institute from 1991, surgical treatment is the most effective method for the treatment of morbid obesity.

Former standard bariatric procedures such as sleeve gastrectomy and Roux-en-Y gastric bypass have been

Correspondence to: *Ana Car Peterko, MD*, Department of General Surgery, Urology and Orthopedics, Virovitica General Hospital, Ljudevita Gaja 21, HR-33000 Virovitica, Croatia  
E-mail: [anacarpeterko@yahoo.com](mailto:anacarpeterko@yahoo.com)

Received February 27, 2013, accepted June 19, 2013

effective treatment, nevertheless, 20% of patients did not lose weight after surgery and 15% did not show improvement in glucose level control. Therefore, an idea has evolved of a new combined procedure of sleeve gastrectomy and mini-gastric bypass that could theoretically provide better glucose control and weight loss over two dominant endocrine systems.

### *Sleeve gastrectomy*

Sleeve gastrectomy (SG) is a restrictive, irreversible procedure that reduces stomach capacity by 70%-90%. It can be performed as a distinct operation or as a first stage of duodenal switch for the super-super obese persons (BMI >60)<sup>3,4</sup>.

Surgical approach used for this procedure can be either open or laparoscopic, but the minimally invasive one is preferred. After gas insufflation, five trocars are introduced in the abdomen. The procedure starts with dissection of the greater curvature of stomach, 2-5 cm orally from pylorus to the angle of Hiss, thus revealing left crura of the hiatus of the esophagus. This is followed by the introduction of nasogastric tube (thickness from 36 Fr to 48 Fr) and stapler resection from the antrum to the fundus of the stomach. The resected part of the stomach is then removed from the abdomen, in a plastic bag, through the left subcostal incision<sup>5,6</sup>.

Since it was first performed, SG has shown good results in the treatment of obesity. It is due to the anatomic reduction of the stomach volume but also to the consequential decreased level of the hunger hormone ghrelin. Nevertheless, the procedure has several disadvantages. In the early postoperative period, excessive food intake may lead to dilatation of the stomach and dehiscence of stapled line and the possible development of the gastroesophageal reflux disease must be emphasized as a late complication.

### *Mini-gastric bypass*

The most frequently performed bariatric procedure is laparoscopic Roux-en-Y gastric bypass (LRYGB). The technique unites restriction and malabsorption components<sup>7</sup>. After being first reported in 1994 by Wittgrove, the method has been exceptionally well accepted and it is still not replaced. Nevertheless, LRYGB has various modifications, mostly related to gastroenteroanastomosis (GEA) creation, but the

principle of operation and postoperative effects are mainly the same.

Mini-gastric bypass (MGB) is one of the modified versions of LRYGB whose popularity is increasing. The method has been developed and pioneered by Rutledge and Walsh<sup>8,9</sup>. The procedure is carried out with 5 trocars, which are introduced in the abdomen after gas insufflation. It begins with dissection of the angle of Hiss and lesser curvature of the stomach, 2-3 cm orally from pes anserinus, and continues with vertical stapler resection (with 45 mm long green or black cartridge) and horizontal stapler resection from the pes anserinus to the angle of Hiss (with 60 mm long green or blue; black or purple cartridge). Thus a 7 cm long, narrow stomach stump is created and prepared for the creation of GEA. The excluded part of the stomach remains in the abdomen and empties through the duodenum into the biliopancreatic segment of the jejunum. This part of the procedure is followed by mobilization of the jejunum, identification of the ligament of Treitz and creation of termino-lateral GEA at 200 cm from the ligament. Enteroenteroanastomosis (EEA) is not created in MGB procedure because reflux is avoided by two mechanisms: longer inlet limb of the small intestine in which there is a minor amount of biliopancreatic content and the fact that the narrow stomach stump does not possess the suction torque<sup>10</sup>.

MGB is an effective method not only for its restriction and malabsorption components, but also because of alteration in the activity of gastrointestinal hormones induced by the exclusion of duodenum. Beneficial effects after MGB procedure, such as rapid improvement of glucose level control and weight loss, are mediated by the increase of incretins, gastrointestinal hormones with potent gluoregulatory and energy homeostasis controlling functions. However, hypoglycemia is a potentially serious complication<sup>11-13</sup>.

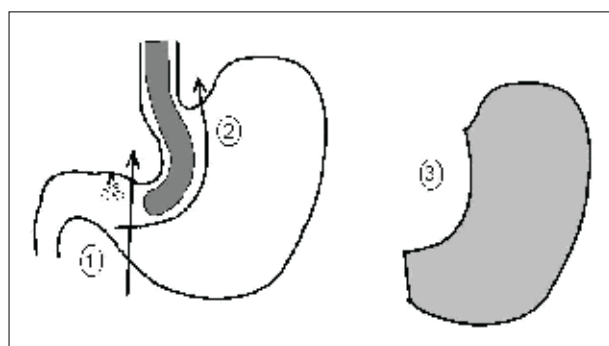
### *Combined mini-gastric bypass and sleeve gastrectomy = mini-gastric bypass + proximal sleeve gastrectomy (MGB+PSG)*

Combined MGB and PSG is a modified bariatric procedure composed of former standard procedures of sleeve gastrectomy with intact antrum and mini-gastric bypass. It can be performed by open or laparoscopic technique.

Laparoscopic technique begins with CO<sub>2</sub> insufflations until the working pressure reaches 12-14 mm Hg. The insufflation site is Palmers point, beneath the left rib arc, in the midclavicular line, just beside the arc itself. Veres needle is, in this manner, introduced in the abdominal cavity in a rather safe position, where the rib arc is convex and therefore the possibility of organ injury is minimal. Nevertheless, injuries of the spleen, liver, stomach, colon and omentum are still possible.

Optical instrument is introduced above the umbilicus and laterally from the median line. Penetration with optical trocar should be performed by rotational motions, with minimal pressure on the surface and under visual control of all layers of the abdominal wall. After entering abdominal cavity, the position of Veres needle is inspected as well as the possible organ injury. Inspection is followed by removal of the needle.

Two 12-mm trocars are inserted in the left hemi-abdomen to enable the work of the surgeon and his assistant. Their position must allow for undisturbed stapler utilization as well as unobstructed dissection of greater curvature of the stomach until the angle of Hiss and left crus of diaphragm. The first trocar is in the level or slightly below the level of optical trocar and the other is closer to the rib arc and lateral to the first one. Operating trocars in the left hemi-abdomen provide gastric resection with tube formation for MGB. They also enable greater curvature dissection and manipulation with the small intestine from the ligament of Treitz to the point predicted for GEA



*Fig. 1. Gastric resection: resection lines (1 and 2); resected part of the stomach prepared for extraction (3).*

*Fig. 2. Antecolic, isoperistaltic termino-lateral gastroenteroanastomosis.*

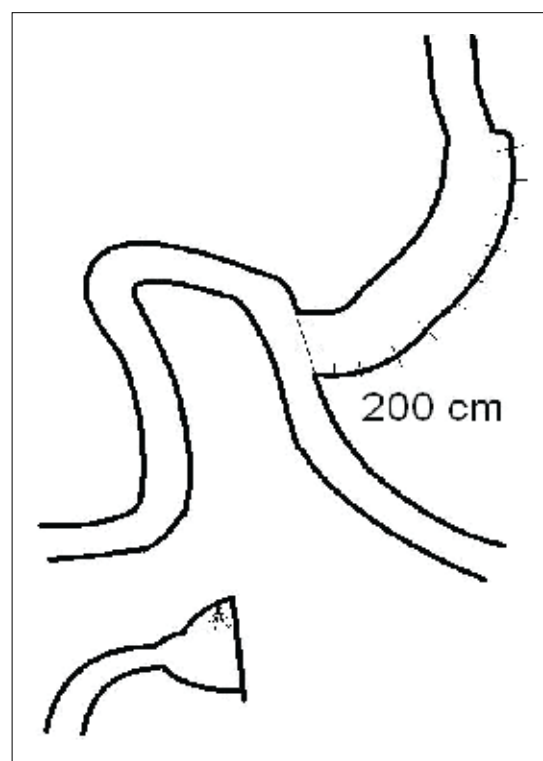
(approximately 200 cm).

A 12-mm trocar is inserted in the right hemi-abdomen, also in the level or slightly below the level of optical trocar, enabling the introduction of stapler or some other operating instruments. A liver retractor is set up high in the epigastrium through the 5-mm trocar aperture.

The procedure continues by exploration of the abdominal cavity, with particular attention to potential adhesions, mobility of the omentum and small intestine mesentery, checking out the position of nasogastric tube and emptying the stomach.

The next step is opening of the gastrocolic ligament at the greater curvature with the ultrasonic knife. Thus created gap in the ligament enables exploration of the dorsal wall of the gastric corpus in the area of stapler resection (close to gastric antrum). Marking point on the lesser curvature is pes anserinus.

Gastric resection is performed with two 60 mm long green or black cartridge of stapler. First resection line extends from the greater curvature (orally from gastric antrum) towards the lesser curvature (orally from the pes anserinus) (Fig. 1, line 1). Second resection line is in the manner of sleeve resection: insertion of the calibration tube (34 Fr) and proximal gastric



resection (Fig. 1, line 2). Cartridge could be green or blue (black or purple), and length of stapler 60 mm<sup>4</sup>. The next procedure is dissection of the greater curvature by ultrasonic knife and placing the resected part of the ventricle in the sac, thus preparing it for extraction (Fig. 1, item 3).

The part of the procedure described leaves a created gastric stump prepared for anastomosis with small intestine.

The first portion of the small intestine is mobilized from Treitz ligament and then measured until 200 cm and used to create antecolic, isoperistaltic GEA (Fig. 2). The procedure is performed by linear stapler of 45 mm in length, with blue cartridge and by running one-layered suture of the stapler gap. Anastomosis must be examined with blue dye solution or with air insufflate through gastric tube. At the end of the procedure, the tube is extracted, the possible bleeding is controlled, toilet and drainage is performed according to the decision of the surgeon. The resected part of the ventricle is extracted and sent for pathologic examination. All trocars are removed under visual control and all wounds are sutured.

X-ray control with water-soluble contrast is performed 24 hours after the procedure and then liquid diet is introduced. The patient is discharged after restoration of intestinal functions.

The procedure is based on the advantages of MGB and SG: one anastomosis, achieved effects of restriction and malabsorption, decreased level of hormones that stimulate appetite, reduced appearance of dilatation and retention in the gastric stump that is formed only of antrum with preserved peristaltic function. The method can be converted in Billroth I resection if necessary.

Indications for combined MGB + PSG procedure are identical as those for MGB and SG. The time required for this procedure is 30-50 min prolonged in the initial phase of performing this method.

***Proposed research project: Metabolic and endocrine effects of a novel bariatric technique – combined MGB + PSG***

The new bariatric procedure, combined MGB and PSG, is still a novel technique with assumed beneficial effects based on the theory and former experience with both techniques individually. Therefore, a re-

search project of 3-year duration has been proposed to analyze the metabolic and endocrine effects of combined MGB and PSG procedure. The main hypothesis is the observation that the combined procedure could provide better postoperative control of glucose level and weight loss because it would affect both dominant endocrine systems causing an increase in the level of incretins (observed after MGB) and a decrease in the level of ghrelin (observed after SG).

A total of 45 patients scheduled for bariatric surgery would be randomly assigned to one of the three groups according to the procedure: group 1, MGB; group 2, GSR; and group 3, combined MGB + PSG. A day before surgery, basal metabolic rate will be measured and venous blood sample taken for all standard biochemical markers including Hb1Ac, cholesterol and triglyceride level. Testing of inflammatory status would include TNF $\alpha$ , IL-6 and CRP. Continuous glucose measurement for 72 hours will be initiated a day before surgery. In conventional way, glucose will be measured every 6 hours. Thyroid gland function will be analyzed by specific tests as well as other endocrine assays. Markers specific for obesity will include leptin, ghrelin and adiponectin. These tests will be performed six times: before surgery; on postoperative day 1; and at 1, 3 and 6 months and 1 year after the procedure. The results and the conclusion will be presented when the research is completed.

## Discussion

Herein, we present the idea of a new bariatric procedure that is a combination of two standard and effective bariatric techniques, sleeve gastrectomy and mini-gastric bypass.

The potential benefit of this combined procedure is to provide beneficial effect of both techniques. The aim is to achieve better glucose control and weight loss after surgery than with either procedure over two endocrine systems, ghrelin and incretin. Although this hypothesis has not yet been investigated, this hybrid procedure has already been proposed and approved by the Sestre milosrdnice University Hospital Center Ethics Committee as a research project of 3-year duration. At the end of the research, results will be presented at international and Croatian conferences of surgical and endocrinological societies as well as sub-

mitted for publishing in relevant journals. We hope that our expectation of this new method would be justified and therefore contribute to the development of bariatric surgery.

## References

- JAMES WPT, RIGBY N, LEACH R. The obesity epidemic, metabolic syndrome and future prevention strategies. *Eur J Cardiovasc Prev Rehab* 2004;11:3-8.
- CULNAN DM, COONEY RN, STANLEY B, LYNCH CJ. Apolipoprotein A-IV, a putative satiety/antiatherogenic factor, rises after gastric bypass. *Obesity (Silver Spring)* 2009;17:46-52.
- BUCHWALD H. A bariatric surgery algorithm. *Obes Surg* 2002;12:733-46.
- BALTASAR A, SERRA C, PEREZ N, BOU R, BENGOCHEA M, FERRI L. Laparoscopic sleeve gastrectomy: a multi-purpose bariatric operation. *Obes Surg* 2005;15:1124-8.
- GRGIĆ T, KULIŠ T, VIDOVIĆ D. Laparoscopic sleeve gastrectomy for morbid obesity – case report. *Acta Chir Croat* 2008;5:20-2.
- KULIŠ T, GLAVAN E, ŠKORJANEC S, LEDINSKY M, BEKAVAC-BEŠLIN M. Biliopancreatic diversion with sleeve gastrectomy and antroileal anastomosis – case report. *Acta Clin Croat* 2007;46:37-40.
- MASON EE, ITO C. Gastric bypass in obesity. *Surg Clin North Am* 1967;47:1454-51.
- RUTLEDGE R, WALSH TR. Continued excellent results with the mini-gastric bypass: six year study in 2,410 patients. *Obes Surg* 2005;15:1304-8.
- LEE WJ, SER KH, LEE JC, TSOU JJ, CHEN SC, CHEN JC. Laparoscopic Roux-en-Y vs. mini-gastric bypass for the treatment of morbid obesity: a 10 year experience. *Obes Surg* 2012;22:1827-34.
- BEKAVAC-BEŠLIN M, CAR PETERKO A, GAURINA A, DIKLJIĆ D, GRGIĆ T, FILIPOVIĆ J. What is the bariatric surgery? *BH Surgery* 2011;1:66-79.
- NGUYEN NT, VARELA E, SABIO A, TRAN CL, STAMOS M, WILSON SE. Resolution of hyperlipidemia after laparoscopic Roux-en-Y gastric bypass. *J Am Coll Surg* 2006;203:24-9.
- PINHEIRO JS, SCHIAVON CA, PEREIRA PB, CORREA JL, NOUJAIM P, COHEN R. Long-limb Roux-en-Y gastric bypass is more efficacious in treatment of type 2 diabetes and lipid disorders in super-obese patients. *Surg Obes Relat Dis* 2008;4:521-5; discussion 526-7.
- KHALAILEH A, MATOT I, SCHWEIGER C, APPELBAUM L, ELAZARY R, KEIDAR A. Laparoscopic Roux-en-Y gastric bypass for the treatment of morbid obesity: experience with 50 patients. *Isr Med Assoc J* 2008;10:350-3.

## Sažetak

### KOMBINACIJA SLEEVE GASTREKTOMIJE I MINI-GASTRIČNOG *BYPASSA* U NOVOM BARIJATRIJSKOM ZAHVATU: *MINI-GASTRIC BYPASS* I PROKSIMALNA *SLEEVE* GASTREKTOMIJA

*A. Car Peterko, B. Mazul-Sunko, G. Mirošević i M. Bekavac-Bešlin*

Kirurške su metode najučinkovitije u liječenju patološke pretilosti. Povoljni učinci barijatrijske kirurgije posljedica su anatomskih promjena, ali i promjena do kojih dolazi u metaboličkom i endokrinom statusu. Na temelju iskustva s dosadašnjim standardnim barijatrijskim postupcima proizišla je zamisao o novom, kombiniranom barijatrijskom zahvatu koji bi mogao omogućiti bolju poslijeoperacijsku kontrolu razine glukoze u krvi, kao i bolju kontrolu gubitka tjelesne težine. Zahvat se sastoji od hibridne *sleeve* gastrektomije i *mini-gastric bypassa* i kao takav ujedinjuje prednosti obaju postupaka: jedna anastomoza, postignut učinak restrikcije i malapsorpcije te porast razine inkretina i pad razine grelina kao rezultat djelovanja na dva dominantna endokrina sustava. S obzirom na to da je metoda još neispitana ove će hipoteze biti predmet ispitivanja već najavljenog istraživačkog projekta.

Ključne riječi: *Barijatrijska kirurgija; Debljina; Sleeve gastrektomija; Mini-gastrični bypass*