

ENDOSCOPIC BALLOON DILATATION OF POSTSURGICAL INTESTINAL STRICTURES IN CROHN'S DISEASE: CASE REPORT AND REVIEW OF THE LITERATURE

Neven Ljubičić, Alen Bišćanin, Ines Nikić, Ivan Budimir, Marko Nikolić and Tajana Pavić

Division of Gastroenterology, Department of Internal Medicine, Sestre milosrdnice University Hospital Center, School of Medicine and Dental Medicine, University of Zagreb, Zagreb, Croatia

SUMMARY – Strictures are one of the most common complications of Crohn's disease. If symptomatic and resistant to medical anti-inflammatory therapy, and especially in cases of acute obstruction, surgical correction may be unavoidable. Although surgical treatment is dramatically effective in curing Crohn's disease strictures, a high rate of postsurgical restenosis has been recognized, ultimately requiring additional surgery. To avoid the risks and costs entailed by repeated surgical resection, endoscopic balloon dilatation (EBD) has been proposed as a conservative treatment option for intestinal strictures in Crohn's disease, in which the stricture is pneumatically dilated with through-the-scope balloons of different diameters. The main clinical indication for EBD is the appearance of obstructive symptoms associated with the stricture, especially if they are postoperative and shorter than 4 centimeters. Usually more than one dilatation session is required for every stricture. EBD is applied infrequently, possibly due to the perceived risk of perforation and early stricture recurrence, but studies have demonstrated that EBD has a high success rate, a low chance of complications, excellent symptomatic response, as well as good short-term and long-term outcomes, proving that it is a relatively simple and successful technique that provides long-term effective palliation of the symptoms with minimal risk in patients with simple strictures, and offers a reasonable alternative to surgery.

Key words: *Constriction, pathologic – surgery; Endoscopy, gastrointestinal – methods; Crohn's disease – complications*

Introduction

Crohn's disease (CD) is a chronic inflammatory bowel disease of unknown etiology and unpredictable course that can affect any part of the gastrointestinal tract, but most commonly affects terminal ileum. The peak age at onset is between 15 and 30 years, more frequent in women, while the second peak occurs between the ages of 60 and 80.

Crohn's disease is characterized by an aberrant and persistent inflammatory process causing transmural

lesions of the bowel wall, and by the excessive fibrogenic response resulting in transmural fibrosis, which often leads to the development of complications, both intestinal and extra-intestinal.

Vienna and Montreal classification of CD, as a clinical classification, considers age at onset (A), disease location (L), and disease behavior (B) as the predominant phenotypic elements¹. By disease behavior (B), CD is divided into non-stricturing, non-penetrating (B1), stricturing (B2), and penetrating disease (B3), which is important in clinical practice for treatment planning.

The first line of treatment is medication, but when the disease does not respond or when complications arise and there is a need to relieve symptoms, surgery is required. Surgery is palliative because CD is a sur-

Correspondence to: *Prof. Neven Ljubičić, MD, PhD, FACG*, Department of Internal Medicine, Sestre milosrdnice University Hospital Center, Vinogradska c. 29, HR-10000 Zagreb, Croatia
E-mail: neven.ljubcic@kbcsm.hr

Received May 3, 2012, accepted September 22, 2012

gically incurable disease and implies major risks and complications. Most of these major complications require repeated surgical procedures.

Strictures, as the main feature of B2-stricturing disease and as one of the most common complications of CD, often require surgical resection needed to treat the associated subocclusive symptoms, and frequently recur after resection, which can lead to repeated surgery. Considering the risks and costs entailed by surgical resection and postoperative complications, endoscopic balloon dilatation (EBD) as an alternative to surgery and a method that pneumatically dilates CD strictures and thus preserves the length and function of the bowel, is of high clinical importance².

Case Report

A 19-year-old woman was diagnosed with CD in 2001, at the age of eight, after several months with symptoms of elevated temperature, inappetence, aphthous changes inside the mouth and anemia. The patient was introduced into remission with steroids and was without symptoms until 2006, when there was a recurrence that was treated with enteral nutrition. The

next relapse occurred in 2008 and was treated with prednisone, following azathioprine. Azathioprine was discontinued due to nausea and vomiting. After six months, colonoscopy revealed severe ulcerations in the terminal ileum and aphthae in the entire colon, so methotrexate was introduced in therapy. In 2009, after another relapse, resection of the terminal ileum, the cecum and the ascending colon with ileotransverse terminolateral anastomosis was made.

In March 2011, the patient experienced sudden pain in the lower right half of the abdomen and vomiting. She was admitted at another hospital, where endoscopic examination revealed stenosis of the ileotransverse anastomosis, and she was transferred to our hospital for dilatation of the stenosis.

At the beginning of April 2011, under general anesthesia (propofol and fentanyl), EBD of the anastomotic opening was made with through-the-scope (TTS) balloons of 6, 9, 12 and 15 mm in diameter (Fig. 1 a, b). The procedure and post-procedural course passed without complications and the patient was released from the hospital.

At the end of April, the patient was readmitted to the hospital and another balloon dilatation was

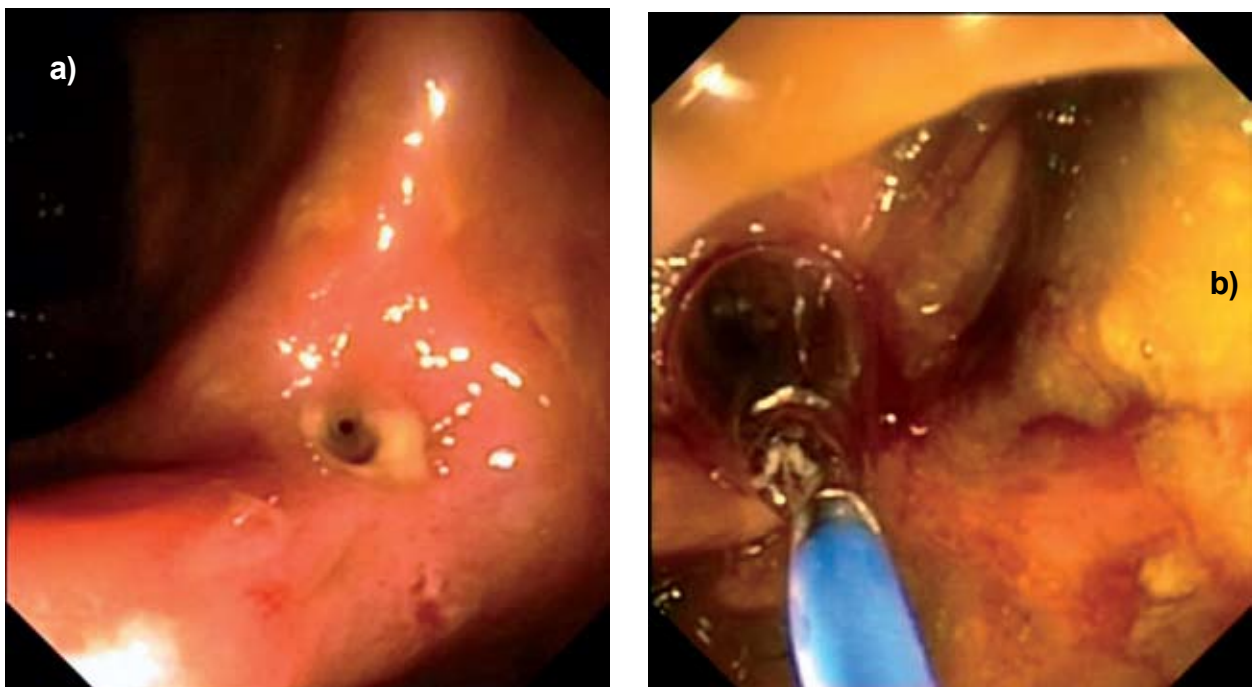


Fig. 1. (a) Stenosis of the ileotransverse anastomotic opening; (b) endoscopic balloon dilatation of the anastomotic opening with through-the-scope (TTS) balloon.

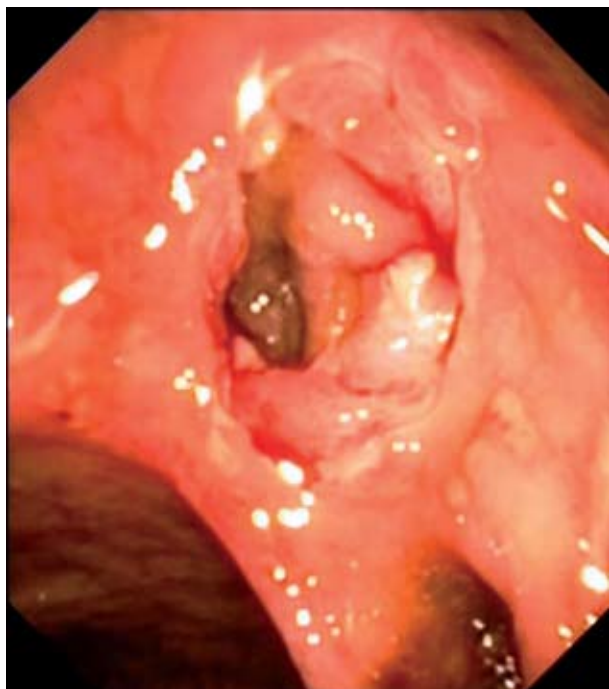

Fig. 2. Result of endoscopic balloon dilatation of the anastomotic opening.

performed with a TTS balloon of 18 mm in diameter. The procedure and post-procedural course passed without complications (Fig. 2). Additionally, a small bowel follow-through (SBFT) was performed, which showed an isolated loop of the small intestine (which corresponded to jejunoileal transition), with markedly irregular mucosal surface in the length of 11 cm; in some places shallow pseudo-ulcerations; spindle-shaped outgrowths of the contrast medium on one of the projections, which corresponded to a 10 mm-length of pseudo-diverticulum. The SBFT through the anastomosis was undisturbed. In therapy, methotrexate was replaced with azathioprine and budesonide. Considering the course of the disease, the patient was scheduled for biological therapies.

After four months, magnetic resonance imaging enteroclysis revealed the lumen of anastomosis of about 0.7 cm in diameter, with no pathologic opacification of the intestinal wall. The appearance of the surrounding adipose tissue showed no abnormalities.

Currently, the patient is symptom-free, and the results of clinical and laboratory tests are normal.

Discussion

Strictures, as one of the most common complications of CD, occur as a result of the healing response to chronic inflammation in the intestinal wall, and of an excessive fibrogenic response caused mainly by fibroblasts and smooth muscle cell activation, resulting in transmural fibrosis and consequently narrowing of the intestinal lumen. They can occur anywhere in the gastrointestinal tract, but most commonly affect ileocolonic anastomoses, terminal ileum and colon^{2,3}.

If symptomatic and resistant to medical anti-inflammatory therapy, and especially in cases of acute obstruction or perforation, surgical correction by intestinal resection or stricturoplasty may be unavoidable^{3,4}. It is estimated that up to 80% of CD patients will eventually require at least one surgical resection within 10 years of the diagnosis². Postoperative complications that can occur include fistulas, leaks, short bowel syndrome, and strictures that frequently recur at the anastomosis site (due to bacterial stasis from postoperative narrowing of the lumen, high intraluminal pressure and vascular compromise), thus creating a vicious cycle⁴.

Although surgical treatment is dramatically effective in curing CD strictures, a high rate of post-surgical restenosis has been recognized within a 1-year postintervention period, ultimately requiring additional surgery in at least 34% of cases². Postoperative morbidity associated with bowel resection is estimated to range from 6% to 45%, and mortality ranges from 0.5% to 5.5%⁴. To avoid the risks and costs entailed by repeated surgical resection, EBD has been proposed².

Endoscopic balloon dilatation is a non-surgical treatment option for intestinal strictures in Crohn's disease, in which the stricture is pneumatically dilated with TTS balloons of different diameters. Two different approaches can be used: applying maximum caliber dilatation from the outset or starting with a lower caliber and gradually increasing to greater balloon diameters, which we consider is safer due to a lower risk of perforation².

The use of local steroid infiltration at the site of dilatation is controversial, requiring further studies, as well as the use of antibiotics during and after the procedure^{2,3}. Considering that improved prognosis can be achieved by good control of the disease, we did

not use any of the above, awaiting their application to be evaluated in a controlled manner.

The main clinical indication for EBD is the appearance of obstructive symptoms associated with the stricture, especially if they are postoperative and shorter than 4 centimeters because they are technically easier to dilate and have a lower risk of perforation, as opposed to *de novo* strictures. Usually more than one dilatation session is required for every stricture.

For decompression of malignant bowel obstruction, metallic enteral endoprotheses (as an upgrade to EBD) proved useful in case studies, but to completely evaluate the success, the results of randomized studies are needed⁵.

The only predictor of a surgery-free follow-up is a short stricture. It remains unclear whether the failure of longer stricture dilatation is the result of an intrinsic resistance to pneumatic dilatation or a mere technical limitation².

Endoscopic balloon dilatation is applied infrequently, possibly due to the perceived risk of perforation and early stricture recurrence. In the past, studies showed a variation in success and in complication rates, which was associated with variations in the techniques used, selection of strictures for dilatation and the in-

definable technical abilities of endoscopists. However, the latest studies have provided evidence that EBD has a high success rate, a low chance of complications, an excellent symptomatic response, as well as good short-term and long-term outcomes, proving that it is a relatively simple and successful technique, with good and prolonged symptomatic relief (Table 1)^{2,3}.

It is important to mention that bowel perforation was the most common complication, but no death plausibly related to pneumatic dilatation has ever been reported, whilst there is no doubt that even the most conservative surgical approach is hampered by a definite mortality rate. In two series, a complication rate was unexpectedly high, 11% in Couckuyt's series, which was widely related to its aggressive technique (up to 1-h dilatation under general anesthesia) and 18% in Singh's series, which is quite enigmatic, considering the prudent technique adopted by the authors².

Other publications confirm these data, demonstrating even a long-term success rate of endoscopic dilatation of 80%, which is remarkable. The relapse rate after single EBD is probably somewhat higher than after surgery, but by repeated dilatation of relapsing strictures, surgery can be often avoided or

Table 1. Overview of the main variables monitored in the studies

First author (ref.)	No. of patients	Postsurgical strictures (%)	Maximum caliber	Steroid injection	Scope passing (%)	Technical success (%)	Clinical efficacy (%)	Major complications (%)
Dear ⁶	22	91	18	No	45	100	73	0
Sabate ⁷	38	65	25	No	56	84	53	3
Williams ⁸	7	71	20	No	100	71	71	0
Ferlitsch ⁹	46	62	20	Yes	-	85	57	4
Brooker ¹⁰	14	79	20	Yes	86	100	79	0
Gibson ¹¹	59	73	18	No	74	73	41	3
Ramboer ¹²	13	71	18	Yes	77	100	100	0
Couckuyt ¹³	55	67	20	No	73	85	60	11
Morini ¹⁴	43	67	18	No	70	79	42	0
Blomberg ¹⁵	27	100	25	No	100	100	67	0
Singh ¹⁶	17	30	20	Yes	96	100	76	18
Stienecker ¹⁷	25	52	18	No	97	97	94	3
Ajlouni ³	37	38	18	No	84	84	75	3
Hirai ¹⁸	25	0	18	No	72	72	-	8
Overall	428	63	25	-	79	88	68	3.75

delayed¹⁷. It is reasonable to assume that the longer the duration of follow-up, the higher the likelihood of recurrence and surgery³. Furthermore, the results indicate that EBD adds at least 50% to the efficacy of a previous surgery, so it would be a serious mistake to consider surgery and endoscopic dilatation as antagonist solutions for CD patients².

In conclusion, endoscopic dilatation of strictures in CD patients may achieve clinical benefit in many patients and provide long-term effective palliation of symptoms with minimal risk in patients with simple strictures, and offer a reasonable alternative to surgery. Dilatation may be repeated in recurrent intestinal obstructions and appears safe without morbidity^{4,19}.

References

1. SATSANGI J, SILVERBERG MS, VERMEIRE S, COLOMBEL JF. The Montreal classification of inflammatory bowel disease: controversies, consensus, and implications. *Gut* 2006;55(6):749-53.
2. HASSAN C, ZULLO A, de FRANCESCO V, IERARDI E, GIUSTINI M, PITIDIS A, TAGGI F, WINN S, MORINI S. Systematic review: endoscopic dilatation in Crohn's disease. *Aliment Pharmacol Ther* 2007;26(11-12):1457-64.
3. AJLOUNI Y, ISER JH, GIBSON PR. Endoscopic balloon dilatation of intestinal strictures in Crohn's disease: safe alternative to surgery. *J Gastroenterol Hepatol* 2007;22(4):486-90.
4. FOSTER EN, QUIROS JA, PRINDIVILLE TP. Long-term follow-up of the endoscopic treatment of strictures in pediatric and adult patients with inflammatory bowel disease. *J Clin Gastroenterol* 2008;42(8):880-5.
5. MARTINES G, UGENTI I, GIOVANNI M, MEMEO R, IAMBRENGHI OC. Anastomotic stricture in Crohn's disease: bridge to surgery using a metallic endoprosthesis. *Inflamm Bowel Dis* 2008;14(2):291-2.
6. DEAR KL, HUNTER JO. Colonoscopic hydrostatic balloon dilatation of Crohn's strictures. *J Clin Gastroenterol* 2001;33:315-8.
7. SABATE JM, VILLAREJO J, BOUHNİK Y, *et al.* Hydrostatic balloon dilatation of Crohn's strictures. *Aliment Pharmacol Ther* 2003;18:409-13.
8. WILLIAMS AJ, PALMER KR. Endoscopic balloon dilatation as a therapeutic option in the management of intestinal strictures resulting from Crohn's disease. *Br J Surg* 1991;78:453-4.
9. FERLITSCH A, REINISCH W, PUSPOK A, *et al.* Safety and efficacy of endoscopic balloon dilation for treatment of Crohn's disease strictures. *Endoscopy* 2006;38:483-7.
10. BROOKER JC, BECKETT CG, SAUNDERS BP, BENSON MJ. Long-acting steroid injection after endoscopic dilation of anastomotic Crohn's strictures may improve the outcome: a retrospective case series. *Endoscopy* 2003;35:333-7.
11. THOMAS-GIBSONS, BROOKERJC, HAYWARD CM, SHAH SG, WILLIAMS CB, SAUNDERS BP. Colonoscopic balloon dilation of Crohn's strictures: a review of long-term outcomes. *Eur J Gastroenterol Hepatol* 2003;15:485-8.
12. RAMBOER C, VERHAMME M, DHONDT E, HUYS S, van EYGEN K, VERMEIRE L. Endoscopic treatment of stenosis in recurrent Crohn's disease with balloon dilation combined with local corticosteroid injection. *Gastrointest Endosc* 1995;42:252-5.
13. COUCKUYT H, GEVERS AM, COREMANS G, HIELE M, RUTGEERTS P. Efficacy and safety of hydrostatic balloon dilatation of ileocolonic Crohn's strictures: a prospective long-term analysis. *Gut* 1995;36:577-80.
14. MORINI S, HASSAN C, LORENZETTI R, *et al.* Long-term outcome of endoscopic pneumatic dilatation in Crohn's disease. *Dig Liver Dis* 2003;35:893-7.
15. BLOMBERG B, ROLNY P, JARNEROT G. Endoscopic treatment of anastomotic strictures in Crohn's disease. *Endoscopy* 1991;23:195-8.
16. SINGH VV, DRAGANOV P, VALENTINE J. Efficacy and safety of endoscopic balloon dilation of symptomatic upper and lower gastrointestinal Crohn's disease strictures. *J Clin Gastroenterol* 2005;39:284-90.
17. STIENECKER K, GLEICHMANN D, NEUMAYER U, GLASER HJ, TONUS C. Long-term results of endoscopic balloon dilatation of lower gastrointestinal tract strictures in Crohn's disease: a prospective study. *World J Gastroenterol* 2009;15(21):2623-7.
18. HIRAI F, BEPPU T, SOU S, SEKI T, YAO K, MATSUI T. Endoscopic balloon dilatation using double balloon endoscopy is a useful and safe treatment for small intestinal strictures in Crohn's disease. *Dig Endosc* 2010;22(3):200-4.
19. SCIMECA D, MOCCIARO F, COTTONE M, MONTALBANO LM, D'AMICO G, OLIVO M, ORLANDO R, ORLANDO A. Efficacy and safety of endoscopic balloon dilation of symptomatic intestinal Crohn's disease strictures. *Dig Liver Dis* 2011;43(2):121-5.

Sažetak

ENDOSKOPSKA BALONSKA DILATACIJA POSLIJEOPERACIJSKIH CRIJEVNIH STRIKTURA KOD CROHNOVE BOLESTI: PRIKAZ SLUČAJA I PREGLED LITERATURE

N. Ljubičić, A. Bišćanin, I. Nikić, I. Budimir, M. Nikolić i T. Pavić

Striktura su jedna od najčešćih komplikacija Crohnove bolesti. Ako su simptomatske i rezistentne na protuupalnu terapiju, a naročito u slučajevima akutne opstrukcije, kirurška korekcija može biti neizbježna. Iako je kirurško liječenje izrazito uspješno u liječenju striktura Crohnove bolesti, endoskopski je prepoznata visoka stopa poslijeoperacijskih restenoza, što u konačnici zahtijeva dodatnu operaciju. Da bi se izbjegli rizici i troškovi povezani s kirurškom resekcijom predložena je endoskopska balonska dilatacija (EBD) kao konzervativna opcija za liječenje crijevnih striktura u Crohnovoj bolesti, kojom se striktura pneumatski širi TTS balonima različitih promjera. Glavna klinička indikacija za EBD je pojava opstruktivnih simptoma povezanih sa strikturom, osobito ako su poslijeoperacijske i kraće od 4 centimetra. Za svaku strikturu potrebno je u pravilu više od jedne dilatacije. EBD se ne primjenjuje često, vjerojatno zbog zapaženog rizika od perforacije i ranog recidiva strikture; no, studije su pokazale da EBD ima visoku stopu uspjeha, nisku vjerojatnost komplikacija, odličan simptomatski odgovor, kao i dobar kratkoročni i dugoročni ishod, dokazujući da je to relativno jednostavna i uspješna tehnika koja osigurava dugotrajno i učinkovito ublažavanje simptoma uz minimalan rizik u bolesnika s jednostavnim strikturama, te da nudi razumnu alternativu operaciji.

Ključne riječi: Striktura, patološka – kirurgija; Endoskopija, gastrointestinalna – metode; Crohnova bolest – komplikacije