

Šahza Hatibović-Kofman, Clive Schneider-Friedman, Jeta Bylykbashi, Muni El-Kassem

Retrospektivno kliničko istraživanje liječenja pulpe željeznim sulfatom i formokrezolom

Retrospective Clinical Study of Pulp Treatment with Ferric Sulfate and Formo Cresol

Odjel za ortodonciju i pedodonciju, Sveučilište Western Ontario, London, Kanada
Division of Orthodontics and Paediatric Dentistry, University of Western Ontario, London, Canada

Sažetak

Svrha je istraživanja usporediti ishod pulpotomije razrijeđenim formokrezolom (DFC-om) i rezultat pulpotomije željeznim sulfatom (FS-om) koje su obavili pedodonti u privatnim ordinacijama (PP-ima) i studenti u simuliranoj okolini ordinacije (SPEC-u) na Sveučilištu Western Ontario u Londonu (Ontario, Kanada).

Materijali i metode: klinički i rendgenski podaci prikupljeni su retrospektivno iz kartona u PP-ima i SPEC-u. Isti klinički protokol proveden je u oba okruženja. Kriteriji za uključivanje pacijentovih podataka bili su:

1. morao je dolaziti u ordinaciju barem dvije godine nakon liječenja pulpe
2. morao je dolaziti na kontrolne preglede svakih šest ili dvanaest mjeseci
3. morao je imati najmanje dvije rendgenske snimke snimljene za redom.

Rezultati: Ukupno su proučena 354 mliječna molara. U PP-u je klinički/rendgenski uspjeh nakon 3 godine iznosio 99% - 97% za DFC i 98% - 96% za FS. Nije bilo značajne razlike ($p > 0,05$) u kliničkom rezultatu DFC-a i FS-a u oba okruženja. No, rendgenski ishod bio je znatno veći ($p < 0,05$) za obje liječene skupine u PP-u, u usporedbi sa SPEC-om.

Zaključci: DFC i FS imaju isti učinak u terapiji pulpe mliječnih zuba. Rendgenski uspjeh obiju skupina manje je izražen od kliničkoga. Iako su studenti pulpe mliječnih zuba liječili visokokvalitetno, nisu postigli razinu svojih mentora. Ukupni rezultati opravdavaju uporabu netoksičnoga željeznog sulfata kao lijeka prvog izbora za pulpotomiju u odnosu prema formokrezolu.

Zaprimljen: 24. svibnja 2006.

Prihvaćen: 1. lipnja 2006.

Adresa za dopisivanje

Dr. Šahza Hatibović-Kofman
Division of Orthodontics and Paediatric Dentistry
School of Dentistry, Faculty of Medicine & Dentistry
Dental Sciences Building, Room 1012
University of Western Ontario
1152 Richmond Street
London, Ontario, Canada, N6A 5C1
sahza.kofman@schulich.uwo.ca

Ključne riječi

pulpotomija; formokrezol; endodoncija; mliječni zub

Uvod

Mnogo se napora uložilo kako bi se odredila najsigurnija i najdjelotvornija metoda čuvanja pulpe mliječnih zuba i spriječila patoza pulpe. Stručnjaci su pokušali kombinirati najučinkovitiju tehniku liječenja vitalne pulpe s najpouzdanijim materijalima. Prošlih deset godina publicirano je mnogo istraživanja u kojima su se proučavali različiti materijali koji se koriste za pulpotomiju mliječnih zuba (1-15).

Otkako je godine 1904. uveden u stomatologiju, formokrezol je popularno sredstvo za pulpotomiju,

Introduction

Many efforts have been made to determine the safest and most efficient method of preserving primary dental pulp and preventing pulpal pathosis. Researchers have attempted to combine the most effective vital pulp therapy technique with the most reliable materials. The past decade has produced a number of studies researching different materials for use in pulpotomies of primary teeth (1-15).

Since its introduction in 1904, Formo Cresol has been a popular pulpotomy agent which is still wide-

a i danas se često koristi. (13, 15, 16). Unatoč visokim stopama uspjeha formokrezola kao ljekovitog sredstva za pulpu, «pod povećalom» je zbog moguće lokalne i sistemske toksičnosti. Formaldehidni dio formokrezola pokazao je toksična, mutagena i karcinogena svojstva (16-31). Ti su podaci potaknuli istraživače u pedodonciji da pronađu isto tako djelotvoran, ali netoksičan materijal koji se može koristiti za pulpotomiju.

Pulpotomija željeznim sulfatom (FS) pojavila se kao razmjerno novi standard liječenja pulpe mliječnih molara te se taj preparat ispitivao kako bi se ustanovilo može li nadomjestiti formokrezol. Mehanizam djelovanja željeznog sulfata jest aglutinacija krvnih proteina i kontrola krvarenja te sprječavanje stvaranja ugruška. Klinička istraživanja pokazala su slične (1, 5, 6, 9) ili bolje (12, 13) kliničke i rendgenske stope uspjeha željeznog sulfata u usporedbi s razrijeđenjem formokrezola u odnosu 1:5. U retrospektivnom istraživanju su Smith i suradnici dokazali niže stope uspjeha željeznog sulfata od onih ranije objavljenih u literaturi (11). Ipak, mogle su se usporediti s onima kod pulpotomije formokrezolom.

Pulpotomija je kod djece klinički dosta zahtjevana i traži veliku spretnost terapeuta. U nekoliko retrospektivnih i prospektivnih istraživanja uspoređivalo se pulpotomije DFC-om i FS-om. No, ni u jednome do sada nisu se uspoređivali ishodi pulpotomija DFC-om i FS-om koje obavljaju studenti i njihovi mentori.

Svrha ovog istraživanja bila je procijeniti i usporediti rezultate pulpotomija razrijeđenim formokrezolom u omjeru 1:5 i pulpotomija željeznim sulfatom, a provodili su ih na mliječnim zubima pedodonti (mentori) i studenti stomatologije.

Materijal i metode

Klinički i rendgenski podaci skupljeni su retrospektivno iz kartona u privatnoj ordinaciji na adresi: 577 Oxford Street, London (Ontario, Kanada) (PP) te iz simulirane okoline ordinacije (SPEC-a) na Sveučilištu Western Ontario. U istraživanju su bili uključeni pacijenti kojima su na mliječnim molari-ma obavljene pulpotomije, njihovi su zubi analizirani te je procijenjena stopa uspjeha/neuspjeha. Identiteti svih pacijenata bili su zaštićeni šiframa.

Istraživanje je obuhvatilo 200 pacijenata (270 pulpotomija) u privatnoj ordinaciji i 62 (84 pulpotomije) u SPEC-u. Spol nije bio kriterij za uključivanje, a pacijenti su na početku liječenja pulpe bili u dobi od 3 do 6 godina. Kriteriji za razmatranje pacijentovih podataka bili su: a) morao je dolazi-

ly used clinically (13, 15, 16). Despite the high success rates of Formo Cresol as a pulp medicament, its use has been under much scrutiny due to its possible local and systemic toxicity. The formaldehyde content of Formo Cresol has been shown to be toxic, mutagenic and carcinogenic (16-31). These findings have urged researchers in pediatric dentistry to find an equally effective yet non-toxic material for use in pulpotomies.

Ferric Sulfate (FS) pulpotomy has emerged as a relatively new standard of pulp therapy in primary molars and has been investigated as a possible replacement to Formo Cresol. The mechanism of action of Ferric Sulfate is to agglutinate blood proteins and control bleeding while preventing clot formation. Clinical studies have reported similar (1, 5, 6, 9) or higher (12, 13) clinical and radiographic success rates of Ferric Sulfate as compared to 1:5 dilute Formo Cresol. In a retrospective study, Smith et al showed lower success rates for Ferric Sulfate than those previously reported in the dental literature (11). Nevertheless, these success rates were comparable with those reported for dilute Formo Cresol pulpotomies.

Pulpotomy is clinically quite demanding in children and requires high skill levels from the providers. A few retrospective and prospective clinical studies have compared DFC and FS pulpotomies. However, no study has yet compared the outcomes of DFC and FS pulpotomies performed by students and those performed by their instructors.

The objective of this study is to assess and compare the outcomes of 1:5 diluted Formo Cresol pulpotomies and Ferric Sulfate pulpotomies performed on primary teeth by pediatric dentists (Instructors) and dental students.

Materials and Methods

Clinical and radiographic data were retrospectively collected from charts at a private paediatric office located at 577 Oxford Street in London, Ontario, Canada, and at the Simulated Practice Environment Clinic (SPEC) at the University of Western Ontario. Patients that had pulpotomies in their primary teeth were included in this study and their teeth were analyzed and the failure/success rates were assessed. The patients' identities were protected by using codes instead of names.

The study comprised 200 patients (270 pulpotomies) in the private practice and 62 patients (84 pulpotomies) in the SPEC. Gender was not a criterion for inclusions and patients ranged between 3 and

ti u ordinaciju kao pacijent najmanje dvije godine nakon liječenja pulpe; b) morao je dolaziti na kontrolne preglede svakih 6 ili 12 mjeseci; c) morao je imati najmanje dvije rendgenske snimke za redom; d) rendgenske snimke morale su biti pravilne gustoće te imati potvrđenu i prihvatljivu dijagnostičku kvalitetu.

Samo jedan autor – educirao ga je dentalni radiolog - analizirao je sve rendgenske snimke. Klinički uspjeh liječenja pulpe zabilježen je ako je karton pokazivao da nije bilo boli, osjetljivosti na perkusiju, oticanja, fistule i/ili patološke mobilnosti. Kao rendgenski uspjeh smatrala se i odsutnost patološke resorpcije - interne ili eksterne, odsutnost radiolucencije u furkaciji ili periapikalno te kalcifikacijske metamorfoze. Podaci u kartonu za svakog pacijenta uključivali su spol, datum rođenja, datum liječenja te vrijeme praćenja u mjesecima. Rezultati formokrezola i željeznog sulfata analizirani su testom hi-kvadrat.

Tehnika pulpotomije

Isti postupak pulpotomije provodio se na objema lokacijama tijekom posljednjih 15 godina s redovitim jednogodišnjim osvježivanjima tijekom Pokrajinskih susreta na School of Dentistry. Svi mentori smatraju da su njihove tehnike kalibrirane. Svi pacijenti su odgovarajuće anestetizirani, a zubi su izolirani koferdamom. Karijes je uklonjen prije pristupa koronalnoj pulpi, a on je napravljen sterilnim svrdlom s velikim brojem okretaja i vodenim ispiranjem, kako bi se penetrirao krov pulpne komore. Koronalna pulpa je amputirana sterilnim ekskavatorom i/ili okruglim svrdlom s malim brojem okretaja. Krvarenje je kontrolirano vatenim rolama, a ako ga nije bilo moguće zaustaviti, obavljena je pulpektomija ili ekstrakcija.

Zubi koji su tretirani razrijeđenim formokrezolom isprani su sterilnom fiziološkom otopinom. Zatim je na vrh ostavljene pulpe postavljena kuglica vate s razrijeđenim formokrezolom i ostavljena pet minuta kako bi fiksirala pulpu. Nakon toga pulpna rana prekrivena je materijalom Zoe B&T[®] te je na zub postavljena čelična krunica kao trajni nadomjestak. Zubi tretirani željeznim sulfatom također su najprije isprani sterilnom fiziološkom otopinom, a na pulpnu ranu je stavljena otopina željeznog sulfata ViscoStat[®] Ultradent kako bi se osigurala hemostaza. Zatim je rana isprana 15 sekundi sterilnom vodom, pa je prekrivena materijalom Zoe B&T[®] te je na zub postavljena čelična krunica kao trajni nadomjestak.

6 years of age at the beginning of the pulp treatment. Inclusion criteria for consideration of patient's data were: a) the patient must have remained in the clinic as "active patient" for at least two years following pulp therapy; b) the patient must have regularly attended his/her recall examinations at 6 or 12 month intervals; c) the patient must have had at least two sequential radiographs taken at recall examination following pulp therapy; d) radiographs demonstrated proper film density and contrast and proved to be of acceptable diagnostic quality.

Only one investigator, trained by a dental radiologist, analyzed all radiographs. Clinical success of pulpal therapy was registered if the treatment record indicated no registration of feeling pain, tenderness to percussion, swelling, fistulation and/or pathologic tooth mobility. Radiographic success was considered as absence of pathologic resorption, both internal or external, furcation or periapical radiolucency and calcific metamorphosis. Data collected for each patient during chart review included gender, date of birth, tooth number, treatment date and follow-up time in months. Results of Formo Cresol and Ferric Sulfate pulpotomies were analyzed utilizing the chi square test.

Pulpotomy Technique

The same pulpotomy procedure has been performed at both locations for the last 15 years with regular annual updates during Divisional Meetings of the School of Dentistry. All instructors ensure that their techniques are calibrated. All patients were adequately anesthetized and teeth were isolated with a rubber dam. Caries were removed before accessing the coronal pulp. Access was made with a sterile bur in a high speed instrument with water irrigation to penetrate the roof of the pulp chamber. Coronal pulp was amputated with a sterile spoon excavator and/or round bur in a slow speed instrument. The bleeding was controlled by cotton pellets. If the hemorrhage was not arrested, pulpectomy or extraction was performed.

Teeth that were treated with Dilute Formo Cresol pulpotomy were rinsed with sterile saline. A cotton pellet with dilute Formo Cresol was then placed over the amputated pulp for 5 minutes to fixate the pulp. Zoe B & T[®] was then used to cover the pulp stumps and a stainless steel crown (SSC) was placed, as a permanent restoration. Those teeth treated with Ferric Sulfate pulpotomy were also rinsed with sterile saline.

ViscoStat[®] 15.5% Ferric Sulfate Ultradent solution was placed with a disposable brush over the pulp stumps to ensure haemostasis. The pulp was

Pacijenti su se procjenjivali tijekom kontrolnih pregleda u svrhu kliničkih i rendgenskih simptoma neuspjeha liječenja vitalne pulpe. Kontrolni posjeti bili su u razmacima od 6 do 12 mjeseci, 13 do 24 mjeseca te 25 do 36 mjeseci. Potrebno je znati da je mnogo više kartona dobiveno iz PP-a nego iz SPEC-a, budući da najmanje 50% pacijenata iz SPEC-a ne surađuje dovoljno, to jest ne dolazi na kontrolne preglede.

Rezultati

Istraživanje je provedeno na 262 djece u dobi od 3 do 6 godina na početku liječenja - 200 iz privatne ordinacije te 62 iz klinike SPEC-a. Ukupno su pregledana 354 mliječna molara; a 250 (184 iz privatne ordinacije i 66 iz SPEC-a) liječeno je pulpotomijom s razrijeđenim formokrezolom, a 104 (86 iz privatne ordinacije i 18 iz SPEC-a) liječeno je pulpotomijom sa željeznim sulfatom. Distribucija liječenih zuba i lokacija liječenja prikazani su na Tablici 1.

then rinsed for 15 seconds with sterile water. Zoe B & T[®] was placed over the pulp stumps and a SSC was then placed, as a permanent restoration.

Patients were evaluated at recall visits for any clinical or radiographic signs or symptoms of vital pulp therapy failure. Follow-up appointments were made at 6-12 months, 13-24 months, 25-36 months intervals. It should be noted that many more clinical records at PP were obtained than at SPEC because at least 50% of patients at the latter facility do not comply with regular recall visits.

Results

The study consisted of 262 children, 3-6 years of age at the beginning of the treatment; 200 from private practice and 62 from the SPEC clinic. A total of 354 primary molars were studied; 250 (184 from private practice and 66 from SPEC) were treated with Dilute Formo Cresol pulpotomy and 104 (86 from private practice and 18 from SPEC) were treated with Ferric Sulfate pulpotomy. Distribution of treated teeth and location of treatment is presented in Table 1.

Tablica 1. Distribucija zuba liječenih DFC-om i FS-om u PP-u i SPEC-u

Table 1 Distribution of the treated teeth with DFC and FS in PP and SPEC

Zub • Tooth	Lokacija • Location	DFC	FS	Ukupno • Total
Maksila • Maxilla				
1. molar • 1 st molar	PP	15	39	54
	SPEC	3	22	25
2. molar • 2 nd molar	PP	18	26	44
	SPEC	2	6	8
Mandibula • Mandibular				
1. molar • 1 st molar	PP	32	58	90
	SPEC	8	22	30
2. molar • 2 nd molar	PP	21	61	82
	SPEC	5	16	21
UKUPNO • TOTAL	PP	86	184	270
	SPEC	18	66	84

PP - Privatna ordinacija • Private practice

SPEC - Ordinacija Sveučilišta Western Ontario • Environment Clinic University Western Ontario

DFC - Razrijeđeni formokrezol • Dilute Formo Cresol

FS - Željezni sulfat • Ferric Sulfate

Rendgenski nalazi

Od 354 liječena zuba, 26 (7,3%) je imalo rendgenski neuspjeh, bez obzira na uporabljeni materijal i mjesto liječenja (Tablica 2.).

Polovina tih neuspjeha (13 od 26, 50%) pojavila se u razdoblju od 13. do 25. mjeseca. U PP-u je 8 od 270 pulpotomija (2%) upozoravalo na neuspjeh na temelju rendgenskih snimki, s internom resorpcijom kao najprevalentnijim nalazom. U SPEC-u je 18 od

Radiographic Findings

Out of 354 treated teeth, 26 (7.3%) showed radiographic failure with no relationship with the material used or the location of the treatment. (Table 2).

Half of those failures, (13 out of 26; 50%) occurred within a 13-25 month period. In PP, 8 out of 270 (2%) pulpotomies showed radiographic failure with internal resorption being the most prevalent. In

84 (21%) pulpotomija upozoravalo na neuspjeh na temelju rendgenskih snimki, s kalcifikacijskom metamorfozom kao najprevalentnijim nalazom.

SPEC, 18 out of 84 (21%) pulpotomies showed radiographic failure with calcific metamorphosis being the most prevalent.

Tablica 2. Distribucija rendgenskih neuspjeha tijekom vremena u PP-u i SPEC-u
Table 2 Distribution of Radiographical failure over time in PP and SPEC.

Radiološki nalaz • Radiographic finding	Lokacija • Location	6-12 mjeseci • 6-12 months		13-24 mjeseci • 13-24 months		25-36 mjeseci • 25-36 months	
		DFC	FS	DFC	FS	DFC	FS
Unutrašnja resorpcija • Internal Resorption	PP	0	0	0	1	1	2
	SPEC	0	0	2	0	0	0
Vanjska resorpcija • External Resorption	PP	0	0	1	0	0	0
	SPEC	0	0	3	0	1	0
Resorpcija interradikularnih kosti • Interradicular bone Resorption	PP	0	1	0	1	0	0
	SPEC	1	1	1	0	2	0
Kalcifična metamorfoza • Calcific metamorphosis	PP	0	0	0	0	1	0
	SPEC	0	1	2	2	2	0

PP - Privatna ordinacija • Private practice
 SPEC - Ordinacija Sveučilišta Western Ontario • Environment Clinic University Western Ontario
 DFC - Razrijeđeni formokrezol • Dilute Formo Cresol
 FS - Željezni sulfat • Ferric Sulfate

Klinički nalazi

Od 354 pulpotomije, 6 (2%) pokazivalo je klinički neuspjeh (Tablica 3.). U SPEC-u su 4 apscesa bila povezana s neuspjelom pulpotomijom (3 liječena DFC-om, 1 FS-om), U PP-u su bila dva klinička neuspjeha - po jedan za svaki medikament. Svi klinički neuspjesi dogodili su se između 6. i 12. mjeseca praćenja. Sveukupni klinički i rendgenski uspjeh prikazan je na Tablici 4. i Slici 1.

Nije bilo znatne razlike ($p < 0,05$) u kliničkom ishodu između liječenih skupina DFC-a i FS-a), ni između lokacija (PP-a i SPEC-a). Također nije bilo znatne rendgenske razlike ($p > 0,05$) između zuba liječenih DFC-om i FS-om liječenih u PP-u i SPEC-u. Statistička analiza pokazala je da je rendgenski uspjeh znatno veći ($p < 0,05$) za obje liječene skupine (DFC i FS) u PP-u u usporedbi sa SPEC-om.

Clinical Findings

Out of 354 pulpotomies, 6 (2%) showed clinical failure. In SPEC, 4 abscesses associated with failed pulpotomies (3 with DFC treatment and 1 with FS treatment). In PP, 2 clinical failures were observed; 1 for each medicament. All clinical failures occurred within a 6-12 month period. Overall clinical and radiographic success is presented in Table 4 and Fig. 1.

There was no significant difference, ($p > 0.05$) in clinical outcomes between treatment groups (DFC and FS) or between locations (PP and SPEC). There was also no significant radiographic difference, ($p > 0.05$) between teeth treated with DFC and FS within groups treated at SPEC and at PP. However, statistical analysis revealed that radiographic success was significantly higher, ($p < 0.05$) for both treatment groups (DFC and FS) at PP than at SPEC.

Tablica 3. Distribucija kliničkih neuspjeha u PP-u i SPEC-u
Table 3 Distribution of Clinical Failure in PP and SPEC

Klinički nalaz • Clinical Finding	DFC	FS
PP	1 apsces • 1 abscess	1 apsces • 1 abscess
SPEC	3 apscesa • 3 abscesses	1 apsces • 1 abscess

PP - Privatna ordinacija • Private practice
 SPEC - Ordinacija Sveučilišta Western Ontario • Environment Clinic University Western Ontario
 DFC - Razrijeđeni formokrezol • Dilute Formo Cresol
 FS - Željezni sulfat • Ferric Sulfate

Tablica 4. Klinički i rendgenski neuspjesi/uspjesi DFC-a i FS-a u PP-u i SPEC-u
Table 4 Clinical and Radiographical failure/success of DFC and FS in PP and SPEC

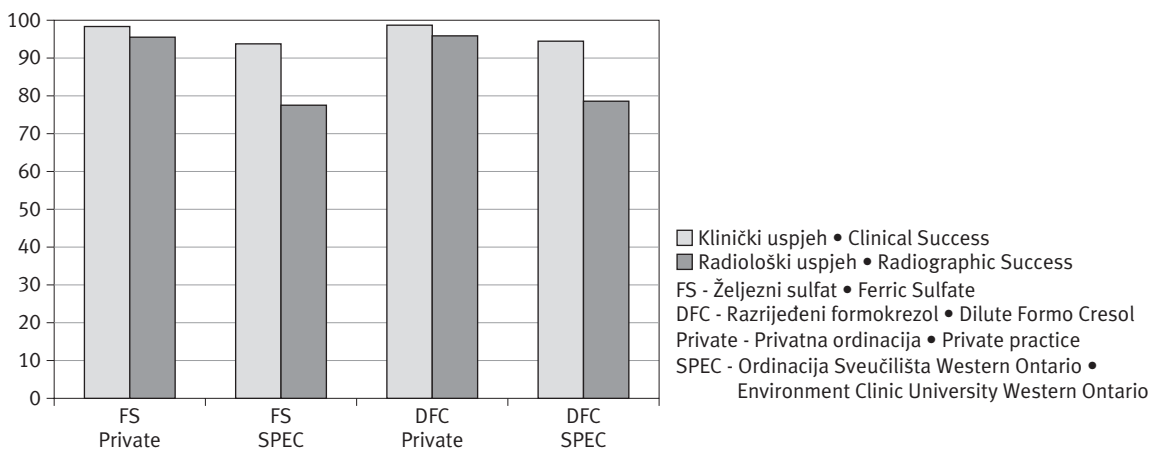
Pulpno sredstvo • Pulp Med.	Lokacija • Location	Broj zubi • # of teeth	Klinički neuspjeh • Clinical Failure		Radiološki neuspjeh • Radiographic Failure		Klinički uspjeh • Clinical Success	Radiološki uspjeh • Radiographic Success
			N	%	N	%	%	%
FS	PP	86	1	1.16	3	3.5	98.8	96.5
	SPEC	18	1	5.56	4	22.2	94.4	77.8
DFC	PP	184	1	0.5	5	2.7	99.5	97.2
	SPEC	66	3	4.5	14	21.2	95.4	78.8

PP - Privatna ordinacija • Private practice

SPEC - Ordinacija Sveučilišta Western Ontario • Environment Clinic University Western Ontario

DFC - Razrijeđeni formokrezol • Dilute Formo Cresol

FS - Željezni sulfat • Ferric Sulfate



Slika 1. Stope kliničke i rendgenske uspješnosti liječenja pulpe DFC-om i FS-om u PP-u i SPEC-u
Figure 1 Clinical and Radiographic Success Rates of Pulp Treatment with DFC & FS in PP and SPEC.

Rasprava

Vitalno liječenje pulpe mliječnih zuba dobro je istražen postupak u pedodonciji. Tehnika pulpotomije često se koristi i prihvaća kao djelotvorna metoda liječenja za opsežne karijesne lezije mliječnih zuba (30). Svrha uklanjanja koronalnoga pulpnog tkiva jest eliminacija upaljenog tkiva i mikroorganizama u njemu. Formokrezol se koristi kao fiksativ za dio pulpnog tkiva koje ostaje. Željezni sulfat ispitivao se kako bi se odredila njegova učinkovitost u usporedbi s formokrezolom koji bi mogao zamijeniti kao toksičnijeg preteču. Željezni sulfat je kemijski spoj bez formaldehida, a kao hemostatski agens koristi se kod uzimanja otisaka za krunice i mostove te u endodonciji. Smatra se da djeluje tako što blokira kapilarni krvotok, čime počinje hemostazu bez stvaranja ugruška.

Ovo istraživanje pokušalo je usporediti kliničke i rendgenske stope uspjeha pulpotomija željeznim sulfatom i formokrezolom u privatnoj ordinaciji i SPEC-u. Nedostatak istraživanja je neproporcionalni

Discussion

Vital pulp therapy in primary teeth has been widely studied in pediatric dentistry. The pulpotomy technique has been commonly used and accepted as an efficient treatment method for extensively carious primary teeth (30). The purpose of removing coronal pulp tissue is to eliminate inflamed tissue and its constituent microorganisms. Formo Cresol has been used in pulpotomies as a fixative for a portion of the remaining pulp tissue. Ferric Sulfate has been researched to determine its efficiency when compared to Formo Cresol as it could replace its more toxic predecessor. Ferric Sulfate is a non-formaldehyde containing chemical which has been used as a haemostatic agent in crown and bridge impressions and in endodontics. It is thought to act by blocking capillary blood flow and thus initiating haemostasis without any clot formation.

The current study attempts to compare the clinical and radiographic success rates of Ferric Sulfate and Formo Cresol pulpotomies at both private prac-

broj slučajeva između dviju skupina (PP-a i SPEC-a). Razlog za to je činjenica da najmanje 50% pacijenata ne dolazi redovito na preglede, zbog toga što se često sele. Unatoč tome, rezultati su u skladu s drugim istraživanjima (1, 5, 19) te pokazuju slične stope kliničke i rendgenske uspješnosti pulpotomija DFC-om i FS-om u privatnoj ordinaciji i u SPEC-u. Stope rendgenske uspješnosti bile su znatno više u privatnoj ordinaciji nego u SPEC-u - i za DFC i za FS. Potrebno je reći da je u istraživanju većina neuspjeha u PP-u bila uzrokovana internom resorpcijom, a u SPEC-u kalcifikacijskom metamorfozom, bez potrebe za imedijatnim djelovanjem. Pulpotomije DFC-om pokazuju malo veću kliničku uspješnost u PP-u u usporedbi sa SPEC-om. Pulpotomije FS-om pokazuju sličnu kliničku uspješnost na objema lokacijama.

Rendgenske i kliničke stope uspješnosti kod željeznog sulfata u PP-u pokazale su se u ovom istraživanju višima nego u nedavno objavljenom istraživanju (11). Te stope se također mogu usporediti s onima u drugim istraživanjima (5, 8, 12). I dok su rendgenske stope uspješnosti za željezni sulfat u SPEC-u bile niže od onih u novijoj literaturi, kliničke stope uspješnosti bile su slične (5, 6, 12).

Potrebno je reći da su stope uspješnosti pulpotomija koje provode studenti u SPEC-u možda pod utjecajem studentskog rada. Uz stručan i pažljiv nadzor mentora, pulpotomije se obavljaju na razini uvodnih vježbi. Rendgenski i klinički neuspjesi možda su pogreške terapeuta, dijagnostike i odabira slučaja, a ne utjecaja lijeka.

Preporuka

Slične stope uspješnosti za željezni sulfat u PP-u i SPEC-u upućuju na činjenicu da bi se studenti u pulpotomiji trebali koristiti željeznim sulfatom. Isto tako, trebalo bi ga rabiti u privatnim ordinacijama, budući da ima slične stope kliničke i rendgenske uspješnosti, ako se usporedi s toksičnim formokrezolom.

Unatoč tome što je ovo istraživanje pokazalo slične stope uspješnosti za pulpotomije formokrezolom i željeznim sulfatom kao i druga istraživanja (1,10,12), još uvijek se željezni sulfat može predlagati kao zamjena formokrezolu. Drugi lijekovi koji obećavaju, na primjer agregat mineralnog trioksida (MTA), trebaju se još ispitati. Zapravo, na temelju podataka iz radova koje su objavili Huth i suradnici (13), Eideman i suradnici (31), Schmidt i suradnici (32) te Hatibović-Kofman i suradnici (34), MTA je nedavno uvršten među sredstva za liječenje pulpe na Sveučilištu Western Ontario.

tice and SPEC. A shortcoming of this study is the disproportionate number of cases between the two groups (PP and SPEC). The reason is that at least 50% of the patients do not come for regular recall appointments due to frequent relocation. In spite of that, the results are consistent with other studies (1, 5, 19) in showing similar clinical and radiographic success rates of DFC and FS pulpotomies at both private practice and SPEC. Radiographic success rates, however, are found to be significantly higher in private practice than in the SPEC for both DFC and FS pulpotomies. It should be mentioned that in this study most of the radiographic failure at PP is due to internal resorption and at SPEC is due to calcific metamorphosis without the need for immediate extraction. DFC pulpotomies show slightly higher clinical success rates in PP than in SPEC. FS pulpotomies show more similar clinical success rates at both locations.

The radiographic and clinical success rates for Ferric Sulfate pulpotomies in PP were found to be higher in this study than those reported in a recent study (11). These rates were also comparable to those reported in other studies (5, 8, 12). Whereas, the radiographic success rates for Ferric Sulfate pulpotomies performed at SPEC were lower than those reported in the recent literature, the clinical success rates were found to be similar (5, 6, 12).

It should be noted that success rates of pulpotomies performed by the dental students at SPEC might have been influenced by student manipulation. With close instructor observation, pulpotomies are performed as an introductory level requirement. Radiographic and clinical failure may have been introduced by operator error, diagnosis and case selection rather than by the nature of the pulp medicament.

Recommendation

Similar clinical success rates using Ferric Sulfate at PP and SPEC with Ferric Sulfate suggests that dental students should preferably use the Ferric Sulfate pulpotomy as vital pulp therapy. As well, Ferric Sulfate should be used in private practice, as it shows similar clinical and radiographic successes when compared to toxic Formo Cresol.

Despite the fact that this study found similar success rates for Formo Cresol and Ferric Sulfate pulpotomies as some other studies (1, 10, 12) one can still suggest that Ferric Sulfate can replace Formo Cresol. The other promising medicaments, such as Mineral Trioxide Aggregate (MTA) should also be researched. In fact, based on the findings by Huth

Zaključci

1. Razrijeđeni formokrezol i željezni sulfat imaju istu učinkovitost u liječenju pulpe mliječnih zuba;
2. Rendgenska uspješnost obaju sredstava na objema lokacijama niža je od kliničke;
3. Studenti na UWO-u visokokvalitetno liječe pulpu mliječnih zuba. Njihovi se rezultati mogu usporediti sa citiranom literaturom;
4. Rendgenski i klinički uspjeh pedodonata je među najvišima u citiranoj literaturi;
5. Željezni sulfat, netoksično ljekovito sredstvo, mogao bi biti bolja alternativa razrijeđenom formokrezolu.

Zahvala

Autori zahvaljuju Canadian Institutes of Health Research (CHIR) na financiranju studenata koji su ljeti bili uključeni u ovo istraživanje.

et al, (2005) (13), Eideman et al (2001) (31) and Schmidt et al (2000) (32) Hatibovic-Kofman et al (2006) (34), MTA has been recently (2000) introduced to students at the University of Western Ontario as a vital pulp therapy agent.

Conclusions

1. Diluted Formo Cresol and Ferric Sulfate are equally effective in pulp therapy of primary teeth.
2. Radiographic success for both medicaments at both locations is lower than clinical success.
3. Students at UWO perform high quality pulp treatment in primary teeth. Their results are comparable with the quoted literature.
4. Radiographic and clinical success of paediatric dentists is amongst the highest in the quoted literature.
5. Ferric Sulphate, a non-toxic medicament, could be a better alternative to Diluted Formo Cresol.

Acknowledgements

The authors acknowledge the Canadian Institutes of Health Research (CIHR) for funding of the summer student involved in this research.

Abstract

Research Objective: To compare outcomes of Diluted Formo Cresol (DFC) pulpotomies versus Ferric Sulphate (FS) pulpotomies performed by paediatric dentists in Private Practice (PP) and those performed by students in Simulated Practice Environment Clinic (SPEC) at the University of Western Ontario, London, ON, Canada. Clinical and radiographic data were retrospectively collected from charts in PP and SPEC. The same, clinical protocol followed in both settings. Inclusion criteria for consideration of patient's data were:

1. The patient must have remained in the clinic at least 2 years following pulp treatment.
2. The patient must have attended his/her recall examinations at 6 or 12 month intervals.
3. The patient must have had at least two sequential radiographs.

A total of 354 primary molars were studied. At PP, clinical/radiographic success after 3 years was 99% / 97% for DFC and 98% / 96% for FS. At SPEC, clinical /radiographic success was 95% / 78% for DCF and 94% / 77% for FS. No significant difference ($p > 0.05$) was observed in clinical outcomes between DFC and FS treatment groups at both settings (PP / SPEC). However, radiographic success was significantly higher ($p < 0.05$) for both treatment groups at PP than at SPEC.

DFC and FS medicaments are equally effective in pulp therapy of primary teeth. Radiographic success of both treatment groups at both settings is less pronounced than clinical success. Even though students performed high quality pulp treatment for primary teeth, they did not match their instructors' performance. Overall, the results justify the use of non-toxic Ferric Sulphate over Formo Cresol as a primary pulpotomy agent.

Received: May 24, 2006

Accepted: June 1, 2006

Address for correspondence

Dr. Šahza Hatibović-Kofman
Division of Orthodontics and Paediatric Dentistry
School of Dentistry, Faculty of Medicine & Dentistry
Dental Sciences Building, Room 1012
University of Western Ontario
1152 Richmond Street
London, Ontario, Canada N6A 5C1
sahza.kofman@schulich.uwo.ca

Key words

pulpotomy; formocresols; endodontics; tooth, deciduous

References

- Fuks AB, Eidelman E, Cleaton-Jones P, Michaeli Y. Pulp response to ferric sulfate, diluted formocresol and IRM in pulpotomized primary baboon teeth. *ASDC J Dent Child*. 1997;64(4):254-9.
- Nadin G, Goel BR, Yeung CA, Glennly AM. Pulp treatment for extensive decay in primary teeth. *Cochrane Database Syst Rev*. 2003;(1):CD003220.
- Waterhouse PJ, Nunn JH, Whitworth JM. An investigation of the relative efficacy of Buckley's Formocresol and calcium hydroxide in primary molar vital pulp therapy. *Br Dent J*. 2000;188(1):32-6.
- Waterhouse PJ, Nunn JH, Whitworth JM, Soames JV. Primary molar pulp therapy: histological evaluation of failure. *Int J Paediatr Dent*. 2000;10(4):313-21.
- Ibricevic H, al-Jame Q. Ferric sulfate pulpotomy agent in primary teeth: twenty month clinical follow-up. *J Clin Pediatr Dent*. 2000;24(4):269-72.
- Fuks AB, Holan G, Davis JM, Eidelman E. Ferric sulfate versus dilute formocresol in pulpotomized primary molars: long-term follow up. *Pediatr Dent*. 1997;19(5):327-30.
- Strange DM, Seale NS, Nunn ME, Strange M. Outcome of formocresol/ZOE sub-base pulpotomies utilizing alternative radiographic success criteria. *Pediatr Dent*. 2001;23(4):331-6.
- Fuks AB. Current concepts in vital primary pulp therapy. *Eur J Paediatr Dent*. 2002;3(3):115-20.
- Cleaton-Jones P, Duggal M, Parak M, William S, Setze S. Ferric sulphate and formocresol pulpotomies in baboon primary molars: histological responses. *Eur J Paediatr Dent*. 2002;3(3):121-5.
- Papagiannoulis L. Clinical studies on ferric sulphate as a pulpotomy medicament in primary teeth. *Eur J Paediatr Dent*. 2002;3(3):126-32.
- Smith NL, Seale NS, Nunn ME. Ferric sulfate pulpotomy in primary molars: A retrospective study. *Pediatr Dent*. 2000;22(3):192-9.
- Fei AL, Udin RD, Johnson R. A clinical study of ferric sulfate as a pulpotomy agent in primary teeth. *Pediatr Dent*. 1991;13(6):327-32.
- Huth KC, Paschos E, Hajek-Al-Khatir N, Hollweck R, Crispin A, Hickel R, Folwaczny M. Effectiveness of 4 Pulpotomy Techniques - Randomized Controlled Trial. *J Dent Res*. 2005;84(12):1144-8.
- Ranly DM. Pulpotomy therapy in primary teeth: new modalities for old rationales. *Pediatr Dent*. 1994;16(6):403-9.
- Ranly DM, Garcia-Godoy F. Reviewing pulp treatment for primary teeth. *J Am Dent Assoc*. 1991;122(9):83-5.
- Avram DC, Pulver F. Pulpotomy medicaments for vital primary teeth. Surveys to determine use and attitudes in pediatric dental practice and in dental schools throughout the world. *ASDC J Dent Child*. 1989;56(6):426-34.
- Verco PJ, Allen KR. Formocresol pulpotomies in primary teeth. *J Int Assoc Dent Child*. 1984;15(1):51-5.
- Fuks AB, Bimstein E. Clinical evaluation of diluted formocresol pulpotomies in primary teeth of school children. *Pediatr Dent*. 1981;3(4):321-4.
- Magnusson BO. Therapeutic pulpotomies in primary molars with formocresol technique. *Acta Odontol Scand*. 1978;36(3):157-65.
- Willard RM. Radiographic changes following formocresol pulpotomy in primary molars. *ASDC J Dent Child*. 1976;43(6):414-5.
- Rolling I, Thylstrup A. A 3-year clinical follow up study of pulpotomized primary molars treated with the formocresol technique. *Scand J Dent Res*. 1975;83(2):47-53.
- Morawa AP, Straffon LH, Han SS, Corpron RE. Clinical evaluation of pulpotomies using dilute formocresol. *ASDC J Dent Child*. 1975;42(5):360-3.
- Redig DF. A comparison and evaluation of two formocresol pulpotomy techniques utilizing "Buckley's" formocresol. *J Dent Child*. 1968;35(1):22-30.
- Beaver HA, Kopel HM, Sabes WR. The effect of zinc oxide-eugenol cement on a formocresolized pulp. *J Dent Child*. 1966;33(6):381-96.
- Berger JE. Pulp tissue reaction to formocresol and zinc oxide eugenol. *ASDC J Dent Child*. 1965;32:13-28.
- Judd PL, Kenny DJ. Formocresol concerns. A review. *J Can Dent Assoc*. 1987;53(5):401-4.
- Sun HW, Feigal RJ, Messer HH. Cytotoxicity of glutaraldehyde and formaldehyde in relation to time of exposure and concentration. *Pediatr Dent*. 1990;12(5):303-7.
- Auerbach C, Moutschen-Dahmen M, Moutschen J. Genetic and cytogenetical effects of formaldehyde and related compounds. *Mutat Res*. 1977;39(3-4):317-61.
- Lewis B. Formaldehyde in dentistry: a review for millennium. *J Clin Pediatr Dent*. 1998;22(2):167-77.
- Swenberg JA, Kerns WD, Mitchell RI, Gralla EJ, Pavkov KL. Induction of squamous cell carcinomas of the rat nasal cavity by inhalation exposure to formaldehyde vapor. *Cancer Res*. 1980;40(9):3398-402.
- McDonald RE, Avery DR. Treatment of deep caries, vital pulp exposure, and pulpless teeth. In: McDonald RE, Avery DR, editors. *Dentistry for the Child and Adolescent*. 7th Ed. St. Louis: Mosby, Inc; 2000. p. 413-39.
- Eidelman E, Holan G, Fuks AB. Mineral trioxide aggregate vs. formocresol in pulpotomized primary molars: a preliminary report. *Pediatr Dent*. 2001;23(1):15-8.
- Schmitt D, Lee J, Bogen G. Multifaceted use of Pro-Root MTA root canal repair material. *Pediatr Dent*. 2001;23(4):326-30.
- Hatibovic-Kofman S, Raimundo L, Chong L, Friedman M, Andreasen, J. Mineral Trioxide Aggregate as treatment for immature endodontically treated teeth. *Balkan Stomatological Society Abstract Book, 11th Congress of the BaSS*. 2006. 097:37.