

Dubravka Knezović Zlatarić<sup>1</sup>, Senka Meštrović<sup>2</sup>, Draženka Kostelac<sup>3</sup>

# Usporedba debljine korteksa donjeg ruba mandibule kod različitih ortodontskih anomalija, ovisno o dobi i spolu ispitanika

## *The Comparison of Cortical Thickness of the Lower Border of the Mandible in Three Malocclusion Groups Dependent on Age and Gender*

<sup>1</sup> Zavod za stomatološku protetiku Stomatološkog fakulteta Sveučilišta u Zagrebu  
*Department of Prosthodontics, School of Dental Medicine University of Zagreb*

<sup>2</sup> Zavod za ortodonciju Stomatološkog fakulteta Sveučilišta u Zagrebu  
*Department of Orthodontics School of Dental Medicine University of Zagreb*

<sup>3</sup> Dom zdravlja - Otočac  
*Health Center Otočac*

### Sažetak

Radiološko istraživanje kvalitete koštane strukture mandibule jako je važno u određivanju svih oblika stomatološke terapije, pa tako i ortodontske.

Svrha istraživanja bila je linearnim radiomorfometrijskim indeksima odrediti debljinu korteksa donjeg ruba mandibule i ustanoviti prije početka ortodontske terapije je li u korelaciji s pacijentovom dobi, spolom i vrstom anomalije.

Sudjelovalo je sedamdeset i sedam ispitanika - 30 dječaka (42,8%) i 47 djevojčica (57,2%).

Statistička analiza pokazala je da nema znatnih razlika između izmjerenih vrijednosti za mentalni i antegonialni indeks ( $p > 0,05$ ). Vrijednost gonialnog indeksa izmjenog na desnoj strani bila je znatno veća negoli na lijevoj ( $p < 0,05$ ). Vrijednosti linearnih radiomorfometrijskih indeksa povećavaju se s dobi. Debljina korteksa donjeg ruba mandibule izmjerena na angulusu pokazala je najveće vrijednosti u skupini ispitanika s klasom III ( $p < 0,01$ ). Na temelju rezultata može se zaključiti da bi primjena linearnih radiomorfometrijskih indeksa mogla biti klinički važna za evaluaciju rasta i razvoja mandibule i za praćenje rezultata ortodontske terapije.

Zaprimljen: 10. ožujka 2006.

Prihvaćen: 22. svibnja 2006.

### Adresa za dopisivanje

Dr. sc. Dubravka Knezović Zlatarić  
Zavod za stomatološku protetiku  
Stomatološkog fakulteta u Zagrebu  
Gundulićeva 5  
10000 Zagreb  
dkz@email.htnet.hr

### Ključne riječi

debljina korteksa; mandibula;  
ortodontska anomalija

### Uvod

Radiološko istraživanje kvalitete koštane strukture mandibule vrlo je važno u planiranju svih oblika stomatološke terapije, pa tako i ortodontske.

U tu svrhu koriste se mnoge kvantitativne i kvalitativne analize, primjerice denzitometrija (1-4)

### Introduction

Radiographic assessment of "bone quantity" is of great value in planning further dental treatment, orthodontics included.

A large number of quantitative and qualitative measurements of mandibular bone from radiograph-

i morfometrija (1, 2, 4, 5), a najčešća rendgenska snimka koja se koristi za dijagnozu i plan terapije u svakodnevnoj praksi jest ortopantomogram.

Neki kvalitativni, ali i kvantitativni indeksi, kao što su mandibularni kortikalni indeks (6), indeks kvalitete koštanog tkiva (7), panoramski mandibularni indeks (8) i debljina korteksa donjeg ruba mandibule (8-10) koriste se na ortopantomogramima kako bi se odredila kvaliteta kosti i prepoznali simptomi resorpcije i osteoporoze.

U dosadašnjim istraživanjima dokazani su utjecaji dobi, spola i indeksa tjelesne mase na različite kvantitativne i kvalitativne mandibularne indekse (1, 2, 4-6), ali nema studija u kojima bi se upozoravalo na utjecaj različitih ortodontskih anomalija na vrijednosti lineranih radiomorfometrijskih indeksa.

Svrha istraživanja bila je linearnim radiomorfometrijskim indeksima odrediti debljinu korteksa donjeg ruba mandibule i ustanoviti prije početka ortodontske terapije je li u korelaciji s pacijentovom dobi, spolom i vrstom anomalije.

## Ispitanici i postupci

### Uzorak

Kao uzorak odabrani su pacijenti Zavoda za ortodontciju Klinike za stomatologiju KBC-a Zagreb. Svima su rutinski, u dijagnostičke svrhe, snimljeni ortopantomogrami i laterolateralne snimke glave. Etičko povjerenstvo Stomatološkog fakultatu odobrilo je to istraživanje, budući da su rendgenske snimke bile u dijagnostičke svrhe kako bi se planirala ortodontska terapija. Roditelji svih ispitanika potpisali su pristanak.

Izabrani uzorak činilo je 77 pacijenata - 30 dječaka (42,8%) i 47 djevojčica (57,2%). Svi su podijeljeni su u tri dobne skupine prema stupnju dentalne zrelosti: prva skupina sastojala se od ispitanika u dobi od 6 do 12 godina (26 ispitanika, 33,8%), druga skupina od ispitanika dobi od 13 do 15 godina (33 ispitanika, 42,9%) i u trećoj su skupini bili ispitanici u dobi od 16 do 18 godina (18 ispitanika, 23,4%).

### Klasifikacija ortodontskih anomalija

Temeljem rendgenkefalometrijske analize ispitanici su podijeljeni u tri skupine skeletnih anomalija: klasa II/2 (20 pacijenata - 26%), klasa III (30 pacijenata - 35%) i skeletni otvoreni zagriz (27 pacijenata - 39%).

hs have been devised for this purpose, including densitometry (1-4) and morphometry (1, 2, 4, 5). The most common radiographic method for application in general practice is panoramic radiograph, which is often used for the diagnosis and treatment planning.

Some qualitative, as well as quantitative indices, such as mandibular cortical index (6), bone quality index (7), panoramic mandibular index (8) and mandibular cortical thickness measured at different regions of the lower border of the mandible (8-10) have been used on panoramic radiographs to assess the bone quality and to find the signs of resorption and osteoporosis.

Previous studies have already demonstrated the influence of age, gender and body mass index on different qualitative and quantitative mandibular indices (1, 2, 4-6) but there are no reports of the influence of different types of malocclusion on the values of linear radiomorphometric indices.

The aim of this study was to assess the cortical thickness of the lower border of the mandible and to determine its correlation with different age, gender and malocclusion category.

## Materials and methods

### The sample

The patient sample was selected from patients at the Department of Orthodontics, School of Dental Medicine, University of Zagreb. All patients had panoramic radiograph (PR) and lateral cephalograms prior to orthodontic treatment. Ethics Committee of the School of Dental Medicine approved the investigation. The informed consent was signed by a parent.

There were 77 patients - 30 boys (42.8%) and 47 girls (57.2%). The patients were classified into three different age groups according to the dental maturity: group 1 consisted of patients from 6 to 12 years old (26 subjects, 33.8%), group 2 consisted of patients from 13 to 15 years old (33 subjects, 42.9%) and group 3 consisted of patients from 16 to 18 years old (18 subjects, 23.4%).

### Classification of orthodontic anomalies

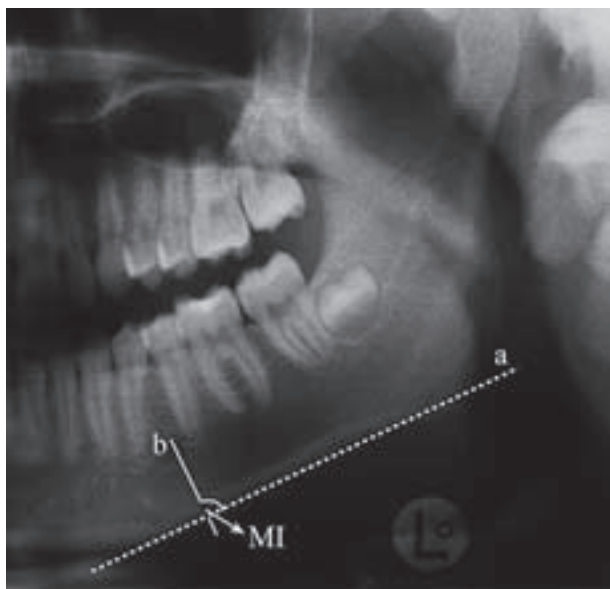
Cephalometric analysis was used to assess different types of skeletal malocclusions. The subjects were classified in three malocclusion groups: Class II/2 (20 patients, 26%), Class III (30 patients, 35%) and skeletal open bite (27 patients, 39%).

### Radiografsko istraživanje

Ortopantomogrami svih ispitanika snimljeni su pri stalnoj struji od 16 mA i ekspoziciji od 16 sekundi pod naponom od 65 do 78 kV (Siemens, Orthopos, Germany). Slike su snimljene Kodakovim filmom i razvijale su se 12 minuta u automatskoj tamnoj komori (Dürr Dental XR 24 Nova).

### Linearna radiomorfometrijska mjerenja

Za procjenu linearnih radiomorfometrijskih indeksa čeljusti ortopantomogrami su promatrani na negatoskopu sa zamućenim izvorom svjetlosti. Mjerenja su obavljena povećalom s povećanjem od 4x (Ghetaldus, Zagreb, Hrvatska) i pomičnom mjerkom (MEBA, Zagreb, Croatia) s preciznošću od 0,01 mm.



**Slika 1.** Crtež prikazuje mjerenje mentalnog indeksa (MI). Linija (b) povučena je kao okomica na tangentu (a) donjeg ruba mandibule kroz središte foramena mentale. Širina korteksa donjeg ruba mandibule izmjerena je duž te linije.

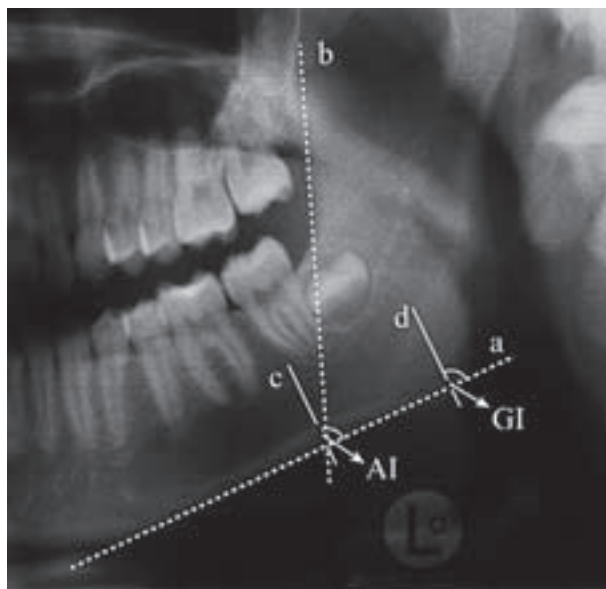
**Figure 1** Diagram showing the measurement of the mental index (MI). A line (b) was drawn perpendicular to the tangent (a) to the lower border of the mandible and through the center of the mental foramen. Measurement was made along this line of cortical width.

### Radiographic Examination

Dental PR was performed with a constant current of 16 mA and an exposure time of 16 sec; the kV varied between 65 and 78 kV (Siemens, Orthopos, Germany). Images were recorded using Kodak film. All films were processed in an automatic dark chamber processor (Dürr Dental XR 24 Nova) for 12 minutes.

### Linear radiomorphometric assessment

To assess cortical thickness of the mandible, the dental panoramic radiographs were viewed using a flat view box in a room with subdued light. Measurements of the linear radiomorphometric indices were made using an x 4 magnifying loupe (Gethaldus, Zagreb, Croatia) and a precise caliper with the precision of a 0.1 mm (MEBA, Zagreb, Croatia).



**Slika 2.** Crtež prikazuje mjerenje antegonijalnog indeksa (AI) i gonijalnog indeksa (GI). Za AI, linija (b) je povučena u produžetku prednjeg ruba uzlaznog kraka mandibule do donjeg ruba mandibule. Linija (c) povučena je okomito na tangentu (a) donjeg ruba mandibule i duž te linije izmjerena je debljina kortikalnog ruba. Za mjerenje GI-a, povučena je linija (d) okomito na tangentu (a) donjeg ruba mandibule kroz gonion, te je na njoj izmjerena širina kortikalnog ruba.

**Figure 2** Diagram showing the measurements of antegonion (AI) and gonion (GI) indices. For AI, line (b) best fitting on the anterior border of the ascending ramus down to the lower border on the mandible was drawn through the tangent (a) to the lower border of the mandible. Line (c) was drawn perpendicular to the tangent (a) and the measurement was made along this line of cortical width. For GI, line (d) was drawn perpendicular to the tangent (a) to the lower border of the mandible and through the gonion. Measurement was made along this line of cortical width.

Sljedeći linearni radiomorfometrijski indeksi izmjereni su na ortopantomogramima: debljina kortikalne kosti donjeg ruba mandibule ispod mentalnog otvora (mentalni indeks - MI), na angulusu mandibule (gonialni indeks - GI) i u projekciji prednjeg ruba vertikalnog kraka mandibule na antegonionu (antegonijalni indeks - AI).

Već su opisane metode mjerenja debljine korteksa na gonionu GI (8), antegonionu AI (9) ispod foramena mentale MI (10) na donjem rubu mandibule. (Slike 1. i 2.).

### Konzistencija ispitivača

Indekse na ortopantomogramima određivala su četiri iskusna ispitivača (već su radili s linearnim radiomorfometrijskim indeksima) i šest općih stomatologa (bez iskustva, pa im je bilo potrebno dati preliminarne upute o spomenutoj metodi). Sva mjerenja ponovljena su za tjedan dana. Nije ustanovljena statistički znatna razlika između prvog i drugog mjerenja ( $p=0,80$  za opće stomatologe;  $p=0,89$  za stomatologe s iskustvom; t-test).

### Statistička analiza

Rezultati su analizirani pomoću statističkog paketa SPSS 10,0 (SPSS for Microsoft Windows, Academic Computing Facility, New York University, 1998.).

Za određivanje normalnosti distribucije izmjerenih varijabli koristio se Kolmogorov-Smirnovljev test. Budući da su rezultati pokazali normalnu distribuciju ( $p>0,05$ ), za daljnju analizu su se koristili parametrijski testovi.

Srednje vrijednosti linearnih radiomorfometrijskih indeksa, izmjerenih na lijevoj i desnoj strani mandibule, uspoređene su pomoću t - testa.

T - test za nezavisne uzorke koristio se za usporedbu srednjih vrijednosti izmjerenih varijabli između spolova ( $p<0,01$ ).

One-way ANOVA i post-hoc Scheffeev test poslužili su za određivanje razlika između izmjerenih varijabli, ovisno o dobi i ortodontskoj anomaliji.

### Rezultati

Sva mjerenja na ortopantomogramima obavljena su obostrano.

T - test je pokazao da nema statistički znatne razlike za MI i AI između desne i lijeve strane mandibule ( $p>0,05$ ). Statistički znatne razlike pronađene su između vrijednosti lijevog i desnog GI-a ( $t=-3,858$ ;  $df=76$ ;  $p<0,05$ ); GI na desnoj strani mandibule bio je statistički znatno veći nego na lijevoj strani (Slika 3.).

The following linear radiomorphometric indices on the lower border of the mandible were measured: cortical thickness below the mental foramen (mental index - MI), at the angle of the mandible (gonion index - GI) and the projection of the vertical part of the mandible on antegonion (antegonial index - AI). The methods of measuring cortical width at gonion GI (8), antegonion AI (9) and below the mental foramen MI (10), on the lower border of the mandible have been described (Figures 1 and 2).

### Observer consistency

Four experienced observers and six inexperienced general dental practitioners assessed indices on all dental panoramic radiographs and the measurement was repeated after a week interval. There was no significant difference between the first and the second measurement ( $p=0.80$  for the general practitioners,  $p=0.89$  for the experienced observers; paired t-test).

### Statistical Analysis

The data were analyzed by the SPSS 10.0 statistical package (SPSS for Microsoft Windows, Academic Computing Facility, New York University, 1998).

One-sample Kolmogorov-Smirnov test was used to analyze the normality of the distribution of all the indices measured in this study. The results had shown normal distribution ( $p>0.05$ ) and parametric tests were used in the further statistical analysis.

Paired-samples t-test was used to compare the mean values of linear radiomorphometric indices measured on the left and on the right side of the mandible.

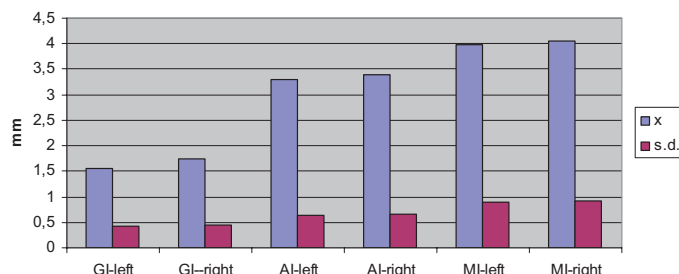
Independent t-test was used to compare all mean values between gender ( $p<0.01$ ).

One-way ANOVA and post-hoc Scheffee's test were used to test the significance of the mean values within the different age and malocclusion categories.

### Results

All measurements in this study were made bilaterally on the panoramic radiographs.

Paired-samples t-test revealed no statistically significant difference for the MI and AI between the left and the right side of the mandible ( $p>0.05$ ), but statistically significant difference was found between the left and the right GI ( $t=-3.858$ ;  $df=76$ ;  $p<0.05$ ); GI on the right side of the mandible was significantly higher than on the left side (Figure 3).



**Slika 3.** Srednje vrijednosti (x) i standardne devijacije (s.d.) izmjerenih vrijednosti gonialnog indeksa (GI), antegonialnog indeksa (AI) i mentalnog indeksa (MI) na lijevoj i desnoj strani mandibule; left = lijevo; right = desno

**Figure 3** Distribution of the gonion (GI), antegonion (AI) and mental (MI) indices measured on the left and the right side of the mandible

Zbog toga su se srednje vrijednosti lijevog i desnog MI-a i AI-a koristile za daljnju statističku analizu.

Srednje vrijednosti i standardne devijacije mentalnog (MI) i antegonialnog indeksa (AI), te lijevog (GI-lijevi) i desnoga gonialnog indeksa (GI-desni), ovisno o spolu i dobi predstavljene su na Slikama 4. - 7.

Rezultati su pokazali da nema statistički znatne razlike za sve indekse ovisno o spolu ( $p > 0,05$ ), ali je statistički znatna razlika pronađena za desni GI, te AI i MI - ovisno o dobi, s time da je vrijednost indeksa rasla proporcionalno s dobi (Slike 4. - 7, Tablica 1.) ( $p < 0,01$ ). Vrijednost desnoga GI-a također raste s dobi, ali razlike nisu dosegnule razinu znatnosti ( $p < 0,01$ ).

Therefore, the mean values of the right and the left side MI and AI were used in all further statistical analyses.

Mean values and standard deviations of mental (MI) and antegonion indices (AI), as well as left gonion (GI-left) and right gonion indices (GI-right), dependent on gender and age groups are shown in Figures 4 to 7.

The results revealed no statistically significant differences for all indices dependent on gender ( $p > 0,05$ ), but the statistically significant difference was found for GI-right, AI and MI dependent on the age group with the values of the indices increasing with age (Figures 4-7, Table 1) ( $p < 0,01$ ). The values of GI-left also increased with age, but they did not reach the level of significance ( $p < 0,01$ ).

**Tablica 1.** Znatnost razlika između lijevog i desnoga gonialnog indeksa (GIL-lijevi, GID-desni), antegonialnog indeksa (AI) i mentalnog indeksa (MI) za različite dobne skupine pacijenata ( $p < 0,01$ ).

**Table 1** Significance of the differences in left and right gonion (GIL-left, GID-right), antegonion (AI) and mental (MI) indices between age groups of the patients ( $p < 0,01$ )

Linearni radiomorfometrijski indeksi • Linear radiomorphometric indices	Stupnjevi slobode • Df	F-vrijednost • F-value	Razina značajnosti • p
GIL	2	2,391	0,099
GID	2	6,272	0,003*
AI	2	11,601	0*
MI	2	10,647	0*

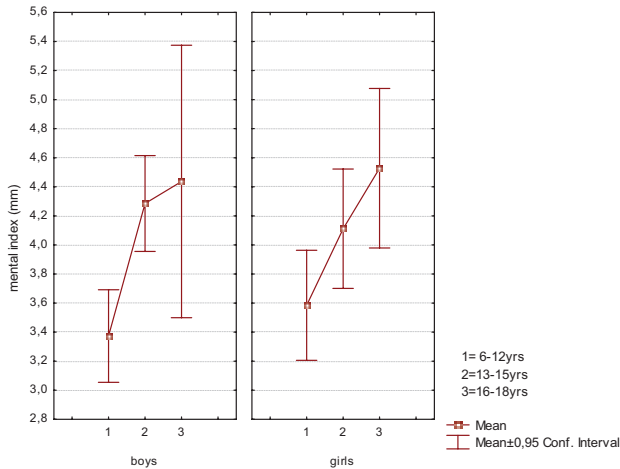
\*  $p < 0,01$

Uporabom post-hoc Scheffeova testa pronađene su statistički znatne razlike za GI-desni između prve i treće dobne skupine (6 -12 godina i 13 -15 godina) te između svih dobnih skupina za AI i MI.

Srednje vrijednosti i standardne devijacije za MI, AI, GI-lijevi i GI-desni, ovisno o ortodontskoj anomaliji, prikazane su na Slici 8. Najveća vrijednost za lijevi i desni GI pronađena je kod ispitanika s klasom III, a najmanja kod onih s klasom II/2 (Slika 8.).

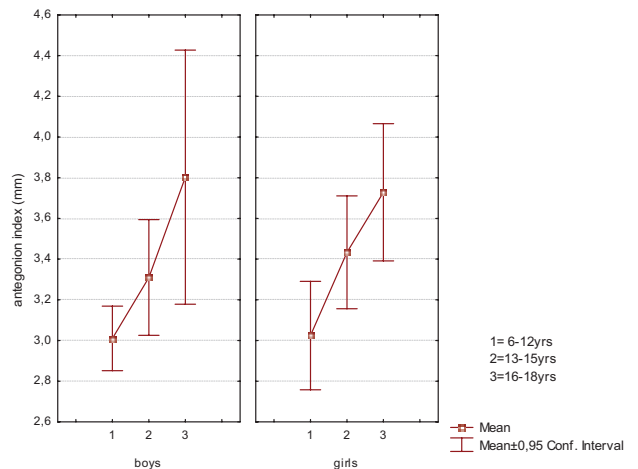
Post-hoc Scheffe's test for multiple comparisons between different age groups showed statistically significant differences between the first and the third age group (6-12 years and 13-15 years) for GI-right and between all age groups for AI and MI.

Mean values and standard deviations of MI, AI, GI-left and GI-right dependent on malocclusion groups are shown in Figure 8. The highest mean values of the left and the right GI were found in the Class III malocclusions and the lowest



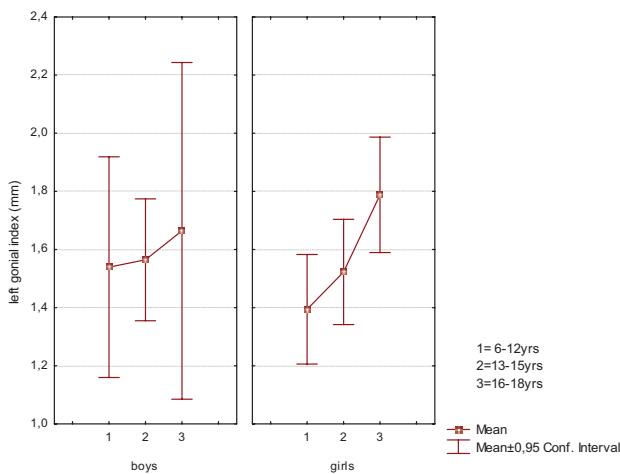
**Slika 4.** Srednje vrijednosti (y-os) i standardne devijacije izmjerenih vrijednosti mentalnog indeksa (mental index) ovisno o spolu i dobi ispitanika (boys = dječaci; girls = djevojčice)

**Figure 4** Mean values (y-axis) and standard deviations of mental index dependent on the gender and different age groups of the patients



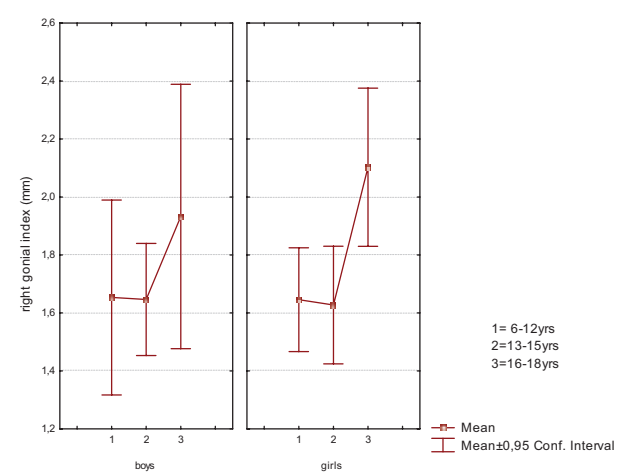
**Slika 5.** Srednje vrijednosti (y-os) i standardne devijacije izmjerenih vrijednosti antegonionnog indeksa ovisno o spolu i dobi ispitanika (boys = dječaci; girls = djevojčice)

**Figure 5** Mean values (y-axis) and standard deviations of antegonion index dependent on gender and age groups of the patients



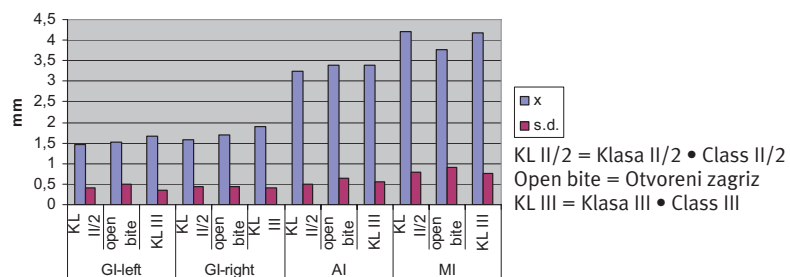
**Slika 6.** Srednje vrijednosti (y-os) i standardne devijacije izmjerenih vrijednosti lijevoga gonialnog indeksa (left gonial index) ovisno o spolu i dobi ispitanika (boys = dječaci; girls = djevojčice)

**Figure 6** Mean values (y-axis) and standard deviations of left gonion index dependent on gender and age groups of the patients



**Slika 7.** Srednje vrijednosti (y-os) i standardne devijacije izmjerenih vrijednosti desnog gonialnog indeksa (right gonial index) ovisno o spolu i dobi ispitanika (boys = dječaci; girls = djevojčice)

**Figure 7** Mean values (y-axis) and standard deviations of right gonion index dependent on gender and age groups of the patients



**Slika 8.** Srednje vrijednosti (X) i standardne devijacije (s.d.) izmjerenih vrijednosti desnog (GI-right) i lijevoga (GI-left) gonialnog indeksa, antegonionnog indeksa (AI) i mentalnog indeksa (MI) ovisno o vrsti ortodontske anomalije ispitanika

**Figure 8** Mean values (X) and standard deviations (s.d.) of gonion left and right (GI-left, GI-right), antegonion (AI) and mental (MI) indices dependent on malocclusion groups.

Srednje vrijednosti AI-a podjednake su za sve skupine anomalija, a malo su veće kod otvorenog zagrizu te klase III, u odnosu prema anomaliji klase II/2. Najveće vrijednosti za MI izmjerene su kod ispitanika s klasom II/2, zatim kod klase III, a najmanje u skupini ispitanika s otvorenim zagrizom (Slika 8.).

Statistički znatne razlike pronađene su za različite ortodontske anomalije samo za desni GI ( $df=2$ ;  $F=4,121$ ;  $p=0,02$ ), i to između ispitanika s anomalijom klase II/2 i klase III ( $p<0,05$ ).

## Rasprava

Debljina korteksa donjeg ruba mandibule može se vidjeti odmah na svakom ortopantomogramu i zbog toga je koristan parametar za određivanje kvalitete koštane supstancije mandibule.

U posljednje vrijeme autori studija upozorili su na to da kliničari mogu na temelju analize ortopantomograma predvidjeti kod starijih ljudi gubitak zuba zbog parodontitisa ili osteoporoze. Za to se koriste kvalitativni i kvantitativni indeksi ili čak denzitometrija osealne strukture mandibule (1, 2, 4, 5, 8 -11). No, u dosad dostupnoj literaturi još nema istraživanja o mladim pacijentima kod kojih se radiomorfometrijskim indeksima pratio rast i razvoj mandibule.

Klinička istraživanja već su dokazala ulogu žvačne muskulature na rast i razvoj orofacijalnog sustava (12). Aktivnost žvačne muskulature, posebice m. massetera, razlikuje se kod pojedinih ortodontskih anomalija (2). Zbog različitog opterećenja potporne kosti na mjestima hvatišta mišića, povećava se ili smanjuje debljina kortikalnog ruba čeljusti.

Rezultati ovog istraživanja pokazali su da nema statistički znatne razlike između vrijednosti indeksa izmjerenih s lijeve i desne strane mandibule ( $p>0,05$ ). Razlika je pronađena samo za vrijednost gonijalnog indeksa na angulusu mandibule, gdje se nalazi hvatište m. massetera. Debljina korteksa donjeg ruba mandibule na desnoj strani bila je veća (1,73 mm) u usporedbi s lijevom (1,56 mm) (Slika 5,  $p<0,05$ ). Takav rezultat postignut je jer su većina ispitanika bili desni žvakači, što su potvrdila i mnogobrojna elektromiografska istraživanja. Naime, ona su pokazala da su EMG-razine i masetera i temporalnog mišića bile veće na radnoj strani u odnosu prema balansnoj, a razlike su bile jače izražene za m. masseter (13).

Rezultati istraživanja također upozoravaju na to da su izmjerene vrijednosti linernih radiomorfometrijskih indeksa (GI-lijevi, GI-desni, MI i AI) veće

in Class II division 2 malocclusion group (Figure 8).

The mean AI values were almost the same for all groups, with slightly higher values for open bite and Class III than Class II/2. The mean MI values were the highest in the Class II/2, a little lower in Class III and the lowest in open bite group (Figure 8).

Statistically significant difference was found between different groups only for the right GI ( $df=2$ ;  $F=4,121$ ;  $p=0,02$ ), between the Class II division 2 and the Class III malocclusions ( $p<0,05$ ).

## Discussion

The cortical thickness of the lower border of the mandible could be easily observed on each panoramic radiograph and therefore it is a useful parameter for the assessment of the status of the mandibular bone.

In some recent studies it was proven that the clinician, using panoramic radiographs, may estimate the future risk of tooth loss in elderly individuals with periodontitis and osteoporosis by assessment of qualitative or quantitative indices, or even bone mineral density of particular parts of the mandible (1, 2, 4, 5, 8-11), but, there are no studies using linear radiomorphometric indices for the assessment of the growth and development of the mandible in young patients.

Clinical studies have already demonstrated the role of masticatory muscle function in normal and abnormal dentofacial development (12). It has been proven that masticatory muscle activity, especially masseter activity differs in different malocclusion groups (2). Muscle activity is reflected by a different extent of strain forces to the bone at muscular attachments, thus affecting increase or decrease of cortical thickness.

The results of this study revealed no significant difference between the indices measured on the left and the right side of the mandible ( $p>0,05$ ), except for GI at the angle of the mandible, masseter muscle attachment region. The right cortical thickness was higher (1.73 mm) than the left (1.56 mm) (Figure 5,  $p<0,05$ ). This finding can be attributed to the fact that the majority of subjects prefer right side chewing. Earlier studies indicated that the EMG levels for both masseter and the temporal muscles were normally higher on the working side. This difference was more pronounced for the masseter muscle (13).

The results of this study showed that values of all linear radiomorphometric indices (GI-left, GI-right, MI and AI) were higher in older subjects (Fig-

kod starijih ispitanika (Slike 3. - 7., Tablica 1.). To je posljedica rasta i razvoja mandibule u dobi od šeste do osamnaeste godine. U tom razdoblju također se povećava vrijednost žvačne sile, pa je i veće naprezanje na mjestima mišićnih insercija donjeg ruba mandibule (masseter, buccinator i ostali mišići).

Poznato je da postoji korelacija između jačine žvačne sile i spola, dobi, težine, antropometrijskog tipa građe, ortodontske terapije, simptoma temporomandibularne disfunkcije i kefalometrijskih mjera kod mlađih ispitanika (14, 15). Jakost žvačne sile povećava se tijekom rasta i razvoja proporcionalno s dobi, bez spolne specifičnosti (12).

Utjecaj spola i dobi na intenzitet mineralizacije osealne strukture mandibule te kvaliteta kostiju kod starijih ljudi, već su ranije bili predmet mnogobrojnih istraživanja.

Von Wowern (16) je pronašao da je gubitak minerala iz mandibule mnogo veći kod starijih žena (1,5% po godini) u odnosu prema muškarcima (0,9% po godini).

Ulm je, pak, upozorio na znatne razlike u smanjenju mineralizacije ovisno o spolu (17), što je u skladu s rezultatima Dubravke Knezović-Zlatarić (4). Vrijednosti gustoće koštane strukture i linearnih radiomorfometrijskih indeksa statistički su znatno veće kod muških ispitanika u odnosu prema ženskima, zbog utjecaja metabolizma spolnih hormona (18).

Rezultati ovog istraživanja pokazuju također da nema statistički znatne razlike za izmjerene vrijednosti linearnih radiomorfometrijskih indeksa između dječaka i djevojčica ( $p > 0,05$ ). Razlog je dob ispitanika manja od 18 godina, te to što nema hormonalnog disbalansa. Utjecaj različitih spolnih hormona na strukturu i kvalitetu kostiju za tu dobnu skupinu još nije dosegnuo razinu znatnosti.

Poznato je da se elektrografski izmjerena aktivnost mišića žvakača razlikuje između ispitanika s normalnom okluzijom, u odnosu prema anomalijama klase II i klase III (19, 20).

Deguchi i Iwahara pronašli su veću kumulativnu voltažu EMG-signala u m. masseteru kod ispitanika s klasom III (21). Također su ustanovili mnogobrojne nepravilnosti u žvačnoj funkciji kod japanskih adolescentica s anomalijom klase II, u odnosu prema normalnoj okluziji (20).

U ovom istraživanju rezultati pokazuju da ispitanici s anomalijom klase III imaju veće vrijednosti GI-a (statistički znatno na desnoj strani mandibule,  $p < 0,05$ ). Ispitanici s otvorenim zagrizom imaju najveće vrijednosti za AI, a ispitanici s anomalijom klase II/2 imaju najveće vrijednosti za MI. To po-

res 3 to 7, Table 1). This finding is a result of growth and development of mandible from 6<sup>th</sup> to 18<sup>th</sup> year of age. During this period bite forces increase, resulting in higher masticatory muscle activity and higher strain forces at muscular attachment zone at the lower border of the mandible (masseter, buccinator and other muscles).

Earlier studies reported correlations of maximum bite force with body type, gender, age, weight, history of prior orthodontic treatment, history of TMJ symptoms, and various cephalometric measurements for young subjects (14,15). The results of those studies revealed that maximum bite force increased throughout growth and development without gender specificity (12).

Influence of gender and age on mineral content and mandibular bone quality is a topic of a number of studies on older populations.

Von Wowern (16) found that the bone mineral loss in the mandibular bone was higher in old women (1.5% per year) than in old men (0.9% per year).

Ulm reported the significant difference in bone mineral content between sexes (17) which is in agreement with the results of Knezović Zlatarić (4). Bone mineral density values, as well as linear radiomorphometric indices, were significantly higher in males, due to different sex-hormone metabolism (18).

The results of this study showed that there was no significant difference for all linear radiomorphometric indices between boys and girls (Figures 4-7) ( $p > 0,05$ ). This could be attributed to the fact that this study group represented a typical range of young boys and girls with no signs of any hormonal disbalance. The influence of different sex-hormone metabolism to the bone structure and bone quality in those subjects had not yet reached the level of significance.

The findings of previous studies revealed different electromyographic masticatory muscle activity and coordination between subjects with normal occlusion and subjects with Class II and Class III malocclusion (19, 20).

Deguchi and Iwahara found higher mean cumulative voltage of EMG signals in masseter muscle on the working side in comparison to the same side temporal muscle in Class III pretreatment stage (21). They also found numerous masticatory abnormalities in Japanese female adolescents with Class II malocclusions in comparison with normal occlusion Japanese female adults (20).



tvrdjuje ulogu različite žvačne funkcije i prijenos sile i naprezanja na mjesta hvatišta miškulature kod različitih stanja okluzije. Zbog toga se i debljina korteksa donjeg ruba mandibule razlikuje ovisno o mjestu mjerenja za različite okluzije ( $p < 0,05$ ).

### Zaključak

Nema statistički znatne razlike između desne i lijeve strane mandibula za vrijednosti MI-a i AI-a ( $p > 0,05$ ). Vrijednost GI-a na desnoj je strani statistički znatno veća u odnosu prema lijevoj ( $p < 0,05$ ).

Vrijednosti svih lineranih radiomorfometrijskih indeksa znatno rastu s porastom dobi.

Debljina korteksa donjeg ruba mandibule na angulusu najveća je kod ispitanika s klasom III ( $p < 0,05$ ).

Na temelju rezultata ovog istraživanja, uporaba linearnih radiomorfometrijskih indeksa mogla bi biti klinički vrijedan pokazatelj rasta i razvoja mandibule te pomoć u praćenju rezultata ortodontske terapije.

The results of the present study revealed that the patients with Class III malocclusion demonstrated the highest values of GI (statistically significant on the right side of the mandible,  $p < 0,05$ ). Open bite group demonstrated the highest values of AI and Class II/2 group demonstrated the highest values of MI. This confirmed the role of different masticatory muscle activity and their strain forces at the muscular attachment zones in different malocclusion groups. Therefore, the cortical thickness of the lower border of the mandible varied at different regions, depending on the type of occlusion (Figure 8,  $p < 0,05$ ).

### Conclusion

No significant difference was found between the right and the left side of the mandible for MI and AI ( $p > 0,05$ ). The right GI was significantly higher than the left GI ( $p < 0,05$ ).

All linear radiomorphometric indices increased significantly with age.

The cortical thickness at the angle of the mandible demonstrated the highest value in Class III malocclusion ( $p < 0,05$ ).

Based on the results of this study, assessment of linear radiomorphometric indices could be clinically valuable for the evaluation of the growth and development of the mandible and for the assessment of the results in different orthodontic treatment procedures.

### Abstract

Radiographic assessment of "bone quantity" is of great value in planning dental treatment and it also has its applications in orthodontics.

The aim of this study was to assess the cortical thickness of the lower border of the mandible using linear radiomorphometric indices, and to determine if it is correlated with different age, gender and malocclusion categories in orthodontic pretreatment period of the patients.

Seventy seven patients - 30 boys (42.8%) and 47 girls (57.2%), participated in the study.

The results of the statistical analysis revealed no significant difference between the right and the left side measurements for mental and antegonial indices ( $p > 0,05$ ). The right gonial index was significantly higher than the left ( $p < 0,05$ ). All linear radiomorphometric indices increased with age. The cortical thickness at the angle of the mandible demonstrated the highest value in Class III malocclusion group ( $p < 0,01$ ). Based on the results of this study, assessment of linear radiomorphometric indices could be clinically valuable for the evaluation of the growth and development of the mandible and for assessing results of orthodontic treatment.

Received: March 10, 2006

Accepted: May 22, 2006

### Address for correspondence

Dubravka Knezović Zlatarić Ph.D.  
Department of Prosthodontics  
School of Dental Medicine University of Zagreb  
Gundulićeva 5  
HR-10 000 Zagreb, Croatia  
dkz@email.htnet.hr

### Key words

mandible; malocclusions; bone and bones; orthodontics; gender identity

## References

1. Knezović Zlatarić D, Čelebić A. Clinical bone densitometric evaluation of the mandible in removable denture wearers dependent on the morphology of the mandibular cortex. *J Prosthet Dent.* 2003;90(1):86-91.
2. Knezović Zlatarić D, Čelebić A. Mandibular bone mineral density changes in complete and removable partial denture wearers: a 6-month follow-up study. *Int J Prosthet.* 2003;16(6):661-5.
3. Knezović Zlatarić D, Čelebić A, Milat O, Papić M. A method to evaluate and compare two different intra-oral radiographs of the same patients. *Coll Antropol.* 2002;26(2):657-66.
4. Knezović Zlatarić D, Čelebić A, Kobler P. Relationship between body mass index and local quality of mandibular bone structure in elderly individuals. *J Gerontol A Biol Sci Med Sci.* 2002;57(9):M588-93.
5. Knezovic Zlataric D, Celebic A, Lazic B, Baucic I, Komar D, Stipetic-Ovcaricek J, Ibrahimagic L. Influence of age and gender on radiomorphometric indices of the mandible in removable denture wearers. *Coll Antropol.* 2002;26(1):259-66.
6. Klemetti E, Kolmakov S, Kroger H. Pantomography in assessment of osteoporosis risk. *Scand J Dent Res.* 1994;102(1):68-72.
7. Lekholm U, Zarb GA. Patient selection and preparation. In: Branemark PI, Zarb GA, Albrektsson T, editors. *Tissue-integrated prostheses. Osseointegration in clinical dentistry.* Chicago: Quintessence Publishing; 1985. p. 199-209.
8. Bras J, van Ooij CP, Abraham-Inpijn L, Kusen GJ, Wilmink JM. Radiographic interpretation of the mandibular angular cortex: A diagnostic tool in metabolic bone loss. Part I. Normal state. *Oral Surg Oral Med Oral Pathol.* 1982;53(5):541-5.
9. Ledgerton D, Horner K, Devlin H, Worthington H. Radiomorphometric indices of the mandible in a British female population. *Dentomaxillofac Radiol.* 1999;28(3):173-81.
10. Ledgerton D, Horner K, Devlin H, Worthington H. Panoramic mandibular index as a radiomorphometric tool: an assessment of precision. *Dentomaxillofac Radiol.* 1997;26(2):95-100.
11. Tozum TF, Taguchi A. Role of dental panoramic radiographs in assessment of future dental conditions in patients with osteoporosis and periodontitis. *N Y State Dent J.* 2004;70(1):32-5.
12. Braun S, Hnat WP, Freudenthaler JW, Marcotte MR, Honigle K, Johnson BE. A study of maximum bite force during growth and development. *Angle Orthod.* 1996;66(4):261-4.
13. Ahlgren J. Pattern of chewing and malocclusion of teeth. A clinical study. *Acta Odontol Scand.* 1967;25(1):3-13.
14. Braun S, Bantleon HP, Hnat WP, Freudenthaler JW, Marcotte MR, Johnson BE. A study of bite force: Part I. Relationship to various physical characteristics. *Angle Orthod.* 1995;65(5):367-72.
15. Braun S, Bantleon HP, Hnat WP, Freudenthaler JW, Marcotte MR, Johnson BE. A study of bite force, part 2: Relationship to various cephalometric measurements. *Angle Orthod.* 1995;65(5):373-7.
16. von Wowern N. Bone mineral content of mandibles: normal reference values - rate of age-related bone loss. *Calcif Tissue Int.* 1988;43(4):193-8.
17. Ulm CW, Solar P, Ulm MR, Matejka M. Sex-related changes in the bone mineral content of atrophic mandibles. *Calcif Tissue Int.* 1994;54(3):203-7.
18. Devlin H, Ferguson MW. Alveolar ridge resorption and mandibular atrophy. A review of the role of local and systemic factors. *Brit Dent J.* 1991;170(3):101-4.
19. Deguchi T, Kumai T, Garetto L. Statistics of differential Lissajous EMG for normal occlusion and Class II malocclusion. *Am J Orthod Dentofacial Orthop.* 1994;105(1):42-8.
20. Deguchi T, Garetto LP, Sato Y, Potter RH, Roberts WE. Statistical analysis of differential lissajous EMG from normal occlusion and Class III malocclusion. *Angle Orthod.* 1995;65(2):151-60.
21. Deguchi T, Iwahara K. Electromyographic investigation of chin cup therapy in Class III malocclusion. *Angle Orthod.* 1998;68(5):419-24.