

Tomislav Badel¹, Josip Pandurić¹, Miljenko Marotti², Kocijan Lovko³

Poremećaj čeljusnog zgloba pacijentice s otalgijom

Temporomandibular Joint Disorder in an Otalgia Patient

¹ Zavod za stomatološku protetiku Stomatološkog fakulteta Sveučilišta u Zagrebu, Zagreb, Hrvatska
Department of Prosthodontics, School of Dental Medicine, University of Zagreb, Croatia

² Zavod za dijagnostičku i intervencijsku radiologiju Kliničke bolnice "Sestara milosrdnica", Sveučilište u Zagrebu, Zagreb, Hrvatska
Department of Diagnostic and Intervention Radiology, Clinical hospital "Sisters of Mercy", Zagreb, Croatia

³ Psihijatrijska ambulanta Opće bolnice Zabok, Zabok, Hrvatska
Department of Psychiatry, Zabok General hospital, Zabok, Croatia

Sažetak

Na temelju povezanosti embrionalnog razvoja čeljusnog zgloba i uha objašnjava se često krivo tumačenje nespecifičnih otoloških simptoma, uzrokovanih nekim od oblika temporomandibularnih poremećaja. Opisan je slučaj pacijentice koja se liječila kod otorinolaringologa zbog otalgije, ali je zaključeno da se radi o patologiji čeljusnog zgloba. Kliničkim pregledom te magnetskom rezonancijom čeljusnih zglobova potvrđen je anteriorni pomak zglobne pločice. Kako pacijentica nosi pet godina stare potpune proteze, izradene su joj nove. Simptomi poremećaja čeljusnog zgloba potpuno su iščeznuli, a za pacijenticu je bilo najvažnije da je nestala bol. S obzirom na njezinu dob, stečenu bezubost i nemogućnosti liječenja *restitutio ad integrum*, pacijentica je dobila upute kako da održava bezbolno funkcijsko stanje žvačnog sustava.

Zaprimljen: 25. rujna 2005.

Prihvaćen: 2. veljače 2006.

Adresa za dopisivanje

Dr. sc. Tomislav Badel
Zavod za stomatološku protetiku
Stomatološki fakultet Sveučilišta u
Zagrebu
Gundulićeva 5, 10 000 Zagreb
badel@sfzg.hr

Ključne riječi

poremećaji čeljusnog zgloba; magnetska rezonanca; zubne proteze; bol uha; tjeskoba

Uvod

Muskuloskeletalni poremećaji žvačnog sustava obuhvaćeni su, na temelju kliničkih stanja koja uzrokuju, skupnim nazivom temporomandibularni poremećaji. Suvremene definicije temporomandibularnih poremećaja smatraju se skupom različitih kliničkih problema u žvačnom mišićju, čeljusnom zglobov ili oboje (*American Academy of Orofacial Pain*, 1996) (1) ili su, pak, upalne i/ili degenerativne promjene žvačnog mišićja i/ili čeljusnog zgloba, koje stvaraju tegobe u stomatognatom sustavu (Palla, 1998) (2).

Proučavanje etiopatogeneze i simptomatologije temporomandibularnih poremećaja vezuje se za oto-

Introduction

Musculoskeletal disorders of the masticatory system, based on the clinical situations they can cause, belong to the group of temporomandibular disorders (TMD). Current definitions consider TMDs to be a group of different clinical problems in masticatory muscles, TMJ, or both (1), or they are considered to be inflammatory and/or degenerative changes of the masticatory muscles and/or TMJ that cause disturbances in the orofacial system (2).

Etiology, pathogenesis and symptomatology of TMDs is connected to ENT specialist J. B. Costen, after whom the Costen syndrome was named; the

rinolaringologa J. B. Costena. Po njemu je u praksi uobičajen termin *Costenov sindrom*, koji se i danas rado koristi - iako se kasnije pokazalo - bez znanstvenog temelja. Ipak, može se - zbog neposredne anatomske bliskosti uha i čeljusnog zgloba, njihove međusobne povezanosti tijekom embrionalnog razvoja te zbog karakterističnosti muskuloskeletalnih bolova, kao što je teška lokalizacija i širenje udaljeno od mjesta uzroka - bol, otalgiju i druge nespecifične otološke simptome (npr. šum u uhu) krivo pripisati tegobama uha i slušno-ravnotežnog aparata (3).

Temporomandibularni poremećaji, u koje se ubrajaju poremećaji mišićja (tendomiopatije) te poremećaji čeljusnog zgloba (diskopatije, artroza), nisu sami po sebi sindrom, tj. simptomi nisu karakteristični da bi se na temelju njih postavila dijagnoza. Za dijagnostiku temporomandibularnih poremećaja važno je shvatiti koliko je individualno važan pojedini simptom za pacijenta te moguću patofiziološku osnovu i trajanje tegoba (4).

Bol je najkarakterističnija, najizraženija i klinički najteža tegoba temporomandibularnih poremećaja (5). Ona je najvažniji razlog zašto medicinsku i/ili stomatološku pomoć traži oko 97% pacijenata s bolnim temporomandibularnim poremećajima. Ne osjeća se isključivo u području žvačnog sustava, nego se javlja i u drugim dijelovima tijela, najčešće na licu i glavi (kranioandibularna regija) (5, 6).

Temporomandibularni poremećaji češći su kod žena i to reproduktivne dobi. Kako se u postmenopauzalnom razdoblju smanjuje učestalost temporomandibularnih poremećaja, smatra se da ne progrediraju ovisno o porastu dobi. Isto tako je karakteristično da je, bez obzira na visoku prevalenciju simptoma (i više od 75% populacije), potreba za liječenjem simptomatskih osoba manja od 10% (od oko 3 do 7%) (7).

Od mnogobrojnih mogućih čimbenika etiopatogeneze temporomandibularnih poremećaja, za temporomandibularne boli vezuju se psihološki poremećaji. Psihološki čimbenik može imati važnu perpetualnu ulogu i kod muskuloskeletalnih bolova uzrokovanih drugdje u ljudskom tijelu (8). Anksioznost je difuzan, neugodan osjećaj brige i straha, a često ga prati široki spektar somatskih simptoma, a oni mogu uključivati: mišićnu napetost, tremor, nemir, znojenje, osjećaj lakog i brzog umaranja, suha usta, vrtoglavicu, mučninu, nesanicu i poteškoće u koncentraciji. Određen stupanj anksioznosti upozorava na različite vanjske ili unutarnje opasnosti te smanjuje kvalitetu života (9, 10).

term is still popular, although, as was later confirmed, it had no scientific basis. Still, due to immediate anatomic proximity, their relationship during embryonic development, characteristic musculoskeletal pain and difficulty in localization as well as the dissemination of pain, one might wrongly attribute pain, otalgia and other unspecific symptoms in the area (humming) to the disorders of the ear and hearing-balance system (3).

TMDs that include tendomyopathia and discopathia and arthrosis do not represent a syndrome by themselves, i.e. the symptoms are not characteristic in order to support a diagnosis. For the diagnostic of TMDs it is important to visualize the individual importance of each symptom for the patient, possible pathophysiological basis and the duration of problems (4).

Pain is the most characteristic, most pronounced and clinically the most difficult symptom of TMDs (5). Pain is the most important reason for seeking medical and/or dental professional help in around 97% of the patients with painful TMDs. It is not exclusively present in the masticatory system, it can also appear in other parts of the body, most frequently face and craniomandibular region (5, 6).

The frequency of TMDs is higher in women in reproductive age. Since the frequency of TMDs in postmenopausal women is lower, it is considered that TMDs do not progress with age. Characteristically, notwithstanding the high prevalence in symptoms (more than 75% of the population), treatment needs of individuals with symptoms is lower than 10% (between 3 and 7%) (7).

Numerous etiological and pathological factors of TMDs include psychological disorders as well. Psychological factor can have an important perpetual role in musculoskeletal pains that are caused elsewhere in the body (8). Anxiety is a diffuse, uncomfortable sensation of worry and fear, often followed by a wide spectrum of somatic symptoms that can include muscle tenderness, tremor, restlessness, sweating, tiredness, xerostomia, dizziness, nausea, sleeplessness and difficulty in concentration. Anxiety is a warning for different external or internal threats that can cause a decrease of life quality (9, 10).

Neuroplastic changes characteristic for musculoskeletal pain can result in chronic temporomandibular pains. It is possible that anxiety diminishes and decreases the success of initial and definitive therapy of TMDs (8, 11, 12).

The aim of this case report is acquaintance with possible clinical casuistic that, due to insufficient

Upravo neuroplastične promjene svojstvene za muskuloskeletalne bolove mogu imati kao posljedicu kronificiranje i temporomandibularne bolove. Moguće je da anksioznost otežava i smanjuje uspjeh inicijalne i definitivne terapije temporomandibularnih poremećaja (8, 11, 12).

Svrha opisa ovoga kliničkog slučaja jest obavijestiti o mogućoj kliničkoj kazuistici koja, zbog nedovoljnog interdisciplinarnog prepoznavanja zdravstvenih tegoba, odgađa potrebnu dijagnostiku uzroka boli te u ovom slučaju i definitivnu protetsku terapiju.

Prikaz slučaja

Na Zavod za stomatološku protetiku Stomatološkog fakulteta u Zagrebu polivalentni stomatolog poslao je pacijenticu (u dobi od 71 godine) i to na temelju medicinske dokumentacije koju je donijela od svojega liječnika opće prakse i otorinolaringologa.

Prethodno liječenje

Tegobe u lijevom uhu javile su se prije više od šest mjeseci: povremena bol u lijevom uhu, a ponekad je i škljocalo u lijevom čeljusnom zglobu. Jedanput joj se i zakočila čeljust dok je otvarala usta, pa je u lijevom čeljusnom zglobu snažno puknulo.

Pacijentica se liječila kod otorinolaringologa – ustanovljen je *streptococcus haemolyticus* u nazofarinksu te je zbog - na rendgenogramu pneumatskih šupljina dijagnosticiranog polipa u desnom maksilarnom sinusu - indicirana i provedena sinusoskopi-ja. U lijevom sinusu utvrđeno je tek suspektno zadebljanje sluznice.

I nakon toga pacijentica se žalila na povremenu tupu bol u lijevom uhu s otorinolaringološkim nalazom koji ne upućuje na patološko stanje uha, nazofarinksa ili nosnih šupljina. Tek tada je zbog, u liječničkoj dokumentaciji navedene bolne palpaci-je područja lijevog čeljusnog zgloba, zaključeno da bi tegobe mogle biti povezane s poremećajem čeljusnog zgloba.

Klinički pregled s anamnezom

Zubni status: pacijentica je nosila pet godina stare potpune proteze (Slika 1 i 2). Žalila se na povremene bolove umjerenog intenziteta (ocijenjeno s 2 na analognoj vizualnoj ljestvici od 0 do 10) u području lijevoga čeljusnog zgloba, u kojemu se ponekad javljalo škljocanje dok je otvarala usta. Također se žalila na bolove u lijevom uhu. Artralgija i otalgija su se pojačavale tijekom žvakanja i pri jačem otvaranju usta. Pacijentica nije osjećala znatniju li-

interdisciplinary approach to health problems, postpones the needed diagnostics of pain causes, and, as in this case, definitive prosthetic therapy.

Case report

Seventy-one year old female patient was referred to the Department of Prosthodontics, School of Dental Medicine, Zagreb, Croatia. The referral was based on the medical documentation from the patient's medical doctor and ENT specialist.

Earlier treatment

Problems in left ear started more than six months ago like temporary pain in the left ear. Sometimes there were clicks in the left TMJ. Once the jaw was blocked while she was opening the mouth, and there was subsequent loud click in the left TMJ.

ENT specialist treated the patient; *Streptococcus haemolyticus* was isolated from nasopharynx, and, due to a polyp growth in the right maxillary sinus, sinusoscopy was performed. In the left sinus only suspect epithelium thickening was diagnosed.

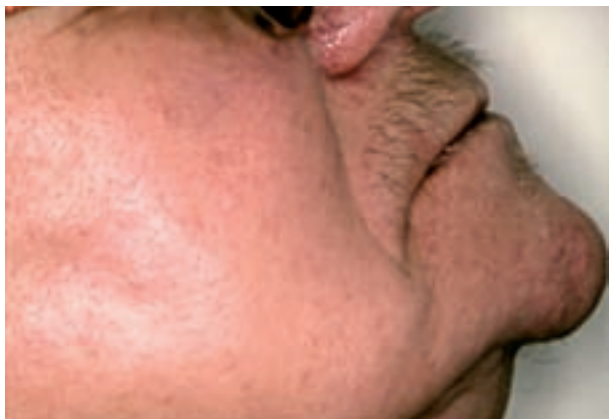Still, the patient complained about occasional dull pain in the left ear with an ENT status that did not imply any pathology in the ear, nasopharynx or paranasal areas. Only then the medical documentation included painful palpation in the area of left TMJ, and subsequently it was concluded that the symptoms might have some connection to TMD.

Clinical examination and anamnesis

Dental status: the patient had five-year-old complete dentures (Figs. 1 and 2) and complained about mildly intensive pain in the area of the left TMJ (on visual analog scale from 0 to 10, mark 2); additionally, she mentioned infrequent clicking in the left TMJ while opening the mouth. She was also complaining about the pain in the left ear. Arthralgia and otalgia were stronger during chewing and wider mouth opening. The patient did not feel significant limitation of the mandibular movement (maximal opening, measured at incisors, was 45 mm).

During the diagnostic procedure the patient claimed she had frequent, but light headaches (tension type). There were no signs or symptoms of bruxism, but she claimed to be exposed to stress situations, and to have insomnia. She could not relate the described symptoms of arthralgia and otalgia to some dental procedure, trauma of the orofacial region or some incident that might, according to her opinion, be the cause of such disturbances.

Manual diagnostic procedures (passive compression, dynamic compression with translation) con-



Slika 1. Fizionomija pacijentice s apliciranim postojećim potpunim protezama u ustima
Figure 1 Patient with old complete dentures in her mouth

mitaciju mandibularnih kretnji (otvaranje usta mjereno na središnjim sjekutićima proteza s uračunatim preklapom iznosilo je 45 mm).

Tijekom pregleda pacijentica je izjavila da pati i od čestih laganih glavobolja (tenzijski tip glavobolje). Nije pokazivala ni znakove ni simptome bruskizma, ali je izjavila da je izvrgnuta stresogenim situacijama i da pati od nesanicе. Nikako nije mogla povezati simptome artralgiје i otalgije s nekim stomatoloških zahvatom, doživljenom traumom orofacijalne regije ili nekim zbivanjem koje bi, prema njezinu mišljenju, moglo biti uzrokom tih tegoba.

Manualnim pretragama (pasivne kompresije, dinamičke kompresije s translacijama) ustanovljena je bolnost bilaminarne zone te anteriorni pomak zglobne pločice (*discus articularis*) s repozicijom lijevoga čeljusnog zgloba. Isključena je tendomiopatija skupina žvačnih mišića (13).

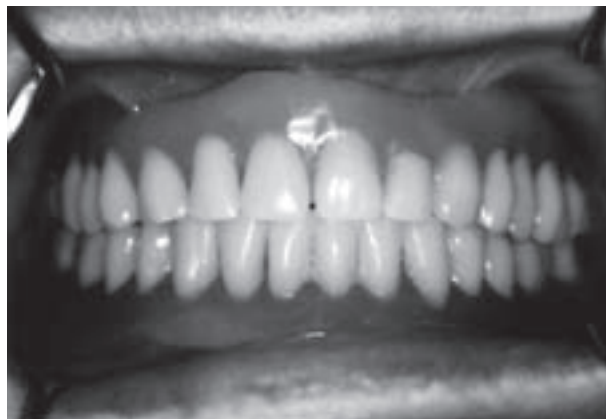Radiološka dijagnostika

Ortopantomogram nije pokazao znakove patoloških i drugih promjena koje bi indicirale upućivanje pacijentice oralnom kirurgu (Slika 3).

Magnetskom rezonancijom (uređaj Magnetom Harmony, Siemens, jačina magnetskog polja 1 Tesla) provjerilo se stanje tvrdih i mekih tkiva čeljusnih zglobova. Utvrđen je anteriorni pomak zglobne pločice u oba čeljusna zgloba s lagano deplaniranom glavicom kondila i dorzalnim smještajem unutar zglobne jamice (T1 mjerene snimke, spin-echo tehnika SE 700/40 msec; Slike 4 i 5).

Psihološko testiranje

Anksioznost je potvrđena psihološkim mjernim instrumentom State-Trait Anxiety Inventory (14). Rezultati u STAI 1 (odnosi se na anksioznost kao subjektivno stanje, osjećaj u zadnjih tjedan dana,



Slika 2. Okluzija s postojećim potpunim protezama koje su stare pet godina
Figure 2 Occlusion with old complete dentures, five year old.

firmed the pain in the bilaminar zone and anterior movement of the discus articularis with reposition of the left TMJ. Tendomyopathia of the masticatory muscles (13) was excluded.

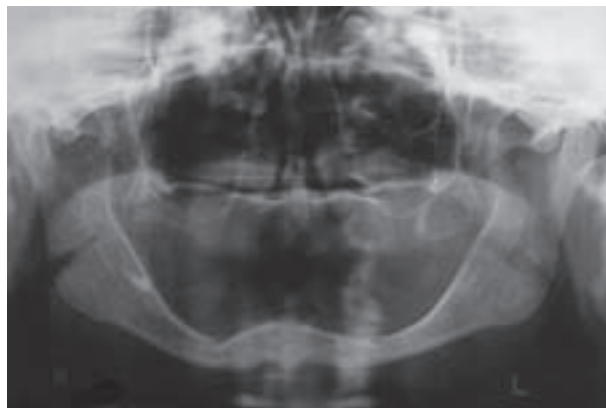
Radiological diagnostics

Orthopantomographic radiograph did not show any pathological signs that would indicate a referral to maxillofacial surgery (Fig. 3).

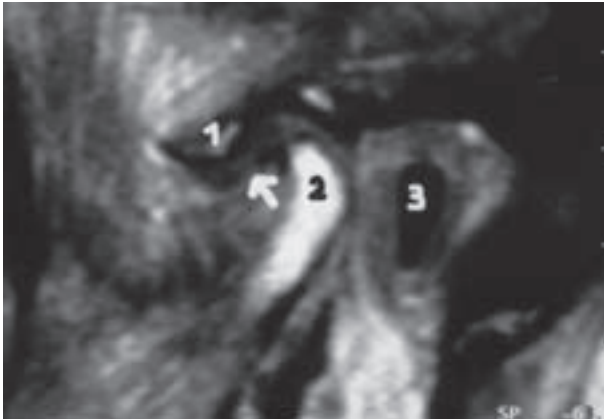
Magnetic resonance (Magnetom Harmony, Siemes, magnetic field 1 Tesla) displayed the status of hard and soft tissue of TMJs. Anterior shift of the disc was confirmed in both TMJs, with slightly deplaned condyle head and dorsal location inside the fossa articularis (T1 measured pictures, Spin-echo technique SE 700/40 msec; Figs. 4 and 5).

Psychological testing

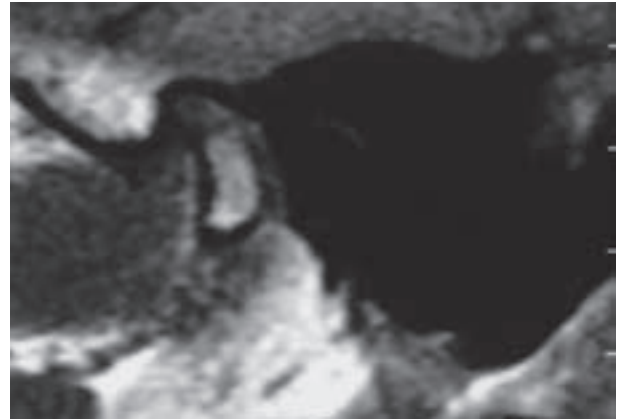
Anxiety was confirmed by a psychological measuring instrument State-Trait Anxiety Inventory



Slika 3. Ortopantomogram uzapredovalo resorbiranih alveolarnih grebena
Figure 3 Orthopantomographic depiction of advanced resorption of alveolar ridges.



Slika 4. Prikaz desnoga čeljusnog zgloba pomoću magnetske rezonancije s anteriornim položajem zglobne pločice (strelice; 1, zglobna kvržica; 2, glavica kondila; 3, vanjski zvukovod)
Figure 4 Right TMJ (MR) with anterior shift of the disc (arrows: 1. condylar tuberculum, 2. condyl head, 3. outer sound canal).



Slika 5. Prikaz lijevoga čeljusnog zgloba pomoću magnetske rezonancije. Zglobna pločica je također anteriorno pomaknuta.
Figure 5 Left TMJ (MR). The anterior displacement of the disc can be seen.

uključujući i danas) i STAI 2 (odnosi se na anksioznost kao na razmjerno stabilnu individualnu karakteristiku općenito tijekom života) pokazuju visoku razinu anksioznosti. STAI 1=41 i STAI 2=52 mnogo su više vrijednosti od referentnih prosječnih vrijednosti koje iznose 32,20 za STAI 1 i 31,79 za STAI 2.

Konačna dijagnoza i terapija

Magnetskom rezonancijom potvrđena je klinička dijagnostika utvrđena za bolesni čeljusni zglob. U desnom, asimptomatskom, čeljusnom zglobu ustanovljen je također anteriorni pomak zglobne pločice.

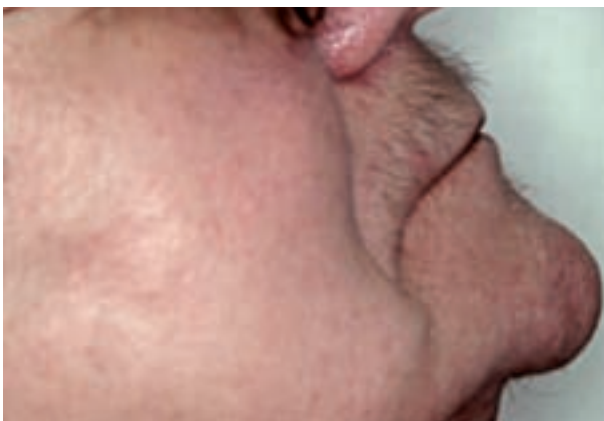Osnovni cilj stomatološkog liječenja bio je postići bolje, to jest za pacijenticu zadovoljavajuće funkcijsko stanje. U prvom redu to je značilo reguliranje

(14). The STAI 1 results (related to anxiety as a subjective state, feelings in the last week, including today) and STAI 2 results (related to anxiety as relatively stable individual characteristic through the life) show high level of anxiety. Both STAI 1 = 31 and STAI 2 = 52 gave higher values than referent mean values that are 32.2 and 31.79, respectively.

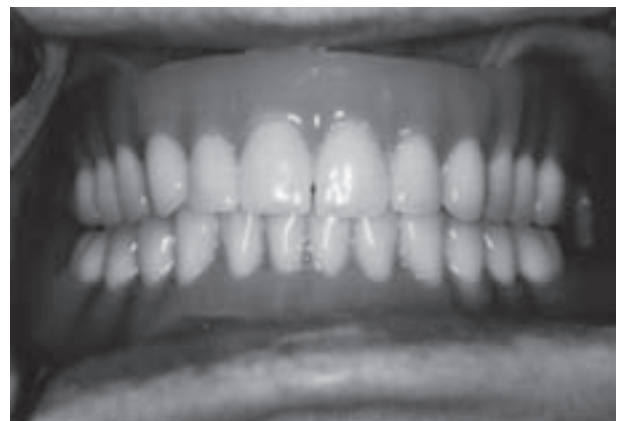Final diagnosis and therapy

MR has confirmed clinical diagnostics determined for the TMJ. The right, asymptomatic TMJ also had anterior dislocation of the disc.

The main goal of dental treatment was the establishment of a better and more satisfactory functional state for the patient. In the first place, it required intermaxillary relationship and intraarticular regulation by producing new complete dentures (Figs. 6



Slika 6. Fizionomija pacijentice s novoizrađenim potpunim protezama u ustima
Figure 6 Patient with new complete dentures in her mouth



Slika 7. Okluzija s novoizrađenim potpunim protezama
Figure 7 Occlusion with new complete dentures.

međučeljusnih odnosa i unutarzglobnih struktura čeljusnih zglobova izradom novih potpunih proteza (Slika 6 i 7). Pacijentici je također objašnjeno što je patofiziološka osnova uzroka njezinih tegoba te da bolesni čeljusni zglob na izlaže nepotrebnom opterećenju koje bi moglo ne samo inicirati bolno stanje, nego ga i pogoršati.

Iako u slučaju te pacijentice nije bilo liječenja potencijalnoga psihosocijalnog čimbenika temporomandibularne boli, pokazalo se da dijagnosticirana anksioznost nije imala negativan, tj. otegotni utjecaj na provedbu protetske terapije.

Rasprava i zaključak

Temporomandibularni poremećaji, zbog sve veće kliničke važnosti tegoba koje uzrokuju i razmjerno visoke prevalencije simptoma, objedinjuju gotovo sve stomatološke discipline. Često je potrebna i šira interdisciplinarna suradnja s mnogobrojnim medicinskim specijalnostima zbog njezine, u cijelosti nerazjašnjene, etiopatogeneze i patofiziologije, a koja može biti u interakciji s drugim organima i funkcijskim sustavima ljudskog tijela.

Specifičnost određivanja pojma temporomandibularnih poremećaja jest u tome što se temelji na simptomima, a ne na njihovoj etiologiji i/ili patogenezi. Pojedini isti ili slični simptomi u žvačnom sustavu mogu biti povezani s temporomandibularnim poremećajima, ali i s drugim stanjima koja su posljedica stomatoloških zahvata u žvačnom sustavu (2).

Ortopantomografija i ciljane tehnike rendgenografskog snimanja čeljusnih zglobova nisu dijagnostički upotrebljive za prikaz mekih tkiva čeljusnog zgloba, odnosno za utvrđivanje anteriornog pomaka/položaja zglobne pločice, kao najvažnijeg oblika diskopatije čeljusnog zgloba (15). Nalaz magnetske rezonancije može se vrjednovati samo ako se prije toga zna kliničko stanje. Utvrđeno je da i više od 33% populacije asimptomatskih osoba ima anteriorno pomaknute zglobne pločice, što je dijagnosticirano u desnom čeljusnom zglobu te pacijentice (16).

Psihološki čimbenici (anksioznost i dr.) pridruženi su svim kategorijama etioloških čimbenika temporomandibularne boli. Važno svojstvo temporomandibularne boli, koje pogoršava kliničko stanje pacijenta, jest prelazak akutne u kroničnu bol. Mogućnost djelomičnog uklanjanja kronične boli i kontrole njezina intenziteta potrebna je da bi se podignula kvaliteta života pacijenta, ali i proveli definitivni terapijski postupci. (5, 11, 12, 17). Kod većine pacijenata temporomandibularna bol ipak ne uzrokuje veća ograničenja u svakodnevnim aktivnostima (18).

and 7). Also, the patient was educated concerning the pathophysiological base of her ailment, and instructed not to load the left TMJ exceedingly, since it might not only initiate earlier symptoms, but aggravate them as well.

Although this case did not resolve in complete curing of the potential psychosocial factor of temporomandibular pain, it was shown that the diagnosed anxiety did not have negative, i.e. adverse, influence on the course of prosthetic therapy.

Discussion and Conclusion

TMDs, due to ever-greater clinical importance of the symptoms that accompany them and their relatively high prevalence, encompass almost all fields of dentistry. Often a wider, interdisciplinary approach that includes many medical fields is needed, since unknown etiology, pathogenesis and pathophysiology might put it into interaction with other organs and functional systems of the human body.

TMD is based on the symptoms, not on the etiology and/or pathogenesis. Similar or equal symptoms in the masticatory system can be connected to TMDs, but also to other disorders that are consequences of dental treatment (2).

Orthopantomographic radiography and radiography of TMJs are essential for determining the anterior dislocation/shift of the disc, representing the most important type of discopathy (15). MR can be evaluated only if the clinical status is known in advance. It was established that 33% of asymptomatic population has anterior dislocation of the disc; similar finding was present in the right TMJ of the presented case (16).

Psychological factors (anxiety etc.) are associated with all categories of etiological factors of temporomandibular pain. The main property of temporomandibular pain that worsens the clinical status is the shift from acute to chronic pain. The possibility of partial pain removal and the control of its intensity is needed in order to increase the patient's quality of life, as well as for performing definitive therapeutical measures (5, 11, 12, 17). Most of the patients with temporomandibular pain do not have greater disabilities in everyday life (18).

Diagnostics and therapy of TMDs must be individual, since it can be idiopathic, notwithstanding the possible etiological and pathological factors (19). Patients with complete dentures can be successfully treated, like other patients with partially

Dijagnostika i terapija temporomandibularnih poremećaja treba biti individualna, zbog mogućeg idiopatskog uzroka (19). Pacijenti s potpunim protezama mogu se uspješno liječiti kao i ostali pacijenti sa sačuvanim habitualnim stanjem i mogućim patološkim varijacijama okluzije prirodnih zuba (20). Važnost fizioloških okluzijskih odnosa i dalje je važan element oralnog zdravlja bez obzira na disfunkcijsko stanje stomatoloških pacijenata.

Zahvala

Ovaj rad izrađen je u sklopu znanstvenih projekata br. 0065010 i 0134014 Ministarstva znanosti, obrazovanja i športa Republike Hrvatske.

conserved habitual status and possible pathological variations of the natural occlusion (20). The importance of physiological occlusal relations remains an important element in the overall oral health, with no regards to dysfunctional status of dental patients.

Acknowledgment

This case report is a part of scientific projects No. 0065010 and 0134014, financed by the Ministry of Science, Education and Sports of the Republic of Croatia.

Abstract

Often wrong judgment of unspecific otological symptoms, caused by some types of temporomandibular disorders, is based on the connection in the embryonic development of the temporomandibular joint (TMJ) and the ear. This is a report of a female patient who was previously treated by the ear-nose-throat specialist because of otalgia, but it was concluded that she had some TMJ pathology. Clinical examination and magnet resonance of the TMJs confirmed anterior slide of the disc. Since the patient has five-year-old complete dentures, new ones were fabricated. The symptoms recede, and for the patient the most important thing was that the pain disappeared. With regards to her age, acquired anodontia and impossible restitutio ad integrum treatment, she was instructed how to support the painless functional status of her masticatory system.

Received: September 25, 2005

Accepted: February 2, 2006

Address for correspondence
Tomislav Badel, DDS, PhD
Department of Prosthodontics
School of Dental Medicine
University of Zagreb
Gundulićeva 5
HR-10000 Zagreb, Croatia
badel@sfz.hr

Key words

temporomandibular joint disorders;
magnetic resonance; earache; anxiety;
dentures

References

- Okeson JP, editor. Temporomandibular disorders. Guidelines for classification, assessment, and management. 2th ed. Chicago: Quintessence; 1996.
- Palla S. Myoarthropathien des Kausystems. Zürich: ZZMK der Universität Zürich; 1998.
- Kanter RJ. Prevalence and etiology of craniomandibular dysfunction: an epidemiological study of the Dutch adult. Winssen: RP Scientific; 1990.
- Carlsson GE, Magnusson T. Management of Temporomandibular Disorders in the General Dental Practice. Chicago: Quintessence; 1999.
- Türp JC. Temporomandibular Pain - Clinical Presentation and Impact. Berlin: Quintessenz-Verlag; 2000.
- Türp JC. Myoarthropathien des Kausystems - ein chronisches Schmerzproblem. Freier Zahnarzt. 1999;41:52-7.
- Okeson JP. Management of Temporomandibular Disorders and Occlusion. St Louis: Mosby; 2003.
- de Boever JA, Carlsson GE. Etiology and Differential Diagnosis. In: Zarb GA, Carlsson GE, Sessle BJ, Mohl ND, editors. Temporomandibular Joint and Masticatory Muscle Disorders. Copenhagen: Munksgaard; 1994. p. 171-87.
- Kaplan HI, Sadock BH. Compressive Textbook of Psychiatric. Baltimore: Lippincott; 1995.
- Edelman RJ. Anxiety theory, research and interventions. Clinical and health Psychology. Chichester: Wiley; 1995.
- Gremlion HA. Multidisciplinary diagnosis and management of orofacial pain. Gen Dent. 2002;50(2):178-86.
- Manfredini D, Landi N, Bandettini Di Poggio A, Dell'Osso L, Bosco M. A critical review on the importance of psychological factors in temporomandibular disorders. Minerva Stomatol. 2003;52(6):321-6, 327-30.
- Bumann A, Lotzman U. Funktionsdiagnostik und Therapieprinzipien. Stuttgart, New York: Thieme; 2000.
- Spielberger CD. Priručnik za upitnik anksioznosti kao stanja i osobine ličnosti (STAI) (Oblik Y). Jastrebarsko: Naklada Slap; 2000.
- Leon SD. The use of panoramic radiography for evaluating temporomandibular disorders. Gen Dent. 2004;52(4):339-41.
- Haiter-Neto F, Hollender L, Barclay P, Maravilla KR. Disk position and the bilaminar zone of the temporomandibular joint in asymptomatic young individuals by magnetic resonance imaging. Oral Surg Oral Med Oral Pathol Oral Radiol Endod. 2002;94(3):372-8.
- Türp JC, Schindler HJ. Chronische Myoarthropathien des Kausystems. Schmerz. 2004;18:109-17.
- Nilges P. Psychosoziale Faktoren bei Gesichtsschmerz. Schmerz. 2002;16:365-72.
- Greene CS. The Etiology of Temporomandibular Disorders: Implications for Treatment. J Orofac Pain. 2001;15(2):93-105.
- Badel T, Pandurić J, Perenčević K. Vertikalisationsschiene als Initialtherapie bei totalprothetischer Versorgung. Quintessenz Zahntech. 2002;28:748-56.