

De Novo Case of a Partial Trisomy 4p and a Partial Monosomy 8p

Ivana Škrlec¹, Jasenka Wagner¹, Silvija Pušeljić², Marija Heffer¹ and Feodora Stipoljev^{1,3}

¹ »J. J. Strossmayer« University, School of Medicine, Department of Medical Biology, Cytogenetic laboratory, Osijek, Croatia

² »J. J. Strossmayer« University, University Hospital Centre Osijek, Pediatric Clinic, Osijek, Croatia

³ University of Zagreb, »Sveti Duh« University Hospital, Department of Obstetrics and Gynecology, Cytogenetic laboratory, Zagreb, Croatia

ABSTRACT

The extent of clinical expression in cases of segmental aneuploidy often varies depending on the size of the chromosomal region involved. Here we present clinical and cytogenetic findings in a 5-month old boy with a duplication of a chromosomal segment 4p16.1→4pter and a deletion of a chromosomal segment 8p23.1→8pter. His karyotype was determined by applying classical GTG banding and FISH method (WHCR region, centromere 4, centromere 8, telomere 8p) as 46,XY,der(8)t(4;8)(p16.1;p23.1).ish der(8)t(4;8)(D8S504-,WHCR+,D8Z2+)dn. Parents are not related and have normal karyotypes, indicating de novo origin. We have compared similarity of the clinical features in our proband to other patients carrying only a duplication of the distal part of 4p or a deletion of distal part of 8p or similar combination described in the literature.

Key words: chromosome aberrations, clinical findings, partial trisomy 4p, partial monosomy 8p, phenotypic variability, unbalanced translocation, fluorescence in situ hybridization

Introduction

Extent of clinical expression in segmental aneuploidy often varies with the size of chromosomal region involved. The translocation between short arm of chromosome 4 and short arm of chromosome 8, in either a balanced or an unbalanced form, has been reported several times^{1,2}. Most of unbalanced published cases conferred to derivate chromosome 4p implicating on presence of partial trisomy 8p and monosomy 4p, respectively. *De novo* 4p deletions are reasonably assumed to be single chromosome anomalies. Unbalanced *de novo* translocations involving the short arms of chromosomes 4 and 8 were detected with an unexpectedly high frequency in Wolf-Hirschhorn syndrome (WHS) patients^{3,4}. Patients with der(4) had WHS, whereas subjects with der(8) showed a milder spectrum of dysmorphic features¹. Zollino et al.⁴ observed that in WHS patients with a *de novo* unbalanced translocation t(4;8) the breakpoint in 8p recurred always in the same region within olfactory receptor gene cluster. On the contrary, breakpoints in 4p occurred at two different sites; at a distance of approximately 5 and 14Mb from the telomere, thus implying a different ex-

tent of the 4p deletion⁴. Phenotype of the unbalanced t(4;8) patients is variable and there is no specific clinical pattern which allows identification of these patients³. The short stature and severe mental retardation of those with the WHS contrasted sharply with the mild to moderate mental retardation, less severe dysmorphic features and physical overgrowth of those with the 4p16.3 duplication^{2,5}.

We have compared similarity of the clinical features in our proband to other patients carrying a solely duplication of the distal part of 4p or a deletion of distal part of 8p, and similar combination of unbalanced form, described in the literature.

Case Report

The proband is a 5-month old boy referred for genetic evaluation because of dysmorphic features. He was delivered at term by cesarean section after uneventful pregnancy. At birth, length was 52 cm, weight 3,360 g, and

head circumference 35 cm. There was no family history of malformations or mental retardation. He showed a distinctive facial dysmorphic features: narrow forehead, hirsutism, wide nasal bridge, anteverted nostrils, low set and malformed ears, small mandible and low hairline on the neck. Heart defect was present in the form of atrioventricular septal defect. A bilateral inguinal hernia with undescended right testicle was present. There were unilateral vesicoureteral reflux, grade III and diastasis of the rectus abdominis muscles by 3 cm. Magnetic resonance imaging of the brain showed hypoplasia of the corpus callosum. He had clinodactyly and low inserted third toe. However, there was no growth delay. This study was approved by the Ethics Committee of the University Hospital Centre Osijek and School of Medicine, J. J. Strossmayer University Osijek and the written informed consent was obtained from the parents of the proband.

Cytogenetic and FISH Analysis

Cytogenetic examination of GTG banded metaphases (at resolution of 550 bands) obtained by standard methods⁶, showed an unbalanced proband's karyotype with extra chromosome material at the short arm of the chromosome 8 (Figure 1) using Olympus BX61 microscope and Cytovision 3.93 software (Applied Imaging, England). FISH (fluorescence *in situ* hybridization) with spe-

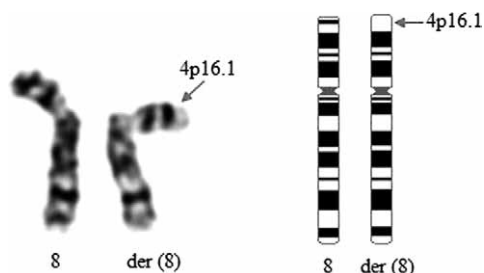

Fig. 1. Partial karyotypes of the GTG banded chromosomes and ideograms of a proband showing *de novo* derived chromosome 8.

cific probes (Vysis/Abbott) for centromere of chromosome 4 (D4Z2), locus specific probe for Wolf-Hirschhorn Syndrome region (WHCR, 4p16.3), centromere 8 (D8Z2) and subtelomere of chromosome 8p (D8S504) on metaphases showed presence of two hybridization signals for probe WHCR (4p16.3) at each of the 4p and one additional signal at the p arm of the derivative chromosome 8 (Figure 2). Subtelomere 8p probe signal is present in only one copy and is missing from the derivative chromosome 8. Subsequent chromosomal analysis of the parents revealed normal karyotypes. The karyotype of proband is then 46,XY,der(8)t(4;8)(p16.1;p23.1).ish der(8)t(4;8)(D8S504-,WHCR+,D8Z2+)dn.

Discussion and Conclusion

We described a proband with dysmorphic features and an unbalanced translocation resulting in both partial trisomy for 4p16.1→pter and partial monosomy for 8p23.1→pter, respectively. We have compared similarity of the clinical features in our proband to other patients carrying a duplication of the distal part of 4p^{7,8} and patients carrying a deletion of distal part of 8p^{9,10-12} as described in the literature (Table 1).

Individuals with deletion of 8p are reported to share a distinctive pattern of clinical features which include low birth weight, congenital heart disease, developmental delay and a characteristic behaviour profile with hyperactivity and impulsiveness^{9,10,13,14}. Patients with terminal deletion 8p frequently have heart defects, especially atrioventricular septal defect and this led to the suggestion that this chromosome region may harbour a gene (*GATA4*, OMIM 600576) important in heart development^{10,11,15}. Studies with model vertebrate systems have implicated *GATA4*, transcription factor as a critical regulator of cardiac gene expression and development¹⁶. It should be noted that not all patients with proven deletion of 8p23.1 have cardiac anomalies. Possible explanations are that the patients without cardiac pathology are not deleted for *GATA4* or, compensatory increases in

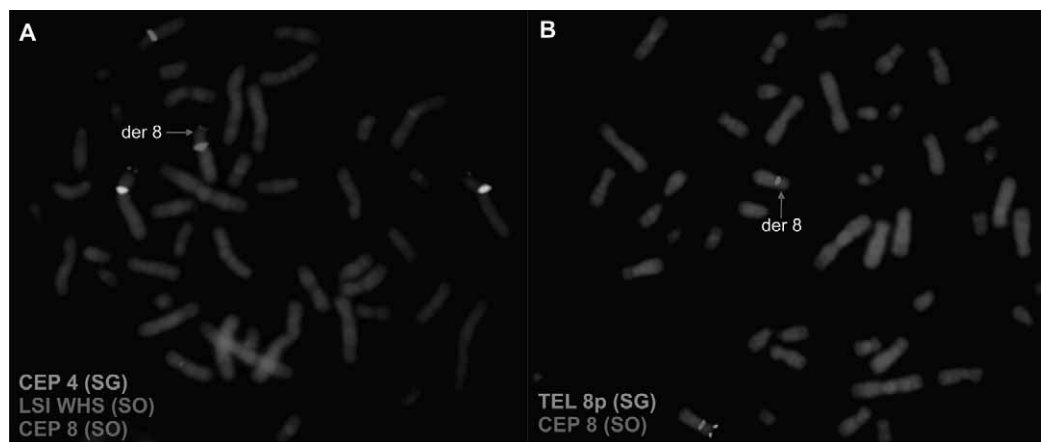


Fig. 2. Proband FISH analysis (A) using centromere probes 4 and 8 (D8Z2) and locus specific probe LSI WHS-4p16.3 and (B) using centromere probe 8 (D8Z2) and subtelomere probe 8p: D8S504 (Vysis/Abbott).

TABLE 1
LIST OF CLINICAL SYMPTOMS CHARACTERISTIC FOR PARTIAL TRISOMY 4p AND PARTIAL MONOSOMY 8p

	Partial trisomy 4p (Gerard-Blanluet 2004, Demirhan 2010, Mau 2000)	Partial monosomy 8p (Brocker-Vriends 1986, Blennow 1990, Hutchinson 1992, Gilmore 2001)	Our case der(8)t(4;8)(p16.1;p23.1)	Case of der(8)t(4;8)(p12;p23) Mau et al. (2000)
Craniofacial anomalies	Microcephaly, low hairline, hirsutism, low set and enlarged ears, bulbous nose, broad nasal bridge, long eyelashes, synophrys, hypertelorism, retrognathia, micrognathia, pointed chin, short neck	Microcephaly, craniofacial dysmorphism, high and narrow forehead, small eyes, strabismus, hypertelorism, epicanthal folds, long philtrum, short nose, small jaw, irregularly implanted teeth, retrognathia, thin upper lip, low set and malformed ears, narrow external ear canal, short neck, nystagmus	Low hairline, hirsutism, narrow forehead, wide nasal bridge, anteverted nostrils, low set and malformed ears, small jaw	Hirsutism, low hairline, synophrys, high arched eyebrows, short nose with a wide nasal bridge, anteverted nostrils, full cheeks, long philtrum, thin lips, flat palate, widely spaced teeth, low set ears
Skeletal anomalies	Pointed chin, arachnodactyly, clinodactyly, rocker-bottom feet	Clinodactyly, low inserted thumb, widely spaced nipples, rocker bottom feet, hypoplastic toenails	Clinodactyly, widely spaced nipples, third toe low inserted	Small hands with proximal placement of the thumbs, dystrophic nails, fifth finger clinodactyly, widely spaced nipples
Cardiovascular anomalies	Atrial septal defect	Atrioventricular septal defect, ductus arteriosus, pulmonary valve stenosis, patent ductus arteriosus, isomerism of the atria, tetralogy of Fallots	Atrial septal defect	Mild hypertrophy of the heart
Urogenital and renal anomalies	Shawl scrotum, cryptorchidism	Hypospadias, undescended testis, cryptorchidism, horseshoe kidneys, bilateral ureteric reflux	Vesicoureteral reflux grade III right side, bilateral inguinal hernia, diastasis rectus abdominis 3 cm, undescended right testis (high in scrotum)	Small clitoris

GATA5 or *GATA6* may mitigate the effects of *GATA4* deletion, and haploinsufficiency for other cardiac transcription factor genes (e.g. *TBX5*, *NKX2-5*) causes congenital heart disease¹⁶. Alternatively, inherited mutations in other genes or stochastic events may impact on the severity of heart disease in patients haploinsufficient for *GATA4*¹⁷. Deletion 8p23.1 should be considered in the differential diagnosis of cases suspected to have velocardiofacial syndrome^{10,17}. Intellectual disability is the most frequently reported developmental outcome. There does seem to be a relation between the size of the deleted region on chromosome 8 and the degree of intellectual disability, with more distal terminal deletions being associated with higher functioning¹².

On the other hand, more than 75 cases of trisomy 4p have been reported thus far, most of them due to unbalanced translocations^{7,8}. Trisomy 4p has been shown to cause specific phenotype associated with characteristic facial appearance, postnatal growth retardation and severe psychomotor retardation with or without seizures, microcephaly and various major and minor anomalies. The large variability of the phenotype in trisomy 4p syndrome may be explained by the variation in length and

the breakpoint location of the duplicated segments on 4p⁷.

To the best of our knowledge, until today there have been only few reports of a combination of duplication 4p16.1→4pter and deletion 8p23.1→8pter syndrome^{15,17}.

With exception of microcephaly, synophrys, hypertelorism, retrognathia, pointed chin, short neck and rocker bottom feet, our proband had most of the clinical features associated with dup 4p syndrome. These included low hairline, hirsutism, wide nasal bridge, low set ears, clinodactyly, atrial septal defect and cryptorchidism. The variation in severity of phenotype may be related to such variables as age, sex and different size of chromosome segment involved in dup 4p syndrome, as well as the terminal loss of genetic material of the second chromosome involved in such an unbalanced translocation^{7,8}. The most of the cases of trisomy 4p have been due to unbalanced translocations. In half of the cases, an acrocentric chromosome was involved¹⁸. The involved breakpoints vary between the cases, with consequently variation in phenotypes.

There are only few published cases with a derivative chromosome 8p and a partial trisomy 4p and monosomy

8p, respectively. Our proband and case of der(8)t(4;8)(p12;p23)² have some phenotypic similarity, such as: hirsutism, low hairline, a wide nasal bridge, anteverted nostrils, low set ears, and widely spaced nipples. Maas et al.¹⁷ reported two patients with duplication of 4p16 and deletion of 8p23.1, however, no clinical features were given for these cases^{15,17}. One patient with the karyotype 46,XX,der(8)t(4;8)(p15.32;p22), was reported at 3 months of age to be developmentally and physically normal⁵. According to the Unique database¹⁹ with 10 affected members, level of learning difficulty ranges from severe to mild form, with some of them showing obsessive or compulsive behaviour patterns. The degree of mental handicap varies from moderate to mild with no specific behavioural characteristics⁵. They tend to be tall, which can be explained by the presence of third copy of FGFR3 gene on the 4p16.3. That could be also an explanation for a lack of growth retardation in our case. Facial features include a slight asymmetry, widely spaced eyes, a small nose and a short neck¹⁹. An abnormal muscular tone and in some children foot position can be cause of delayed gross motor skill development in most of the patients with this translocation. Development of fine motor skills is also very often affected¹⁹. This type of unbalanced form comprises generalized overgrowth with a duplication of 4p16.3, and mild to moderate mental retardation.

Giglio et al.¹ found that t(4p;8p) may be the most frequent translocation after the t(11q;22q), which is the

most common reciprocal translocation in humans^{1,16}. Since it involves regions of very similar size and banding pattern, it may be undetected by a routine cytogenetic analysis. Possible molecular mechanism of translocation 4p;8p formation is an ectopic meiotic recombination between the olfactory receptor gene clusters located on chromosome 4p and 8p. Those clusters, on molecular level, are organized like heterozygous submicroscopic inversion and can cause a chromosomal imbalance involving those two chromosomal regions. That kind of chromosomal rearrangements implies that inversion heterozygotes may be at risk of having a child with a *de novo* chromosomal rearrangement^{1,15}. It was recently demonstrated that WHS-associated t(4p;8p) translocations frequently occur within olfactory receptor gene clusters on both 4p and 8p, with the involvement of two distinct olfactory receptor gene clusters in 4p at a distance of about 5 and 14Mb from the telomere and of a unique olfactory receptor gene cluster in 8p⁴. Proband's parents can be inversion heterozygotes on molecular level for an olfactory receptor gene clusters on both chromosome 4p and 8p, and that can be the cause of unbalanced rearrangement also in our proband.

Further case studies with a detailed clinical and molecular characterization will certainly contribute to a more precise description of the deletion 8p syndrome and will pinpoint the candidate region on chromosome 4 responsible for partial trisomy 4p.

REFERENCES

- GIGLIO S, CALVARI V, GREGATO G, GIMELLI G, CAMANINI S, GIORDA R, RAGUSA A, GUERNERI S, SELICORNI A, STUMM M, TONNIES H, VENTURA M, ZOLLINO M, NERI G, BARBER J, WIECZOREK D, ROCCHI M, ZUFFARDI O, Am J Hum Genet, 71 (2002) 276. — 2. MAU UA, BACKSCH C, SCHAUDT H, TREFZ FK, KAISER P, Am J Med Genet, 91 (2000) 180. DOI: 10.1002/(SICI)1096-8628(20000320)91:3<180::AID-AJMG4>3.0.CO;2-R. — 3. TONNIES H, STUMM M, NEUMANN L, VOLLETH M, GRUMPELT U, MUSEBECK J, ANNUSS G, NEITZEL H, J Med Genet, 38 (2001) 21. DOI: 10.1136/jmg.38.6.e21. — 4. ZOLLINO M, LECCE R, SELICORNI A, MURDOLO M, MANCUSO I, MARANGI G, ZAMPINO G, GARAVELLI L, FERRARINI A, ROCCHI M, OPITZ JM, NERI G, Eur J Hum Genet, 12 (2004) 797. DOI: 10.1038/sj.ejhg.5201203. — 5. PARTINGTON MW, FAGAN K, SOUBJAKI V, TURNER G, J Med Genet, 34 (1997) 153 DOI: 10.1136/jmg.34.9.179. — 6. MOORHEAD PS, NOWELL PC, MELLMAN WJ, BATTIPS DM, HUNGERFORD DA, Exp Cell Res, 20 (1960) 613. — 7. DEMIRHAN O, ÖZGÜNEN FT, TASTEMIR D, Balk J Med Genet, 13 (2010) 8. — 8. GERARD-BLANLUET M, ROMANA S, MUNIER C, LE LORCH M, KANAFANI S, SINICO M, TOUBOUL C, LEVAILLANT JM, HADDAD B, LOPEZ N, LELONG F, BILLETTE DE VILLEMEUR T, VERLOES A, BORGHI E, Am J Med Genet, 130A (2004) 299. DOI: 10.1002/ajmg.a.30314. — 9. BROCKER-VRIENDS AHJT, MOOLJ PD, VAN BELL F, BEVERSTOCK GC, VAN DE KAMP JJP, J Med Genet, 23 (1986) 153. — 10. REDDY KS, Prenat Diagn, 19 (1999) 868 DOI: 10.1002/(SICI)1097-0223(199909)19:9<868::AID-PD641>3.0.CO;2-A. — 11. DEVRIENDT

- K, MATTHIJS G, VAN DAEL R, GEWILLIG M, EYSKENS B, HJALGRIM H, DOLMER B, MCGAUGHRAN J, BRONDUM-NIELSEN K, MARYNEN P, FRYNS JP, VERMEESCH JR, Am J Hum Genet, 64 (1999) 1119. — 12. GILMORE L, CUSKELLY M, JOBLING A, SMITH S, Dev Med Child Neurol, 43 (2001) 843. DOI: 10.1111/j.1469-8749.2001.tb00174.x. — 13. BLENNOW E, BRONDUM-NIELSEN K, J Med Genet, 27 (1990) 327. — 14. HUTCHINSON R, WILSON M, VOULLAIRE L, J Med Genet, 29 (1992) 407. — 15. GIGLIO S, GRAW SL, GIMELLI G, PIROLA B, VARONE P, VOULLAIRE L, LERZO F, ROSSI E, DELLAVECCHIA C, BONAGLIA MC, DIGILIO MC, GIANNOTTI A, MARINO B, CARROZZO R, KORENBERG JR, DANESINO C, SUJANSKY E, DALLAPICCOLA B, ZUFFARDI O, Circulation, 102 (2000) 432. DOI: 10.1161/01.CIR.102.4.432. — 16. PEHLIVAN T, POBER BR, BRUECKNER M, GARRETT S, SLAUGH R, VAN RHEEDEN R, WILSON DB, WATSON MS, HING AV, Am J Med Genet, 83 (1999) 201. DOI: 10.1002/(SICI)1096-8628(19990319)83:3<201::AID-AJMG11>3.0.CO;2-V. — 17. MAAS NMC, VAN VOOREN S, HANNES F, VAN BUGGENHOUT G, MYSLIWIEC M, MOREAU, FAGAN K, MIDRO A, ENGIZ O, BALCI S, PARKER MJ, SZNAJER Y, DEVRIENDT K, FRYNS JP, VERMEESCH JR, Genet Counseling, 18 (2007) 357. — 18. BARTOCCI A, STRIANO P, MANCARDI MM, FICHERA M, CASTIGLIA L, GALESÌ O, MICHELUCCI R, ELIA M, Brain Dev, 30 (2008) 425. DOI: 10.1016/j.braindev.2007.11.004. — 19. UNIQUE, The rare chromosome disorder support group, accessed 08.06.2013. Available from: URL: <http://www.rarechromo.org/information/Chromosome%20%208/4p%208p%20Translocation%20FTNW.pdf>.

I. Škrlec

J.J. Strossmayer University, School of Medicine, Cytogenetic laboratory, J. Huttlera 4, 31 000 Osijek, Croatia
e-mail: iskrlec@mefos.hr

DE NOVO SLUČAJ DJELOMIČNE TRISOMIJE 4p I DJELOMIČNE MONOSOMIJE 8p

SAŽETAK

Fenotip pacijenata s djelomičnom aneuploidijom često ima varijabilnu kliničku sliku ovisnu o veličini kromosomskog segmenta uključenog u translokaciju. Prikazane su kliničke citogenetičke osobitosti dječaka starog pet mjeseci s duplikacijom dijela kromosoma 4p16.1→4pter i s gubitkom dijela kromosoma 8p23.1→pter. Kariotip probanda određen je primjenom klasičnog GTG pruganja kromosoma i korištenjem FISH proba (lokus specifična proba za WHCR regiju, centromera 4, centromera 8, telomera 8p): 46,XY,der(8)t(4;8)(p16.1;p23.1).ish der(8)t(4;8)(D8S504-,WHCR+,D8Z2+)dn. Roditelji nisu u srodstvu i utvrđen im je normalan kariogram. Usporedili smo sličnost kliničkih osobitosti našeg pacijenta s ostalim pacijentima opisanim u literaturi koji imaju samo duplikaciju distalnog dijela 4p ili deleciju distalnog dijela 8p, ili sličnu kombinaciju nebalansiranog kariotipa.

