

A Case of Transient Constrictive Pericarditis in a 42-year-old Patient

Marina Gradišer¹, Jasna Cmrečnjak¹, Branko Ostrički¹, Ivana Marodi¹, Višnja Kokić², Slaven Kokić⁴ and Andrej Pal³

¹ County Hospital Čakovec, Department of Internal Medicine, Čakovec, Croatia

² University of Split, University Clinical Hospital Centre Split, Split, Croatia

³ County Hospital Varaždin, Department of Radiology, Varaždin, Croatia

⁴ University of Split, School of Medicine, Split, Croatia

ABSTRACT

We report a case of 42 year old patient with acute idiopathic pericarditis in whom we describe transient cardiac constriction, consisting of the temporary development of features of constrictive pericarditis with subsequent return to normality after medical therapy alone. After a mean of 6 months, there have been no recurrences of constrictive physiology or clinical symptoms. The results of our study suggest that patients who have constrictive features early in the course of their illness and are hemodynamically stable should be considered for a trial of conservative therapy before pericardiectomy is pursued.

Key words: transient constrictive pericarditis, echocardiography, conservative therapy

Introduction

Constrictive pericarditis (CP) classically presents as a progressive and debilitating condition characterized by pericardial fibrosis, with or without calcification. This results in chronic refractory congestive heart failure for which pericardiectomy is often required. Until relatively recently, the development of constrictive physiology was presumed to be irreversible. However, in the past two decades there have been reports describing transient forms of constrictive pericarditis that have resolved without surgical intervention¹. The development of constrictive hemodynamics and subsequent resolution with medical therapy (transient constrictive pericarditis) was first described by Sagrista-Sauleda et al.². Since then, it has been described in the setting of collagen vascular disease³, purulent bacterial pericarditis^{3,4}, and chemotherapy⁵. Two-dimensional echocardiography with Doppler is one of the initial tests performed when CP is clinically suspected and oftentimes is diagnostic. However, it should be noted that even a carefully performed echocardiogram may be inconclusive in differentiating CP from restrictive cardiomyopathy, and in these cases additional testing, including cardiac catheterization and even surgical exploration, may be required to establish the diagnosis⁶.

Case report

We present a case of 42-year-old patient with a one-month history of fatigue and exertional dyspnea who came to our Emergency Room (ER) department complaining of abdominal discomfort accompanied by anasarca. There were no specific changes on initial electrocardiogram (ECG), the values of troponin T were normal and the brain natriuretic peptide NT fragment (NT pro BNP) slightly increased. On presentation, he was normothermic, tachycardic (heart rate 113/min) with normal first and second heart sounds and without audible pericardial rub. Jugular veins were markedly distended with positive Kussmaul sign and hepatomegaly. Blood pressure (BP) was 115/100 mmHg. Chest X-ray showed increased size of the heart, bilateral pleural effusion and increased hilar drawing. Technically adequate M-mode echocardiogram was available for analysis and reviewed in detail by two observers. A transthoracic echocardiogram in our patient, revealed abnormal ventricular septal motion-septal bounce (Figure 1), respiratory variation in ventricular size, biatrial enlargement and presence of a dilated inferior vena cava without inspiratory collapse. The Doppler flow velocity measurements revealed exaggerated respiratory variation (more than 25%) in both mitral inflow velocity (Figure 2) and tricus-

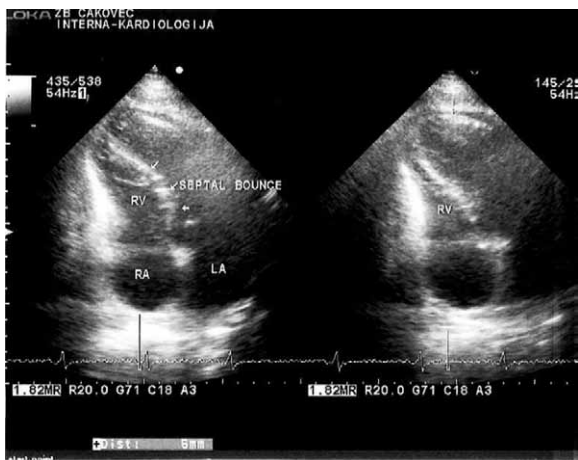

Fig. 1. Echocardiographic findings in constrictive pericarditis showing abnormal ventricular septal motion-septal bounce (arrows). LA=left atrium, LV=left ventricle, RV=right ventricle.

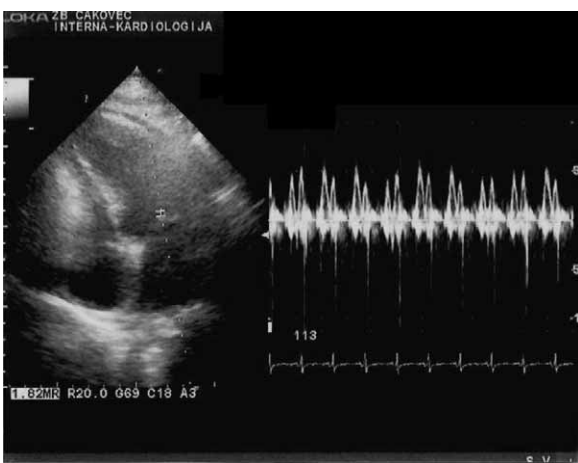

Fig. 2. Doppler finding in constrictive pericarditis. Pulsed-wave Doppler recording of flow velocity measurements revealed exaggerated respiratory variation (more than 25%) in both mitral inflow velocity.

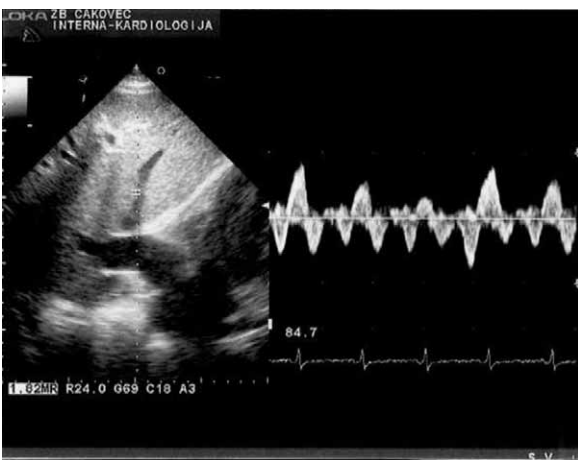


Fig. 3. Doppler finding in constrictive pericarditis. Pulsed-wave Doppler recording of prominent systolic retrograde wave in hepatic vein flow.

pid-mitral inflow difference. We also recorded characteristic Doppler findings in CP: expiratory decreases in hepatic vein diastolic forward flow and increase in hepatic vein diastolic flow reversals. (Figure 3). Left ventricular ejection fraction (LV EF) was normal and there weren't any signs of pulmonary hypertension or pulmonary valve stenosis. Early diastolic filling (E/E'), based upon measure of tissue doppler imaging (TDI) of the mitral annulus (diastolic function of left ventricle) was 5. Chest Multi-slice computed tomography (MSCT) revealed thickened pericardium (8–16 mm) especially surrounding right ventricle without signs of calcification. There was also a moderate-sized right pleural effusion present with associated compressive atelectasis (Figure 4). With subsequent diagnostic work-up we excluded restrictive cardiomyopathy, primary liver disease, pulmo-

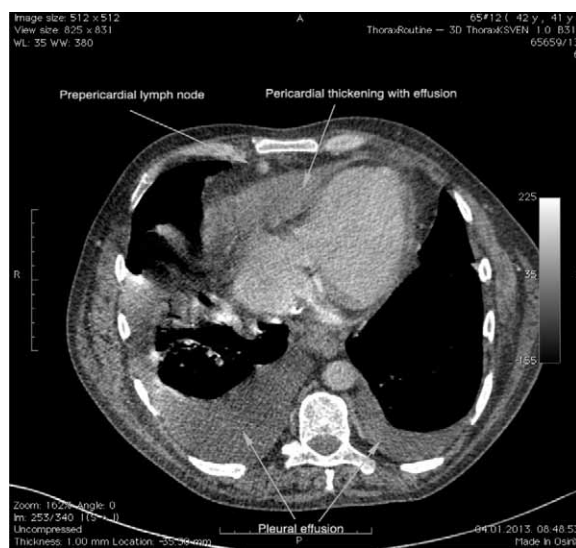


Fig. 4. Pericardial thickening in constrictive pericarditis. Cardiac MSCT imaging in a 42-year-old man who presented with idiopathic pericarditis. Note marked thickening of the pericardium over the right heart as well as a moderate-sized right pleural effusion present with associated compressive atelectasis (arrows).

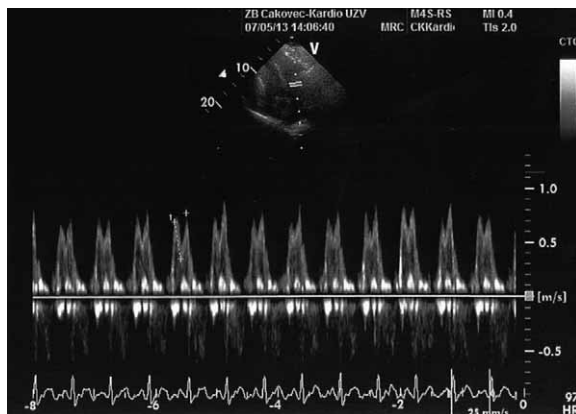


Fig. 5. Follow-up echocardiogram one month later, Doppler recording of the mitral inflow velocity in patient described in Fig. 2., showing no respiratory variations in transmitral inflow, consistent with resolution of constrictive hemodynamics.

nary hypertension and lung disease. Patient refused cardiac catheterization. The etiology of pericardial constriction was not established but idiopathic or postviral cause seemed likely. Patient was treated with nonsteroidal anti-inflammatory drugs (NSAID), diuretics and salt restrictive diet to relief fluid overload and peripheral edema, beta blocker and antibiotic therapy. Once constriction features had disappeared, finding of physical examination was normal in our patient. Significant clinical improvement was seen following 4 weeks of treatment with regression of edema, ascites, hepatomegaly and pleural effusion. Sinus rhythm persisted throughout the clinical evolution. Control echocardiography after 3 months, revealed resolution of constrictive hemodynamics according to flow velocity measurements as well as regression of vena cava inferior and hepatic vein dilation (Figure 5). Follow-up MSCT imaging of the heart performed in the same patient three months later demonstrated normal thickness of the pericardium (Figure 6). After a mean of 6 months, there have been no recurrences of constrictive physiology or clinical symptoms. The symptoms and constrictive physiologic features in our patient resolved after 3 months with medical therapy alone, a phenomenon that has been labeled »transient constrictive pericarditis«. Therefore, we recommend a trial of medical therapy with the expectation of an average recovery time of three months.

Conclusion

It is important to recognize the CP in the acute phase of illness, because if the constrictive findings are going to resolve, they do so at average time of three months. The resolution of echocardiographic findings of constriction

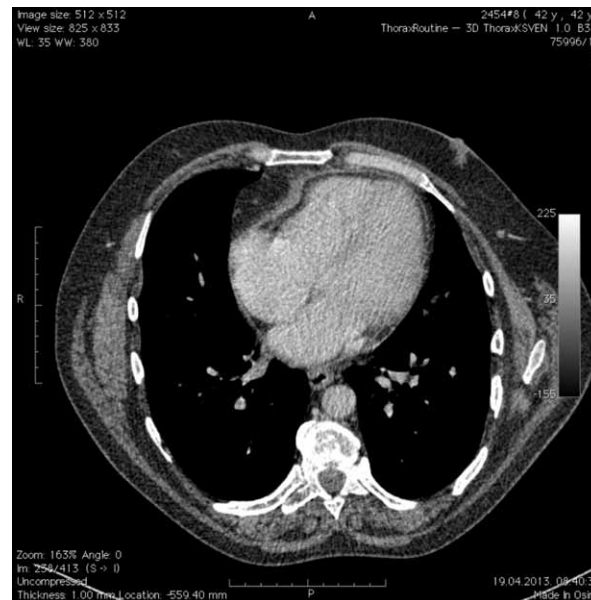


Fig. 6. Resolution of pericardial thickening in transient constrictive pericarditis. Follow-up imaging of the heart performed in the same patient three months later demonstrates normal thickness of pericardium.

can be expected in less than 6 months. The results of our study also confirm the results of other studies^{1–3} suggesting that patients who have constrictive features early in the course of their illness and are hemodynamically stable should be considered for a trial of conservative therapy before pericardiectomy is pursued.

REFERENCES

1. HALEY JH, TAJIK AJ, DANIELSON, J Am Coll Cardiol, 43 (2004) 271. — 2. SAGRISTA-SAULEDA J, PERMANYER-MIRALDA G, CANDRELL-RIERA J, Am J Cardiol, 59 (1987) 961. — 3. OH JK, HATLE LK, MULVAGH SL, Mayo Clin Proc, 68 (1993) 1158. — 4. ALLARIA A, MI-

CHELLI D, CAPELLI H, Eur J Pediatr, 151 (1992) 250. — 5. ENGEL PJ, FOWLER NO, TEI CW, J Am Coll Cardiol, 6 (1985) 471. — 6. HATLE LK, APPLETON CP, POPP RL, Circulation, 79 (1989) 357.

S. Kokić

University of Split, University Hospital Centre Split, Šoltanska 1, 21 000 Split, Croatia
e-mail: kokić.slaven@gmail.com

SLUČAJ PROLAZNOG KONSTRIKCIJSKOG PERIKARDITISA KOD 42-GODIŠNJEG PACIJENTA

SAŽETAK

Prikazujemo slučaj 42-godišnjeg pacijenta s idiopatskim akutnim perikarditisom u kojem opisujemo prolaznu srčanu konstrikciju, koji prikazuje privremeni razvoj značajki konstrikcijskog perikarditisa s naknadnim normaliziranjem nakon medicinske terapije. Nakon razdoblja od 6 mjeseci, nije bilo recidiva konstrikcijske fiziologije ili kliničkih simptoma. Rezultati našeg istraživanja pokazuju kako pacijenti sa konstrikcijskim značajkama i koji su hemodinamski stabilni u ranom stadiju njihove bolesti trebaju biti uzeti u obzir za konzervativnu terapiju prije pojave perikardiotomije.

