

Identification and characterization of natural concurrent avian leukosis virus subgroup J and *Aspergillus flavus* infection in commercial layer chickens

**Liming Cai, Yanming Wang, Guihua Wang, Yumei Cai,
and Ziqiang Cheng***

College of Veterinary Medicine, Shandong Agricultural University, Tai'an, China

CAI, L. M., Y. M. WANG, G. H. WANG, Y. M. CAI, Z. Q. CHENG: Identification and characterization of natural concurrent avian leukosis virus subgroup J and *Aspergillus flavus* infection in commercial layer chickens. Vet. arhiv 84, 279-289, 2014.

ABSTRACT

Simultaneously occurring myelocytomas caused by avian leukosis virus subgroup J (ALV-J) and Aspergillosis caused by *Aspergillus flavus* were diagnosed in a commercial layer flock. The mortality was up to 1% at 180 days old in this one of two, fifteen thousand layer flocks. Clinical signs of the affected chickens started from 80 day old, and included inactivity, depressed and anorexia. No respiratory signs were observed. On necropsy, various sized gray to yellow tumor-like nodular lesions were found on viscera. Microscopically, the tumor-like nodules were composed of two kinds of patterns, central caseous necrotic granulomas and multifoci eosinophilic myeloid cell proliferation. Intestinal adenocarcinoma in the duodenum, atrophy lesion in the ovaries, arteritis in various tissues, and hydrocephalus were observed, respectively. Hemotologically, the percentage of heterophils and eosinophils were significantly increased, while lymphocytes, basophils and monocytes were significantly decreased. Aetiologically, *A. flavus* was cultured from the liver granulomas, and four strains of ALV-J were isolated from the serum of sick chickens, while ALV-A, ALV-B, MDV and REV were PCR negative. The antibody of ALV-J was negative (viremia) in seven sick chickens. The isolates have the highest nucleotide sequence homology (98.2~98.4%) with the prototype strain HPRS-103 of ALV-J. The evidence in this study shows that the source of ALV-J was from vertical transmission, while the source of *A. flavus* was not determined. This is the first report of ALV-J and *A. flavus* occurring naturally and concurrently in commercial layer hens.

Key words: avian leukosis virus subgroup J, *Aspergillus flavus*, myelocytomas, aspergillosis

*Corresponding author:

Prof. Dr. Ziqiang Cheng, College of Veterinary Medicine, Shandong Agricultural University, Tai'an, 271018, China, Phone +86 135 0548 4575; Fax: +86 538 8241 419; E-mail: czqsd@126.com

Introduction

Avian leukosis virus subgroup J (ALV-J) is an oncogenic exogenous retrovirus of chicken, first reported in the UK (PAYNE et al., 1991) and it subsequently caused severe economic losses in the poultry industry all over the world. Clinical infection is associated with neoplastic diseases, including myelocytomas, hemangiomas, erythroblastosis, nephromas and any form of sarcoma, and non-neoplastic diseases, including body weight loss, immune tolerance and production problems (ARSHAD et al., 1997; PAYNE, 1998; LANDMAN et al., 2002; PAYNE et al., 1992; STEDMAN and BROWN, 1999). Impairment of immune responses in single or dual ALV infected chickens has been observed (STEDMAN and BROWN, 1999; CUI et al., 2006; WILLIAMS and SELLERS., 2012; FENTON et al., 2005).

Aspergillosis is a fungal disease caused by fungi of the genus *Aspergillus*. *A. fumigatus* and *A. flavus* are considered to be major respiratory and non-respiratory pathogens in chicks, because *A. fumigatus* has smaller spores, at 2-3 μm , compared to *A. flavus* at 3-6 μm (BRAKHAGE and GUNZER., 2007). Other species, such as *A. niger*, *A. nidulans*, and *A. terreus*, may also be isolated from avian cases of aspergillosis (OKOYE et al., 1989; PERELMAN and KUTTIN, 1992; AKAN et al., 2002; BEHNSEN et al., 1998; MARTIN et al., 2007; OKOYE and OKEKE, 1986). In natural outbreaks, *A. flavus* has been isolated from tissue involving skin, bone, trachea, and nonrespiratory viscera (MOHAMMED et al., 1980; GHAZIKHANIAN, 1989; BARTON et al., 1992; PAL et al., 1989). The ability of *A. flavus* to cause disease may be promoted by immunosuppressive events, such as stress or concurrent infection with infectious bursal disease virus (IBDV) (OKOYE et al., 1991). There has been no report of natural co-infection of ALV-J and *A. flavus* in commercial layer chicken flocks.

On October 29, 2012, seven sick 180-day-old commercial layer hens were sent to the Molecular Pathology Lab, College of Veterinary Medicine, Shandong Agricultural University for diagnosis. The chickens were from a fifteen thousand layer flock. All the chickens had been obtained from a parental breeder at 1 day of age. The houses had been completely cleaned and disinfected before the flock was placed. Commercial layer chicken feed and municipal drinking water were provided. The birds received routine vaccinations. At 80 days of age, the chickens experienced increased daily mortality of approximately 0.1%. Daily mortality continued at approximately 0.1%/day in the flock until 180 days of age, when it increased to 1%/day. Peak egg production was significantly lower than in the other unaffected flock. Affected chickens showed emaciation, anorexia and diarrhea. A high incidence of tumor-like nodules was observed in the mortality by the owner or veterinarian when the flock was examined. No respiratory signs were observed.

Materials and methods

Hematology. Blood was collected from the wing vein. One milliliter of blood was preserved for total leukocyte count (TLC), percent of heterophils, eosinophils, lymphocytes, basophil and monocytes, whereas one milliliter of blood was allowed to coagulate for separation of serum to detect avian leukosis virus subgroup J (ALV-J) antibodies (Avian Leukosis Virus Antibody Test Kit -Subgroup J, IDEXX Bio-tek, America). Blood smears were fixed in methanol and stained with Wright's-Giemsa stain for determination of differential leukocyte count and morphological evaluation of all blood cells. The results of hematology were compared with previous reported normal chickens (PAMPORI and IQBAL, 2007).

Gross and histopathology. Seven chickens were euthanatized by cervical dislocation and necropsied. Gross lesions were examined. Tissue samples of the liver, spleen, heart, lung, kidney, proventriculus, ventriculus, intestine, muscle, ovary, brain, bone marrow and discrete nodules were removed from the birds and fixed in 10% neutral buffered formalin. Tissues were processed by standard paraffin embedding, sectioned at approximately 4 μ m, and stained with hematoxylin and eosin (H&E) for observation.

Pathogens test. A fungal culture was obtained by aseptically swabbing the internal of nodule, liver, spleen and kidney, and streaking the swab across a petri dish containing a specially prepared fungal isolation medium. The protocol was carried out according to a previous report (MARTIN et al., 2007). After the appearance of fungal colonies, sterile transfers of hyphal tips to a new medium were made, to obtain pure cultures of the fungus.

DNA was extracted from the spleen and amplified with primers specific for ALV-J, ALV-A, ALV-B, REV and MDV by polymerase chain reaction (PCR) (CHENG et al., 2010). Filtrated serum from PCR positive chicken was inoculated on monolayer DF-1 cells, and cultured for 7 days. DNA of infected DF-1 cells was extracted, then for PCR. The amplified gene was purified using an agarose gel DNA extraction kit (E.Z.N.A. TM GEL Extraction Kit, Omega Bio-tek, America) and further cloned into the pMD18-T vector, according to the manufacturer's instructions. Recombinant plasmids were transformed into a DH5 α competent cell. Single colonies were picked and cultured for plasmid extraction. Plasmids were sequenced for homological comparison. The genomic DNA of DF-1 infected Chinese NX0101 strain of ALV-J was used as a positive control.

Results

Hematology. The hematological profile of seven sick chickens is shown in Table 1. The percentage of heterophils and eosinophils was increased; lymphocytes, basophil and monocytes were relatively decreased. TLC was increased almost 10 times compared with normal chickens. Blood smear showed that erythrocytes appeared to have normal features, and the number of heterophils, thrombocytes and eosinophils were increased.

The ALV-J antibodies of seven sick chickens were all negative when tested by an ELISA kit. It indicated that all seven affected chickens were in a viraemic state.

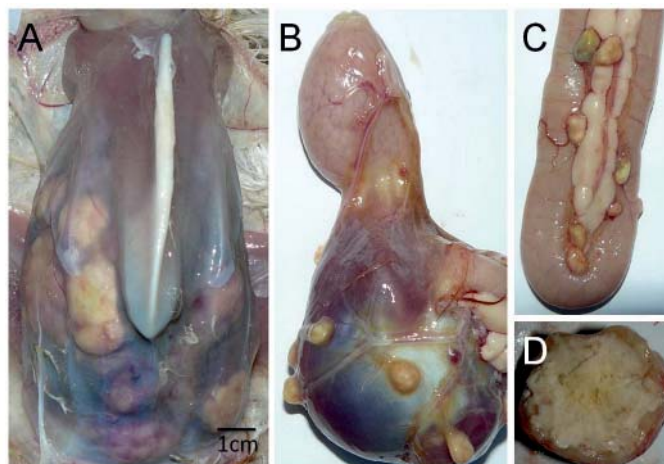


Fig. 1. Gross lesions. A: pale atrophy muscle, big abdomen, translucent peritoneum, and numerous granulomas under peritoneum; B: granulomas on ventriculus; C: granulomas on intestine and pancreas; D: cut surfaces of big granuloma, caseous masses were showed in center. Scale bar = 1 cm.

Gross lesions. All chickens had pale atrophy of the muscles and ovary, an enlarged abdomen, translucent peritoneum, and numerous tumor-like nodules of the viscera (Fig. 1A), including the liver, ventriculus (Fig. 1B), intestine (Fig. 1C), and pancreas (Fig. 1C). Tumor-like nodules were variably sized (the diameter of the largest one was 3.8 cm), roughly spherical to oval in shape, moderately firm, pale to yellow in color with irregular, lumpy surfaces, and they replaced much of the affected organ, especially the liver. On cut surfaces, single or multiple caseous masses were seen in the center (Fig. 1D), but some small solid nodules without caseous masses in the center were also observed. Hemorrhage was a common lesion in the liver, muscles and kidneys. Bone marrow was pale and firm. No nodules were seen on air sacs, crops, lungs, spleen, heart, kidney, ovary, nerve, brain or bone.

Histopathology. Microscopically, the nodular lesions seen grossly in multiple tissues were composed of two types of form. One was a well-organized granulomatous form, with peripheral giant cells and connective vallum that widely varied in thickness, and more or less inflammatory cells or infiltrated tumor cells. A typical granuloma often consists of four layers. The central mass was composed of caseous necrotic dark stained exudates , and spores were occasionally seen in it. The second layer was composed of more or less irregular multinucleated giant cells surrounding the central mass. The third

layer was a zone of fibroblasts and abundant capillaries, with sporadic infiltration of lymphocytes, heterophils and macrophages. Small granulomas were also occasionally located in this zone. The fourth layer was a large number of myelocytomas cells, among the connective tissues. Granulomas were found in the liver (Fig. 2A), spleen (Fig. 2C), kidney, proventriculus, ventriculus, intestine (Fig. 2E), pancreas and heart (Fig. 2F). The other nodular form was myelocytomas, which had no caseous masses in the center, in the liver (Fig. 2B), bone marrow (Fig. 2D), spleen, kidney and heart. Myelocytoma cells had similar morphology to the myeloid cells that had a large number of acidophilic granules in the cytoplasm and a vesicular or lobulated nucleus, with a few chromatin clumps. Mitotic figures were often seen in the tumor foci.

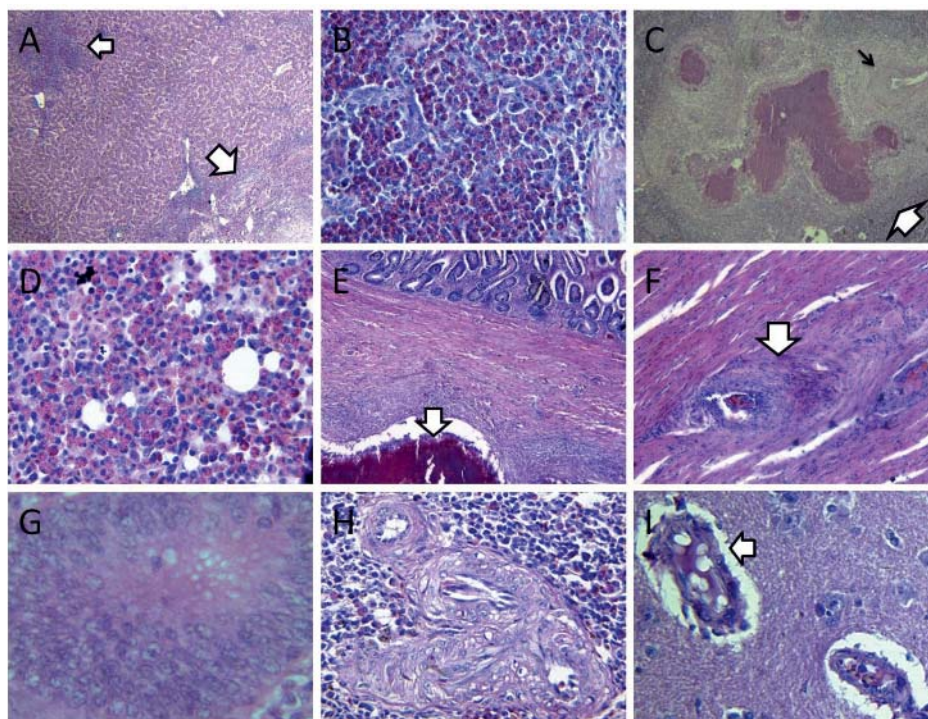


Fig. 2. Histopathology lesions. A: foci of myelocytoma and granuloma in liver ($\times 100$, HE); B: proliferated myelocytomas cells in liver ($\times 200$, HE); C: big granuloma with small granuloma and degeneration artery in spleen ($\times 40$, HE); D: crowded myelocytomas cells in bone marrow ($\times 200$, HE); E: granuloma on serosum layer of duodenum ($\times 40$, HE); F: proliferated nodules in heart ($\times 100$, HE); G: intestinal adenocarcinoma ($\times 400$, HE); H: arteritis in spleen ($\times 200$, HE); I: non-purulent encephalitis ($\times 200$, HE).

Simultaneously, intestinal adenocarcinoma was found in one bird. It was located in the duodenum, which appeared pale and firm. Intestinal gland tubes had lost their normal structure. Many cuboidal epithelial cells were crowded together and appeared to be aggressive growth (Fig. 2G). No mitotic figures were observed. No granulomas or myelocytomas were present in the muscle, lung, ovary, nerve, brain and bone.

In addition, significant arteritis in various tissues, especially in the spleen, liver and kidneys, and non-purulent encephalitis in the brain were observed. Arteritis was characterized by endothelium swellings and proliferates, and the walls of the vessels had suffered fibrinoid necrosis (Fig. 2H). Non-purulent encephalitis was characterized by perivascular lymphocytes cell cuffing, congestion, hyaline thrombosis, edema and encephalomalacia (Fig. 2I).

Table 1. Hematological profile of seven sick chickens infecting with ALV-J and aspergillosis

Items	No.1	No.2	No.3	No.4	No.5	No.6	No.7	Ref
TLC ($10^3/\mu\text{L}$)	170.4	309.6	292.8	201.6	195.6	174.7	184.1	21.0
Heterophils (%)	60.0	58.4	57.2	58.7	56.5	56.9	57.6	43.6
Eosinophils (%)	13.0	13.8	15.2	14.6	16.0	15.0	16.0	10.3
Basophils (%)	0	0.1	0.05	0.2	0.1	0.3	0.2	0.3
Lymphocytes (%)	26.3	27.2	26.8	25.9	26.9	27.3	25.6	45.2
Monocytes (%)	0.7	0.5	0.7	0.6	0.5	0.5	0.6	1.5

Note: TLC — total leukocyte count

Pathogens test. *A. flavus* was identified by the colony character (Fig. 3A), spores (3~6 μm) (Fig. 3B) and hyphae size (Fig. 3C) (KLICH and PITT, 1988), morphology and its pathogenicity. Cultures were negative for bacterial organisms.

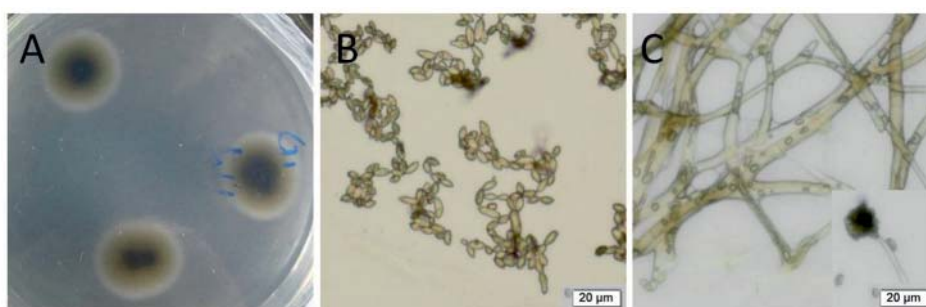


Fig. 3. *A. flavus* culture. (A). *A. flavus* was identified by the colonies characters , spores (3~6 μm) (B). and hyphae size (C). Scale bar = 20 μm . The *A. flavus* was seperated from the liver granulomas of the sick chicken.

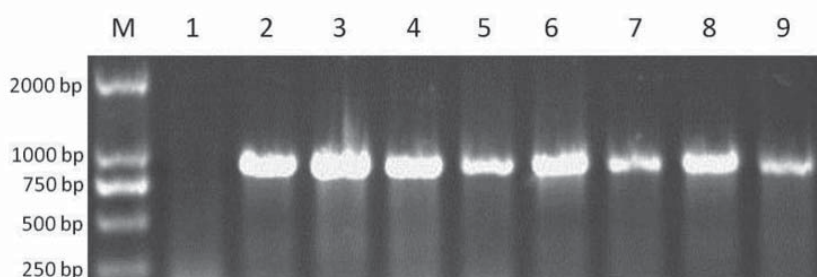


Fig. 4. PCR results. M: 2000 bp marker; 1: negative; 2: positive; 3-9: the seven sick chickens. All seven sick chickens were PCR positive for ALV-J.

The seven sick chickens were all positive on PCR for ALV-J (Fig. 4), negative for ALV-A, ALV-B, REV and MDV. Four strains of ALV-J were isolated in the DF-1 cell line.

Sequencing. Gp85 genes of four strains were sequenced and homology was analyzed. The gp85 gene sequence was compared with HPRS-103 (Z46390), ADOL-Hc1 (AF097731), ADOL-4817 (AY027920), and the China strain YZ9901 (AY897222), NX0101 (AY897227), SD0002 (AY8972724) and SD0101 (AY8972725) (BAI et al., 1995; BEHNSEN et al., 1998; ZAVALA et al., 1998; CUI et al., 2006; CUI et al., 2003). The GenBank accession number which corresponds to the virus-related sequences of strains is after the strain name. Homology is shown in Fig. 5. The homology of strains CX11102903, CX11102901, CX11102601 and CX11102905 with HPRS-103 was 98.2%, 98.3%, 98.4% and 98.4%, respectively.

		Percent Identity												
		1	2	3	4	5	6	7	8	9	10	11		
Divergence	1	█	100.0	99.9	99.8	98.4	96.0	94.7	95.5	93.8	96.1	94.5	1	CX11102905.seq
	2	0.0	█	99.9	99.8	98.4	96.0	94.7	95.5	93.8	96.1	94.5	2	CX11102601.seq
	3	0.1	0.1	█	99.7	98.3	95.9	94.6	95.4	93.9	96.0	94.4	3	CX11102901.seq
	4	0.2	0.2	0.3	█	98.2	95.8	94.5	95.3	93.6	95.9	94.3	4	CX11102903.seq
	5	1.6	1.6	1.8	1.9	█	96.9	91.7	74.4	89.5	73.8	73.1	5	HPRS-103.seq
	6	4.2	4.2	4.3	4.4	3.2	█	93.8	95.2	94.8	94.7	94.1	6	ADOL-Hc1.seq
	7	5.6	5.6	5.7	5.8	8.9	6.5	█	93.0	91.3	93.7	92.5	7	ADOL-4817.seq
	8	4.6	4.6	4.7	4.9	31.5	5.0	7.5	█	96.7	96.8	97.9	8	YZ9901.seq
	9	6.5	6.5	6.4	6.8	11.3	5.4	9.4	3.4	█	95.7	96.1	9	NX0101.seq
	10	4.1	4.1	4.2	4.3	32.3	5.6	6.7	3.3	4.5	█	96.5	10	SD0002.seq
	11	5.7	5.7	5.8	5.9	33.4	6.2	8.0	2.1	4.0	3.6	█	11	SD0101.seq
		1	2	3	4	5	6	7	8	9	10	11		

Fig. 5. Percentage of nucleotide identity of ALV-J strains

Discussion

The horizontal spread of ALV-J normally leads to an immune response characterized by the development of virus-neutralizing antibodies (PAYNE, 1998). In contrast, birds that are vertically infected become immunologically tolerant to the virus, have a persistent viremia and do not develop neutralizing antibodies (WITTER and FADLY, 2001). In this case, all seven sick chickens were virus positive and antibody negative (viremic) for ALV-J. This means that this commercial layer flock may have been congenitally infected by ALV-J.

Natural infections with *A. flavus* result in disseminated infections that affect multiple tissues (GHAZIKHANIAN, 1989), and they do not cause severe respiratory disease in commercial poultry because of its larger spores (RICHARD et al., 1981). Immunosuppressive virus infection or other stress factors can increase the severity of *A. flavus* infections (OKOYE and OKEKE, 1986).

Microscopically, myelocytomas caused by ALV-J and granulomas caused by *A. flavus* were found concurrently in the liver, spleen, kidney and heart. In some nodules, we found granulomas and myelocytomas existing independently, infiltrated or surrounding each other. So, ALV-J and *A. flavus* may mutually promote the development of lesions. In the duodenum, we found marked intestinal adenocarcinoma. In our previous report, we observed that intestinal adenocarcinoma was associated with ALV-J and REV (CHENG et al., 2010; WANG et al., 2012), but we did not exclude possible *A. flavus* infection. It is well known that aflatoxins (AF) produced by *A. flavus* can induce mutagenesis, teratogenesis and carcinogenesis (EDDS and BORTELL, 1983). Based on non-respiratory symptoms, the gross and histopathology lesions, we concluded that the flock's exposure to *A. flavus* was possibly by ingestion. Thus, the possibility that *A. flavus* induced intestinal adenocarcinoma was high.

Evidence from this case confirmed that ALV-J and *A. flavus* have synergy. Potentially ALV-J infection in chickens with Aspergillosis should be considered as a step towards a better understanding of the pathogenesis.

Acknowledgements

This study was supported by grants from the Natural Science Foundation of China (31372458) and the Shandong Agricultural Technology and Industry System (SDAIT-13-011-04).

References

- AKAN, M., R. HAZROGLU, Z. ILHAN, B. SAREYYUPOGLU, R. TUNCA (2002): A case of aspergillosis in a broiler breeder flock. *Avian Dis.* 46, 497-501.

- ARSHAD, S. S., A. P. BLAND, S. M. HACKER, L. N. PAYNE (1997): A low incidence of histiocytic sarcomatosis associated with infection of chickens with the HPRS-103 strain of subgroup J avian leukosis virus. *Avian Dis.* 41, 947-956.
- BAI, J., L. N. PAYNE, M. A. SKINNER (1995): HPRS-103 (exogenous avian leukosis virus, subgroup J) has an env gene related to those of endogenous elements EAV-0 and E51 and an E element found previously only in sarcoma viruses. *J. Virol.* 69, 779-784.
- BARTON, J. T., B. M. DAFT, D. H. READ, H. KINDE, A. A. BICKFORD (1992): Tracheal aspergillosis in 6 K-week-old chickens caused by *Aspergillus flavus*. *Avian Dis.* 36, 1081-1085.
- BEHNSEN, J., P. NARANG, M. HASENBERG, F. GUNZER, U. BILITEWSKI, N. KLIPPEL, M. ROHDE, M. BROCK, S. J. BENSON, B. L. RUIS, A. L. GARBERS, A. M. FADLY, K. F. CONKLIN (1998): Independent isolates of the emerging subgroup J avian leucosis virus derive from a common ancestor. *J. Virol.* 72, 10301-10304.
- BRAKHAGE, A. A., M. GUNZER (2007): Environmental dimensionality controls the interaction of phagocytes with the pathogenic fungi *Aspergillus fumigatus* and *Candida albicans*. *PLoS Pathog.* 3, 138-151.
- CHENG, Z. Q., J. Z. LIU, Z. Z. CUI, L. ZHANG (2010): Tumors associated with avian leukosis virus subgroup J in layer hens during 2007 to 2009 in China. *J. Vet. Med. Sci.* 72, 1027-1033.
- CUI, Z., Y. DU, Z. ZHANG, R. F. SILVA (2003): Comparison of Chinese field strains of avian leukosis subgroup J viruses with prototype strain HPRS-103 and United States strains. *Avian Dis.* 47, 1321-1330.
- CUI, Z., S. SUN, J. WANG (2006): Reduced serologic response to Newcastle disease virus in broiler chickens exposed to a Chinese field strain of subgroup J avian leukosis virus. *Avian Dis.* 50, 191-195.
- EDDS, G. T., R. A. BORTELL (1983): Biological effects of aflatoxins: poultry aflatoxin and *Aspergillus flavus* in corn. In bulletin of the diener. (Asquit R. L., J. W. Dickens, Eds.). Alabama Agricultural Experiment Station Alabama, AL, USA, Auburn University. pp. 64-66.
- FENTON, S. P., R. R. MADDULA, T. J. BAGUST (2005): Single and concurrent avian leukosis virus infections with avian leukosis virus-J and avian leukosis virus-A in Australian meat-type chickens. *Avian Pathol.* 34, 48-54.
- GHAZIKHANIAN, G. Y. (1989): An outbreak of systemic aspergillosis caused by *Aspergillus flavus* in turkey poults. *J. Am. Vet. Med. Assoc.* 194, 17-98.
- LANDMAN, W. J., J. POST, A. G. BOONSTRA-BLOM, J. BUUYSE, A. R. ELBERS, G. KOCH (2002): Effect of an in ovo infection with a Dutch avian leukosis virus subgroup J isolate on the growth and immunological performance of SPF broiler chickens. *Avian Pathol.* 31, 59-72.
- KLICH, M. A., J. I. PITT (1988): A laboratory guide to common *Aspergillus* species and their teleomorphs. Commonwealth Scientific Research Organization, Division of Food Processing, North Ryde, New South Wales, Australia.
- MARTIN, M. P., K. P. BOUCK, J. HELM, M. J. DYKSTRA, D. P. WAGES, H. J. BARNES (2007): Disseminated *Aspergillus flavus* infection in broiler breeder pullets. *Avian Dis.* 51, 626-631.

- MOHAMMED, M. A., S. M. SOKKAR, A. BATRAWI, M. K. REFAIE, A. A. S. AHMED (1980): Natural and experimental nodular dermatomycosis in chickens. *Avian Pathol.* 9, 185-192.
- OKOYE, J. O. A., H. C. GUGNANI, C. N. OKEKE (1989): Pulmonary infections due to *Aspergillus flavus* in turkey poults and goslings. *Mycoses* 32, 336-339.
- OKOYE, J. O. A., C. N. OKEKE (1986): Pathogenicity of an isolate of *Aspergillus flavus* in chickens. *Avian Pathol.* 15, 259-270.
- PAL, M., R. M. GANGOPADHYAY, K. S. PRAJAPATI (1989): Systemic aspergillosis in chicks due to *Aspergillus flavus*. *Indian J. Anim. Sci.* 59, 1074-1075.
- PAMPORI, Z. A., S. IQBAL (2007): Haematology, serum chemistry and electrocardiographic evaluation in native chicken of Kashmir. *Int. J. Poultry Sci.* 6, 578-582.
- PAYNE, L. N. (1998): Retrovirus-induced disease in poultry. *Poultry Sci.* 77, 1204-1212.
- PAYNE, L. N., S. R. BROWN, N. BUMSTEAD, K. HOWES, J. A. RAZIER, M. E. THOU LESS (1991): A novel subgroup of exogenous avian leukosis virus in chickens. *J. Gen. Virol.* 72, 801-807.
- PAYNE, L. N. (1998): HPRS-103: a retrovirus strikes back. The emergence of subgroup J avian leukosis virus. *Avian Pathol.* 27, S36-S45.
- PAYNE, L. N., A. M. GILLESPIE, K. HOWES (1992): Myeloid leukaemogenicity and transmission of the HPRS-103 strain of avian leukosis virus. *Leukemia* 6, 1167-1176.
- PERELMAN, B., E. S. KUTTIN (1992): Aspergillosis in ostriches. *Avian Pathol.* 21, 159-163.
- RICHARD, J. L., R. C. CUTLIP, J. R. THURSTON, J. SONGER (1981): Response of turkey poults to aerosolized spores of *Aspergillus fumigatus* and aflatoxigenic and nonaflatoxigenic strains of *Aspergillus flavus*. *Avian Dis.* 25, 53-67.
- STEDMAN, N. L., T. P. BROWN (1999): Body weight suppression in broilers naturally infected with avian leukosis virus subgroup J. *Avian Dis.* 43, 604-610.
- WANG, G. H., Y. WANG, L. L. YU, Y. P. JIANG, J. Z. LIU, Z. Q. CHENG (2012): New pathogenetic characters of reticuloendotheliosis virus isolated from Chinese partridge in specific-pathogen-free chickens. *Microb. Pathogenesis* 53, 57-63.
- WILLIAMS, S. M., H. S. SELLERS (2012): Response of white leghorn chickens to infection with avian leukosis virus subgroup J and infectious bursal disease virus. *Avian Dis.* 56, 2-6.
- WITTER, R. L. A. M. FADLY (2001): Reduction of horizontal transmission of avian leukosis virus subgroup J in broiler breeder chickens hatched and reared in small groups. *Avian Pathol.* 30, 641-654.
- ZAVALA, G., M. A. JACKWOOD, S. HAFNER, J. R. GLISSON, D. A. HILT (1998): Molecular and biological characterization of an oncogenic subgroup J avian leukosis-like virus (ALV-J). *J. Virol.* 72, 10301-1030.

Received: 25 January 2013

Accepted: 28 March 2014

CAI, L. M., Y. M. WANG, G. H. WANG, Y. M. CAI, Z. Q. CHENG: Identifikacija i karakterizacija virusa leukoze peradi podskupine J i plijesni *Aspergillus flavus* kod istodobne prirodne infekcije komercijalnih nesilica. Vet. arhiv 84, 279-289, 2014.

SAŽETAK

Istodobna pojava mijelocitoma prouzročenog virusom ptičje leukoze podskupine J (ALV-J) i aspergiloze prouzročene vrstom *Aspergillus flavus* opisana je u jednom komercijalnom jatru nesilica. Mortalitet je iznosio do 1% u 180 dana starih pilića na jednoj od dvije farme od 15 tisuća nesilica. Zahvaćeni pilići počeli su pokazivati kliničke znakove bolesti u dobi od 80 dana. Bili su nepokretni, potišteni i nisu uzimali hranu. Dišni znakovi nisu bili primijećeni. Pri razudbi su na visceralnim organima ustanovljene sivkaste do žućkaste čvoraste tumorske promjene različite veličine. Mikroskopski su bila ustanovljena dva tipa tumorskih čvorova: granulomi sa središnjom kazeoznom nekrozom i multifokalna proliferacija eozinofilnih mijeloidnih stanica. Ustanovljen je adenokarcinom dvanaesnika, atrofične lezije jajnika, arteritis u različitim tkivima i hidrocefalus. Hematološkom pretragom ustanovljen je značajno povećan postotak neutrofila i eozinofila, dok je broj limfocita, bazofila i monocita bio značajno smanjen. *A. flavus* bio je izdvojen iz granuloma jetre, a četiri soja virusa leukoze podskupine J bila su izdvojena iz seruma oboljelih pilića. Lančanom reakcijom polimerazom nisu bili dokazani virus leukoze podskupine A i podskupine B, virus Marekove bolesti i virus retikulendotelioze. Protutijela za virus podskupine J nisu bila dokazana pretragom sedam bolesnih pilića. Po nukleotidnom slijedu izolati su pokazivali najvišu homolognost (98,2-98,4%) s prototipnim sojem HPRS-103 virusa leukoze ptica podskupine J. Pokazalo se da se virus prenosio vertikalno, a izvor plijesni *A. flavus* nije bio ustanovljen. Ovo je prvo izvješće o prirodnoj istodobnoj infekciji virusom leukoze podskupine J i vrstom *A. flavus* u komercijalnih nesilica.

Ključne riječi: virus leukoze peradi podskupina J, *Aspergillus flavus*, mijelocitom, aspergiloza
