

## ACUTE DISSEMINATED ENCEPHALOMYELITIS MIMICKING ACUTE MENINGOENCEPHALITIS

Mahmoud Reza Ashrafi<sup>1</sup>, Davood Amirkashani<sup>1</sup>, Armin Hirbod-Mobarakeh<sup>2,3,4</sup>, Bahareh Yaghmaei<sup>1</sup>,  
Alireza Tavassoli<sup>1</sup>, Farzad Manafi<sup>1</sup> and Nima Rezaei<sup>1,2,3</sup>

<sup>1</sup>Pediatrics Center of Excellence, Children's Medical Center; <sup>2</sup>Research Center for Immunodeficiencies; <sup>3</sup>Molecular Immunology Research Center and Department of Immunology, School of Medicine; <sup>4</sup>Students' Scientific Research Center, Tehran University of Medical Sciences, Tehran, Iran

**SUMMARY** – Acute disseminated encephalomyelitis is an inflammatory demyelinating disease of the central nervous system that usually occurs following an antecedent infection or vaccination. Children and young adults are predominantly affected, but it has low incidence in children younger than 3 years. The disease manifests with a wide range of neurological abnormalities and a variable combination of fever, headache, meningism, convulsion and cranial nerve palsies, and there are no pathognomonic clinical or laboratory findings. So, establishment of definitive diagnosis is challenging in infants. This challenge may result in delayed diagnosis and consequently delayed treatment of acute disseminated encephalomyelitis, which may cause permanent neurological disability. Herein, we report an infant with acute disseminated encephalomyelitis, who mimicked the symptoms of meningoencephalitis and the correct diagnosis and treatment were delayed till the development of a severe phase of the disease.

**Key words:** *Encephalomyelitis, acute disseminated; Meningoencephalitis; Case report*

### Introduction

Acute disseminated encephalomyelitis (ADEM) is a monophasic, polysymptomatic disorder resulting from inflammatory demyelination of the central nervous system (CNS) white matter<sup>1</sup>. It usually develops very fast and presents various combinations of motor, sensory, visual and cognitive signs to general pediatricians<sup>2-4</sup>. The diagnosis is established by evidence of multifocal, hyperintense lesions on fluid-attenuated inversion recovery (FLAIR) and T2-weighted magnetic resonance imaging (MRI) scan<sup>3,5</sup>. ADEM is a rare disease with an estimated incidence of 0.8/100,000/year, usually occurring after an infection or vaccination<sup>1,6</sup>. The incidence is highest in children but low

among very young patients, especially those below three years of age<sup>7</sup>.

In children, ADEM can present with a prodromal phase including fever, malaise, headache, nausea and vomiting, which usually progresses over hours or days to meningeal signs and drowsiness. These symptoms represent a diagnostic challenge. In children, especially in infants, the manifestations of ADEM can be interpreted by several conditions due to the wide range of possible etiologies. This diagnostic challenge may result in delayed diagnosis until the symptoms of a severe phase of disease appear. Consequently, delay in treatment may cause permanent neurological disability acquired very early in life<sup>4,8</sup>.

There are only few cases of infantile ADEM in the literature. The mean age of children with ADEM who have been reported in the literature since 1987 was 6.7 years and only rarely there was a case younger than 1 year<sup>8,9</sup>. In a study of 28 patients with ADEM, there was not any case of ADEM younger than 3 years<sup>10</sup>.

Correspondence to: *Nima Rezaei, MD, PhD*, Children's Medical Center Hospital, 62 Qarib St., Keshavarz Blvd., Tehran 14194, Iran

E-mail: rezaei\_nima@tums.ac.ir

Received July 17, 2012, accepted January 16, 2013

Herein, we report a 3-month-old girl with ADEM, who mimicked the symptoms of septic meningoen-  
cephalitis. She was first treated as a case of meningitis and after deterioration of her condition, she was diag-  
nosed as ADEM.

### Case Report

A 3-month-old girl with a chief complaint of fever and poor feeding was admitted to emergency depart-  
ment of the Children's Medical Center, Pediatrics Center of Excellence in Iran. She was the first child to unrelated parents, was born by cesarean section and

had a birth weight of 3500 g. She had up-to-date im-  
munization.

One week before admission, she had rhinorrhea, coughing and wheezing. Family physician diagnosed it as a nonspecific upper respiratory tract infection and prescribed amoxicillin and acetaminophen, which improved the symptoms. Three days prior to admis-  
sion, she presented fever, fatigue and poor feeding. Finally, the patient was admitted to the emergency department due to exacerbation of these symptoms. On admission, she was ill-looking, anicteric and fe-  
brile (tympanic temperature, 38.5 °C), with low state of consciousness. She had tachypnea with a respira-

*Table 1. Laboratory findings of the patient*

	Patient	Normal range
White blood cell count	1750/ $\mu$ L	4.5-11.0 $10^3/\mu$ L
Red blood cell count	4.1	3.1-4.3 mill/ $\text{mm}^3$
Reticulocyte count	3%	0%-2.8%
Platelet	532000	300-700 $\times 10^3/\text{mm}^3$
Hematocrit	27.1%	29%-42%
Neutrophils	62%	17%-45%
Lymphocytes	33%	41%-71%
Monocytes	4%	4%-7%
Eosinophils	0.7%	0%-3%
Basophils	0.3%	0%-1%
Hemoglobin	9.1g/dL	13.5-17.0 g/dL
Mean cellular volume	77.5 fm	74-96 fm
C-reactive protein	15 mg/dL	0-12 mg/dL
Erythrocyte sedimentation rate	15 mm/h	0-20 mm/h
Lymphocyte markers:		
CD3	76%	49%-76%
CD4	60%	31%-63%
CD19	11.9%	14%-37%
CD8	16.6%	17.4%-34.2%
Arterial blood gas:		
pH	7.44	7.35-7.45
PCO <sub>2</sub>	25 mm Hg	35-45 mm Hg
HCO <sub>3</sub>	17 mEq/L	19-25 mEq/L
Cerebrospinal fluid:		
White blood cell count	42/ $\mu$ L (80%Lymph)	0.7 WBC/ $\text{mm}^3$
Red blood cell count	2	0
Glucose	57 mg/dL	40-80 mg/dL
Protein	25 mg/dL	5-40 mg/dL

tory rate of 48/min. The patient had neither diarrhea nor vomiting. She had had low urine volume from the previous day. The patient had nothing abnormal on physical examination and also neck stiffness was absent, but she had a slight bilateral palpebral edema.

Urine and blood culture, serology for human immunodeficiency virus (HIV), cytomegalovirus (CMV), Epstein-Barr virus (EBV), HHV6, influenza, herpes simplex viruses (HSV) and typhoid and paratyphoid A and B fever were done and were all negative. Laboratory results for blood revealed normocytic anemia with mild respiratory alkalosis and increased inflammatory markers (Table 1). Immunologic tests were all within the normal range. Lumbar puncture was performed and cerebrospinal fluid (CSF) analysis revealed leukocytosis with lymphocytic predominance.

Due to the presence of fever and inflammatory changes in blood and CSF, the initial diagnosis was infective meningoencephalitis, especially herpes simplex meningoencephalitis; therefore, empirical treatment with ceftriaxone, vancomycin and acyclovir was started. In the next few hours, the patient showed signs of respiratory distress. In the meantime, CSF was analyzed for HSV, HHV7, influenza, H1N1 using the polymerase chain reaction (PCR), with negative results.

On day 3, the patient developed focal seizures with upward gaze on the right eye and bilateral tonic movements in the limbs with right-sided dominance. These seizures repeated 3 times within 2 hours; so, phenobarbital was administered to the patient. After 8 hours, phenytoin was added to drug regimen due to another event of seizure, which improved the patient's condition. Electroencephalography (EEG) was not remarkable for epilepsy. Computed tomography (CT) scan of the brain was performed, which revealed mild prominence of the frontal lobe gyri, widening of the sylvian fissure, minimal prominence of the lateral ventricle, and excess of extra-axial fluid. Dexamethasone (0.15 mg/kg every 6 hours) was added to drug regimen to prevent focal neurological deficits of probable meningitis. On day 4, the patient's general status including fever, consciousness and respiratory distress improved dramatically. Dexamethasone was stopped, but several hours later, the patient presented right eye deviation and anisocoria (right pupil miosis and left mydriatic). A positive Babinski sign in the right foot was seen too. In the next hours, the patient developed fatigue and low grade fever. On MRI, disseminated demyelinated lesions in the right periventricular region, left cerebellum and brain stem were seen. Considering the signs, MRI results and exclusion of other

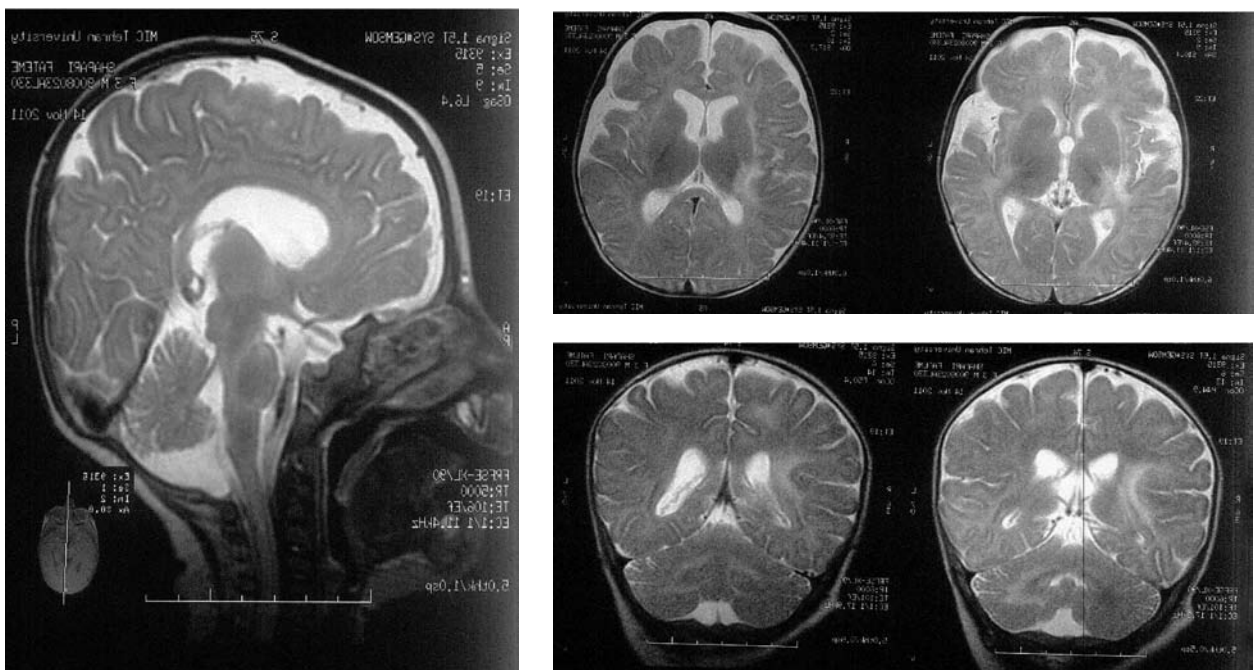


Fig. 1. Magnetic resonance images of the brain before treatment, fluid-attenuated inversion recovery (FLAIR) sequence.

possible etiologies, the diagnosis of ADEM was established (Fig. 1). Therefore, corticosteroid therapy was started with prednisolone (2 mg/kg/day), while antibiotics were stopped. On day 3 of corticosteroid therapy, all the symptoms including fever improved. Taking brain stem lesions into consideration, the auditory brainstem response (ABR) test was taken, which yielded normal result. Corticosteroid therapy was continued with a tapering dose of oral prednisone for 6 weeks.

## Discussion

Acute disseminated encephalomyelitis is a rare demyelinating disorder of the white matter of the CNS with highest incidence in childhood<sup>1,5,6</sup>. Although it has a wide range of clinical manifestations, including various combinations of motor, sensory, visual and cognitive symptoms, it usually begins with systemic symptoms like fever, malaise, myalgia, headache, nausea, and vomiting<sup>11,12</sup>. The severe course of the disease can be presented by a variable combination of convulsions, cranial nerve palsies, visual field deficits, language disturbances, mental status abnormalities, and psychiatric changes in children<sup>3,11,12</sup>. Seizures are mainly seen in severe cases in children younger than 5 years<sup>2,13</sup>. Our patient in the early phase of disease presented with just a low grade fever, fatigue and poor feeding, and due to the delay in diagnosis and consequently mistreatment rapidly developed seizures as a manifestation of a severe phase of the disease. In our patient, the course of development of symptoms and their improvement in response to corticosteroids were more rapid than usual. These findings suggest an aggressive form of the disease, which may be age-related<sup>14</sup>.

Timely diagnosis of ADEM is of great importance because delay in treatment may result in permanent neurologic disorder<sup>2,15</sup>. In infants, in-time diagnosis can be compromised by a number of factors. The rarity of infantile ADEM is one of the most important factors that may delay suspicion and thus the diagnosis of ADEM. In infants, the systemic symptoms of the early phase of the disease present as some more nonspecific symptoms, such as poor feeding, fatigue and fever. These symptoms in infants represent a diagnostic challenge as they can be caused by a wide range of possible etiologies<sup>8,16-18</sup>. Therefore, the dis-

ease may remain unsuspected and without appropriate treatment would develop to severe phase and present with cranial nerve palsies and generalized or focal seizures<sup>11,12</sup>. As there are no pathognomonic clinical or laboratory findings for ADEM, even on brain CT or MRI, the physician can take ADEM in consideration only through a careful process of exclusion of other diseases<sup>4,19</sup>. These laboratory tests often delay the establishment of ADEM diagnosis and appropriate treatment.

The first and most important differential diagnosis in the early phase of ADEM, especially in infants, is acute viral, bacterial, or parasitic meningoencephalitis, especially HSV meningoencephalitis<sup>2,4,8,15,20</sup>. Meningoencephalitis has the same initial clinical features as ADEM (fever, headaches, and confusion)<sup>8</sup>. ADEM usually begins after a nonspecific upper respiratory tract infection, so the physician may assume the antecedent infection if ADEM has extended to the meninges and brain and misinterpret the symptoms as meningoencephalitis<sup>21</sup>. If this event is too close to presentation of ADEM, this would be even more disguising, as in our patient. The latency period takes 4 to 21 days on average<sup>2,4</sup>. The reason for the short latency period in our patient may have been the immaturity of the CNS myelin or age related differences in the patient's immune response in comparison to adults.

Laboratory findings in ADEM, which are the same as in septic meningoencephalitis, show an inflammatory profile such as elevated white cell count, erythrocyte sedimentation rate and C-reactive protein<sup>17</sup>. Even by CSF, the physician cannot exclude septic meningitis, as the CSF profile in ADEM shows lymphocytic pleocytosis or polymorphonuclear leukocytosis in early phases<sup>7</sup>. In addition, atypical CSF profile in infantile ADEM may delay the diagnosis. For instance, the total protein content in CSF is usually increased<sup>7</sup>, but in the presented case there was no increase in the CSF protein content. CT scan most of the time is unrevealing but may show evidence of CSF excess mostly due to inflammatory reactions<sup>17</sup>. The evidence of CSF excess in our patient's CT scan was a misleading factor, which was interpreted as a consequence of meningoencephalitis. After the episodes of seizure, EEG may be done, which usually does not demonstrate any significant changes<sup>7</sup>.

The most valuable test for the diagnosis of ADEM is MRI, although no imaging criteria have been identified for ADEM<sup>7,22</sup>. Inflammatory demyelinating white matter lesions, as hallmarks of ADEM, are most frequently identified on T2-weighted and FLAIR sequences. These asymmetric lesions usually involve the subcortical and central white matter in children and in 30%-60% of cases they may also involve periventricular white matter<sup>8</sup>. The MRI of the patient presented also revealed lesions in the cerebellum and brainstem, which are common sites of involvement in children<sup>2</sup>.

Treatment of infantile ADEM is an enigma. The fatality rate of ADEM is 10%-25%, with neurologic deficits in up to 40% of survivors<sup>7,9</sup>. Due to the low incidence of ADEM, currently there is no controlled trial concerning treatment of ADEM, so therapies for ADEM are just based on clinical data<sup>7</sup>. We used corticosteroid therapy as the first-line treatment to improve cerebral edema and inflammatory process in the brain<sup>7,17,23</sup>. Although the efficacy of corticosteroids has not been well established, the result of this treatment in our patient was favorable, since dramatic improvement was seen even with a low dose of dexamethasone. Herpetic meningoencephalitis should be excluded as a probable differential diagnosis before treatment with corticosteroids, as it is a contraindication. It is recommended to use appropriate antibiotic and acyclovir to eliminate possible meningoencephalitis until the diagnosis of ADEM is definitely established<sup>17</sup>.

In conclusion, infantile ADEM is difficult to diagnose and manage at the clinical level. It is important to establish a correct diagnosis at an early stage, since permanent neurological damages may be prevented by rapid corticosteroid therapy<sup>2,15</sup>. General pediatricians should consider the diagnosis of ADEM in children with meningism, fever and acute encephalopathy, especially when they appear after an infection or vaccination<sup>4</sup>. In this condition, most of the time an early MRI will help the physician suspect ADEM<sup>22,24,25</sup>.

## References

1. TENEMBAUM S, CHITNIS T, NESS J, HAHN JS. Acute disseminated encephalomyelitis. *Neurology* 2007;68:S23-36.
2. GARG RK. Acute disseminated encephalomyelitis. *Postgrad Med J* 2003;79:11-7.
3. MURTHY SN, FADEN HS, COHEN ME, BAKSHI R. Acute disseminated encephalomyelitis in children. *Pediatrics* 2002;110:e21.
4. MENGE T, HEMMER B, NESSLER S, WIENDL H, NEUHAUS O, HARTUNG HP *et al.* Acute disseminated encephalomyelitis: an update. *Arch Neurol* 2005;62:1673-80.
5. MURTHY JM. Acute disseminated encephalomyelitis. *Neurol India* 2002;50:238-43.
6. MENGE T, KIESEIER BC, NESSLER S, HEMMER B, HARTUNG HP, STUVE O. Acute disseminated encephalomyelitis: an acute hit against the brain. *Curr Opin Neurol* 2007;20:247-54.
7. WENDER M. Acute disseminated encephalomyelitis (ADEM). *J Neuroimmunol* 2011;231:92-9.
8. TENEMBAUM SN. Disseminated encephalomyelitis in children. *Clin Neurol Neurosurg* 2008;110:928-38.
9. DAVIS LE, BOOSS J. Acute disseminated encephalomyelitis in children: a changing picture. *Pediatr Infect Dis J* 2003;22:829-31.
10. DALE RC, De SOUSA C, CHONG WK, COX TC, HARDING B, NEVILLE BG. Acute disseminated encephalomyelitis, multiphasic disseminated encephalomyelitis and multiple sclerosis in children. *Brain* 2000;123 Pt 12:2407-22.
11. YOUNG NP, WEINSHENKER BG, LUCCHINETTI CF. Acute disseminated encephalomyelitis: current understanding and controversies. *Semin Neurol* 2008;28:84-94.
12. HYNSON JL, KORNBERG AJ, COLEMAN LT, SHIELD L, HARVEY AS, KEAN MJ. Clinical and neuroradiologic features of acute disseminated encephalomyelitis in children. *Neurology* 2001;56:1308-12.
13. TENEMBAUM S, CHAMOLE S, FEJERMAN N. Acute disseminated encephalomyelitis: a long-term follow-up study of 84 pediatric patients. *Neurology* 2002;59:1224-31.
14. CARSTAIRS SD, CARSTAIRS KL. Emergency department presentation of acute disseminated encephalomyelitis. *Pediatr Emerg Care* 2007;23:109-11.
15. FUJIKI F, Tsuboi Y, HORI T, YAMADA T. Aseptic meningitis as initial presentation of acute disseminated encephalomyelitis. *J Neurol Sci* 2008;272:129-31.
16. MIHIĆ J, ROTIM K, MARCIKIĆ M, SMILJANIĆ D. Head injury in children. *Acta Clin Croat* 2011;50:539-48.
17. STONEHOUSE M, GUPTE G, WASSMER E, WHITEHOUSE WP. Acute disseminated encephalomyelitis: recognition in the hands of general paediatricians. *Arch Dis Child* 2003;88:122-4.
18. CRNKOVIĆ M, MATIJEVIĆ-MIKELIĆ V, DEMARIN V, KOŠIČEK T, MOROVIĆ S, GRAZIO S. Risk factors for gross motor dysfunction of lower limbs in children. *Acta Clin Croat* 2011;50:361-6.
19. MARCHIONI E, TAVAZZI E, MINOLI L, Del BUE S, FERRANTE P, PICCOLO G *et al.* Acute disseminated encephalomyelitis. *Neurol Sci* 2008;29 Suppl 2:S286-8.

20. HARLOFF A, RAUER S, HOFER M, KLISCH J, ELS T. Fulminant acute disseminated encephalomyelitis mimicking acute bacterial meningoencephalitis. *Eur J Neurol* 2005;12:67-9.
21. CHOWDHARY J, ASHRAF SM, KHAJURIA K. Measles with acute disseminated encephalomyelitis (ADEM). *Indian Pediatr* 2009;46:72-4.
22. OKUN MS, MILLAR B, WATSON R. Early diagnostic magnetic resonance imaging in acute disseminated encephalomyelitis. *South Med J* 2000;93:793-6.
23. DIKANOVIĆ M, KADOJIĆ D, DEMARIN V, TRKANJEC Z, MIHALJEVIĆ I, BITUNJAC M *et al.* The effect of stress hormones on cerebral hemodynamics in patients with chronic posttraumatic stress disorder. *Acta Clin Croat* 2009;48:405-11.
24. IVANKOVIĆ M, DEMARIN V. From recurrent peripheral facial palsy to multiple sclerosis. *Acta Clin Croat* 2011;50:419-21.
25. BAŠIĆ KES V, CESARIK M, ČORIĆ L, ZAVOREO I, ROTIM K, BEROŠ V *et al.* Tumor-like multiple sclerosis. *Acta Clin Croat* 2012;51:113-6.

### Sažetak

#### AKUTNI DISEMINIRANI ENCEFALOMIJELITIS KOJI IZGLEDA KAO AKUTNI MENINGOENCEFALITIS

*M. Reza Ashrafi, D. Amirkashani, A. Hirbod-Mobarakeh, B. Yaghmaei, A. Tavassoli, F. Manafi i N. Rezaei*

Akutni diseminirani encefalomijelitis je upalna demijelinizirajuća bolest središnjega živčanog sustava koja se najčešće javlja nakon prethodne infekcije ili cijepljenja. Uglavnom zahvaća djecu i mlađe odrasle osobe, ali ima nisku incidenciju u djece mlađe od tri godine. Bolest se očituje širokom lepezom neuroloških nenormalnosti i različitim kombinacijama groznice, glavobolje, meningizma, konvulzija i paralize kranijalnih živaca, a nema nikakvih karakterističnih kliničkih ili laboratorijskih nalaza. Stoga je kod dojenčadi postavljanje konačne dijagnoze vrlo zahtjevno, što može dovesti do kašnjenja u dijagnozi i posljedično zakašnjelog liječenja, a to opet može uzrokovati trajne neurološke posljedice. Ovdje prikazujemo slučaj dojenčeta s akutnim diseminiranim encefalomijelitisom, kod kojega su simptomi bili slični simptomima meningoencefalitisa pa je zakašnjelo postavljanje točne dijagnoze, a time i liječenje dovelo do razvoja teže faze bolesti.

Ključne riječi: *Encefalomijelitis, akutni diseminirani; Meningoencefalitis; Prikaz slučaja*