

The Clinical Evidence and the Role of Imiquimod in the Extramammary Paget Disease

Christos Iavazzo¹, Fotinie Ntziora², Charalampos Karachalios³, Paraskevi Evangelia Iavazzo⁴, Ioannis D. Gkegkes⁵

¹Iaso Maternity Hospital, Athens, ²1st Department of Medicine, Laiko General Hospital, Athens, ³Department of Surgery, Elena Venizelou Hospital, Athens, ⁴Rural Practice, Molos, Fthiotida, ⁵Department of Surgery, Korinthos General Hospital, Corinth, Greece

Corresponding author:

Christos Iavazzo, MD, MSc, PhD
38, Seizani Str., Nea Ionia
Athens 14231
Greece
christosiavazzo@hotmail.com

Received: October 11, 2013

Accepted: February 15, 2014

SUMMARY Extramammary Paget disease is a rare disease. Different treatment options are used for its management, among them treatment with imiquimod. Our aim is to clarify the efficacy and safety of the use of topical imiquimod cream in the treatment of extramammary Paget disease. In this article the current literature in Pubmed and Scopus on this topic is reviewed.

According to the literature the topical use of imiquimod can be used as first-line treatment in different dosages and durations with excellent results, reaching a 87.5% cure rate with rare complications. The available evidence is currently limited to case reports and a single case series, but is definitely in favor of imiquimod use as an alternative treatment for extramammary Paget disease.

KEY WORDS: extramammary, Paget disease, imiquimod, vulva, scrotum, genital neoplasia

INTRODUCTION

Extramammary Paget disease is an infrequent cutaneous neoplasm of the apocrine gland-bearing vulvar or scrotum skin with an unknown etiology (1,2). It represents less than 1% of vulvar neoplasms (3,4). The presentation is variable and non-specific. Most commonly, it presents as an intraepithelial adenocarcinoma in situ, and rarely as the pagetoid spread of an underlying regional internal malignancy (5,6). It clinically presents as an erythematous, eczematous, pruriginous, and sometimes painful plaque with a scaly grayish well demarcated crust with erosion and ulceration on its surface (7,8). For this reason, it may be mistaken for other skin conditions, such as inflammatory diseases or infections, which can lead to a

delay in diagnosis and treatment (9). It usually affects postmenopausal women between 50 and 80 years of age or men in their seventh decade of life, predominantly of Caucasian origin.

The first-line therapeutic option for extramammary Paget disease is wide surgical excision with microscopically clear margins (10). However, surgical treatment is characterized by high recurrence rates, between 20-50% (2). Mohs microscopically controlled surgery seems to be an alternative treatment with significantly lower recurrence rates than wide local excision (45). Furthermore, not all patients are capable of undergoing an operation due to comorbidities, and some of them may opt out (11). Other treatment

options include topical agents and localized radiation therapy, electrodesiccation and curettage, laser, photodynamic therapy with aminolevulinic acid, and local chemotherapy with bleomycin, and 5-fluorouracil (5-FU) (12,13).

Imiquimod is an imidazoquinolin derivative with immunomodulating properties. It was approved by the FDA in 1997. It binds to toll-like receptor-7 of antigen-presenting cells, such as macrophages, monocytes, and dendritic cells, and promotes the activation and release of numerous cytokines, including IFN- α , TNF- α and several interleukins (14). In addition to its antiviral, antiproliferative, and antiangiogenic properties, imiquimod enhances the activity of T-cells and the aforementioned cytokines activate NK and cytotoxic cells. It is also involved with the migration of Langerhans cells to the lymph nodes and the proliferation of B-lymphocytes, and consequently induces apoptosis and obstructs the angiogenesis of the tumor (14). Imiquimod is the drug of choice for external genital warts, actinic keratosis, superficial basal cell carcinoma, vulvar intraepithelial neoplasia (VIN), and vaginal intraepithelial neoplasia (VaIN) (15), but it can also be used as a local treatment of extramammary Paget disease. It was first used this way by Zampogna *et al.* in 2002 (46). Imiquimod is locally administered, mostly in regimens of 5% cream and different application schemata. Common side effects of imiquimod include local skin irritation, erythema, and erosion. Less common side effects are post-inflammatory hyper- or hypopigmentation, flu-like symptoms, nausea, and vomiting (16).

The aim of our study is to review the published articles on the efficacy and safety of the use of topical imiquimod cream in the treatment of extramammary Paget disease.

METHODS

Data sources

We performed an electronic, systematic search of PubMed (until 23 April 2013) and Scopus (until 23 April 2013). The search strategy applied to both PubMed and Scopus databases, consisted of the combination of the following key words: (Paget disease OR Paget) AND imiquimod. In order to reveal additional studies, a manual search was also performed in the references of the selected studies.

Study selection criteria

Studies reporting data on the application of imiquimod cream in cases of extramammary Paget disease were included in the review. Abstracts from

Table 1. Main characteristics and outcomes of the female patients with extramammary Paget disease

Demographics	No. patients/ Total (%)
Age, in years*	69 (48-90)
Nr of patients	31
Medical History	
Comorbidities	4/31 (12.9)
Onset of the disease, in years*	2 (0.2-15)
Major diameter of the lesion, in cm*	5 (1.5-10)
Symptoms	
<i>pruritus</i>	21/27 (77.8)
<i>erythematous plaque</i>	18/27 (66.7)
<i>pain</i>	5/27 (18.5)
<i>local hypopigmentation</i>	1/27 (3.7)
<i>indolent eczematous eruption</i>	1/27 (3.7)
Local lymphadenopathy	0/31
Initial treatment applied	
<i>topical cream treatment</i>	10/31 (32.3)
<i>none</i>	8/31 (25.8)
<i>combination of treatments</i>	7/31 (22.6)
<i>local excision</i>	6/31 (19.3)
Location of the lesions	
<i>vulva</i>	27/31 (87.1)
<i>perianal area</i>	9/31 (29)
<i>gluteus</i>	4/31 (12.9)
<i>thorax</i>	1/31 (3.2)
<i>axilla</i>	1/31 (3.2)
Clinical features of imiquimod treatment	
Applied dose	
<i>3 times per week</i>	23/31 (74.2)
<i>2 times per week</i>	3/31 (9.7)
<i>daily</i>	4/31 (12.9)
Duration of treatment, in weeks*	14 (2-32)
Complications	
<i>pain</i>	12/31 (38.7)
<i>skin erosion</i>	12/31 (38.7)
<i>local irritation</i>	10/31 (32.3)
<i>none</i>	7/31 (22.6)
<i>erythema</i>	5/31 (16.1)
<i>pruritus</i>	4/31 (12.9)
<i>flu like symptoms</i>	3/31 (9.7)
Outcomes	
Healing	24/31 (77.4)
Follow up, in months*	10.5 (0.5-36)
Relapse	6/31 (19.3)
Treatment of relapse	
<i>surgical excision</i>	4/31 (12.9)
<i>prolongation of imiquimod treatment</i>	2/31 (6.5)
<i>radiation therapy</i>	1/31 (3.2)
<i>photodynamic therapy</i>	1/31 (3.2)

scientific conferences, editorials, and animal studies were excluded. Studies published in languages other than English, French, Italian, Spanish, German, or Greek were not included.

RESULTS

During the literature search in PubMed and Scopus, a total of 45 and 122 search results were retrieved respectively. Among these, 36 studies (35 case reports and 1 case series) were identified as eligible for inclusion in our review. One additional study was identified through manual reference search (Figure 1).

CASE REPORTS

In Table 1 we summarize the existing data from female patients included in case reports on cases of extramammary Paget disease; data for 30 patients from 21 reports were available (1-7,9,11,14,16-25).

The median age of the 30 women with extramammary Paget's disease was 69, ranging from 48 to 90 years. Four out of 30 had comorbidities. The median onset of the disease was 2 years (ranging from 0.2 to 15 years), and the median major lesion diameter was 5 cm (1.5-10 cm). The main symptoms included pruritus (77.8%), erythematous plaque (66.7%), pain (18.5%), local hypopigmentation (3.7%), and indolent eczematous eruption (3.7%). None of the patients had local lymphadenopathy. The main location of the disease was the vulva in 90% of the patients, followed by the perianal area in 30%, the gluteus in 13.3%, the thorax 3.3% and the axilla in 3.3%. The disease was initially treated with topical cream in 33.3% of the patients, a combination of treatment in 23.3%, local excision in 20.0%, while 23.3% patients received no intervention. The application of imiquimod ranged from daily (13.3%) to 3 times or (76.7%) 2 times per week (10.0%), and was given for an average of 14 weeks ranging from 2-32 weeks depending on the symptoms and complications. The most common complications after the use of imiquimod included pain in 40.0% of the patients, skin erosion in 40.0%, local irritation in 33.3%, erythema in 16.6%, pruritus in 13.3%, and flu-like symptoms in 10.0%, while 23.3% had no complications. Eighty per cent of patients were healed. During the median follow-up period of 10.5 months (0.5-36 months), 20.0% of the patients relapsed. These patients were treated with surgical excision, renewed of imiquimod treatment, or radiation or photodynamic therapy.

In Table 2 we summarize the available data from 16 male patients included in 16 case reports of extramammary Paget disease (8,16,26-39).

Table 2. Main characteristics and outcomes of the male patients with extramammary Paget disease

Demographics	No. patients/ Total (%)
Age, in years*	70 (57-82)
Nr of patients	16
Medical History	
Comorbidities	6/16 (37.5)
Onset of the disease, in years*	4 (0.2-20)
Major diameter of the lesion, in cm*	5 (1.5-9)
Symptoms	
<i>pruritus</i>	7/16 (41.2)
<i>erythematous plaque</i>	10/16 (43.8)
<i>pain</i>	3/16 (18.7)
<i>superficial ulcers</i>	1/16 (6.3)
<i>local hypopigmentation</i>	1/16 (6.3)
<i>indolent eczematous eruption</i>	1/16 (6.3)
<i>fever</i>	1/16 (6.3)
Local lymphadenopathy	0/16
Initial treatment applied	
<i>none</i>	7/16 (41.2)
<i>topical cream treatment</i>	6/16 (37.5)
<i>local excision</i>	3/16 (18.7)
<i>combination of treatments</i>	1/16 (6.3)
Location of the lesions	
<i>scrotum</i>	13/16 (81.3)
<i>penile shaft</i>	8/16 (50)
<i>perianal area</i>	4/16 (25)
<i>axilla</i>	1/16 (6.3)
<i>thorax</i>	1/16 (6.3)
Clinical features of imiquimod treatment	
Applied dose	
<i>3 times per week</i>	11/16 (68.8)
<i>daily</i>	6/16 (37.5)
Duration of treatment, in weeks*	16 (6-36)
Complications	
<i>erythema</i>	9/16 (56.3)
<i>none</i>	4/16 (25)
<i>skin erosion</i>	4/16 (25)
<i>pain</i>	4/16 (25)
<i>local irritation</i>	3/16 (18.7)
<i>flu like symptoms</i>	1/16 (6.3)
Outcomes	
Healing	14/16 (87.5)
Follow up, in months*	12 (5-24)
Relapse	2/16 (12.5)
Treatment of relapse	
<i>radiation therapy</i>	2/16 (12.5)
<i>photodynamic therapy</i>	1/16 (6.3)

Abbreviation: cm = centimeters, nr = number
* median (range).

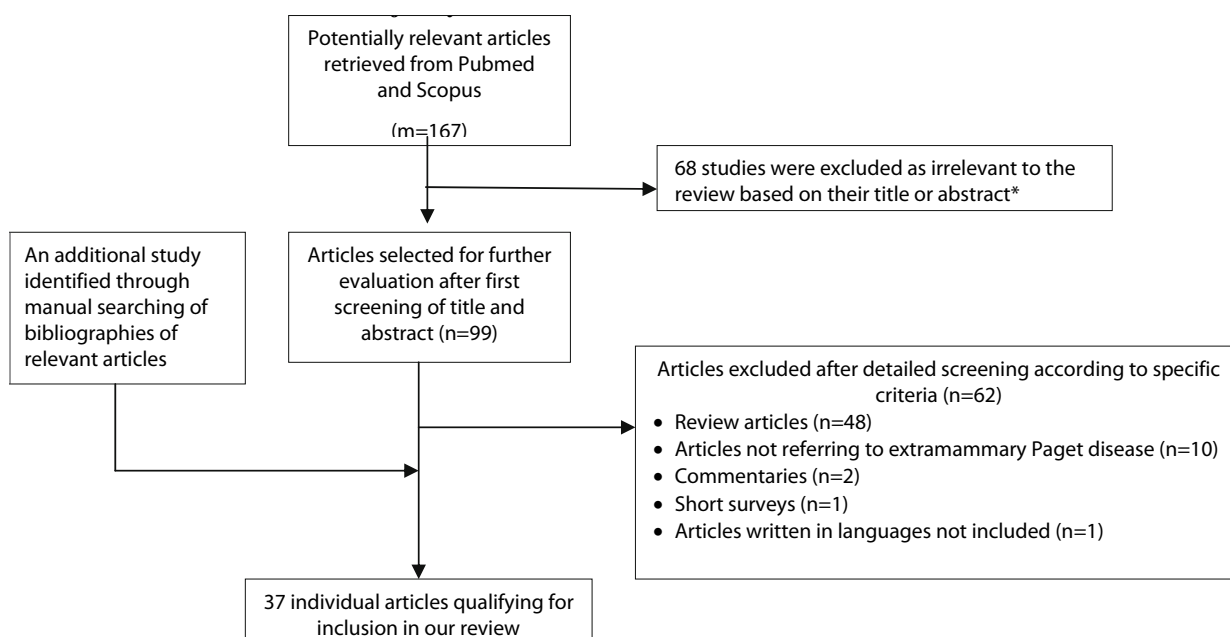


Figure 1. Flow chart of the selection process of articles eligible for inclusion in the review.

* The majority of studies were found in both databases

The median age of the male patients was 70, ranging from 57 to 82 years. Six out of 16 patients had comorbidities. The median onset of the disease was 4 years (ranging from 0.2 to 20 years), and the median major lesion diameter was 5 cm (1.5-9 cm). The main symptoms included pruritus (41.2%), erythematous plaque (43.8%), pain (18.7%), local hypopigmentation (6.3%), indolent eczematous eruption (6.3%), superficial ulcers (6.3%), and fever (6.3%). None of the patients had local lymphadenopathy. The main location of the disease was the scrotum in 81.3%, the penile shaft in 50.0%, perianal area in 25.0%, the thorax in 6.3%, and the axilla in 6.3%. The disease was initially treated with topical cream in 37.5%, a combination of treatment in 6.3%, and local excision in 18.7%, while 41.2% had no intervention. The application of imiquimod ranged from daily (37.5%) to 3 times per week (68.8%) and was given for an average of 16 weeks, ranging from 6-36 weeks depending on the symptoms and the complications. The most common complications after imiquimod treatment included pain in 25.0%, skin erosion in 25.0%, local irritation in 18.7%, erythema in 56.3%, and flu-like symptoms in 6.3% of the patients, while 25.0% had no complications. 87.5% of patients were healed. During the median follow-up period, which was 12 months (5-24 months), 12.5% of the patients relapsed. These patients were treated with surgical excision, radiation, or photodynamic therapy.

CASE SERIES

We also identified a single case series that included fourteen patients with extramammary Paget disease (40). The study included 14 patients with a mean age of 73 years (range: 58-91). The onset of the symptoms was 34.7 months on average. The majority of the patients (13 out of 14) presented with lesions located in the genital region. The mean size of the lesion was 6.7 cm (range: 2-15). 47.0% of the lesions had previously been treated. As first-line treatment, the topical use of imiquimod was applied in 8 out of 14 patients. The most frequent imiquimod dosage was 3 times weekly for at least 3 months. The mean duration of imiquimod treatment was 5.5 months (range: 2-12). Residual disease after treatment was present in 5 out of 14 patients.

DISCUSSION

There is limited data regarding the presentation of extramammary Paget disease and its possible management with local application of imiquimod cream.

The available evidence shows that its presentation varies in location, and mainly presents in the seventh decade of life. The median onset of the disease was 2 years in women and 4 years in men, a difference that can perhaps be attributed to more frequent screening of women for genital area diseases. The workup includes: physical examination, skin examination, lymph nodes palpation, PAP smear plus or minus

colposcopy, rectal examination, and breast examination. Mammogram, ultrasound, and colonoscopy are necessary in order to exclude mammary, genitourinary, or gastrointestinal cancer (41). The main symptoms are local and include pruritus, erythema, pain, burning, hypopigmentation (well-defined hypopigmented to pink plaque), and indolent eczematous eruption. Local lymphadenopathy was not found in patients with extramammary Paget disease (1-9,11,14,16-39,42). The differential diagnosis includes Bowen's disease, psoriasis, and dermatitis, which could delay the diagnosis (9,32). Patients usually have a history of topical use of corticosteroids, antibiotics, antifungals, and pimecrolimus 1% cream (11). It should be noted that punch biopsy is very significant for the diagnosis, as it can clarify whether there is any underlying malignancy (2,5,11,16-20,22,29,34-36,42). The histological findings include hyperkeratosis, parakeratosis, acanthosis, diffuse infiltration by cells with abundant pale cytoplasm, and vacuolated nuclei (Paget's cells) throughout the epidermis (43). Immunohistochemistry is positive for carcinoembryonic antigen (CEA), cytokeratin (CK7), cytokeratin (CK18), and epithelial membrane antigens, and negative for S-100 protein(44).

Local application of imiquimod (on the lesion and 1-2 cm around it) nightly or up to 2 or 3 times weekly for a median period of 4 months is suggested. Fusidic acid ointment could be used locally to loosen the small crusts (1,21). Various dosing regimens have been suggested to achieve histopathologic clearance (1-9,11,14,16,18,19,21-23,26-31,33-38), but maintenance treatment is clearly indicated. In our review, we tried to clarify the role of imiquimod in the partial or complete recovery in patients with extramammary Paget disease. The evidence from case reports and case series suggested that the majority of patients with extramammary Paget disease can be cured with imiquimod (80% of the women and 87.5% of the men). Complications are relatively common, but they are mainly local and include local irritation, erosion, and tenderness, and rarely flu like symptoms, nausea, and diarrhea only rarely (1-3,5,7,9,11,14,16,17,21-24,26-32,34-39,42). The management of complications includes temporarily terminating imiquimod use and local application of lidocaine 3% cream (11). Recurrence rate is up to 43%, and can usually be treated with wide local excision, radiation, or photodynamic therapy (40).

The major advantage of imiquimod is that it can be used in the treatment of elderly patients or in patients that are poor surgical candidates in general (14,25,26,30). As it can also offer good cosmetic results, it can be suggested to patients who are afraid

of or opt out of surgical management, as it can be applied locally(5,24).

CONCLUSION

Imiquimod could be an effective alternative conservative treatment option for extramammary Paget disease though the use would be off-label. The available evidence is currently limited to case reports and studies with different study designs and patients characteristics. More data regarding the dose, complications, and follow-up is necessary. Randomized controlled trials could determine the safety, dose related issues, and efficacy of the treatment, especially after long follow-up periods. It should be noted that continuous clinical monitoring following treatment of extramammary Paget disease is essential independently of the therapeutic options, in order to early diagnose possible recurrences. Gynaecologists, urologists, and dermatologists should be aware of the disease and the possible role of imiquimod in its management.

References

1. Hiraldo-Gamero A, Gomez-Moyano E, Segura-Palacios JM, Sanchez-Fajardo F, Sanz-Trelles A. Extramammary Paget disease treated with 5% imiquimod cream. *Actas Dermosifiliogr* 2011;102:554-6.
2. Tonguc E, Gungor T, Var T, Ozat M, Sahin I, Sirvan L. Treatment of recurrent vulvar Paget disease with imiquimod cream: a case report and review of the literature. *Arch Gynecol Obstet* 2011;283:97-101.
3. Cecchi R, Pavesi M, Bartoli L, Brunetti L, Rapicano V. Perineal extramammary Paget disease responsive to topical imiquimod. *J Dtsch Dermatol Ges* 2010;8:38-40.
4. Feldmeyer L, Kerl K, Kamarashev J, de Viragh P, French LE. Treatment of vulvar Paget disease with topical imiquimod: a case report and review of the literature. *J Dermatol Case Rep* 2011;5:42-6.
5. Hatch KD, Davis JR. Complete resolution of Paget disease of the vulva with imiquimod cream. *J Low Genit Tract Dis* 2008;12:90-4.
6. Sendagorta E, Herranz P, Feito M, Ramirez P, Floristan U, Feltes R, *et al.* Successful treatment of three cases of primary extramammary Paget's disease of the vulva with Imiquimod--proposal of a therapeutic schedule. *J Eur Acad Dermatol Venereol* 2010;24:490-2.
7. Anton C, Luiz AV, Carvalho FM, Baracat EC, Carvalho JP. Clinical treatment of vulvar Paget's disease: a case report. *Clinics (Sao Paulo)* 2011;66:1109-11.



8. Tanaka VD, Sanches JA, Torezan L, Niwa AB, Festa Neto C. Mammary and extramammary Paget's disease: a study of 14 cases and the associated therapeutic difficulties. *Clinics (Sao Paulo)* 2009;64:599-606.
9. Toledo F, Silvestre JF, Cuesta L, Ballester I, Latorre N, Monteagudo A. Sequential use with imiquimod and surgery in extramammary Paget's disease. *Dermatol Ther* 2012;25:82-5.
10. Bakalianou K, Salakos N, lavazzo C, Paltoglou G, Papadias K, Gregoriou O, *et al.* Paget's disease of the vulva. A ten-year experience. *Eur J Gynaecol Oncol* 2008;29:368-70.
11. Wang LC, Blanchard A, Judge DE, Lorincz AA, Medenica MM, Busbey S. Successful treatment of recurrent extramammary Paget's disease of the vulva with topical imiquimod 5% cream. *J Am Acad Dermatol* 2003;49:769-72.
12. Brightman L, Warycha M, Anolik R, Geronemus R. Do lasers or topicals really work for nonmelanoma skin cancers? *Semin Cutan Med Surg* 2011;30:14-25.
13. Funaro D, Krasny M, Lam C, Desy D, Sauthier P, Bouffard D. Extramammary Paget disease: epidemiology and association to cancer in a Quebec-based population. *J Low Genit Tract Dis* 2013;17:167-74.
14. Wagner G, Heine M, Sachse MM. Extramammary Paget disease: successful therapy with imiquimod 5% cream. *Hautarzt* 2012;63:42-6.
15. lavazzo C, Pitsouni E, Athanasiou S, Falagas ME. Imiquimod for treatment of vulvar and vaginal intraepithelial neoplasia. *Int J Gynaecol Obstet* 2008;101:3-10.
16. Ho SA, Aw DC. Extramammary Paget's disease treated with topical imiquimod 5% cream. *Dermatol Ther* 2010;23:423-7.
17. Baiocchi G, Begnami MD, Fukazawa EM, Surima WS, Badigliani-Filho L, Costa FD, *et al.* Conservative management of extramammary paget disease with imiquimod. *J Low Genit Tract Dis* 2012;16:59-63.
18. Bertozzi S, Londero AP, Fruscalzo A, Marchesoni D, Lelle RJ. Paget disease of the vulva: resolution after local treatment with imiquimod—report of a case and review of the literature. *Gynakol Geburtshilfliche Rundsch* 2009;49:326-30.
19. Challenor R, Hughes G, Fitton AR. Multidisciplinary treatment of vulval extramammary Paget's disease to maintain sexual function: an imiquimod success story. *J Obstet Gynaecol* 2009;29:252-4.
20. Cooper JC, Hew KE, Audlin KM, Im DD, Matsuo K. Synchronous of breast and vulvar Paget's disease: a case report. *Eur J Gynaecol Oncol* 2012;33:534-6.
21. Dias Coelho J, Vale E, Viana I, Martins O. Treatment of primary extramammary Paget's disease of the perineum with topical imiquimod 5% cream. *Eur J Dermatol* 2010;20:532-3.
22. Geisler JP, Manahan KJ. Imiquimod in vulvar Paget's disease: a case report. *J Reprod Med* 2008;53:811-2.
23. Madnani NA, Bhalerao-Gandhi A, Khan KJ. Vulvar puritus for one year. *Dermatol Online J* 2010;16:10.
24. Misery L. Treatment of genital Paget's skin disease with topical imiquimod: severe adverse events. *J Dermatolog Treat* 2007;18:191-2.
25. Mirer E, El Sayed F, Ammoury A, Lamant L, Messer L, Bazex J. Treatment of mammary and extramammary Paget's skin disease with topical imiquimod. *J Dermatolog Treat* 2006;17:167-71.
26. Badgwell C, Rosen T. Treatment of limited extent extramammary Paget's disease with 5 percent imiquimod cream. *Dermatol Online J* 2006;12:22.
27. Berman B, Spencer J, Villa A, Poochareon V, Elgart G. Successful treatment of extramammary Paget's disease of the scrotum with imiquimod 5% cream. *Clin Exp Dermatol* 2003;28 Suppl 1:36-8.
28. Cohen PR, Schulze KE, Tschien JA, Hetherington GW, Nelson BR. Treatment of extramammary Paget disease with topical imiquimod cream: case report and literature review. *South Med J* 2006;99:396-402.
29. Gil-Bistes D, Kluger N, Rigau V, Guillot B. Successful treatment of recurrent extramammary Paget's disease of the penis and scrotum with imiquimod 5% cream. *Presse Med* 2011;40:1205-6.
30. Green JS, Burkemper NM, Fosko SW. Failure of extensive extramammary Paget disease of the inguinal area to clear with imiquimod cream, 5%: possible progression to invasive disease during therapy. *Arch Dermatol* 2011;147:704-8.
31. Hartman R, Chu J, Patel R, Meehan S, Stein JA. Extramammary Paget disease. *Dermatol Online J* 2011;17:4.
32. Jim On SC, Izumi AK. Extramammary Paget disease: failure to respond to topical imiquimod 5%. *J Am Acad Dermatol* 2011;65:656-7.
33. Olazaran-Medrano Z, Trevino-Gonzalez JJ, Salas-Alanis JC, Lemus-Arias JA. [Treatment with imiquimod and surgical excision of a patient with extramammary Paget's disease. Case report] [Ar-

- ticle in Spanish]. *Rev Med Inst Mex Seguro Soc* 2010;48:83-6.
34. Qian Z, Zeitoun NC, Shieh S, Helm T, Oseroff AR. Successful treatment of extramammary Paget's disease with imiquimod. *J Drugs Dermatol* 2003;2:73-6.
 35. Vereecken P, Awada A, Ghanem G, Marques da Costa C, Larsimont P, Simoens C, *et al.* A therapeutic approach to perianal extramammary Paget's disease: topical imiquimod can be useful to prevent or defer surgery. *Med Sci Monit* 2007;13:CS75-7.
 36. Ye JN, Rhew DC, Yip F, Edelstein L. Extramammary Paget's disease resistant to surgery and imiquimod monotherapy but responsive to imiquimod combination topical chemotherapy with 5-fluorouracil and retinoic acid: a case report. *Cutis* 2006;77:245-50.
 37. Yeh MH, Hu SL. Treatment of double ectopic extramammary Paget's disease of bilateral chest with imiquimod 5% cream. *J Eur Acad Dermatol Venereol* 2007;21:997-9.
 38. Yoo KH, Seo SJ, Park J, Han TY, Li K, Song KY, *et al.* Extramammary Paget's disease of the penis with features of Bowen's disease. *Clin Exp Dermatol* 2009;34:e999-1000.
 39. Zampogna JC, Flowers FP, Roth WI, Hassenein AM. Treatment of primary limited cutaneous extramammary Paget's disease with topical imiquimod monotherapy: two case reports. *J Am Acad Dermatol* 2002;47(S229-35).
 40. Pang J, Assaad D, Breen D, Fialkov J, Antonyshyn O, Balogh J, *et al.* Extramammary Paget disease: review of patients seen in a non-melanoma skin cancer clinic. *Curr Oncol* 2010;17:43-5.
 41. Frangioni JV. New technologies for human cancer imaging. *J Clin Oncol* 2008;26:4012-21.
 42. Matin RN, Gibbon K, Rizvi H, Harwood CA, Cerio R. Cutaneous mucinous carcinoma arising in extramammary Paget disease of the perineum. *Am J Dermatopathol* 2011;33:705-9.
 43. Kohler S, Rouse RV, Smoller BR. The differential diagnosis of pagetoid cells in the epidermis. *Mod Pathol* 1998;11:79-92.
 44. Wang EC, Kwah YC, Tan WP, Lee JS, Tan SH. Extramammary Paget disease: Immunohistochemistry is critical to distinguish potential mimickers. *Dermatol Online J* 2012;18:4.
 45. Bae JM, Choi YY, Kim H, Oh BH, Roh MR, Nam K, Chung KY. Mohs micrographic surgery for extramammary Paget disease: a pooled analysis of individual patient data. *J Am Acad Dermatol* 2013;68:632-7.
 46. Zampogna JC, Flowers FP, Roth WI, Hassenein AM. Treatment of primary limited cutaneous extramammary Paget's disease with topical imiquimod monotherapy: two case reports. *J Am Acad Dermatol* 2002;47(4 Suppl):S229-35.

