

## WALDENSTRÖM'S MACROGLOBULINEMIA AS A DIAGNOSTIC CHALLENGE: CASE REPORT

Ivan Budimir<sup>1</sup>, Marko Nikolić<sup>1</sup>, Mateja Sabol Pušić<sup>2</sup>, Davor Hrabar<sup>1</sup>, Neven Ljubičić<sup>1</sup>, Marko Duvnjak<sup>1</sup>, Vladimir Supanc<sup>1</sup>, Ivana Nikolac<sup>3</sup>, Nenad Babić<sup>4</sup> and Marija Šokčević<sup>5</sup>

<sup>1</sup>Department of Gastroenterology and Hepatology, Clinical Department of Medicine, Sestre milosrdnice University Hospital Center, Zagreb; <sup>2</sup>Department of Cardiology, Čakovec County Hospital, Čakovec; <sup>3</sup>Institute of Emergency Medicine of the City of Zagreb; <sup>4</sup>Clinical Department of Radiology, <sup>5</sup>Department of Cytology, Sestre milosrdnice University Hospital Center, Zagreb, Croatia

**SUMMARY** – Waldenström's macroglobulinemia is a distinct clinicopathologic entity defined as a B-cell neoplasm characterized by lymphoplasmacytic infiltrate in the bone marrow, with an associated immunoglobulin (Ig) M paraprotein. Clinical manifestations are due to deposition of IgM in the liver, spleen, and/or lymph nodes, so it presents with anemia, hyperviscosity, lymphadenopathy, hepatomegaly, splenomegaly and neurologic symptoms. The main diagnostic criteria are a typical peak on serum protein electrophoresis and malignant cells in bone marrow biopsy samples. There is no standard therapy for the treatment of symptomatic Waldenström's macroglobulinemia and no agents have been specifically approved for this disease, but initial treatment usually starts with the monoclonal anti-CD20 antibody rituximab, either alone or in combination with other agents, rather than chemotherapy alone. This article confirms that, despite the existence of more modern imaging methods, ultrasonography still has a significant diagnostic role.

**Key words:** *Waldenström macroglobulinemia; B-lymphocytes; Immunoglobulin M; Antibodies, monoclonal; Ultrasonography*

### Introduction

Waldenström's macroglobulinemia is a rare malignant monoclonal gammopathy characterized by the production of excess IgM monoclonal protein. It presents with symptoms related to the infiltration of the hematopoietic tissues or the effects of monoclonal IgM in the blood. No definite etiology exists for Waldenström's macroglobulinemia, but environmental, familial, genetic, and viral factors have been reported. We present a case of a patient who was diagnosed with a solitary liver lesion by abdominal ultrasonography (US) and had undergone further diagnos-

tic imaging test, and later blood test and biopsy until the diagnosis of Waldenström's macroglobulinemia was set<sup>1-3</sup>.

### Case Report

A 61-year-old female patient first presented to our department in May 2011 with a history of nonspecific symptoms of weakness, sweating, weight loss, and pain in the upper abdomen. Blood tests revealed mild anemia, elevated erythrocyte sedimentation rate, normal liver function tests, and abdominal US showed a hypoechoic lesion measuring 12x8 cm in the right liver lobe without change of the US structure (Fig.1 a, b). The patient underwent further diagnostic tests that eliminated infectious, autoimmune and systemic causes of the liver lesion. Besides liver lesion, computed tomography (CT) showed a couple

Correspondence to: *Ivan Budimir, MD*, Department of Gastroenterology and Hepatology, Sestre milosrdnice University Hospital, Vinogradska c. 29, HR-10000 Zagreb, Croatia  
E-mail: [ivan.budimir.zg@gmail.com](mailto:ivan.budimir.zg@gmail.com)

Received December 3, 2012, accepted April 15, 2013

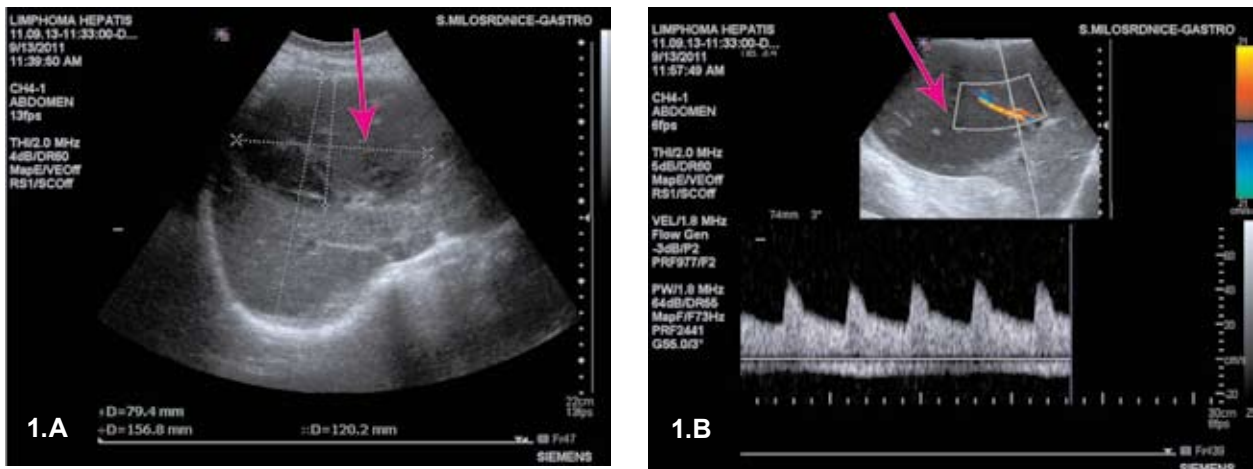


Fig. 1. Abdominal ultrasound showing; A) a hypoechoic lesion 12x8 cm in the right liver lobe; B) without change of ultrasound structure.

of enlarged lymph nodes retrocrurally (Fig. 2), but the etiology of liver lesion remained unknown, possible liver steatosis. Then, magnetic resonance imaging (MRI) was performed, indicating that the lesion could be due to perfusion problems (Fig. 3). Because of the unsolved etiology, the patient was admitted to the hospital in September 2011. In the hospital, the patient underwent US-guided cytologic biopsy of the liver lesion and serum protein electrophoresis was also performed. According to the cytology report, abundant smears showed a monotonous picture of numerous lymphoplasmacytes with frequent proplasma and plasma cells and some mastocytes, concluding that

the finding was compatible with the diagnosis of non-Hodgkin's lymphoma of the lymphoplasmacytic type. Serum protein electrophoresis results were as follows: total protein 101 g/L, albumin 27.9 g/L, alpha1-globulin 2.7 g/L, alpha2-globulin 6.2 g/L, beta-globulin 54.7 g/L, gamma-globulin 8.5 g/L, M-protein 47.2 g/L, IgG 4.6, IgA 0.90, IgM 66.8. Bone marrow aspiration biopsy was also performed to demonstrate a lymphoproliferative process with 25% of lymphocytes and 2% of plasma cells. In the blood smear, lymphocytes accounted for 46% of cells and there were 7% of plasma cells. Red blood cells adhered together in the rouleau formations due to the high blood protein

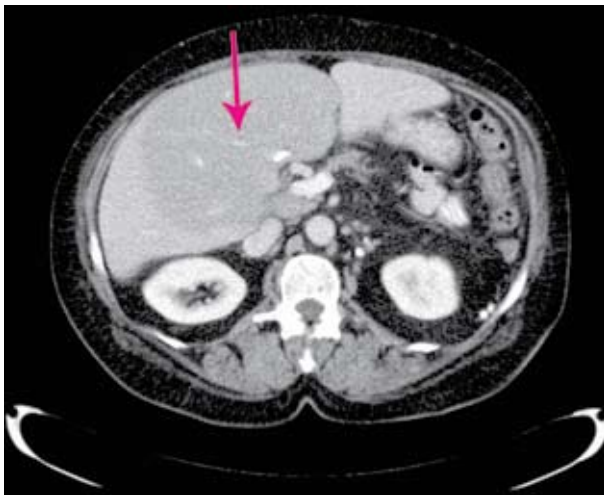

Fig. 2. Computed tomography of the abdomen 70 seconds after intravenous contrast application. Transverse reconstruction – centrobilar expansive hypodense liver change.

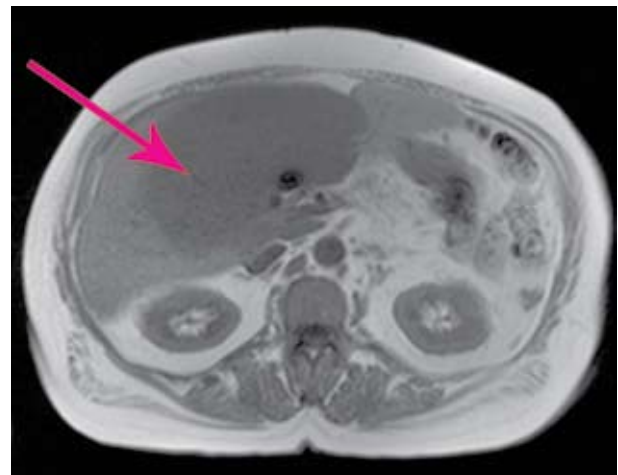
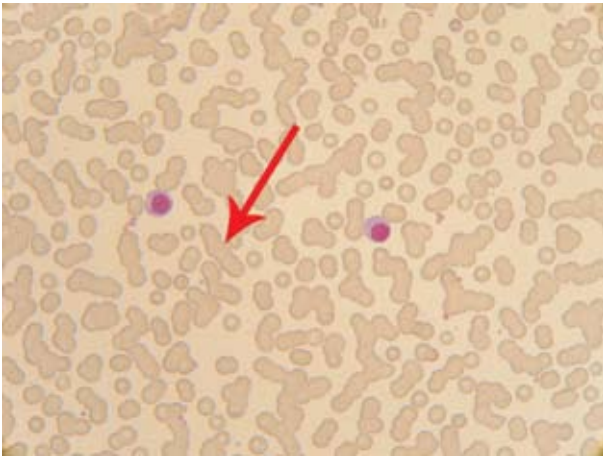


Fig. 3. Nuclear magnetic resonance, 2-weighted image: transverse layers showing centrobilar expansive liver lesion.



*Fig. 4. Peripheral blood smear: MGG staining, magnification x1000: one proplasma and one plasma cell in peripheral blood. Erythrocytes are stucked together in rouleaux formations due to high protein content in the blood.*

content (Fig. 4). Then, the diagnosis of Waldenström's macroglobulinemia was set.

Chest CT excluded lymphoplasmacytoma sites in other solid organs.

Therapy with fludarabine was administered, with good patient response. She was released for home care in good condition and planned for the next cycle of chemotherapy in four weeks. However, she was readmitted earlier, through emergency unit because of epistaxis, retinal bleeding, and worsening of her general condition. Two plasmapheresis sessions were done as well as albumin correction, and she received crystalloid solutions, three doses of fresh frozen plasma and three doses of irradiated red blood cell concentrates. With these interventions, her condition improved with serum protein reduction from 83 g/L to 75 g/L, and M-peak reduction from 47 g/L to 28.4 g/L. She also underwent the second cycle of chemotherapy with fludarabine and rituximab, and was discharged for home care in good condition.

## Discussion

Waldenström's macroglobulinemia is a rare disease with an incidence of approximately three *per* million people *per* year in the United States and the median

age at diagnosis is 64 years<sup>4</sup>. Although it is considered to be a sporadic disease, familial predisposition is present in up to 20 percent of the cases<sup>5</sup>.

The disease presents itself with diversity of symptoms, which are attributable to tumor infiltration of lymphoid tissues and bone marrow, circulating IgM, IgM tissue deposition and autoantibody activity of IgM. Most patients with Waldenström's macroglobulinemia present with nonspecific constitutional symptoms like weakness, fatigue, weight loss, but also hepatomegaly, splenomegaly, lymphadenopathy, bleeding, and symptoms due to hyperviscosity such as blurring or loss of vision, headache, vertigo, nystagmus, tinnitus, diplopia or ataxia<sup>6,7</sup>. Besides clinical presentation, reaching the diagnosis of this condition requires a number of tests.

Anemia is found in about 40% of cases, and other common findings are lymphocytosis and monocytosis. However, the key criteria are the presence of an IgM monoclonal paraprotein on serum protein electrophoresis and 10% or more of the bone marrow biopsy samples showing infiltration by small lymphocytes with plasmacytoid or plasma cell differentiation. This infiltrate should express a typical immunophenotype (e.g., surface IgM+, CD5+/-, CD10-, CD19+, CD20+, CD22+, CD23-, CD25+, CD27+, FMC7+, CD103-, CD138-)<sup>8</sup>.

Imaging methods like US, CT and MRI are also very important, mostly to evaluate the extension of the disease, or as in our case, to set suspicion of the disease. Focal liver lesions are often detected on routine US, but sometimes, as in the case we report, require extensive investigations for an accurate diagnosis. Differential diagnosis of an US detected hypoechoic liver lesion is variable, from liver steatosis either in terms of alcoholic or non alcoholic fatty liver disease, to benign tumors or malignant primary or metastatic liver tumors<sup>9</sup>. The treatment of Waldenström's macroglobulinemia is complex. The decision on whether or not to start treatment is based on the patient's clinical condition. For patients with minimal symptoms, the treatment of first choice is rituximab because of its low toxicity and good response rates. The combination of rituximab and chemotherapy is a preferred treatment option for patients with severe symptoms related to Waldenström's macroglobulinemia. For the hyperviscosity syndrome, the only treatment option is removal

of IgM from the circulation *via* plasmapheresis. There are also some new agents that are still under study, e.g., perifosine, alemtuzumab, imatinib mesylate, everolimus, and sildenafil<sup>10-12</sup>.

## References

1. FONSECA R, HAYMAN S. Waldenström macroglobulinemia. *Br J Haematol* 2007;138(6):700-20.
2. DIMOPOULOS MA, KYLE RA, ANAGNOSTOPOULOS A, TREON SP. Diagnosis and management of Waldenström's macroglobulinemia. *J Clin Oncol* 2005;23(7):1564-77.
3. ANSELL SM, KYLE RA, REEDER CB, *et al.* Diagnosis and management of Waldenström macroglobulinemia: Mayo stratification of macroglobulinemia and risk-adapted therapy (mSMART) guidelines. *Mayo Clin Proc* 2010;85(9):824-33.
4. GROVES FD, TRAVIS LB, DEVESA SS, RIES LA, FRAUMENI JF. Waldenström's macroglobulinemia: incidence patterns in the United States, 1988-1994. *Cancer* 1998;82(6):1078-81.
5. KRISTINSSON SY, BJÖRKHOLM M, GOLDIN LR, McMASTER ML, TURESSON I, LANDGREN O. Risk of lymphoproliferative disorders among first-degree relatives of lymphoplasmacytic lymphoma/Waldenström macroglobulinemia patients: a population-based study in Sweden. *Blood* 2008;112(8):3052-6.
6. VIJAY A, GERTZ MA. Waldenström macroglobulinemia. *Blood* 2007;109(12):5096-103.
7. ŽUPANIĆ-KRMEK D, LANG N, JURČIĆ D, LJUBIĆ N, BILIĆ A. Analysis of the influence of various factors on anemia in patients with lymphoid malignancies. *Acta Clin Croat* 2011;50:495-500.
8. OWEN RG, TREON SP, AI-KATIB A, *et al.* Clinicopathological definition of Waldenström's macroglobulinemia: consensus panel recommendations from the Second International Workshop on Waldenström's macroglobulinemia. *Semin Oncol* 2003;30(2):110-5.
9. TERKIVATAN T, ZONDERVAN PE, LANJOUW E, de RAVE S, IJZERMANS JN, de MAN RA. Focal nodular hyperplasia: findings at state-of-the-art MR imaging, US, CT, and pathologic analysis. *Radiographics* 2004;24(1):3-17.
10. GHOBRIAL IM, GERTZ M, LAPLANT B, *et al.* Phase II trial of the oral mammalian target of rapamycin inhibitor everolimus in relapsed or refractory Waldenström macroglobulinemia. *J Clin Oncol* 2010;28:1408-14.
11. GHOBRIAL IM, ROCCARO A, HONG F, *et al.* Clinical and translational studies of a phase II trial of the novel oral Akt inhibitor perifosine in relapsed or relapsed/refractory Waldenström's macroglobulinemia. *Clin Cancer Res* 2010;16:1033-41.
12. TREON SP, SOUMERAI JD, HUNTER ZR, *et al.* Long-term follow-up of symptomatic patients with lymphoplasmacytic lymphoma/Waldenström macroglobulinemia treated with the anti-CD52 monoclonal antibody alemtuzumab. *Blood* 2011;118:276-81.

## Sažetak

### WALDENSTRÖMOVA MAKROGLOBULINEMIJA KAO DIJAGNOSTIČKI PROBLEM: CASE REPORT

I. Budimir, M. Nikolić, M. Sabol Pušić, D. Hrabar, N. Ljubičić, M. Duvnjak, V. Supanc, I. Nikolac, N. Babić i M. Šokčević

Waldenströmova makroglobulinemija je specifičan kliničkopatološki entitet definiran kao B-stanična neoplazma obilježena limfoplazmatskim infiltratima u koštanoj srži udruženim s paraproteinom imunoglobulinom (Ig) M. Kliničke manifestacije nastaju kao posljedica taloženja IgM u jetri, slezeni i/ili limfnim čvorovima, tako da se bolest manifestira anemijom, hiperviskozitetom, limfadenopatijom, hepatomegalijom, splenomegalijom i neurološkim simptomima. Glavni dijagnostički kriteriji su tipični vršak u elektroforezi serumskih proteina te maligne stanice u uzorcima biopsije koštane srži. Ne postoji standardna terapija za liječenje simptomske Waldenströmove makroglobulinemije i nema lijekova specifično odobrenih za ovu bolest, no liječenje najčešće ne započinje kemoterapijom, nego monoklonskim anti-CD 20 antitijelom rituksimabom kao monoterapijom ili u kombinaciji s drugim lijekovima. Ovaj članak potvrđuje da unatoč postojanju modernih metoda prikazivanja ultrazvuk i dalje ima značajnu dijagnostičku ulogu.

Ključne riječi: *Waldenströmova makroglobulinemija; B-limfociti; Imunoglobulin M; Antitijela, monoklonska; Ultrazvuk*