

TACHYCARDIA IN A NEWBORN WITH ENTEROVIRUS INFECTION

Lidija Banjac¹, Draško Nikčević¹, Danijela Vujošević², Janja Raonić¹ and Goran Banjac¹

¹Institute for Children's Diseases, Clinical Center of Montenegro; ²Center for Medical Microbiology, Institute of Public Health, Podgorica, Montenegro

SUMMARY – Enterovirus infections are common in the neonatal period. Newborns are at a higher risk of severe disease including meningoencephalitis, sepsis syndrome, cardiovascular collapse, or hepatitis. The mechanism of heart failure in patients with enterovirus infection remains unknown. Early diagnosis may help clinicians predict complications in those infants initially presenting with severe disease. An 11-day-old male newborn was admitted to our neonatal intensive care unit because of tachycardia and crises of cyanosis. His elder brother had febrile illness. The newborn was cyanotic, in respiratory distress, with tachycardia, low blood pressure and prolonged capillary refilling time. Limb pulse oximeter was around 85%. During the first day of hospitalization, the newborn had one febrile episode. Laboratory data: elevated transaminases, markers of inflammation negative, all bacterial cultures negative. Enterovirus RNA was detected in blood sample. Other blood findings were without significant abnormalities. Electrocardiogram showed tachycardia, with narrow QRS complexes (atrial tachycardia) and heart rate up to 280/min. In order to convert the rhythm, the patient was administered adenosine and amiodarone. In the further course of hospitalization, the patient was in good general condition, eucardiac and eupneic. Newborns with tachycardia and a family history of febrile illness should be suspected to have enterovirus infection. Enterovirus infection is a highly contagious and potentially life-threatening infection if not detected early. The use of sensitive molecular-based amplification methods offers potential benefits for early diagnosis and timely treatment.

Key words: *Enterovirus infection; Tachycardia; Infant, newborn*

Introduction

Enteroviruses are RNA viruses from the Picornaviridae family. Enteroviruses cause disorders with a wide range of clinical manifestations, including cutaneous, visceral, and neurological diseases¹⁻³. Enterovirus infections are common in the neonatal period⁴. The presentation and prognosis of enterovirus infections differ in many aspects between the neonate and the older child or adult. Approximately 75% of cases of neonatal enteroviral disease have a benign outcome, with diagnosis and symptomatic treatment

in non-intensive care unit settings. For the remainder of patients, more serious consequences can result from systemic enteroviral infection, including meningoencephalitis, sepsis syndrome, cardiovascular collapse, or hepatitis. The latter two organ-specific complications carry high mortality rates^{1,5,6}. Infants younger than 10 days are at a higher risk of severe disease because of their relative inability to mount a significant immune response and their lack of serotype-specific maternal antibody⁷. The mechanism of heart failure in patients with enterovirus infection remains unknown. Norepinephrine cardiotoxicity may play a role in the pathogenesis of heart failure in enterovirus infection. Comparison of heart failure in children with enterovirus rhombencephalitis and cats with norepinephrine cardiotoxicity pointed to this conclusion^{2,6}. Autopsy

Correspondence to: Lidija Banjac, MD, Djoka Miraševića M1 53/7, Podgorica, Montenegro
E-mail: drbanjac@t-com.me

Received February 27, 2013, accepted July 1, 2013

findings in children with enteroviral infection died from progressive cardiorespiratory failure indicate that circulatory dysfunction was of neurogenic origin, but it was not caused by myocarditis⁶. Early diagnosis may help clinicians predict complications in those infants initially presenting with severe disease. The specific diagnosis is best confirmed by identification of enterovirus from clinical samples by nucleic acid amplification or viral culture⁴.

Case Report

An 11-day-old male newborn was admitted to our neonatal intensive care unit because of tachycardia and crises of cyanosis. He was born *via* normal vaginal delivery at 38 weeks of gestation, with birth weight of 3400 g and Apgar score of 10 at 1 minute. His mother was a 25-year-old multigravida in good health, without any significant problem. His elder brother, aged

5, had febrile illness. His maternal and family history was unremarkable. There was no family history of cardiac disease either. The newborn had smaller portions one day before admission to the hospital. There were no other significant problems. He had no other medical visit after birth. On the day of admission, the patient was first examined at primary health center, and because of tachycardia he was referred to a general hospital. Tachycardia persistence and appearance of cyanosis crises were the reasons for referring the patient to a tertiary neonatal center. At admission, he was alert but appeared pale and cyanotic with mottled skin, in respiratory distress, with respiratory rate of 76/min and subcostal retraction. His pulse rate was 230-266/min, accompanied by low blood pressure (32/18/27 mm Hg) and prolonged capillary refilling time. Limb pulse oximetry was around 85%. Tachycardia without any cardiac murmur was found on cardiac examination. His liver edge was palpable 2-3

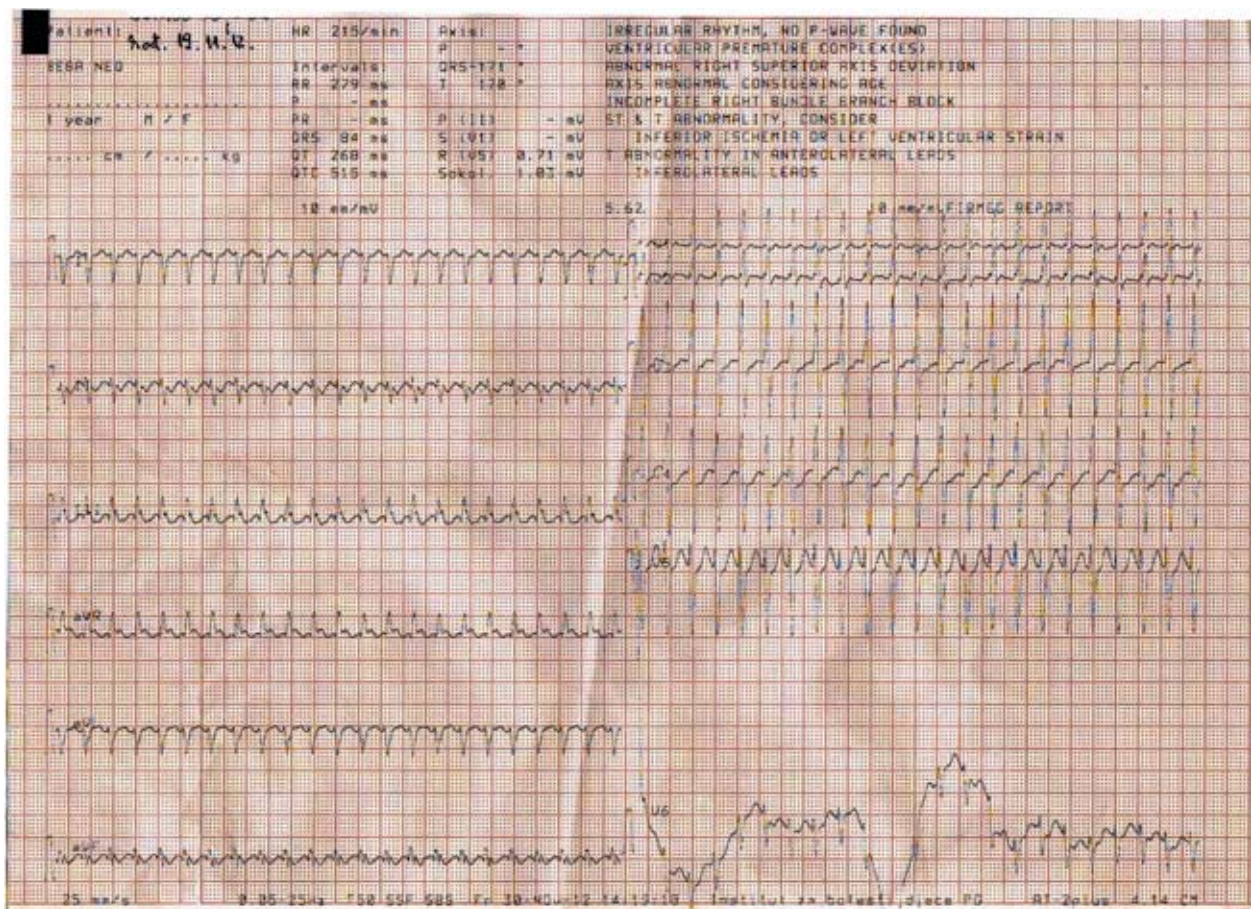


Fig. 1. Electrocardiogram: neonatal atrial tachycardia.

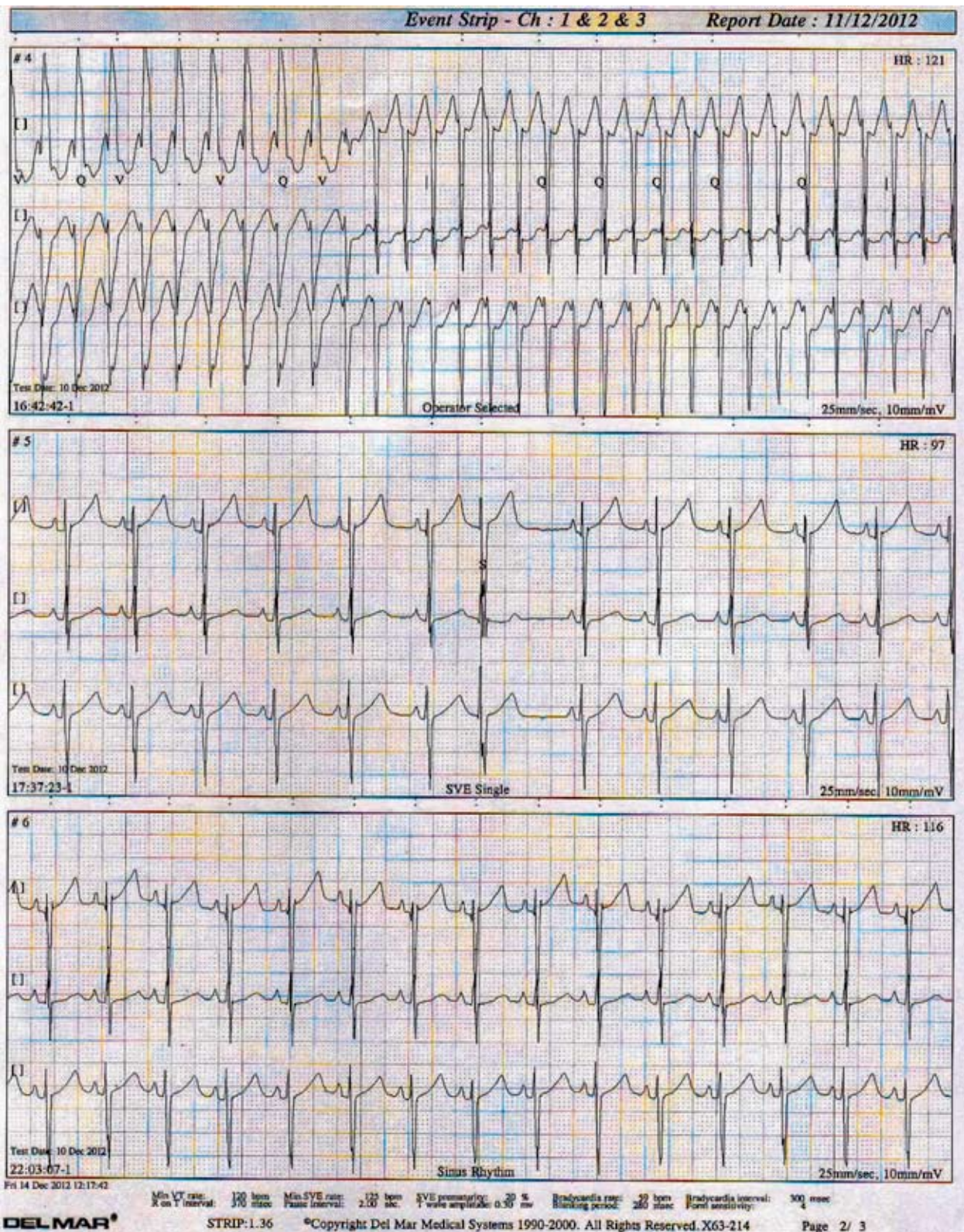


Fig. 2. Holter ECG report summary during hospitalization.

cm below the costal margin, with no splenomegaly. Urine was not obtained on the placed urinary catheter. During the first day of hospital stay, the patient had one febrile episode. Initial laboratory data were as follows: hemoglobin 14.5 g/dL, white blood count 20.400/mm³ with 10.9 (53.4%) neutrophil and 7.39 (36.2%) lymphocyte. Acid-base status: uncorrected metabolic acidosis with hypoxemia (pH 7.23 BE -12.4 mmol/L, pO₂ 4.44 kPa, pCO₂ 4.39 kPa, HCO₃ 13.7 mmol/L), elevated transaminases: AST 97U/L, ALT 219 U/L. Other blood findings were without significant abnormalities. Markers of inflammation were negative: C-reactive protein 0.5 mg/L, procalcitonin 0.11 ng/mL. All bacterial cultures were negative. Report of viral analyses for TORCH diseases was negative. Enterovirus RNA was detected in blood sample. Initial chest radiography revealed cardiac enlargement with increased pulmonary vascular markings. Electrocardiogram (ECG) showed tachycardia with narrow QRS complexes, with a heart rate up to 280/min (Fig. 1). Urgent echocardiogram showed structurally normal heart without anomalies. The left ventricle was of normal size, with substantially lowered ejection fractions. Intravenous infusion (i.v.) of 5% glucose, antibiotic and antiviral (acyclovir) treatment was initiated. In order to convert the rhythm, the patient was administered fast i.v. bolus of adenosine. The expected response was not obtained. Further on, amiodarone was administered first in boluses, then by slow i.v. infusion. One hour after treatment, conversion to sinus rhythm was started, a satisfactory heart rate (to 130/min) appeared, oxygen saturation and arterial blood pressure improved, so the newborn was less dyspneic, had better skin color, started to urinate, and became less anxious. After i.v. infusion of amiodarone, the patient was treated with oral amiodarone and oral beta-blockers (propranolol). Holter ECG Report Summary during hospitalization recorded sinus rhythm at average frequency of 117/min. There were 4 episodes of atrial tachycardia, maximum frequency of up to 280/min (Fig. 2). In the further course of hospitalization, the patient was in good general condition, eucardiac, eupneic, and with regular laboratory findings (transaminases were within the normal range). Holter Report Summary at discharge also recorded several episodes of atrial tachycardia. The infant was discharged from the hospital in stable condition on

33rd day of life, with oral therapy (propranolol and amiodarone) at a maintenance dose. Later follow up revealed that the infant was eucardiac without episodes of atrial tachycardia. He showed satisfactory progress in physical growth.

Discussion

In the present report, we describe an unusual case of enterovirus infection in a newborn. In this patient, enterovirus infection with resistant atrial tachycardia was diagnosed, based on the results of physical examination, presence of enterovirus RNA in blood, and ECG results. Clinical features were complicated by circulatory dysfunction and peripheral hypoperfusion. The child subsequently recovered well with symptomatic treatment, including intravenous administration of acyclovir, adenosine, and amiodarone. Significant improvement after pharmacological rhythm conversion and ECG findings probably excluded viral myocarditis as a possible cause of tachycardia. There is histologic evidence that there is no myocarditis underlying the pathogenesis of tachycardia in enterovirus infection and that it has a neurogenic origin. Enterovirus predilection for specific neurons is also known^{3,8,9}. Subsequent studies will concentrate on the answers if high catecholamine concentrations may play a role in the pathogenesis of tachycardia in enterovirus infection. Any newborn with tachycardia should be suspected to have enterovirus infection, particularly in those cases where other family members have febrile illness. Enterovirus is a highly contagious and potentially life-threatening infection if not detected early¹⁰. Early diagnosis leads to more prompt and definitive treatment of neonates with severe enterovirus infection. The use of sensitive molecular-based amplification methods offers potential benefits for early diagnosis and timely treatment.

References

1. HYYPIA T, HOVI T, KNOWLES NJ, STANWAY G. Classification of enteroviruses based on molecular and biological properties. *J Gen Virol* 1997;78:1-11.
2. SOLOMON T, LEWTHWAITE P, PERERA D, CARDOSA MJ, McMINN P, OOI MH. Virology, epidemiology, pathogenesis, and control of enterovirus 71. *Lancet Infect Dis* 2010;10:778-90.

3. WONG KT, LUM LC, LAM SK. Enterovirus 71 infection and neurologic complications. *N Engl J Med* 2000;342:356-8.
4. HAWKES MT, VAUDRY W. Nonpolio enterovirus infection in the neonate and young infant. *Paediatr Child Health* 2005;10(7):383-8.
5. CATLIN EA, WARREN HS, SHAILAM R, LAHOUD-RAHME M, LEW M. Case 19-2012 – A premature newborn boy with respiratory distress. *N Engl J Med* 2012;366:2409-19.
6. FU YC, CHI CS, LIN NN, *et al.* Comparison of heart failure in children with enterovirus 71 rhombencephalitis and cats with norepinephrine cardiotoxicity. *Pediatr Cardiol* 2006;27:577-84.
7. ZAOUTIS T, KLEIN JD. Enterovirus infections. *Pediatr Rev* 1998;19(6):183-91.
8. JIANG M, WEI D, OU WL, LI KX, LUO DZ, LI YQ, CHEN E, NONG GM. Autopsy findings in children with hand, foot, and mouth disease. *N Engl J Med* 2012;367:91-2.
9. SCHMIDT N, LENNETTE E, HO H. An apparently new enterovirus isolated from patients with disease of the central nervous system. *J Infect Dis* 1974;129:304-9.
10. CHUA KB, KASRI AR. Hand, foot and mouth disease due to enterovirus 71 in Malaysia. *Virol Sin* 2011;26(4):221-8.

Sažetak

TAHIKARDIJA U NOVOROĐENČETA S ENTEROVIRUSNOM INFEKCIJOM

L. Banjac, D. Nikčević, D. Vujošević, J. Raonić i G. Banjac

Enterovirusne infekcije su uobičajene u neonatalnom razdoblju. Novorođenčad su pod većim rizikom za teške oblike bolesti, uključujući meningoencefalitis, sindrom sepse, kardiovaskularni kolaps ili hepatitis. Mehanizam zatajenja srca u bolesnika s enterovirusnim infekcijama ostaje nepoznat. Rana dijagnoza može pomoći kliničarima da predvide komplikacije na početku u dojenčadi s teškom bolešću. Muško novorođenče staro 11 dana primljeno je u našu jedinicu intenzivne neonatalne skrbi zbog tahikardije i krize cijanoze. Njegov stariji brat imao je febrilnu bolest. Novorođenče je bilo cijanotično, u respiracijskom distresu, uz tahikardiju, nizak krvni tlak i produženo kapilarno punjenje. Pulsna oksimetrija je bila oko 85%. Tijekom prvog dana hospitalizacije novorođenče je imalo jednu febrilnu epizodu. Laboratorijski nalazi su pokazali povišene transaminaze, negativne parametre upale i negativne sve bakterijske kulture. Enterovirusna RNA je otkrivena u uzorku krvi. Ostali nalazi krvi bili su bez značajnih odstupanja. Elektrokardiogram je pokazao tahikardiju s uskim kompleksima QRS (atrijska tahikardija) i srčanom frekvencijom do 280/min. Radi pretvorbe ritma bolesnik je dobio adenozin i amjodaron. U daljnjem tijeku hospitalizacije bolesnik je bio dobrog općeg stanja, eukardičan i eupnoičan. Kod novorođenčadi s tahikardijom i podacima o febrilnosti kod drugih članova obitelji treba posumnjati na enterovirusnu infekciju. Enterovirusna infekcija je vrlo zarazna i potencijalno opasna za život ako se ne otkrije na vrijeme. Osjetljive molekularne metode nude potencijalne prednosti za rano otkrivanje i pravodobno liječenje.

Ključne riječi: *Enterovirusna infekcija; Tahikardija; Novorođenče*