

Iztok Štampelj

Endodontsko liječenje prvoga mandibularnog kutnjaka s tri korijena: prikaz slučaja

Endodontic Management of the Three-Rooted Mandibular First Permanent Molar: a Case Report

Odjel za stomatološke bolesti i dentalnu morfologiju Medicinskog fakulteta Sveučilišta u Ljubljani, Slovenija
 Odjel za operativnu dentalnu patologiju i endodonciju Medicinskog fakulteta Sveučilišta u Ljubljani, Slovenija
 Department of Dental Diseases and Dental Morphology, Faculty of Medicine, University of Ljubljana
 Department of Operative Dentistry and Endodontics, University Medical Centre Ljubljana, Ljubljana, Slovenia

Sažetak

Distalni korijen prvoga mandibularnog trajnog kutnjaka (MFPM) obično ima jedan ili dva kanala. Rijetko kad se pronade i drugi/treći kanal u odvojenom korijenu na distolingvalnoj poziciji (DL) – *radix entomolaris* (RE). Kod bijelaca pojavljuje se u manje od četiri posto slučajeva, ali je važno znati da se može pojaviti. U svakom slučaju potrebno je pažljivo proučiti predoperativni radiogram (ortoradijalno i mezijalno pomaknut) te tijekom endodontskog liječenja pažljivo sondirati dno pulpne komore jer može uputiti na tu korijensku varijantu. Lingvalna inklinacija RE-a i bukolingvalni zavoj moraju se, tijekom čišćenja i širenja kanala, uzeti u razmatranje kako bi se izbjegle pogreške poput izravnavanja kanala i stepenice unutar korijenskog kanala, perforacija ili fraktura instrumenta. Svrha ovog prikaza jest analizirati slučaj mladog pacijenta upućenog u endodontsku ordinaciju nakon što se u korijenskom kanalu stvorila stepenica zbog neodgovarajuće instrumentacije bukolingvalnog zakrivljenog RE-kanala.

Zaprimljen: 20. lipnja 2014.

Prihvaćen: 1. kolovoza 2014.

Adresa za dopisivanje

Assis.professor Iztok Štampelj, DMD, PhD
 University of Ljubljana
 Faculty of Medicine
 Department of Dental Diseases and
 Dental Morphology
 Hrvatski trg 6
 1 000 Ljubljana, Slovenija
 iztok.stampelj@mf.uni-lj.si

Ključne riječi

kutnjak, korijenski kanal, liječenje;
 patološke strukture, anatomske; radix
 entomolaris

Uvod

Kod trajnih kutnjaka moguće su mnogobrojne varijacije u broju korjenova i njihovoj morfologiji. Čak i najstabilniji među njima – prvi mandibularni kutnjak (MFPM), ponekad ima tri korijena umjesto uobičajena dva (slika 1.). U ovom slučaju postoje jedan mezijalni i dva distalna korijena. Distobukalni (DB) korijen odgovara uobičajenom distalnom korijenu, a distolingvalni (DL) prekobrojni korijenu radix entomolaris (RE). RE je morfološki promjenjiviji od mezijalnog i distalnog korijena (1). Po izgledu varira od rudimentarnog produžetka do dobro formiranog korijena koji se dužinom približava distalnom korijenu. Često je zakrivljen, posebice u bukolingvalnom smjeru nevidljivom za standardne radiograme i može biti ili odvojen ili neodvojen od distalnog korijena. Ovaj korijen uvijek ima jedan korijenski kanal s gotovo okruglim presjekom (2 – 5). Prevalencija MFPM-a s RE-om u europskoj se populaciji (nizozemska, finska, britanska i njemačka istraživanja) kreće u rasponu od 0,7 do 3,4 posto (6 – 9). Radix entomolaris češći je u azijskoj populaciji (kineska, japanska, tajlandska) i prelazi 20 posto (4, 10–17). Istaknimo da se RE češće pojavljuje kod pojedini

Introduction

Permanent human molars exhibit a wide range of variations in root number and their morphology. Even the most stable among them, the mandibular first permanent molar (MFPM), sometimes has three roots instead of the usual two (Figure 1). In this case there is one mesial and two distal roots. The distobuccal (DB) one corresponds to a regular distal root and the distolingual (DL) one to a supernumerary root, *radix entomolaris* (RE).

The RE is morphologically more variable than the mesial and distal roots (1). It varies from a rudimentary extension to a well-formed root approaching the length of the distal root. Moreover, it is often curved, especially in the radiographically unseen bucolingual plane, and may be separate or non-separate in relation to the distal root. However, this root invariably contains a single canal with a nearly round canal cross-section (2-5).

The prevalence of the MFPM with an RE in European populations (Dutch, Finn, English, German) ranges from 0.7% to 3.4% (6-9). The RE is, however, much more frequent in Asian populations (Chinese, Japanese, Thai) where

naca pogođenih Turnerovim sindromom, negoli kod zdravih pojedinaca (18). RE je dijagnostički i terapijski izazov, osobito u endodonciji, parodontologiji i oralnoj kirurgiji. Može biti i uzrok neuspješnog endodontskog liječenja ako se ne uoči prije terapije ili za njezina trajanja. Tijekom čišćenja i oblikovanja jako zakrivljenog kanala u RE-u mogu nastati mnogobrojne komplikacije (izravnavanje, stepenica u korijenskom kanalu, perforacija, deformacija apikalnog forame na ili fraktura instrumenata). Pojava RE-a je i lokalni čimbenik u progresiji uznapredovale parodontne bolesti (19). Na kraju, tijekom ekstrakcije zuba s RE-om može se dogoditi fraktura zbog toga što je osjetljiv i zakrivljen. Svrha ovog prikaza slučaja jest opisati kod bijelaca endodontske postupke u slučaju MFPM-a s RE-om. U našem slučaju pacijenta je najprije liječio obiteljski liječnik dentalne medicine koji ga je uputio endodontu jer je stvorio stepenicu tijekom instrumentacije bukolingvalnog zakrivljenog RE-kanala. U ovaj članak ističe se anatomija korijena takvih zuba i pregledno predstavljaju koristi i ograničenja dentalne radiografije u dijagnozi RE-a.

Prikaz slučaja

Pacijent u dobi od 14 godina, bijelac, upućen je na Odjel operativne dentalne patologije i endodoncije Medicinskog fakulteta Sveučilišta u Ljubljani radi nastavka endodontske terapije desnog MFPM-a (zub 46). Primarna liječnica navela je da je otkrila četiri kanala, ali nije mogla osigurati prohodnost DL-kanala. Pacijentu je u anamnezi bila navedena astma. Liječio se antihistaminicima i imao je inhalator s kortikosteroidima i inhalator beta2-agonista kratkog djelovanja. Kliničkim pregledom bio je otkriven privremeni meziokluzalni ispun. Zub nije bio pozitivan na perkusiju i bio je fiziološki pomičan. Dubina sondiranja bila je na svih šest točaka oko zuba manja od četiri milimetra. Susjedni drugi trajni kutnjak samo što nije niknuo u oralnu šupljinu. Na intraoperativnom radiogramu koji je pacijent donio od primarne liječnice, jasno se na zubu vide tri odvojena korijena i radiolucencija uz mezijalni korijen (slika 2.). Prekobrojni korijen identificiran je kao RE, te je postavljena dijagnoza asimptomatskog apikalnog parodontisa. Endodontska terapija obavljena je tijekom dvaju posjeta.

Mandibularna anestezija postignuta je 2-postotnim mepvakainom s epinefrinom (Scandonest 2 % Special; Septodont, Saint-Maur des Fossés, Francuska). Nakon što je uklonjen privremeni ispun, mezijalna stijenka koja je nedostajala rekonstruirana je staklenoionomernim cementom Fuji IX (GC, Tokijo, Japan) i postavljen je koferdam (Hygenic Dental Dam, Coltène Whaledent, Langenau, Njemačka). Operativno polje dezinficirano je 2-postotnim klorheksidinom. Sondiranje dna pulpne komore otkrilo je ulaze u meziolingvalni (ML), mezibukalni (MB), distolingvalni (DL) i distobukalni (DB) korijenski kanal (slika 3.). Inicijalna provjera prohodnosti i širenje obavljani su K-proširivačima 8 do 15 (Dentsply Maillefer, Ballaigues, Švicarska). Stepenica je iden-

the prevalence exceeds 20% (4, 10-17). In addition, the RE appears to be more frequent in individuals affected by Turner syndrome than in healthy individuals (18).

An RE represents a diagnostic and therapeutic challenge, particularly in endodontics, periodontology and oral surgery. It may be the cause of endodontic failure if not identified before or during treatment. In addition, complications may arise during cleaning and shaping of a severely curved root canal in the RE (straightening and ledging of the root canal, perforation, deformation of the apical foramen or instrument fracture). On the other hand, the RE appears to be a local factor that contributes to the progression of advanced periodontal disease (19). Lastly, during extraction of a tooth an RE can be easily fractured because of its apical gracility and curvature.

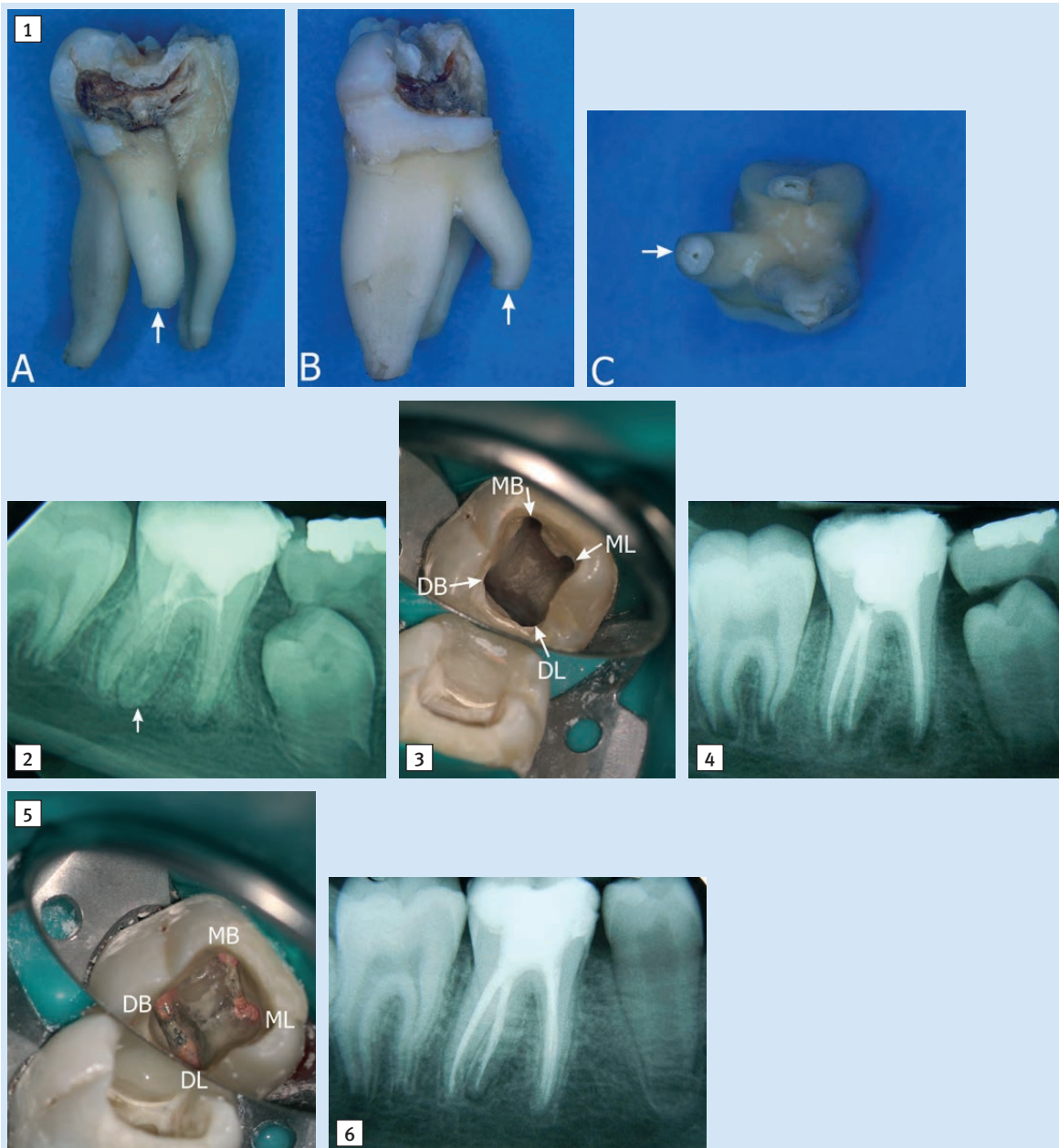
The aim of this case report is to present the endodontic management of a MFPM with an RE in a Caucasian patient. In the present case, the patient was initially treated by a general dentist and then referred to an endodontic office because a ledge was created during instrumentation of a buccolingually curved RE canal. Additionally, this paper highlights the root anatomy of such teeth and reviews the usefulness and limitations of dental radiography in RE diagnosis.

Case Report

A 14-year-old Caucasian patient was referred by his general dentist to the Department of Operative Dentistry and Endodontics, University Medical Centre Ljubljana for continuation of endodontic management of the right MFPM (tooth 46). The referring dentist reported that she identified four root canals, but was not able to establish patency of the DL canal. There was asthma in the patient's medical history. He had been receiving an oral antihistamine, an inhaled corticosteroid, and an inhaled short-acting beta₂-agonist.

Clinical examination revealed a temporary mesio-occlusal restoration. The tooth was not sensitive to percussion and had normal mobility. The probing depth was less than 4 mm at all six locations around the tooth. The neighbouring second permanent molar was about to emerge into the oral cavity. An intraoperative periapical radiograph, made by the referring dentist, clearly showed three separate roots of this tooth and radiolucency associated with the mesial root (Figure 2). A supernumerary root was identified as an RE and a diagnosis of asymptomatic apical periodontitis was made. The root canal treatment was completed in two visits.

The inferior alveolar nerve was anesthetized using 2% mepivacaine with epinephrine (Scandonest 2% Special; Septodont, Saint-Maur des Fossés, France). After removal of the temporary restoration, the missing mesial wall of the access cavity was reconstructed with Fuji IX glass-ionomer cement (GC, Tokyo, Japan) and a rubber dam (Hygenic Dental Dam, Coltène Whaledent, Langenau, Germany) was placed in position. The operative field was disinfected with 2% chlorhexidine. Inspection of the pulp chamber floor revealed mesiolingual (ML), mesiobuccal (MB), distolingual (DL), and distobuccal (DB) root canal orifices (Figure 3). Initial canal exploration and enlargement was performed by K-files



Slika 1. Ekstrahirani prvi lijevi trajni kutnjak s radix entomolaris (RE) lingvalni pogled (A), distalni pogled (B) i apikalni pogled (C). Kruna je opsežno karijesno destruirana; apeksi sva tri korijena su odlomljeni; bijela strjelica pokazuje gdje je RE.

Figure 1 The extracted left mandibular first permanent molar with a *radix entomolaris* (RE) from lingual view (A), distal view (B), and apical view (C). The crown has extensive carious lesions; the apices of all three roots have been fractured away. White arrows indicate the RE.

Slika 2. Radiogram dobiven od primarnog liječnika dentalne medicine prikazuje prvi desni mandibularni trajni kutnjak s tri odvojena korijena gotovo iste dužine. Prekobrojni root radix entomolaris (strjelica) lako se uočava. Korijenski kanali ispunjeni su radiokontrastnim punjenjem kalcijeva hidroksida.

Figure 2 A radiograph, taken by the referring dentist, shows the right mandibular first permanent molar with three separate and almost equally long roots. A supernumerary root *radix entomolaris* (arrow) is easily recognizable. The root canals were filled with a radiopaque calcium hydroxide dressing.

Slika 3. Slika pristupnog kaviteta u zrcalu nakon što su obrađena sva četiri kanala. MB – ulaz u meziobukalni kanal, ML – ulaz u meziolingvalni kanal, DB – ulaz u distobukalni kanal (u distalnom korijenu), DL – ulaz u distolingvalni kanal (u radix entomolaris).

Figure 3 Mirror image of the access cavity after all four root canals had been prepared. MB – orifice of the mesiobuccal canal, ML – orifice of the mesiolingual canal, DB – orifice of the distobuccal canal (in the distal root), DL – orifice of the distolingual canal (in the *radix entomolaris*).

Slika 4. Postoperativni radiogram

Figure 4 Postoperative radiograph.

Slika 5. Slika pristupnog kaviteta u zrcalu nakon potpunog punjenja. MB – ulaz u meziobukalni kanal, ML – ulaz u meziolingvalni kanal, DB – ulaz u distobukalni kanal (u distalnom korijenu), DL – ulaz u distolingvalni kanal (u radix entomolaris).

Figure 5 Mirror image of the access cavity after completed obturation. MB – orifice of the mesiobuccal canal, ML – orifice of the mesiolingual canal, DB – orifice of the distobuccal canal (in the distal root), DL – orifice of the distolingual canal (in the *radix entomolaris*).

Slika 6. Kontrolni radiogram nakon godinu dana

Figure 6 Recall radiograph 1 year later.

tificirana u apikalnoj trećini DL-kanala (RE). Korijenski kanali koronarno su prošireni i pomaknuti CX-instrumentom iz serije ProTaper Universal (Dentsply Maillefer, Ballaigues, Švicarska) kako bi se omogućio pravocrtni pristup instrumentom. S predsavijenim instrumentom Kerr # 10 stepenica je uspješno premoštena i postigla se dužina do apeksa Radix etnomolaris. Radne dužine određene su elektronički korištenjem AFA Apexfindera (EIE Analytic Technology, Orange, SAD). Očitanje za DL-kanal (RE) iznosilo je 22,0 milimetra, a za DB-kanal (u distalnom korijenu) 22,5 milimetra (DB-kvržica kao referentna točka). Ovaj slučaj klinički je klasificiran kao tip III. RE prema De Mooru i suradnicima (20). Korijenski kanali oblikovani su rotirajućim instrumentima ProTaper Universal, osim apikalne trećine RE-kanala koji je obrađen ručno predsavijenim nehrđajućim čeličnim instrumentima. Pokušaji da se ukloni cijela stepenica naslanjanjem instrumenata na lingvalni zid, nisu bili uspješni. Naime, interkanalne nepravilnosti onemogućile su uporabu savitljivih NITI-instrumenata za daljnje proširivanje apikalne trećine RE-kanala. Tijekom instrumentacije korijenski kanali naizmjenice su bili irigirani ultrazvučno 20-postotnim disodium edta (Calcinase, Lege Artis, Dettenhausen, Germany) i 2,5-postotnim NaOCl-om. U kanale je postavljeno međuposjetno punjenje (Calxyl, OCO-Präparate, Dirmstein, Njemačka) i zabrtvljeno staklenoionomernim cementom Fuji Triageom (GC, Tokyo, Japan). Nakon tri tjedna zub je bio asimptomatičan, pa je ponovno otvoren radi konačnog punjenja. Nakon ultrazvučno pojačane irigacije, korijenski kanal napunjen je štapićima gutaperke Roeko (Coltène Whaledent, Langenau, Njemačka) i cementom AH Plus (Dentsply De Trey, Konstanz, Njemačka) tehnikom hladne lateralne kondenzacije (slike 4. i 5.). Konačni ispun bio je od kompozitnih materijala (Excite F i Tetric EvoCeram; Ivoclar Vivadent, Schaan, Lichtenstein). Nakon dvanaest mjeseci pacijent je došao na kontrolu. Na kliničkom pregledu zub je bio asimptomatičan i kontrolni radiogrami su pokazali gotovo potpuno cijeljenje periapikalnog prosvjetljenja (slika 6.).

Rasprava

Općenito, periapikalni radiogrami nisu savršeno sredstvo za otkrivanje prekobrojnih korjenova zato što daju dvodimenzionalni prikaz trodimenzionalnih struktura i trodimenzionalnog kompleksa korjenova. Na standardnim paralelnim slikama može se vidjeti djelomično ili potpuno preklapanje RE-a s glavnim distalnim korijenom jer su smješteni u istoj bukolingvalnoj ravnini. Osim toga RE je manji korijen i ne vidi se uvijek na radiogramima te je potrebna slika s pomakom tubusa za potvrdu prisutnosti. Prema pravilu SLOB (Same Lingual, Opposite Buccal), lingvalno smješteni korijen (RE) prividno se giba u smjeru pomicanja tubusa, a onaj bukalno smješteni pomiče se suprotno od smjera pomaka tubusa. Ako se napravi pomak tubusa od 25° mezijalno, RE će izgledati kao da se pomaknuo također mezi-

in sizes 8 through 15 (Dentsply Maillefer, Ballaigues, Switzerland). A ledge was identified in the apical third of the DL (RE) canal. The root canals were coronally enlarged and relocated with SX file from ProTaper Universal series (Dentsply Maillefer, Ballaigues, Switzerland) to obtain a straight-line entry for the instruments. Using a size 10 Kerr file with a distinct curve at the tip, it was possible to bypass the ledge and reach the apical terminus of the RE. The working lengths were determined electronically using an AFA Apexfinder (EIE Analytic Technology, Orange, USA). Readings for the DL (RE) canal and the DB canal (in the distal root) were 22.0 mm and 22.5 mm, respectively (with the DB cusp as a reference point). Clinically, this case was classified as type III RE according to De Moor et al. (20). Root canals were shaped with ProTaper Universal rotary instruments, except the apical third of the RE canal which was prepared manually with pre-curved stainless steel files. Attempts to completely eliminate the ledge by filing against the lingual wall of the canal were not successful. Thus, the presence of internal canal irregularities did not allow the use of flexible Nickel-titanium instruments for further enlargement of the apical third of the RE canal. During instrumentation root canals were ultrasonically irrigated with 20% disodium edetate (Calcinase, Lege Artis, Dettenhausen, Germany) and 2.5% sodium hypochlorite used in an alternating manner. An interappointment calcium hydroxide dressing (Calxyl, OCO-Präparate, Dirmstein, Germany) was placed in the canals, and sealed with Fuji Triage glass-ionomer cement (GC, Tokyo, Japan).

Three weeks later, the tooth was asymptomatic and was reaccessed for final obturation. After ultrasonically enhanced irrigation, the root canals could be obturated using Roeko gutta-percha cones (Coltène Whaledent, Langenau, Germany), AH Plus sealer (Dentsply De Trey, Konstanz, Germany), and a cold lateral condensation technique (Figures 4 and 5). The final restoration was made using a resin composite (Excite F and Tetric EvoCeram; Ivoclar Vivadent, Schaan, Liechtenstein). Twelve months later the patient was recalled for a follow-up. At the clinical examination the tooth was asymptomatic and the radiographic examination revealed an almost complete resolution of periapical radiolucencies (Figure 6).

Discussion

Generally speaking, periapical radiography is not a perfect tool for detection of supernumerary roots, mostly because radiographs are two-dimensional representations of the three-dimensional root complex. Partial or complete overlapping of the RE and the main distal root can appear on standard parallel views because both roots are mostly situated in the same buccolingual plane. In addition, the RE is usually smaller than the distal root and is therefore not always easily visualized radiographically. An additional angled radiograph may be necessary to confirm its presence. According to the SLOB (Same Lingual, Opposite Buccal) rule, the lingually positioned root (RE) appears to move in the direction of the central ray deviation, while the buccally positioned root (distal root) appears to move in the opposite direction.

jalno pa se može izbjeći preklapanje s distalnim korijenom (21). Trenutačno, unatoč ograničenjima, periapikalni radiogrami prijeko su potrebni za otkrivanja RE-a. Predoperativni radiogrami moraju se pažljivo proučiti, ako je moguće na negatoskopu. Okolno svjetlo može se prigušiti te se dodatno koristiti povećalom za bolji prikaz. Uz takve uvjete RE bi se trebao uočiti u 90 posto slučajeva (22). Čak se i na panoramskom radiogramu može uočiti RE, premda su Harada i suradnici (15) došli do podatka da se samo oko 16 posto RE-a pronađenih na periapikalnim radiogramima može uočiti i na panoramskim radiogramima. Prema stajalištu Krasnera i Rankowa (23) ulazi u korijenske kanale na istoj su udaljenosti u odnosu na zamišljenu liniju povučenu u meziodistalnom smjeru preko dna pulpne komore (1. zakon simetrije) i leži na liniji okomitoj na nju (2. zakon simetrije). Iznimke su trajni maksilarni kutnjaci te MFPM s RE-om. Kod posljednjega 1. pravilo simetrije ne može se primijeniti jer se ulaz u RE nalazi na većoj udaljenosti od zamišljene crte koja popola dijeli dno pulpne komore, negoli ulaz u distalni korijenski kanal (slika 3.). Ulaz u RE smješten je distolingvalno, lingvalno ili mezioingvalno od ulaza u distalni kanal (24). Iz navedenoga je jasno da se 2. pravilo simetrije (slika 3.) može, ali i ne mora moći primijeniti na MFPM s RE-om. Merenja Gu i suradnici (2) navode da je dno pulpne komore nalik na trapezoid s prosječnim DL-kutom od 75 posto. O tome se mora voditi računa kada se otvara pristupni kavitet koji ne treba biti trokutast ili pravokutan kao kod dvokorijenskih MFPM-a, nego više trapezoidan s produženim DL-kutom (slike 3. i 5.). Pri traženju ulaza u RE mogu poslužiti i tamne razvojne linije na dnu pulpne komore. Prema istraživanjima Gua i suradnika (2) ulaz u RE nalazi se približno tri milimetra od oba okolna ulaza (ML- i DB-ulaz). Ovi autori smatraju da je srednja udaljenost između DL-(RE) i DB-ulaza znatno veća nego između ML- i MB-ulaza (2,9 mm u odnosu na 2,5 mm, $p < 0,01$). Lingvalni zid pulpne komore ima dentinsku policu koja često skriva ulaz u RE-kanal (2). Zato je potrebno prije provjere prohodnosti kanala ukloniti dentinsku policu s lingvalnog zida pristupnog kaviteta kako bi se postigao pravolinijski pristup u sam kanal. To se može postići svrdlima Gates-Glidden, nikal-titanijskim rotirajućim instrumentima velikog koniciteta ili posebno konstruiranim ultrazvučnim nastavcima. Jasno je da se pritom instrumenti manje savijaju nego u originalnom RE-kanalu. Premda RE na predoperativnom radiogramu izgleda ravan, često je zakrivljen prema bukalno. U nedavnim istraživanjima (25, 26) RE-kanal je bio jako zakrivljen ($>25^\circ$) bukolingvalno u 90,5 posto od 60,00 posto promatranih MFPM-a. RE-kanal imao je veću zakrivljenost ($32,06^\circ$) negoli oba glavna korijena (maks. $24,34^\circ$) (26). Zato je važno imati na umu zakrivljenost kanala i koristiti se malim predsavijenim ručnim instrumentima. RE-kanal može biti nagnut i lingvalno, što se potvrđuje većim silama na dršku instrumenta u kanalu prema bukalno. De Moor i suradnici (20) predložili su klasifikaciju primjenjivu klinički, a RE-kanale određuju na temelju njihova bukolingvalne zakrivljenosti i lingvalne inklinacije. Tip I odnosi se na ravni RE-kanal paralelan s kanalom u distalnom korijenu, tip II na ravni kanal ali s lingvalnom inklinacijom RE-kanala i tip III na lingvalno inkliniran

Therefore, if a 25° mesioradial projection is employed, the RE will appear to wander mesially, and can also be successfully removed from any overlapping by the distal root (21).

Currently, despite its limitations, periapical radiography is considered to be an essential imaging method for detection of the RE. Preoperative radiographs should be evaluated with care, preferably using a viewing box. The light surrounding the radiograph may be blocked and a magnifying lens may be used for inspection. Under such conditions, the RE should be readily evident radiographically in over 90% of cases (22). An RE may also be depicted in a panoramic radiograph. However, Harada et al. (15) demonstrated that only about 16% of REs found with periapical films can be detected on panoramic radiographs.

According to Krasner and Rankow (23) the orifices of the root canals are equidistant from an imaginary line drawn mesiodistally through the pulp chamber floor (1st law of symmetry) and lie on a line perpendicular to it (2nd law of symmetry). The permanent maxillary molars as well as the MFPMs with an RE are an exception to these laws. In the latter, the 1st law of symmetry does not apply because the RE orifice lies at a greater distance from the imaginary split of the pulp chamber floor than the orifice of the canal in the distal root (Figure 3). Moreover, the RE orifice is located distolingually, lingually or mesiolingually from the orifice of the canal in the distal root (24). Therefore, the 2nd law of symmetry may (Figure 3) or may not apply to MFPMs with an RE.

Measurements of Gu et al. (2) indicate that the resulting shape of the pulp chamber floor resembles that of a trapezoid with an average DL angle of 75° . One must keep this in mind when creating the access cavity, which should not be triangular or quadrangular, as appropriate for the two-rooted MFPMs, but rather trapezoidal with an extended DL corner (Figures 3 and 5). In looking for the RE orifice, dark developmental lines on the pulp chamber floor may serve as natural guides. According to the study by Gu et al. (2), the RE orifice is located approximately 3 mm from both adjacent orifices (ML and DB orifices). These authors also reported that the mean distance between the DL (RE) and DB orifices is significantly greater than between the ML and MB orifices (2.9 mm vs. 2.5 mm, $p < 0.01$).

The lingual wall of the pulp chamber has a dentinal shelf, which frequently hides the underlying RE orifice (2). Therefore, before negotiating the canal, it is necessary to remove the shelf of dentine from the lingual wall of the access cavity, to get a straight-line access to the canal itself. This can be done using Gates-Glidden drills, nickel-titanium rotary files with a large cone, or preferably with specially designed ultrasonic tips. Clearly, this preliminary step insures that the instruments will encounter a lesser curvature than that of the original RE canal.

Although most of the REs appear straight on the preoperative radiograph, they will often curve markedly towards the buccal. In two recent studies (25, 26) the RE canal was severely curved ($>25^\circ$) bucolingually in 90.5% and 60.0% of the MFPMs examined, respectively. The RE canal possessed greater mean angle of curvature ($32,06^\circ$) than the canals in

i bukolingvalno zakrivljeni RE-kanal (slika 1. b). Song i suradnici (27) poslije su dodali i dodatni morfološki tip: mali tip kod kojega je RE kraći od polovine kanala distalnog korijena, te još manji konični tip kod kojega se RE ne može radiološki identificirati. Kod nekih Korejaca pretežni tipovi su II (47,5 %) i III (40,5 %) a slijede tip I (8,1 %), mali tip (2,5 %) i konični tip (1,4 %) (27).

U opisanom slučaju RE je jasno vidljiv na predoperativnim radiogramima, a primarni liječnik identificirao je i instrumentirao sva četiri kanala. Razlog za upućivanje specijalistu bila je stepenica stvorena na stijenci korijenskog kanala tijekom instrumentacije bukolingvalno zakrivljenog RE-kanala, najvjerojatnije ravnim instrumentom neodgovarajuće veličine. Premda RE na radiogramima izgleda ravan (slika 2.), ručna instrumentacija kanala otkrila je veliku bukolingvalnu zakrivljenost smještenu apikalno (tip III RE). Svladavanje stepenice u RE-u obavljeno je prema nedavnim preporukama Jafarzadeha i Abbotta (28). Uzeta je u obzir i njihova preporuka o neuzimanju NITI-instrumenata za završetak terapije u slučaju da nije uklonjena cijela stepenica. U skladu s European Society of Endodontology Quality guidelines (29), zub je liječen tijekom dvaju posjeta i postavljeno je međuposjetno punjenje od kalcijeva hidroksida. U prikazanom slučaju neradna dužina DB-kanala bila veća od DL-a (RE) samo za 0,5 milimetara (mjereno od iste referentne točke). Ovo nije neobičan nalaz za PMFM. Nedavno istraživanje CT-om pokazalo je da je RE kraći od pola duljine distalnog kanala samo u četiri posto slučajeva (27). Zaista, mjerenja na ekstrahiranim prvim mandibularnim trajnim kutnjacima (14) i mikro CT-slike (30) pokazale su da je RE u prosjeku kraći od distalnog korijena samo za 1,5 (14) i 0,9 milimetara (30).

Dodatni čimbenik koji se mora uzeti u obzir kod instrumentacije RE-a jest debljina radikularnog zida. Tijekom obrade kanala perforacija se najčešće može dogoditi u srednjoj trećini RE-kanala, četiri milimetra od apikalnog foramina gdje je debljina mezijalnog zida u prosjeku samo 1,15 milimetara (30). Srećom, RE je jednostavnog tubularnog oblika, gotovo okruglog presjeka, ima mali prirodni konicitet i nema lateralnih kanala te apikalnih ramifikacija, što omogućuje zadovoljavajuće čišćenje bez preopsežnog uklanjanja korijenskog dentina (24). Očito je da zbog razmjerno tankih dentinskih zidova i zakrivljenosti, RE nije pogodan za sidrenje protetskih kolčića.

both main roots (max. 24.34°) (26). Therefore, it is important to keep in mind the existence of this canal curvature and to use small, precurved hand instruments. The RE canal may also be inclined lingually, in confirmation of which the handle of the instrument introduced faces buccally.

De Moor et al. (20) proposed a clinically applicable classification of RE canals based on their buccolingual curvature and lingual inclination. Type I refers to a straight RE canal, which is parallel to the canal in the distal root, type II to a straight, but lingually inclined RE canal, and type III to a lingually inclined and buccolingually curved RE canal (Figure 1B). Song et al. (27) later added two additional morphological types: a small type, of which the RE canal is shorter than half the length of the canal in the distal root, and an even smaller conical type, in which the RE canal is radiographically unidentifiable. In Korean individuals, types II (47.5%) and III (40.5%) were the prevalent types, followed by type I (8.1%), small type (2.5%), and conical type (1.4%) (27).

In the presented case, RE was clearly depicted on the preoperative radiograph and the referring general dentist identified and instrumented all four root canals. The reason for referral to an endodontic office was ledging of the canal wall created during instrumentation of a buccolingually curved RE canal, most probably with a straight instrument of inadequate size. Although the RE appeared straight on the periapical radiograph (Figure 2), manual instrumentation of its canal revealed a pronounced buccolingual curvature located apically (type III RE). Management of the ledged RE canal has followed recommendations recently presented by Jafarzadeh and Abbott (28). Their recommendation was also taken into account not to use Nickel-titanium instruments for completion of the treatment unless the ledge has been completely eliminated. In accordance with the European Society of Endodontology Quality guidelines (29), the tooth was treated in two visits and dressed with an inter-appointment calcium hydroxide medicament.

In the presented case, the working length of the DB canal exceeded that of the DL (RE) canal by only 0.5 mm (measured from the same reference point). This is not an unusual occurrence for a PMFM. A recent CT study has shown that REs shorter than half of the length of the distal root represent less than 4% of all cases (27). Indeed, measurements on extracted MFPMs (14) and micro-CT images (30) have indicated that the RE is on average shorter than the distal root only by 1.5 mm and 0.9 mm, respectively.

An additional factor which should be considered during RE canal instrumentation is thickness of the radicular wall. During root canal instrumentation, perforation is most likely to occur at the middle level of the RE canal, 4 mm from the apical foramen, where the thickness of the mesial wall averages only 1.15 mm (30). Fortunately, the RE canal with its simple tubular shape, a nearly round cross-section, small natural taper and absence of lateral canals and apical ramifications may be cleaned satisfactorily without extensive removal of the radicular dentine (24). Obviously, due to relatively thin dentinal walls and curvature, an RE is not suitable for anchoring prosthetic dowels.

Zaključak

Prevalencija prvoga mandibularnog trajnog kutnjaka (MFPM) s distolingvalnim prekobrojnim korijenom radix entomolaris (RE) kod europske populacije je, prema podacima iz literature, od 0,7 posto do 3,4 posto. Zato kod proučavanja predoperativnog radiograma MFPM-a kliničari trebaju razmotriti mogućnost RE-a. Da parafraziramo Tropea i Debeliana (31), kliničar nikada neće naći više korjenova nego što ih bude tražio. Potencijalni problemi tijekom instrumentacije korijenskih kanala primarno su povezani s lingvalnim nagibom, naglašenom bukolingvalnom zakrivljenošću i relativno tankim dentinskim zidovima.

Conclusion

The prevalence of the mandibular first permanent molar (MFPM) with a distolingually-located supernumerary root *radix entomolaris* (RE) in European populations ranges from 0.7% to 3.4% according to literature. Therefore, when examining the preoperative radiograph of the MFPM, the clinician should always consider the possibility of an RE. To paraphrase the statement from Tropea and Debelian (31), the clinician will never find more roots than he or she is looking for. The difficulties posed by this additional root during root canal instrumentation are primarily related to its lingual inclination, pronounced buccolingual curvature and relatively thin dentinal walls.

Abstract

The distal root of the mandibular first permanent molar (MFPM) contains one or two canals. More rarely, the second/third distal canal is found in a separate root in a distolingual (DL) position – a *radix entomolaris* (RE). In Caucasians, this occurs in less than 4% of cases, but it is equally important to be aware of this possibility. Careful examination of the preoperative periapical radiographs (orthoradial and mesially angled) and inspection of the pulp chamber floor during endodontic management may indicate that this radicular variant is present. RE's lingual inclination and buccolingual curvature must be taken into account during cleaning and shaping of the canal within this root to avoid procedural errors, such as straightening and ledging of the root canal, perforation or instrument fracture. The aim of the present paper was to discuss a case report of a young patient, referred to an endodontic office after a ledge was created by inappropriate instrumentation of a buccolingually curved RE canal.

Received: June 20, 2014

Accepted: August 1, 2014

Address for correspondence

Assis Professor Iztok Štamfelj DMD, PhD
University of Ljubljana
Faculty of Medicine
Department of Dental Diseases and
Dental Morphology
Hrvatski trg 6
1 000 Ljubljana, Slovenia
iztok.stamfelj@mf.uni-lj.si

Key words

Molar; Root Canal Therapy; Pathological Conditions, Anatomical; radix entomolaris

References

- Carlsen O, Alexandersen V. Radix entomolaris: identification and morphology. *Scand J Dent Res*. 1990 Oct;98(5):363-73.
- Gu Y, Lu Q, Wang H, Ding Y, Wang P, Ni L. Root canal morphology of permanent three-rooted mandibular first molars: part I – pulp floor and root canal system. *J Endod*. 2010 Jun;36(6):990-4.
- Gulabivala K, Opasanon A, Ng YL, Alavi A. Root canal morphology of Thai mandibular molars. *Int Endod J*. 2002 Jan;35(1):56-62.
- Gulabivala K, Aung TH, Alavi A, Ng YL. Root and canal morphology of Burmese mandibular molars. *Int Endod J*. 2001 Jul;34(5):359-70.
- Wang Y, Zheng QH, Zhou XD, Tang L, Wang Q, Zheng GN et al. Evaluation of the root and canal morphology of mandibular first permanent molars in a Western Chinese population by cone-beam computed tomography. *J Endod*. 2010 Nov;36(11):1786-9.
- Bolk L. Bemerkungen über Wurzelvariationen am menschlichen unteren Molaren. *Z Morphol Anthropol*. 1915;17:605-10.
- Hjelmmann G. Morphologische Beobachtungen an den Zähnen der Finnen. *Acta Society of Medicine Fenn Duodecim*. 1929;11:1-136.
- Curzon MEJ. Three-rooted mandibular permanent molars in English Caucasians. *J Dent Res*. 1973 Jan-Feb;52(1):181.
- Schäfer E, Breuer D, Janzen S. The prevalence of three-rooted mandibular permanent first molars in a German population. *J Endod*. 2009 Feb;35(2):202-5.
- Turner CG. Three-rooted mandibular first permanent molars and the question of American Indian origins. *Am J Phys Anthropol*. 1971 Mar;34(2):229-41.
- Reichart PA, Metah D. Three-rooted permanent mandibular first molars in the Thai. *Community Dent Oral Epidemiol*. 1981 Aug;9(4):191-2.
- Tu MG, Huang HL, Hsue SS, Hsu JT, Chen SY, Jou MJ et al. Detection of permanent three-rooted mandibular first molars by cone-beam computed tomography imaging in Taiwanese individuals. *J Endod*. 2009 Apr;35(4):503-7.
- Zhang R, Wang H, Tian YY, Yu X, Hu T, Dummer PMH. Use of cone-beam computed tomography to evaluate root and canal morphology of mandibular molars in Chinese individuals. *Int Endod J*. 2011 Nov;44(11):990-9.
- Chen G, Yao H, Tong C. Investigation of the root canal configuration of mandibular first molars in a Taiwan Chinese population. *Int Endod J*. 2009 Nov;42(11):1044-9.
- Harada Y, Tomino S, Ogawa K, Wada T, Mori S, Kobayashi S et al. Frequency of three-rooted mandibular first molars. Survey by x-ray photographs. *Shika Kiso Igakkai Zasshi*. 1989 Feb;31(1):13-8.
- Curzon MEJ. Miscegenation and the prevalence of three-rooted mandibular first molars in the Baffin Eskimo. *Community Dent Oral Epidemiol*. 1974;2(3):130-1.
- Yang Y, Zhang LD, Ge JP, Zhu YQ. Prevalence of 3-rooted first permanent molars among a Shanghai Chinese population. *Oral Surg Oral Med Oral Pathol Oral Radiol Endod*. 2010 Nov;110(5):e98-e101.
- Midtbø M, Halse A. Root length, crown height, and root morphology in Turner syndrome. *Acta Odontol Scand*. 1994 Oct;52(5):303-14.
- Huang RY, Lin CD, Lee MS, Yeh CL, Shen EC, Chiang CY et al. Mandibular disto-lingual root: a consideration in periodontal therapy. *J Periodontol*. 2007 Aug;78(8):1485-90.
- De Moor RJG, Deroose CAJG, Calberson FLG. The radix entomolaris in mandibular first molars: an endodontic challenge. *Int Endod J*. 2004 Nov;37(11):789-99.
- Wang Q, Yu G, Zhou XD, Peters OA, Zheng QH, Huang DM. Evaluation of X-ray projection angulation for successful radix entomolaris diagnosis in mandibular first molars in vitro. *J Endod*. 2011 Aug;37(8):1063-8.
- Walker RT, Quackenbush LE. Three-rooted lower first permanent molars in Hong Kong Chinese. *Br Dent J*. 1985 Nov 9;159(9):298-9.

23. Krasner P, Rankow HJ. Anatomy of the pulp-chamber floor. *J Endod.* 2004 Jan;30(1):5-16.
24. Abella F, Patel S, Duran-Sindreu F, Mercade M, Roig M. Mandibular first molars with disto-lingual roots: review and clinical management. *Int Endod J.* 2012 Nov;45(11):963-78.
25. Chen YC, Lee YY, Pai SF, Yang SF. The morphologic characteristics of the distolingual roots of mandibular first molars in a Taiwanese population. *J Endod.* 2009 May;35(5):643-5.
26. Gu Y, Lu Q, Wang P, Ni L. Root canal morphology of permanent three-rooted mandibular first molars: part II – measurement of root canal curvatures. *J Endod.* 2010 Aug;36(8):1341-6.
27. Song JS, Choi HJ, Jung IY, Jung HS, Kim SO. The prevalence and morphologic classification of distolingual roots in the mandibular molars in a Korean population. *J Endod.* 2010 Apr;36(4):653-7.
28. Jafarzadeh H, Abbott PV. Ledge formation: review of a great challenge in endodontics. *J Endod.* 2007 Oct;33(10):1155-62.
29. European Society of Endodontology. Quality guidelines for endodontic treatment: consensus report of the European Society of Endodontology. *Int Endod J.* 2006 Dec;39(12):921-30.
30. Gu Y, Zhou P, Ding Y, Wang P, Ni L. Root canal morphology of permanent three-rooted mandibular molars: part III – an odontometric analysis. *J Endod.* 2011 Apr;37(4):485-90.
31. Trope, M; Debelian, GJ - editors. *Endodontics manual for the general dentist.* London: Quintessence Publishing; 2005.