

AN UNUSUAL MANIFESTATION OF OSTEOARTICULAR TUBERCULOSIS: CASE REPORT

Frane Grubišić¹, Igor Borić², Adelmo Šegota³, Božo Krušlin⁴ and Simeon Grazio¹

¹Clinical Department of Rheumatology, Physical Medicine and Rehabilitation, Referral Center for Spondyloarthropathies of the Ministry of Health of the Republic of Croatia, Sestre milosrdnice University Hospital Center, Zagreb; ²Sveta Katarina Special Hospital, Zabok; ³Dr Martin Horvat Hospital for Orthopedics and Rehabilitation, Rovinj; ⁴Ljudevit Jurak Clinical Department of Pathology, Sestre milosrdnice University Hospital Center, Zagreb, Croatia

SUMMARY – Although osteoarticular tuberculosis is usually presented as monoarthritis of the large, weight-bearing joints (predominantly hip, knee or ankle joint), or in the form of spinal disease, it is rarely seen as oligoarthritis. In this article, we present case history of a female patient with tuberculous oligoarthritis of the right talocrural joint and left talocalcaneal joint. A 77-year-old female patient was admitted to our department due to the symptoms of painful and swollen right talocrural joint and left talocalcaneal joint accompanied with fever, general weakness and night sweating. Laboratory findings, including erythrocyte sedimentation rate, whole blood count, liver and kidney functional tests showed no significant changes. Plain x-rays and magnetic resonance imaging of the affected joints showed demineralization, significant narrowing of joint space, erosions of articular surfaces, numerous calcifications, and ankylosis of both right talocrural and left talocalcaneal joint. Synovial biopsy confirmed the diagnosis of tuberculous arthritis. Our patient underwent triple tuberculostatic therapy with rifampicin, isoniazid and pyrazinamide, which resulted in the resolution of arthritis.

Key words: *Tuberculosis, osteoarticular; Ankle joint; Case report*

Introduction

Osteoarticular tuberculosis (OTB) comprises 1%-2% of all cases and up to 10% of extrapulmonary cases in the US¹. Of all cases, the most common is spinal tuberculosis (spondylitis or Pott's disease) accounting for 50% of cases. Other forms of OTB that have been described in the literature are peripheral arthritis, usually as monoarthritis of the large weight-bearing joints (30%), osteomyelitis (19%), tenosynovitis, dacrylitis, bursitis and Poncet's disease^{2,3}. Ankle joint is

a rare site of OTB and the frequency of its involvement may vary between 1% and 6%, depending on the source of data⁴⁻⁶.

The incidence of OTB is increasing due to the increased incidence of the acquired immunodeficiency syndrome, emergence of multi-drug resistant mycobacteria, chronic non-infectious disease (e.g., diabetes mellitus, substance abuse, malnutrition), long-lasting usage of glucocorticoids, different immunocompromised states or poor life standards among certain population groups^{7,8}. The main treatment goals for OTB are curing the infection, limiting deformity, and maintaining mobility and function.

In this report, we describe a case of the unusual presentation of tuberculous oligoarthritis in a 77-year-old female, affecting the joints of talocrural region of both legs.

Correspondence to: *Frane Grubišić, MD, MS*, Clinical Department of Rheumatology, Physical Medicine and Rehabilitation, Sestre milosrdnice University Hospital Center, Vinogradska c. 29, HR-10000 Zagreb, Croatia
E-mail: frane.grubisic@zg.htnet.hr

Received February 25, 2013, accepted July 3, 2013

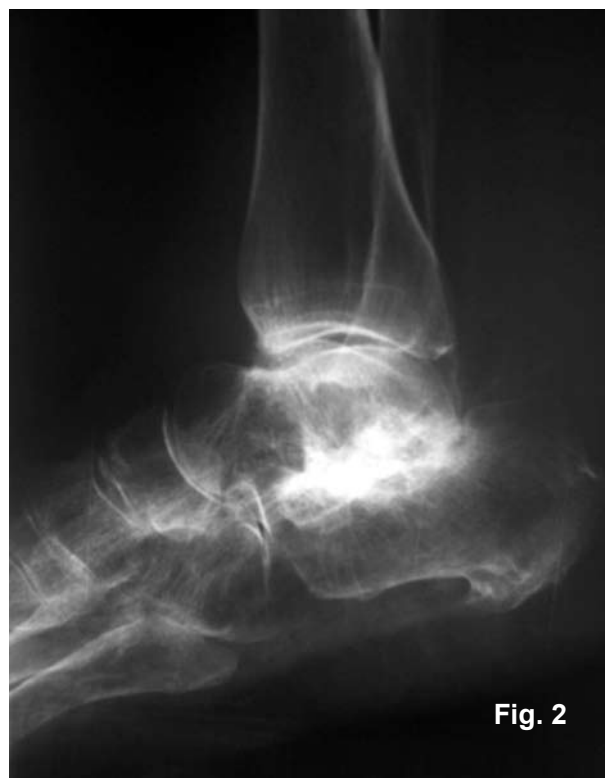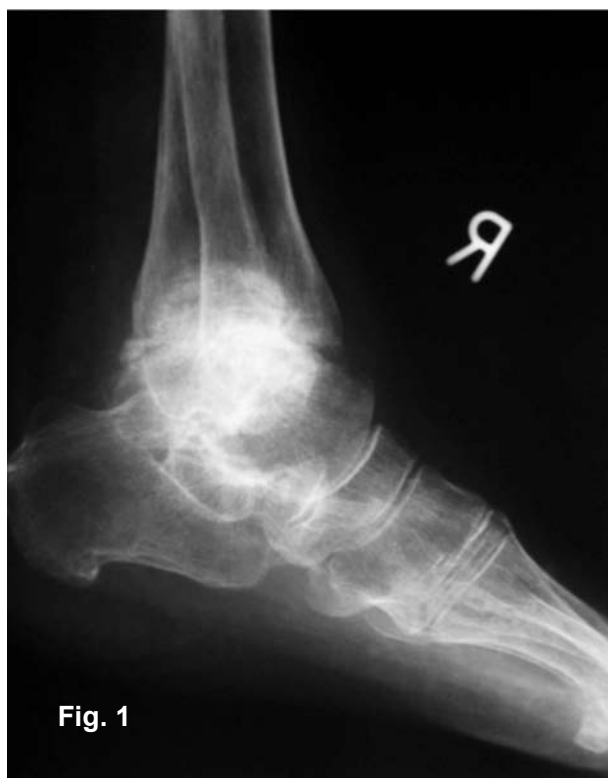Case Report

A 77-year-old female patient was admitted to our Department with the main complaint of persistent pain, swelling and warmth in the talocrural region, which significantly reduced the ability to walk alone. She also complained of fatigue, episodes of fever and night sweating, decreased appetite, weight loss and constipation. No history of any tuberculosis contacts was recorded. Due to persistent arthralgia and instability while standing or walking, our patient had been using canes in both her hands to decrease loading of her feet and to be able to walk. Physical examination revealed soft tissue swelling, pain and warmth of the talocrural region accompanied with a decreased range of flexion and extension in talocrural joints. Her body temperature was not elevated and no abnormal auscultatory sounds on the lungs or peripheral lymphadenopathy were observed. Results of hematologic and biochemical tests showed only mildly elevated erythrocyte sedimentation rate (32 mm/3.6 ks), normocytic anemia ($E\ 3.92 \times 10^{12}/L$, Hgb 114 g/L, hematocrit

0.352 L/L), no lymphopenia or monocytosis. Rheumatoid factor was negative, while C-reactive protein was normal.

Tuberculosis screening using skin test after 72 hours showed 15x20 mm induration (hyperreactor). Chest x-rays showed peribronchial lesion in the basal part of the right lung, consistent with a possible previous TB lung infection. X-rays of the talocrural joints revealed significantly narrowed joint space of the right talocrural joint, severe deformities and calcifications in the left talocalcaneal joint (Figs. 1 and 2). Body scan with technetium-99 showed intensive accumulation of the radioisotope in the right talocrural joint. All these clinical, laboratory and imaging findings raised suspicion of the specific arthritis of the affected joints. Synovial biopsy of the right talocrural joints was performed to confirm the correct diagnosis.

Histopathologic examination revealed a large number of tubercles with the area of caseous necrosis surrounded by epithelioid cells, lymphocytes and Langerhans cells (Figs. 3 and 4). Tuberculostatic therapy in a combined manner (rifampicin, isoni-



Figs. 1 and 2. Conventional x-rays of both right talocrural and left talocalcaneal joints: diffuse demineralization, narrowed joint space of the right talocrural joint, severe deformities and calcifications in the left talocalcaneal joint.

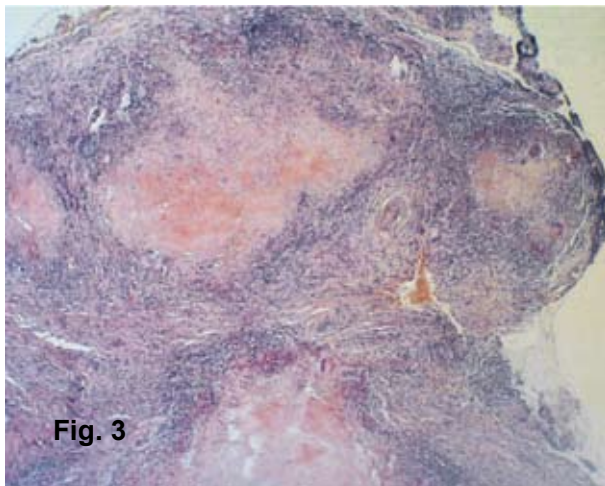


Fig. 3

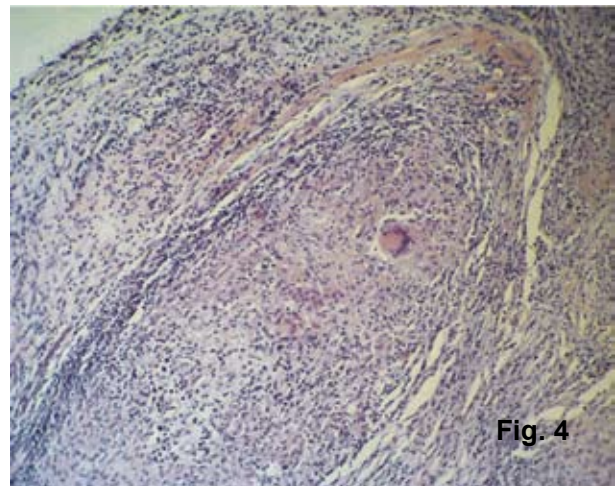


Fig. 4

Figs. 3 and 4. Synovial tissue with numerous granulomata containing epithelioid cells and multinuclear giant cells of Langerhans type (A – HEX40, B – HEX100).

azid and pyrazinamide) was administered over the next twelve months. Our patient underwent regular check-ups. Two years later, radiologic reevaluation was performed. Chest x-rays showed calcification of hilar lymph nodes. Conventional x-rays and magnetic resonance imaging of the talocrural region revealed complete disappearance of the joint space of the right talocrural joint, ankylosis of the right tibiofibular joint, and ankylosis and disappearance of the joint space of the left talocalcaneal joint but without signs of active inflammation.

Four years later, our patient's general health condition is satisfactory; she needs no assistance in daily activities and uses a cane while walking.

Discussion

The ankle joint is a rare site for OTB. Being an uncommon site, along with the lack of awareness and clinical experience and its ability to mimic other rheumatic conditions may cause delay in diagnosis and therapy, which results in severe joint destruction and deformity and leads to functional impairment. Skeletal tuberculosis occurs usually during the first three decades of life. In developed countries, tuberculosis has been successfully reduced and is considered to be a rare condition, which is the reason why current generations of both general practitioners and specialists are unfamiliar with skeletal manifestations of the disease^{9,10}. Recent publications reveal the importance

of identifying the risk groups who are susceptible to the development of tuberculosis; these include elderly native-born individuals, immigrant subgroups from high-incidence tuberculosis countries, prisoners, human immunodeficiency virus infected persons, homeless, and drug addicts. All the risk groups may contribute to the development of tuberculosis¹¹⁻¹⁴.

Mycobacterium tuberculosis may reach bone through the blood stream (from contagious infection) or by lymphatic dissemination. Indirect approach is from epiphyseal or metaphyseal lesions. The delay in the diagnosis of peripheral tuberculous arthritis in our patient was caused by the atypical clinical presentation and radiologic findings, which could not answer the main question of the origin of her arthritis. Other risk factors for which we believe may have contributed to the development of ankle tuberculosis in our patient were peribronchial lesion in the basal part of the right lung on chest radiographs (sign of primary complex) and minor repetitive ankle sprains. Chen *et al.* have published a list of the possible risk factors associated with ankle tuberculosis, including tuberculosis on chest radiographs, history of trauma, presentation with sinus discharge, duration of symptoms of more than 3 months, leukocyte count $<10,000/\mu\text{L}$ and C-reactive protein $<5\text{ mg/dL}$. Also, evidence for tuberculosis on chest radiographs was identified as an independent risk factor for ankle tuberculosis¹⁵. Key factors in confirming the diagnosis of OTB in our patient were radiologic examination and tissue biopsy.

Skeletal tuberculosis must be included in the differential diagnosis of subacute or chronic monoarthritis, chronic abscess, drainage sinus or chronic osteomyelitis.

Earlier diagnosis and treatment (pharmacological and/or surgical) may prevent foot deformity and reduce patient's disability. Adjuvant surgery is required not only to establish the diagnosis (e.g., synovial biopsy), but also for the treatment of patients with deformity and widespread destruction of articular cartilage. Certain operation techniques like tibiototalcaneal arthrodesis using a supracondylar femoral nail or arthroscopically assisted debridement and ankle arthrodesis may be considered for advanced OTB and might enable early return to daily function^{16,17}.

References

1. REIDER HL, SNIDER DE JR, CAUTHEN GM. Extrapulmonary tuberculosis in the United States. *Am Rev Respir Dis* 1990;141:347-51.
2. YAO DC, SARTORIS DJ. Musculoskeletal tuberculosis. *Radiol Clin North Am* 1995;33:679-89.
3. PETO HM, PRATT RH, HARRINGTON TA, LOBUE PA, ARMSTRONG LR. Epidemiology of extrapulmonary tuberculosis in the United States, 1993-2006. *Clin Infect Dis* 2009;49(9):1350-7.
4. BOCCANEGRA TS. Mycobacterial, fungal and parasitic arthritis. In: KLIPPEL JH, DIEPPE PA, editors. *Rheumatology*. London: Mosby, 1999;6.4.1-6.4.12.
5. DHILLON MS, NAGI ON. Tuberculosis of foot and ankle. *Clin Orthop Relat Res* 2002;398:107-13.
6. SAMUEL S, BOOPALAN PR, ALEXANDER M, ISMAVEL R, VARGHESE VD, MATHAI T. Tuberculosis of and around ankle. *J Foot Ankle Surg* 2011;50(4):466-72.
7. CHOI WJ, HAN SH, JOO JH, KIM BS, LEE JW. Diagnostic dilemma of tuberculosis in the foot and ankle. *Foot Ankle Int* 2008;29(7):711-5.
8. World Health Organization. Global tuberculosis control – epidemiology, strategy, financing: WHO Report 2009. WHO website.
9. TULI SM. General principles of osteoarticular tuberculosis. *Clin Orthop Relat Res* 2002;398:11-9.
10. LIN RC, LU KH, LUE KH. Adjuvant arthroscopy for ankle tuberculosis: a report of two cases. *Foot Ankle Int* 2009;30(1):74-9.
11. BARNIOL J, NIEMANN S, LOUIS VR, BRODHUN B, DREWECK C, RICHTER E, BECHER H, HAAS W, JUNGHANSS T. Transmission dynamics of pulmonary tuberculosis between autochthonous and immigrant subpopulations. *BMC Infect Dis* 2009;9:197. doi: 10.1186/1471-2334-9-197.
12. CARVALHO AC, MIGLIORI GB, CIRILLO DM. Tuberculosis in Europe: a problem of drug resistance or much more? *Expert Rev Respir Med* 2010;4(2):189-200.
13. PIMPIN L, DRUMRIGHT LN, KRUIJSHAAR ME, ABUBAKARI, RICE B, DELPECH V, HOLLO V, AMATO-GAUCI A, MANISSERO D, KÖDMÖN C. Tuberculosis and HIV co-infection in European Union and European Economic Area countries. *Eur Respir J* 2011;38(6):1382-92.
14. JURČEV-SAVIČEVIĆ A, KATALINIĆ-JANKOVIĆ V, GJENERO-MARGAN I, ŠIMUNOVIĆ A, VIDIĆ D, GUNJAČA J, OBROVAC M. Epidemiological patterns of tuberculosis in Croatia in the period 1996-2005. *Coll Antropol* 2011;35(2):523-8.
15. CHEN SH, WANG T, LEE CH. Tuberculous ankle *versus* pyogenic septic ankle arthritis: a retrospective comparison. *Jpn J Infect Dis* 2011;64(2):139-42.
16. GAVASKAR AS, CHOWDARY N. Tibiototalcaneal arthrodesis using a supracondylar femoral nail for advanced tuberculous arthritis of the ankle. *J Orthop Surg (Hong Kong)* 2009;17(3):321-4.
17. TANG KL, LI QH, CHEN GX, GUO L, DAI G, YANG L. Arthroscopically assisted ankle fusion in patients with end-stage tuberculosis. *Arthroscopy* 2007;23(9):919-22.

Sažetak

NEOBIČNA MANIFESTACIJA KOŠTANO-ZGLOBNE TUBERKULOZE: PRIKAZ BOLESNICE

F. Grubišić, I. Borić, A. Šegota, B. Krušlin i S. Grazio

Iako se koštano-zglobna tuberkuloza najčešće prezentira kao monoartritis velikih zglobova koji prenose težinu (osobito kukovi, koljena ili gležanj) ili zahvaćenošću kralježnice, rijetko se javlja u obliku oligoartritisa. U ovom članku daje se prikaz bolesnice s tuberkuloznim oligoartritisom desnog talokruralnog zgloba i lijevog talokalkanealnog zgloba. Sedamdeset-sedmogodišnja bolesnica je primljena u našu Kliniku zbog bolova i otekline desnog talokruralnog zgloba i lijevog talokalkanealnog zgloba popraćenog tresavicom, općom slabošću i noćnim znojenjem. Laboratorijski nalazi, uključujući sedimentaciju eritrocita, kompletnu krvnu sliku, jetrene i bubrežne testove, nisu pokazali nikakva odstupanja. Konvencionalni rendgenogrami i magnetska rezonanca zahvaćenih zglobova pokazali su demineralizaciju, značajno suženje zglobnog prostora, erozivne promjene zglobnih površina, brojne kalcifikate i ankilozu desnog talokruralnog zgloba i lijevog talokalkanealnog zgloba. Biopsija sinovije je potvrdila dijagnozu tuberkuloznog artritisa. Kod bolesnice je provedena trojna tuberkulostatska terapija rifampicinom, izonijazidom i pirazinamidom koja je dovela do povlačenja artritisa.

Ključne riječi: *Tuberkuloza kostiju i zglobova; Gležanj, zglob; Prikaz slučaja*