

SEVER'S DISEASE COMPLICATED WITH OSTEOMYELITIS

Matej Mustapić¹, Igor Borić², Dragan Lepur³, Dijana Zadravec¹ and Klaudija Višković⁴

¹Department of Diagnostic and Interventional Radiology, Sestre milosrdnice University Hospital Center, Zagreb; ²Department of Radiology, Sveta Katarina Special Hospital, Zabok; ³Department of Intensive Care Medicine and Neuroinfectology, ⁴Department of Radiology and Ultrasound, University Hospital for Infectious Diseases, Zagreb, Croatia

SUMMARY – Sever's disease is juvenile osteochondrosis of calcaneus, manifested with posterior heel pain and mild swelling, usually in young athletes, caused by repetitive microtrauma. The standard diagnostic procedures include radiographs and ultrasound examination. It is a self-limiting condition, usually treated conservatively. We present a case of Sever's disease complicated with calcaneal osteomyelitis. A 9-year-old boy with a several month history of left heel pain was admitted to our institution for further clinical evaluation and therapy. Bilateral Sever's disease was clinically diagnosed, confirmed by radiographs and ultrasound examination. Magnetic resonance imaging (MRI) showed osteolytic zone in the posterior left calcaneus with peripheral enhancement after contrast administration and surrounding bone and subcutaneous edema, suggestive of osteomyelitis. After six weeks of parenteral antibiotic treatment, the patient's condition improved. Follow up MRI performed 3 months later showed significant regression of osteolytic lesion and replacement with granulation tissue surrounded with new bone formation. To our knowledge and literature search, this is a previously unreported complication of Sever's disease. MRI should be done in all atypical cases of Sever's disease to rule out any other possible disorders including osteomyelitis.

Key words: *Sever's disease; Calcaneus; Osteomyelitis; Diagnostic imaging; Case report*

Introduction

Sever's disease (calcaneal apophysitis, juvenile osteochondrosis of calcaneus) is a painful, self-limiting condition, usually in young athletes, which can interfere with walking and physical performance in sports. It usually occurs in active 10- to 12-year-old boys. It was first described by Sever in 1912, as inflammation of the calcaneal apophysis, resulting in pain at the posterior heel with mild swelling and difficulty with walking¹. The disease is bilateral in 60%-80% of cases. The etiology of Sever's disease is believed to be repetitive trauma to the weaker structure of the apophysis,

caused by traction in the opposite direction between Achilles tendon and plantar structures, causing inflammation^{2,3}. The anatomy of calcaneal apophysis is a contributing factor for significant shear stress because of its vertical orientation and the direction of pull from the strong gastrocnemius-soleus muscle group. This results in a clinical picture of heel pain in a growing active child, which worsens with activity, especially running or jumping, and relieves with rest. The onset of the disease is usually gradual. The diagnosis is provided by physical examination with characteristic history in specific age group, confirmed by x-ray and ultrasound. The treatment is initially focused on reducing the pain and movement limitations, and then on preventing recurrence. Limitation of activity (especially running and jumping) is usually necessary. In patients with symptoms that are not severe enough to limit sports activities, wearing an inner-shoe heel

Correspondence to: *Matej Mustapić, MD*, Department of Diagnostic and Interventional Radiology, Sestre milosrdnice University Hospital Center, Vinogradska c. 29, HR-10000 Zagreb, Croatia
E-mail: mmustapicm@gmail.com

Received May 14, 2013, accepted July 8, 2013

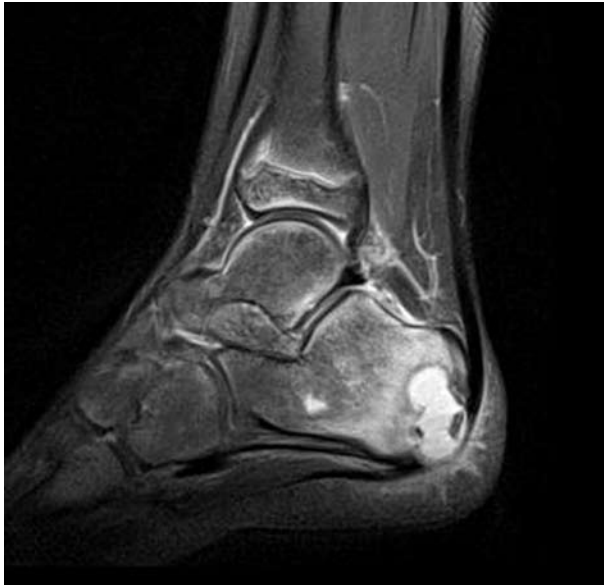

Fig. 1. Sagittal fat-suppressed proton density weighted image of the left heel shows osteolytic lesion in the posterior part of the calcaneus and fragmented apophysis, with surrounding bone marrow and subcutaneous edema.

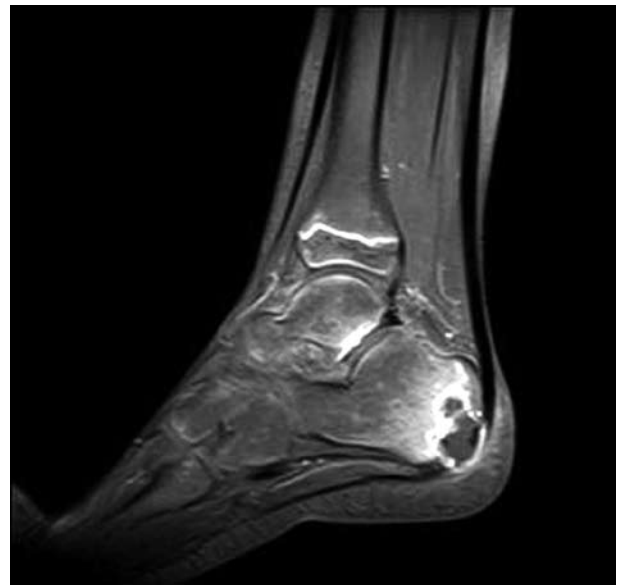


Fig. 2. Sagittal contrast-enhanced fat-suppressed T1 weighted image reveals osteolytic lesion in the left calcaneus with hypointense center and rim enhancement due to abscess formation.

lift, a monitored stretching program, icing, and anti-inflammatory agents normally reduce the symptoms⁴. To prevent recurrence, a good pre-exercise stretching program is obligatory.

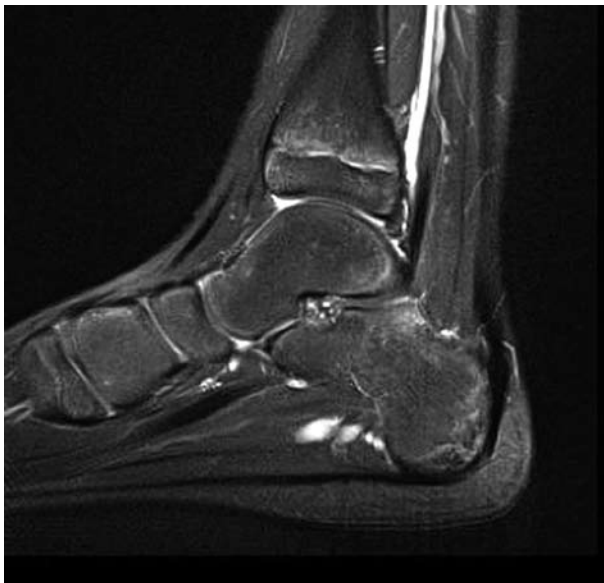
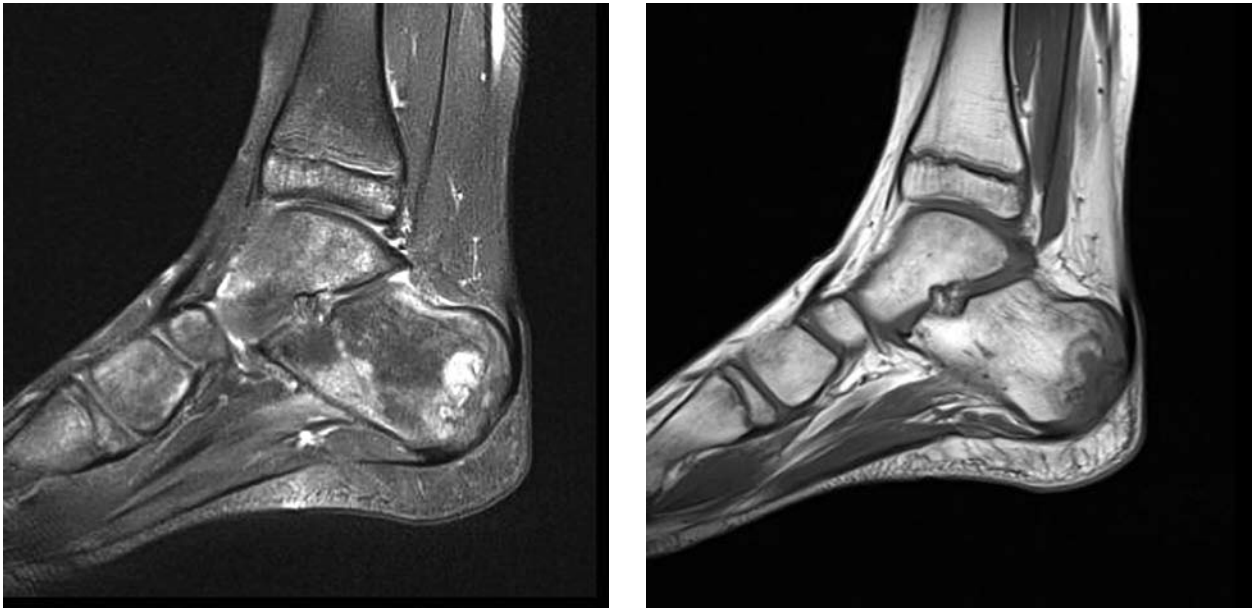
Fig. 3. Sagittal fat-suppressed proton density weighted image of the right heel shows mild edema of calcaneal apophysis with sclerosis and fragmentation of ossification center.

Case Report

A 9-year-old Caucasian boy with a several month history of left heel pain was admitted to the hospital because of Sever's disease. Four months earlier, he had started complaining of pain in his right heel, which was relieved with symptomatic therapy. One month before admission, he also started complaining of pain in his left heel, after minor contusion of the left foot. Radiographs of the ankle and heel showed neither fracture nor dislocation, but bilateral sclerosis and fragmentation of calcaneal apophysis were present. According to clinical and radiographic findings, Sever's disease was diagnosed and confirmed by ultrasound examination. Physical therapy and non-steroidal anti-inflammatory drugs were recommended. Since pain in the left heel was not relieved with therapy, he was admitted to the hospital for further diagnostic procedures. On admission, physical examination showed left heel swelling and painful Achilles insertion with deep palpation. Except for elevated erythrocyte sedimentation rate (26 mm/1 h), elevated C-reactive protein (52 mg/L) and highly positive antistreptolysin-O titer (2560 units/mL), other relevant laboratory values were normal. Magnetic resonance imaging (MRI) of the patient's feet showed osteolytic zone in the posterior left calca-



Figs. 4 and 5. Sagittal fat-suppressed proton density weighted image and sagittal T1 weighted image of the left heel show significant regression of osteolytic lesion in the calcaneus, replacement with granulation tissue surrounded with new bone formation and minimal bone edema.

neus with peripheral enhancement after contrast administration and surrounding bone and subcutaneous edema, compatible with osteomyelitis (Figs. 1 and 2). Apophysis was fragmented and sclerotic. There were also signs of calcaneal apophysitis of the right heel (Fig. 3). After six weeks of parenteral treatment (with clindamycin), the patient's condition significantly improved. Follow up MRI performed 3 months later showed significant regression of the osteolytic lesion and replacement with granulation tissue surrounded with new bone formation (Figs. 4 and 5). Minimal bone edema was present.

Discussion and Conclusion

According to literature search, this is the first case report of Sever's disease complicated with calcaneal osteomyelitis. The obvious asymmetry of physical findings and clinical symptoms, as well as different response to symptomatic therapy was quite unusual in this case. Most patients experience pain with deep palpation at the Achilles insertion and pain when performing toe and ankle dorsiflexion that is relieved with passive equinus positioning. Swelling may be present but is usually mild. Radiographic appearance

of resorption, fragmentation, and increased sclerosis of calcaneal apophysis, leading to eventual union, can be seen. The radiographs showing fragmentation of calcaneal apophysis are not by themselves a diagnostic tool in asymptomatic child because multiple centers of ossification may exist in the normal apophysis as well⁵. The diagnosis of calcaneal apophysitis is a clinical decision with characteristic but not specific signs on x-rays. Besides apophyseal fragmentation, edema of the Achilles tendon at insertion and retrocalcaneal bursitis as well as subcutaneous edema can be seen on ultrasound examination⁶. Differential diagnosis of Sever's disease includes Achilles tendon pathology, calcaneus fracture, rarely bone tumor, tarsal coalition, and possibly osteomyelitis⁷. The question arises whether the osteomyelitis, in this case, is a separate entity or a true complication of Sever's disease. Calcaneus is a rare location for bone infections in children. The calcaneal apophysis can be considered as a metaphyseal region of long bones, leading to bone vulnerability to hematogenous infection, especially if apophysitis is present⁸. Taking into consideration all the above mentioned facts and patient's history, we find osteomyelitis to be the true complication of Sever's disease in this case. In all atypical cases of Sever's

disease, with unusual presentation and disease course, MRI should be performed to rule out osteomyelitis and alternative diagnoses.

References

1. LAU LL, MAHADEV A, HUI JH. Common lower limb sport-related overuse injuries in young athletes. *Ann Acad Med Singapore* 2008;37(4):315-9.
2. HENDRIX CL. Calcaneal apophysitis (Sever disease). *Clin Podiatr Med Surg* 2005;22(1):55-62.
3. HACKNEY AC, KOLTUN KJ. The immune system and overtraining in athletes: clinical implications. *Acta Clin Croat* 2012;51(4):633-41.
4. PECK DM. Apophyseal injuries in the young athlete. *Am Fam Physician* 1995;51(8):1891-5, 1897-8.
5. KOSE O. Do we really need radiographic assessment for the diagnosis of non-specific heel pain (calcaneal apophysitis) in children? *Skeletal Radiol* 2010;39(4):359-61.
6. HOSGOREN B, KOKTENER A, DILMEN G. Ultrasonography of the calcaneus in Sever's disease. *Indian Pediatr* 2005;42(8):801-3.
7. DAMIANO J, BOUYSET M. Hindfoot pain. *Rev Prat* 2010;60(3):353-60.
8. JENZRI M, SAFI H, NESSIB MN, *et al.* Hematogenous osteomyelitis of the calcaneus in children: 26 cases. *Rev Chir Orthop Reparatrice Appar Mot* 2008;94(5):434-42.

Sažetak

SEVEROVA BOLEST KOMPLICIRANA OSTEOMIJELITISOM

M. Mustapić, I. Borić, D. Lepur, D. Zadravec i K. Višković

Severova bolest je juvenilna osteohondroza petne kosti koja se manifestira bolovima i oteklinom u stražnjem dijelu pete, najčešće u mladih sportaša, uzrokovana opetovanim mikrotraumama. Slikovna dijagnostička obrada uključuje rendgenske snimke i ultrazvučni pregled. Bolest se liječi konzervativno, budući da prolazi sama od sebe. Prikazali smo devetogodišnjaka sa Severovom bolesti kod kojega standardna terapija nije polučila klinički učinak. Učinjen je pregled pete magnetskom rezonancijom (MR) koji je pokazao Severovu bolest i osteomijelitis petne kosti. MR pregled pete bi trebalo učiniti u svim atipičnim slučajevima Severove bolesti kako bi se isključila druga patološka stanja uključujući osteomijelitis.

Ključne riječi: *Severova bolest; Kalkaneus; Osteomijelitis; Slikovna dijagnostika; Prikaz slučaja*