

Complications of Pulmonary AVMs in a Patient with Rendu-Osler-Weber Disease

Sanda Škrinjarić-Cincar^{1,2}, Gordana Petrović¹, Vanja Fuštar Bosanac³, Vladimir Fijačko¹
and Ivan Hećimović⁴

¹ »J. J. Strossmayer« University, School of Medicine, University Hospital Center Osijek, Department of Pulmology, Osijek, Croatia

² »J. J. Strossmayer« University, School of Medicine, Osijek, Croatia

³ »J. J. Strossmayer« University, School of Medicine, University Hospital Center Osijek, Department of Cardiology, Osijek, Croatia

⁴ »J. J. Strossmayer« University, School of Medicine, University Hospital Center Osijek, Department of Neurosurgery, Osijek, Croatia

ABSTRACT

Rendu-Osler-Weber Disease, also called hereditary hemorrhagic telangiectasia (HHT), is a rare, genetically determined complex disease with a spectrum of associated manifestations which extend beyond the typical pathology of arteriovenous malformations (AVMs). Our subject, a 54-year old male patient with a long history of HHT has a typical mucocutaneous telangiectasias and bleeding from the nose, but the most important manifestations of the disease are those related to pulmonary AVMs. A variety of complications, such as hypoxemia, polycythemia, cyanosis, clubbing fingers and brain abscesses, have developed over time as a consequence of a-v shunt in the pulmonary AVMs. A large pulmonary AVM necessitated a surgical intervention when the patient was in his thirties, and two more surgeries followed later, due to brain abscesses. Despite intensive manifestations of the disease and episodes of life threatening complications, the patient has adjusted well to his chronic medical condition and lives a near-normal life.

Key words: Osler-Rendu-Weber disease, hereditary hemorrhagic telangiectasia, pulmonary arteriovenous malformation, hypoxemia, complications

Introduction

Rendu-Osler-Weber syndrome, also called hereditary hemorrhagic telangiectasia (HHT), is a rare disorder characterized by abnormal blood vessels with a tendency for bleeding¹. The disease is genetically determined, but a substantial number of the affected persons are unaware of the disease or a positive family history because lesions may be minimal and bleeding never occurs². Typical HHT lesions are mucocutaneous telangiectasias and arteriovenous malformations (AVMs) in different visceral organs, such as the lungs, the brain, the liver, the spleen, the urinary and GI tracts³. It is estimated that at last 30% of HHT patients have pulmonary involvement⁴.

The disease may appear at any age and may have a wide spectrum of manifestations, varying from asymptomatic ones to involving multiple organs. In fact, mucocutaneous telangiectasias and arteriovenous malformations (AVMs) may be a potential source of serious morbidity and mortality⁵. Recurrent epistaxis and telangiectasias

of the skin are often the first and foremost manifestations. However, the greatest danger of an AVM is haemorrhaging.

A diagnosis of HHT is clinical and is made by the Curacao criteria⁶. Epistaxis, telangiectasias, visceral lesions and family history are the criteria. The HHT diagnosis is definite if three criteria are present. The prognosis for patients with the disease depends on the symptoms related to visceral involvement, especially pulmonary⁷ and CNS⁸. Approximately 10% of HHT patients die from complications, while the majority have a normal life expectancy¹. Diagnostic imaging based on ultrasound (US), computed tomography (CT), magnetic resonance imaging (MRI) and digital subtraction angiography (DSA) have a fundamental role in detecting visceral involvement of HHT patients and is therefore crucial for prognostic assessment and therapeutic approach⁹. However, patients with pulmonary AVMs are more prone to

strokes and brain abscesses⁶, while patients prone to heavy bleeding may develop iron deficiency anaemia and require blood transfusions¹⁰. Other possible complications of this disease are abscesses or infections of heart valves, hepatomegaly, heart failure, pulmonary hypertension, thrombosis, decreased oxygen levels in the blood, high red blood cell count, cyanosis, clubbing of the fingers, or difficulty breathing and exercising². In severe cases, a variety of medical and surgical measures is needed for support or to prevent bleeding and other complications.

Case Report

We report a case of a 54-year old male patient diagnosed with the Rendu-Osler-Weber disease. There are no cases of HHT in the patient's family and no genetic testing has been performed up to date. The patient was diagnosed at the age of 27, however he showed some signs of the disease much earlier. A routine chest X-ray revealed an oval, sharply defined mass in the right lung, which

was described as angioma. At that time, besides frequent bleeding from gingivas and the nose, patient had no other symptoms and generally was in good condition. Physical examination revealed livid skin, clubbing fingers, and telangiectatic lesions of the skin (Figure 1) and oral mucosa (Figure 2).

Further diagnostic procedures were performed years later when laboratory tests showed significant hypoxemia (at rest arterial blood gas level was 7.8 kPa and during exercise 60W 6.57 kPa) and polycythemia (E 7.8 million/ μ L; Hgb 262 g/L). A chest CT scan and angiography confirmed an AVM 6–7 cm in size in the middle lobe of the lung and multiple AVMs in both sides (Figure 3). These findings were followed by surgery. Pathohistology of the resected segment of the middle lobe confirmed a few smaller AVMs beside the described large one. After the surgical resection, polycythemia had significantly improved for months and years. A lung function diagnostic revealed normal spirometry and a moderately impaired diffusion capacity (DLCOc was recorded at 49,9%). ECG findings included sinus rhythm and right electrical axis.

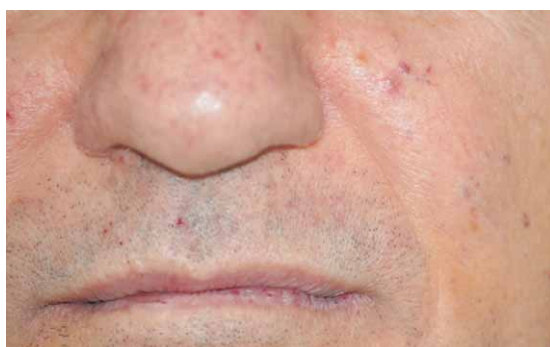

Fig. 1. Telangiectatic lesions of the skin.

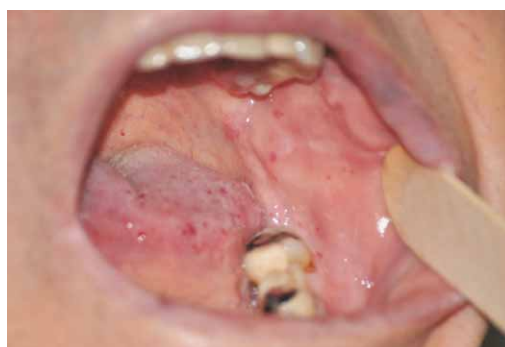

Fig. 2. Telangiectatic lesions of oral mucosa.

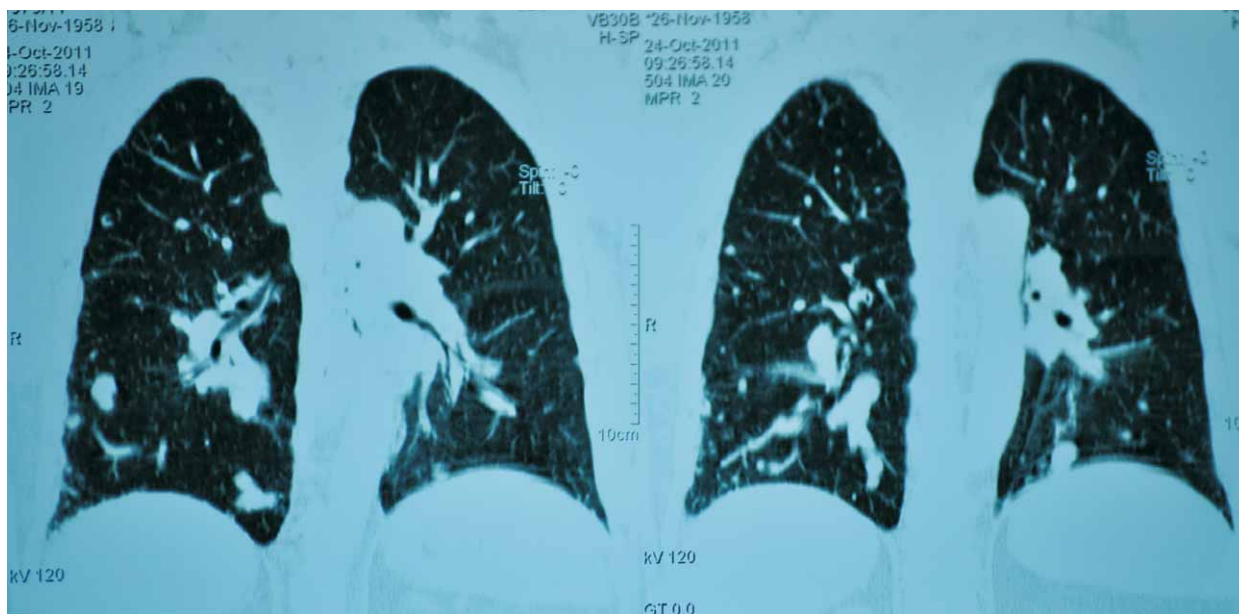


Fig. 3. CT scans showing multiple AVMs in both lungs.

Echocardiography showed normal values of dynamic parameters and resistance, and there were no signs of pulmonary hypertension. Right heart catheterization confirmed right to left shunt due to a-v fistula which was calculated to be 27% of unsaturated blood.

In the years following the procedure, respiratory insufficiency was characterized by a mildly progressive hypoxemia.

Throughout the course of his life, the patient has had serious neurologic complications two times; both were

addressed surgically and successfully resolved. In each case, the patient suffered from a cerebral abscess (Figure 4,5) with signs of sepsis and typical neurological symptoms. The last postoperative period was complicated by phlebothrombosis, which was successfully resolved, and further testing revealed no coagulation abnormalities. After surgical and antibiotic treatments, the patient recovered without neurological sequelae, except slightly dysrhythmic EEGs.

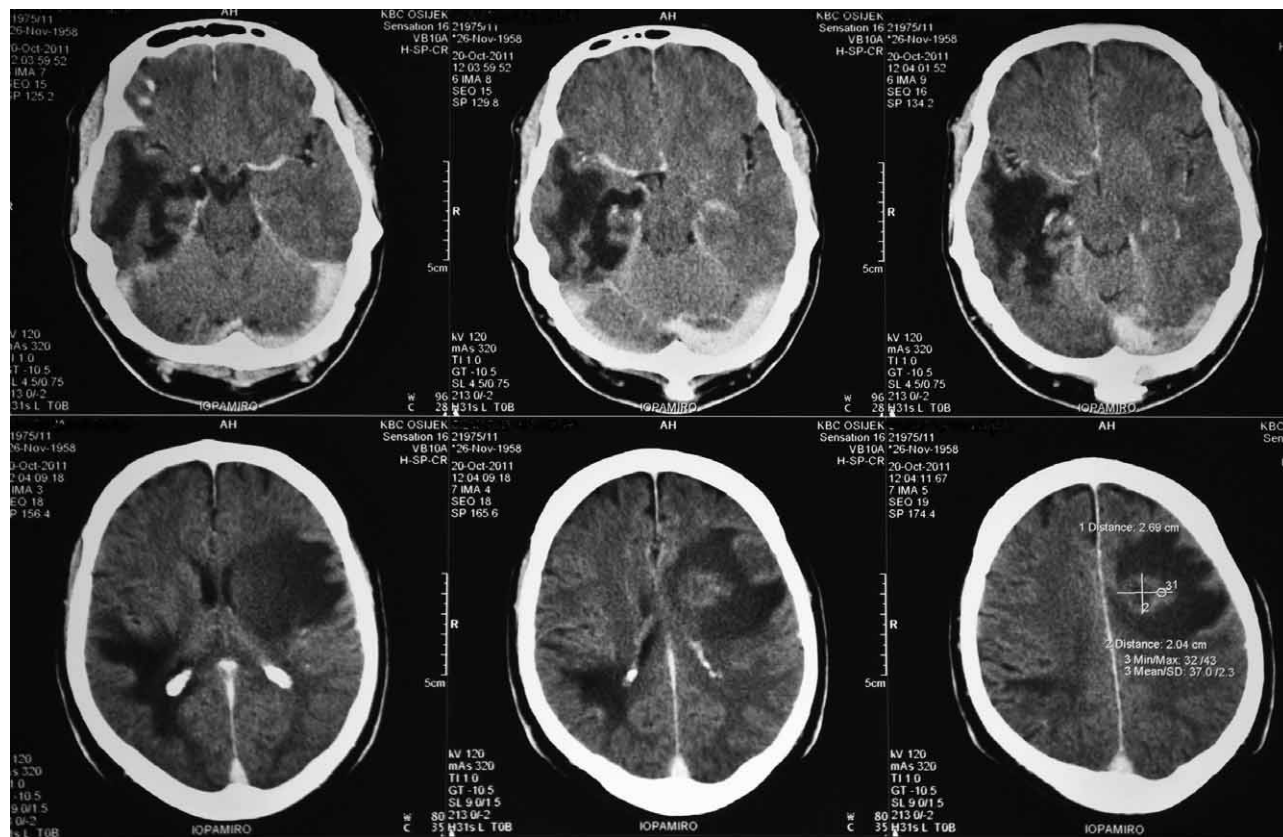


Fig. 4. CT scans showing brain abscesses at the right hemisphere and sequels on the left from the previous one.

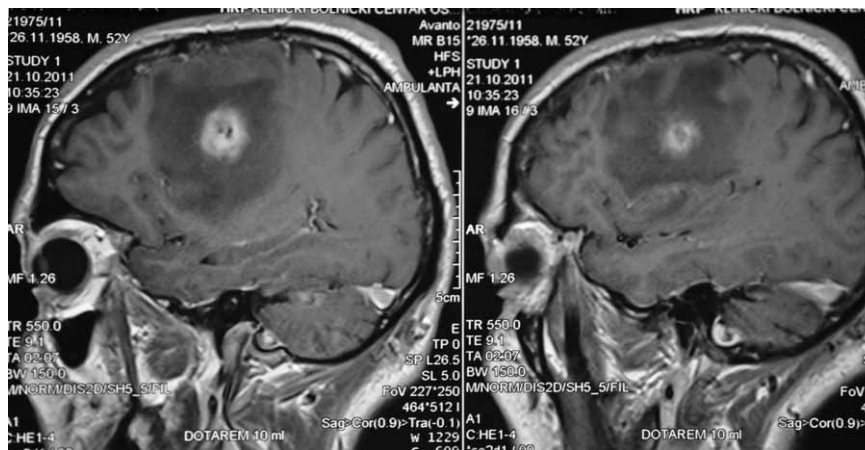


Fig. 5. MR imaging of brain abscesses in patient with pulmonary AVMs.

Because of hypoxemia, the patient has been on long term oxygen therapy for the last three years. Because of anaemia, he regularly takes iron supplements. He has polycythemia, and arterial blood gas analyses shows significant partial respiratory insufficiency without elevated bicarbonates. Last measuring of arterial oxygen before oxygen therapy was 5.7 kPa (SaO₂ 80%), and after the administration of 3 L/min of oxygen, the level was 8,9 kPa (SaO₂ 94%). Spirometry values remain within the normal range, and diffusion capacity has not worsened compared to past measurements. Echocardiography has revealed normal pulmonary vascular resistance which is calculated to be 1.7 WU and has confirmed no signs of pulmonary hypertension so far.

At present, the patient does not complain of health problems including dyspnea and reports feeling well. He performs normal everyday activities and occasionally moderate to strenuous physical activities without breathing symptoms.

Discussion

Rendu Osler Weber disease is a rare disease which may vary in intensity². We describe a patient with a very long history of the disease and serious clinical manifestations which have progressed throughout his life. The patient has experienced the majority of possible complications of the disease due to pulmonary AVMs⁷. The first signs, hypoxemia and polycythemia, were a consequence of right to left shunt in multiple pulmonary AVMs and were responsible for the further course of the disease. Although there are no available data regarding nocturnal oxygen desaturation, we speculate that it was probably significant. Extremely large numbers of red blood cells and haemoglobin, recorded at the time when the disease had been diagnosed, decreased after the resection of the lung segment affected by the large AVM. The group of authors reported about the same findings¹¹. During the time, recurrent bleeding from the nose and gingiva has resulted in chronic iron deficiency with all characteristics of microcytic anaemia, requiring iron substitution, despite the high number of red blood cells. Fortunately, the patient has had no haemoptysis and no symptoms of bleeding from other visceral organs. However, hypoxemia has gradually worsened through the course of the illness. This is an obvious sign of the development of new

AVMs in the lungs, which was confirmed by a control CT scan. This clinical observation is in accordance with the fact that AVMs may be present at birth but may also develop later in life^{12,13}. In one study of patients with pulmonary AVMs, the majority of them had no respiratory symptoms, and only one third of them exhibited physical signs indicating a massive right-to-left shunt such as cyanosis, clubbing and polycythemia¹⁴.

In the case of our subject, brain abscesses complicated the disease two times. This was not surprising because in patients with pulmonary AVMs, free direct capillary communication between pulmonary and systemic circulations makes them predisposed for embolic events, such as cerebral abscesses and embolic stroke⁵. In both cases, our patient has entirely recovered, despite the fact that diagnostic imaging of his brain still shows big remaining sequels.

It is interesting that, despite remarkable hypoxemia and the above mentioned signs, our patient feels neither dyspnea nor other respiratory symptoms and lives a near – normal life. We can explain this with the fact that he has adjusted to his chronic medical condition and remains stable for a long time. It is postulated that patients with pulmonary AVMs have better exercise tolerance than patients with similar degrees of hypoxemia generated by other causes because of lower pulmonary vascular resistance, which allows them to appropriately augment pulmonary blood flow and cardiac output during exercise⁷. Surprisingly good exercise tolerance in our subject could be explained by the fact that he has not developed pulmonary hypertension and has low pulmonary resistance.

To sum up the above-mentioned facts, our patient is still able to lead a rather normal and good life, despite complications and progressive manifestation of his disease. Genetic testing can confirm a presence of mutations within implicated genes and can also be a useful diagnostic tool in identifying individuals at risk of developing disease among family members¹⁵. Because HHT is a complex disease with a wide spectrum of manifestations, patients suffering from HHT require a comprehensive coordination of care from multiple specialists, which is necessary for appropriate treatments. As already emphasized, the treatment of the disease must be supportive and comprehensive in order to prevent complications.

REFERENCES

1. LESSNAU KD, Osler-Weber-Rendu Disease, accessed 25.03.2013. Available from: URL: <http://emedicine.medscape.com/article/2048472>. —
2. SHOVLIN CL, Blood Rev, 24 (2010) 203. DOI: 10.1016/j.blre.2010.07.001. —
3. GUTTMACHER AE, MARCHUK DA, WHITE RI Jr, N Engl J Med, 333 (1995) 918. —
4. HAITJEMA T, DISCH F, OVERTOOM TTS, WESTERMANN CJJ, LAMMERS JWJ, Am J Med, 99 (1995) 519. —
5. BEGBIE ME, WALLACE GM, SHOVLIN CL, Postgrad Med J, 79 (2003) 18. —
6. SHOVLIN CL, GUTTMACHER AE, BUSCARINI E, FAUGHNAN ME, HYLAND RH, WESTERMANN CJJ, KIELDSEN AD, PLANCHU H, Am J Med Genet, 91 (2000) 66. —
7. GOSSAGE JR, KANJ G, Am J Respir Crit Care Med, 158 (1998) 643. —
8. FULBRIGHT RK, CHA LOUPKA JC, PUTMAN CM, SZE GK, MERRIAM MM, LEE GK, FAYAD PB, AWAD IA, WHITE RI Jr, AJNR Am J Neuroradiol, 19 (1998) 477. —
9. MEMEO M, SCARDAPANE A, DE BLASI R, SABBA C, CARELLA A, ANGELELLI G, Radiol Med, 113 (2008)547. DOI: 10.1007/s11547-008-0276-3. —
10. DOS SANTOS JWA, DALCIN TC, NEVES KR, MANN KC, PRETTO GLN, BERTOLAZI AN, J Bras Pneumol, 33 (2007) 109. —
11. KUKULJ S, IVANOVI-HERCEG Z, SLOBODNJAK Z, Coll Antropol, 24 (2000) 241. —
12. KRINGS T, OZANNE A, CHNG SM, ALVAREZ H, RODESCH G, LASJAUNIAS PL, Neuroradiology, 47 (2005) 711. —
13. SHOVLIN C. Hereditary hemorrhagic telangiectasia (Osler-Rendu-Weber Syndrome), accessed 26.03.2013. Available from: URL: <http://www.upto>

date.com/contents/hereditary-hemorrhagic-telangiectasia. — 14. SHOVLIN CL, LETARTE M, Thorax, 54 (1999) 714. — 15. PRIGODA NL, SAVAS S, ABDALLA SA, PIOVESAN B, RUSHLOW D, VANDEZAN-

DEK, ZHANG E, OZCELIK H, GALLIE BL, LETARTE M, J Med Genet, 43 (2006)722. DOI: 10.1136/jmg.2006.042606.

S. Škrinjarić-Cincar

»J. J. Strossmayer« University, University Hospital Center Osijek, Department of Pulmology, J. Huttlera 4,
31000 Osijek, Croatia
e-mail: sanda.cincar@gmail.com

KOMPLIKACIJE PLUĆNIH ARTERIOVENSKIH MALFORMACIJA (AVM) U BOLESNIKA S RENDU-OSLER-WEBEROVOM BOLEŠĆU

SAŽETAK

Rendu-Osler-Weberova bolest, također poznata pod imenom hereditarne hemoragijske telangiektazije (HHT), je rijetka, nasljedna i složena bolest u kojoj se u podlozi raznolikih kliničkih manifestacija nalaze karakteristične arteriovenske malformacije (AVM). Prikazan je slučaj 54-godišnjeg muškarca s dugotrajnom anamnezom HHT koji ima tipične simptome krvarenja iz mukokutanih telangiektazija, ali klinički najznačajnije manifestacije bolesti su posljedica plućnih AVM. Čitav niz komplikacija kao hipoksemija, policitemija, cijanoza, batičasti prsti i apscesi mozga razvijali su se tijekom njegovog života kao posljedica desno lijevog shunta u plućnim AVM. Kirurška intervencija bila je potrebna u trećem desetljeću njegova života zbog velike plućne a-v fistule te kasnije u dva navrata zbog apscesa mozga. Usprkos značajnim kliničkim manifestacijama i ozbiljnim komplikacijama bolesnik se prilagodio svom zdravstvenom stanju i živi gotovo normalan život.