

Case report

Pericardial effusion as the first manifestation of occupational tuberculosis in a health care worker

Veljko Flego, Dubravka Matanić Lender, and Ljiljana Bulat-Kardum

Department of Pulmonology, Clinical Hospital Centre Rijeka, Rijeka, Croatia

Received in June 2014

CrossChecked in June 2014

Accepted in November 2014

Tuberculosis (TB) is an infectious disease and, apart from protecting patients, attention must be given to protecting the persons who come in contact with them, especially nurses and medical practitioners. A 43-year-old immunocompetent male nurse developed occupationally disseminated TB after contact with patients affected by active TB (culture positive) while working in a psychiatric hospital. The first manifestation of the disease was exudative pericarditis with *Mycobacterium tuberculosis* (MT) confirmed two months after pericardiocentesis and evacuation of 1200 mL of pericardial effusion. Many lymph nodes showed histologic findings of granulomatous inflammation with necrosis. Treatment with antituberculosis drugs caused complications, including transient short-term medication-induced toxic hepatitis, prolonged fever, left pleural nonspecific effusion, and mononeuritis of the right peroneus nerve. The treatment lasted 14 months and led to permanent consequences, including fibrothorax with restrictive ventilation disorders and reduced diffusion of the alveolar-capillary membrane. This case highlights the need to improve the protection of health care workers who are in contact with TB patients, as well as the usefulness of the tuberculin skin test and QuantiFERON-TB test, which can be used to identify early latent TB.

KEY WORDS: *antituberculous; disseminated tuberculosis; extrapulmonary tuberculosis; nosocomial disease; occupational disease; tuberculous pericarditis*

The incidence of active tuberculosis (TB) among health care workers (HCW) has been reported to be 0.4 % in Germany, 1.0 % in Portugal, or up to 2.5 % in Brazil (1-3), with nurses enduring the highest risk, followed by physicians. Nurses are at a greater risk of acquiring TB if they work in pulmonary medicine or human immunodeficiency virus (HIV) wards, likely due to repeated contact with infected patients (4). The risk of developing TB is highest during the first years of exposure. The predominant clinical presentations are extrapulmonary cases (48 %), followed by pulmonary (44 %) and combination cases (8 %) (5). The most common forms of extrapulmonary TB (EPTB) include pleural, lymph node, osteoarticular, and abdominal TB. Other localisations such as central nervous system, urogenital, breast, chest wall, cutaneous, middle ear, and pericardial TB are rarely observed (6, 7).

Pericarditis is a rare manifestation of TB, occurring in approximately 1-2 % of all TB cases (8). TB accounts for up to 4 % of acute pericarditis and 7 % of cardiac tamponade (5). Organisms usually spread to the pericardium from the mediastinal or hilar lymph nodes or from the lungs, and rarely as part of miliary TB. Tuberculous pericarditis (TBP) is a potentially lethal condition, and its prompt treatment can be lifesaving. Effective treatment requires a rapid and accurate diagnosis, which is often difficult. In occupationally exposed staff, pericardial effusion non-responsive to routine therapy should arouse suspicion of occupational TBP.

Here, we report a case of TBP in a 43-year-old male nurse. Following a positive culture of *Mycobacterium tuberculosis* (MT) from the pericardial fluid, he immediately began undergoing treatment with antituberculous chemotherapy.

Case report and discussion

The 43-year-old male patient had been employed as a male nurse in a chronic psychiatric hospital for eight months before experiencing the first symptoms. He had received BCG vaccination and had a scar on his left upper arm. The patient had no history of tuberculosis, diabetes, or immunosuppression. He was not a smoker, did not drink alcohol or abuse drugs.

Four months before the onset of the first symptoms, our patient was in daily contact with five patients suffering from active pulmonary TB (nosocomial TB), as shown by a positive sputum culture for MT. The patient had a negative Mantoux test at the start of his employment, as well as four months later. After an additional three months, his Mantoux test was 22×25 mm, showing hyperresponsiveness. At the same time, his QUANTIFERON-TB test result was also positive (8.19 IU mL⁻¹). Two weeks before these positive test results, he was subfebrile for ten days. Radiological findings of the thorax were normal. Sputum was sent for microbiological examination. Ziehl-Neelsen stained smears did not show acid-fast bacilli. Six weeks later, the patient presented a fever of 39.5 °C, pain in the epigastrium, and shortness of breath with effort. He was hospitalized at the Department for Infectious Diseases, where ultrasound findings established pericardial effusion. The patient was then transferred to the Department of Cardiovascular Diseases, where he underwent pericardiocentesis and evacuation of 1200 mL of

pericardial effusion. The aetiology of pericardial effusion was not established, and the patient was treated with prednisone 40 mg at decreasing doses.

Two months later, at a prednisone dose of 5 mg, the patient once again became febrile. Pericardial effusion was still found and the prednisone dose was increased to 30 mg. The patient remained febrile and fatigued. The prolonged-incubation mycobacteria growth indicator tube (MGIT) showed positive findings in the sputum collected four months earlier. Positive findings were also established in MGIT and cultures on Lowenstein-Jensen media of pericardial effusion samples from two months earlier. The patient was hospitalised at the Department of Pulmonology. Prednisone treatment was rapidly decreased and antituberculosis treatment was initiated with isoniazid 400 mg, rifampicin 600 mg, and ethambutol 1200 mg. Radiological findings of the thorax were normal. After a month of hospital treatment, the patient was discharged to his home, without a fever and in good general condition.

A week later, the patient was again admitted to the Department of Pulmonology with a temperature of 39.5 °C and pain in the left side of the chest. Extensive left pleural effusion was established (Figures 1 and 2). On two occasions, thoracocentesis was performed, removing 900 and 600 mL of pleural effusion-type exudate. Treatment with piperacillin/tazobactam 4.5 g *i.v.* every 8 hours was started, but the fever persisted. We performed two additional thoracocenteses,

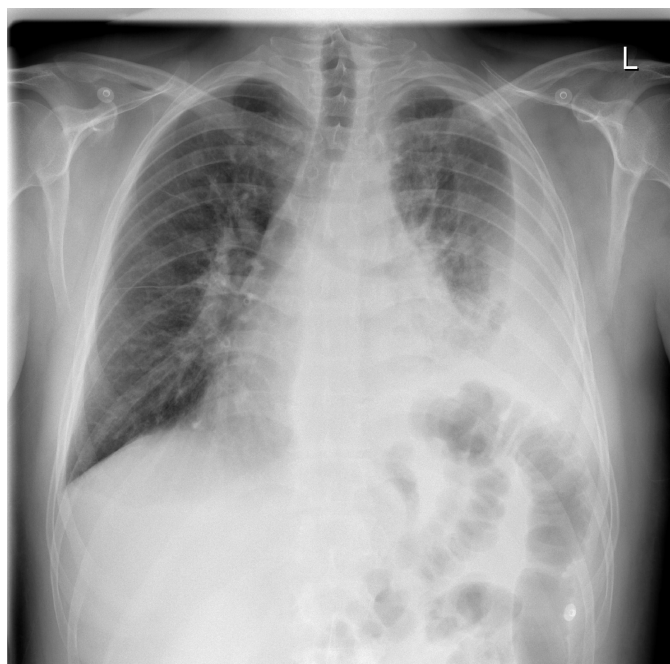


Figure 1 A chest radiogram showing large left pleural effusion

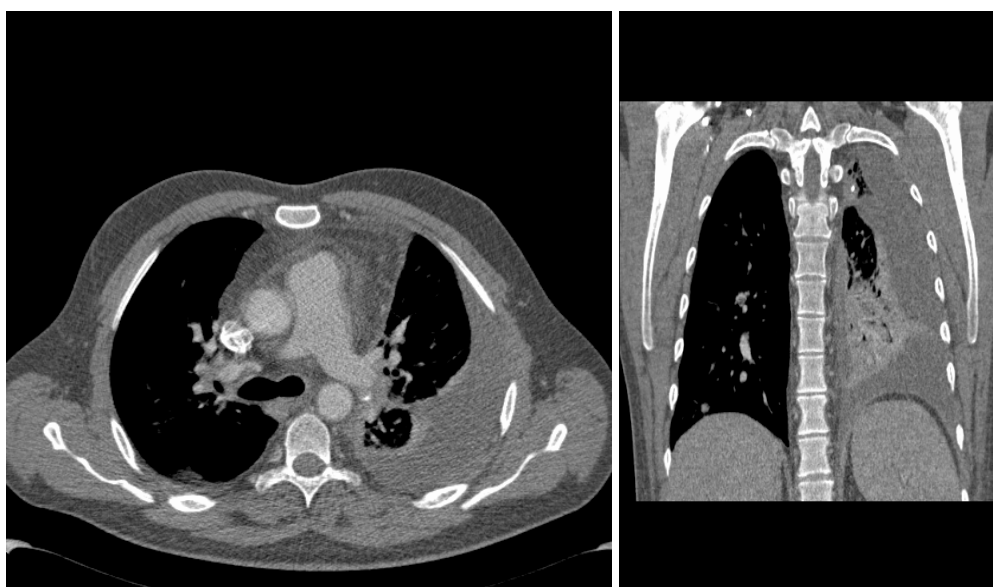


Figure 2 Axial computed tomography (CT) scan (left) and coronal reformatted CT image (right) of the chest showing left pleural effusion

removing a total of 1500 mL of additional pleural effusion. Cytological findings of extracted pleural effusion included non-specific inflammation, and bacteriological examination revealed sterility. Treatment continued with antituberculosis drugs (isoniazid 400 mg, rifampicin 600 mg, ethambutol 1200 mg, pyrazinamide 1.5 g) and prednisone 25 mg. Pleural effusion gradually regressed, but the patient remained continuously febrile.

After a month of treatment, the patient's fever subsided and prednisone treatment was suspended. A few days later, the patient's temperature rose to 38.5 °C and would not decrease for two weeks. Multislice computed tomography (MSCT) revealed lesions consistent with active pulmonary tuberculosis and enlarged lymph nodes (neck, axilla, mediastinum, and groin), a small left pleural effusion, and a small pericardial effusion. Treatment with antituberculosis drugs was further complicated by transient short-term medication-induced toxic hepatitis, prolonged fever of unclear aetiology, pleural effusion of unclear aetiology, and mononeuritis of the right *nervus peroneus*. To make sure that no other condition was causing the fever (lymphoma), positron emission tomography-computed tomography (PET/CT) scanning was performed, showing a number of metabolically active lesions in the lymph nodes and the left pleura. The patient was further investigated by cytologic puncture of three nodes (axilla and groin), and biopsy of a lymph node in the right groin. The findings showed granulomatous inflammation with

necrosis and further treatment was started with rifampicin 600 mg and isoniazid 400 mg.

Two months later, an echocardiogram showed no pericardial effusion, pulmonary hypertension, or constrictive pericarditis. Spirometry indicated restrictive ventilation disorders of an intermediate level, due to a higher left side fibrothorax. It was recommended that the patient continue taking rifampicin and isoniazid. Three months later at a check-up with the pulmonologist, the patient exhibited no fever and felt well, except for the occasional stabbing pain in the left part of the chest. Further treatment with rifampicin and isoniazid was recommended. Three months later, radiological examination showed residual pleuropulmonary changes, which was a consequence of tuberculous infection. Treatment with rifampicin and isoniazid continued. After 14 months, the antituberculosis treatment was completed. The patient still felt shortness of breath, intolerance of effort, and a constant stabbing pain in the left part of the chest. As a result of excessive tuberculosis, there were residual consequences in the form of a left fibrothorax, restrictive disorders of ventilation (FVC 53.1 %), and reduced diffusion of carbon monoxide (DLCO 48.5 %) (Table 1). The patient is now employed at a location where he is no longer exposed to contact with MT and can avoid greater physical exertion.

This case is important for several reasons. TB is a rare disease in the general population, but is the most common occupational infectious disease among HCWs. Tuberculous pericarditis is an uncommon

Table 1 Time sequence of disease development

Month	Symptoms, diagnostic tests, and therapy
1	Employment; Mantoux test: negative.
4	Mantoux test: negative
5	Subfebrility; Chest X-ray: normal
7	Mantoux test: hyperresponsiveness; QUANTIFERON-TB test: positive
9	Pericardial effusion; Prednisone
11	MT positive; Chest X-ray: normal; TB therapy
13	Fever; Left exudative pleurisy; TB therapy+piperacillin/tazobactam
14	Fever; Pleural effusion regressed; TB therapy+prednisone
15	Fever; MSCT of chest
16	Medicamentous toxic hepatitis
17	Fever; PET/CT; TB lymph nodes; TB therapy
19	Normal echocardiogram; Left side fibrothorax; TB therapy
23	No fever; Pleuropulmonary residues; TB therapy
25	Completed TB therapy; Left side fibrothorax; Restrictive disorders of ventilation

MT – *Mycobacterium tuberculosis*

TB – Tuberculosis

localization of EPTB and is rarely the first manifestation of generalized TB. The presently reported patient became very ill soon after contact with patients suffering from active TB, but the MT culture of sputum on Lowenstein-Jensen media became positive only after four months. Finally, the patient suffered notable complications during treatment with antituberculosis drugs, and severe and permanent damage after TB was cured.

In 2009, Croatia reached the levels of other European countries with low incidence of TB, reaching a notification rate of below 20 TB cases per 100,000 inhabitants for the first time. The rate of occupational diseases among those working in health care and social care in Croatia was 11.78/100,000 employees (9). Occupational diseases were reported in 3 % of Croatian HCWs between 2002 and 2009, with infectious diseases comprising 68 % of such cases (10). Among these occupational infectious

diseases in HCWs, 27 % were TB (the most common). According to these data, the incidence of active TB as an occupational disease in HCWs in Croatia is 0.6 %. Among occupational diseases in HCWs, 39 % occurred in nurses and 23 % in doctors. There is mounting evidence that HCWs are at an increased risk of contracting a TB infection and developing the disease (11). Effective environmental and personal protective measures, along with education of patients and HCW are urgently needed to reduce the occupational risk of TB.

EPTB occurs in 15-20 % of immunocompetent and 20-70 % of HIV-infected patients with TB (12). Studies from the Netherlands and the US show that EPTB is more often diagnosed in women and is associated with ethnic minorities and those born in other countries (13). Tuberculous pericarditis is seen in 1-8 % of EPTB patients (14). A stratification of the data by high- and low-incidence countries shows a higher proportion of EPTB in low-incidence countries. The proportion of EPTB increased during the period from 2002 to 2011 in the European Union, mainly because the notification rate of pulmonary TB decreased (15). TB is diagnosed in only 4 % of acute pericarditis cases (16), while pericarditis may be seen in 1-2 % of pulmonary tuberculosis cases. It is difficult to isolate *Mycobacterium species* from pericardial fluid samples and only one-third of such samples are diagnostic.

The presently reported patient had generalised TB with lymph nodes, pericardium, and coexisting pulmonary TB. TBP was the first evidence of generalized TB, which is very rare (17). The significant amount of time it took to diagnose the patient contributed to the severe clinical disease condition and long duration of treatment. The disease was recognized as occupational and our patient was no longer capable of performing the work he performed before contracting the disease. It is favourable that this patient did not develop constrictive pericarditis, which is often a severe and permanent consequence of TBP (18, 19).

Tuberculous pericardial effusion rarely occurs in immunocompetent persons. Our present case demonstrates the need for a higher index of suspicion for TB in any case of pericardial effusion, particularly among HCWs with previous exposure to TB. Assessment of TB as an occupational disease should be limited to occupationally exposed populations. Tuberculin skin test and QUANTIFERON-TB tests can identify early latent TB and are useful for

diagnosing contact with MT in low-incidence countries, even in a vaccinated population, as well as for directing diagnoses to active TB (20).

REFERENCES

1. Niihau's A, Kesavachandran C, Wendeler D, Haamann F, Dulon M. Infectious diseases in healthcare workers – an analysis of the standardised data set of a German compensation board. *J Occup Med Toxicol* 2012;7:8. doi: 10.1186/1745-6673-7-8
2. Costa JC, Silva R, Ferreira J, Nienhaus A. Active tuberculosis among health care workers in Portugal. *J Bras Pneumol* 2011;37:636-45. doi: 10.1590/S1806-37132011000500011
3. do Prado TN, Galavote HS, Brioshi AP, Lacerda T, Fregona G, Detoni Vdo V, Lima Rde C, Dietze R, Maciel EL. Epidemiological profile of tuberculosis cases reported among health care workers at the University Hospital in Vitoria, Brazil. *J Bras Pneumol* 2008;34:607-13. doi: 10.1590/S1806-37132008000800011
4. Fronteira I, Ferrinho P. Do nurses have a different physical health profile? A systematic review of experimental and observational studies on nurses' physical health. *J Clin Nurs* 2011;20:2404-24. doi: 10.1111/j.1365-2702.2011.03721
5. Wanjari K, Baradkar V, Mathur M, Kumar S. A case of tuberculous pericardial effusion. *Indian J Med Microbiol* 2009;27:75-7. PMID: 19172070
6. Lalić H, Kukuljan M, Đindić Pavičić M. A case report of occupational middle ear tuberculosis in a nurse. *Arh Hig Rada Toksikol* 2010;61:333-7. doi: 10.2478/10004-1254-61-2010-2034
7. Fader T, Parks J, Khan NU, Manning R, Stokes S, Nasir NA. Extrapulmonary tuberculosis in Kabul, Afghanistan: a hospital-based retrospective review. *Int J Infect Dis* 2010;14:e102-10. doi: 10.1016/j.ijid.2009.03.023
8. Bolt RJ, Rammeloo LA, van Furth AM, van Well GT. A 15-year-old girl with a large pericardial effusion. *Eur J Pediatr* 2008;167:811-2. doi: 10.1007/s00431-007-0559-z
9. Register of Occupational Diseases, Croatian Institute for Health Protection and Safety at Work [displayed 19 May 2014]. Available at <http://hzzzsr.hr/?what=content&ID=70&cat=68>
10. Bogadi-Šare A. Profesionalne bolesti zdravstvenih radnika u Republici Hrvatskoj [Occupational disease of health workers in the Republic of Croatia, in Croatian]. [displayed 19 May 2014]. Available at <http://www.hzzzsr.hr/images/documents/Skupovi%20i%20izobrazba/Skupovi%20doma%C4%87i/4.%20SIMPOZIJ%20HRVATSKE%20LIJE%C4%8CNI%C4%8CKE%20KOMORE/Profesionalne%20bolesti%20zdravstvenih%20radnika.pdf>
11. Jesudas CD, Thangakunam B. Tuberculosis risk in health care workers. *Indian J Chest Dis Allied Sci* 2013;55:149-54. PMID: 24380222
12. Karstaedt AS. Extrapulmonary tuberculosis among adults: experience at Chris Hani Baragwanath Academic Hospital, Johannesburg, South Africa. *S Afr Med J* 2013;104:22-4. doi: 10.7196/samj.6374
13. Solovic I, Jonsson J, Korzeniewska- Kosela M, Chiotan DI, Pace-Asciak A, Slump E, Rumetshofer R, Abubakar I, Kos S, Svetina-Sorli P, Haas W, Bauer T, Sandgren A, van der Werf MJ. Challenges in diagnosing extrapulmonary tuberculosis in the European Union, 2011. *Eurosurveillance* 2013 [displayed 19 May 2014]. Available at: <http://www.eurosurveillance.org/ViewArticle.aspx?ArticleId=20432>
14. Suman A, Sarin JL, Grant SC, Bazaraa TA. A case of tuberculous pericardial effusion. *Age Ageing* 2003;32:450-2. doi:10.1016/S2222-1808(13)60031-6
15. Sandgren A, Hollo V, van der Werf MJ. Extrapulmonary tuberculosis in the European Union and European Economic Area, 2002 to 2011. *Eurosurveillance* 2013; [displayed 19 May 2014]. Available at: <http://www.eurosurveillance.org/ViewArticle.aspx?ArticleId=20431>
16. Avşar A, Günay NK, Celik A, Melek M. A case of cardiac tamponade caused by tuberculous pericarditis. *Turk Kardiyol Dern Ars* 2008;36:482-4. PMID: 19155666
17. Afzal A, Keohane M, Keeley E, Borzak S, Callender CW, Iannuzzi M. Myocarditis and pericarditis with tamponade associated with disseminated tuberculosis. *Can J Cardiol* 2000;16:519-21. PMID: 10787468
18. Russell JB, Syed FF, Ntsekhe M, Mayosi BM, Moosa S, Tsifularo M, Smedema JP. Tuberculous effusive-constrictive pericarditis. *Cardiovasc J Afr* 2008;19:200-1. PMID: 18776964
19. Caroselli C, Manara F, Bruno G. Coming from the past: Tuberculous chronic constrictive pericarditis. *Am J Med Sci* 2011;341:233. PMID: 21446080
20. Targowski T, Chelstowska S, Plusa T. Tuberculin skin test and interferon- γ release assay in the detection of latent tuberculosis infection among Polish health care workers. *Pol Arch Med Wewn* 2014;124:36-42. PMID: 24343239

Sažetak**Perikardijalni izljev kao prva manifestacija profesionalne tuberkuloze u zdravstvenog radnika**

Tuberkuloza (TBC) zarazna je bolest, stoga je prijeko potrebno zaštititi ne samo bolesnike nego i osoblje koje dolazi u kontakt s njima, u prvom redu medicinske sestre i liječnike. Nakon kontakta s bolesnicima oboljelima od TBC-a (u kulturama pozitivne) 43-godišnji imunokompetentni medicinski tehničar, zaposlen u psihijatrijskoj bolnici, obolio je od profesionalnog diseminiranog TBC-a. Prva manifestacija bolesti bio je eksudativni perikarditis s dokazanim *Mycobacterium tuberculosis* (MT), dva mjeseca nakon perikardiocenteze i evakuacije 1200 mL perikardijalnog izljeva. Histološki nalaz limfnih čvorova na više lokalizacija pokazivao je granulomatoznu upalu s nekrozom. Liječenje antituberkuloticima bilo je praćeno komplikacijama. Došlo je do prolaznog, kratkotrajnog, medikamentozno toksičnog hepatitisa, dugotrajnog febriliteta, nespecifičnog ljevostranog pleuralnog izljeva i mononeuritisa desnog peronealnog živca. Liječenje je trajalo 14 mjeseci. Kao trajna posljedica razvio se fibrotoraks, koji je doveo do restriktivnih smetnji ventilacije i smanjene difuzije alveolarno-kapilarne membrane. Ovaj slučaj upozorava na potrebu poboljšanja zaštite zdravstvenih radnika koji su u kontaktu s oboljelima od tuberkuloze, kao i korisnost tuberkulinskog kožnog testa i QuantiFERON-TB testa, koji mogu rano otkriti latentni TBC.

KLJUČNE RIJEČI: *antituberkulotici; diseminirana tuberkuloza; ekstrapulmonalna tuberkuloza; nozokomijalna bolest; profesionalna bolest; tuberkulozni perikarditis*

CORRESPONDING AUTHOR:

Veljko Flego
Department of Pulmonology
Clinical Hospital Centre Rijeka
Tome Strižića 3, HR-51000 Rijeka, Croatia
E-mail: veljko.flego@medri.uniri.hr