

Josipa Dičak, Zrinka Tarle, Alena Knežević

Vizualno – taktilna detekcija karijesa u usporedbi s laserskom fluorescencijom

Visual - Tactile Caries Detection in Comparison with Laser Fluorescence

Zavod za endodonciju i restaurativnu stomatologiju Stomatološkog fakulteta Sveučilišta u Zagrebu
Department of Endodontics and Restorative Dentistry, University of Zagreb School of Dental Medicine

Sažetak

Suvremeni stomatološki načini liječenja karijesa zahtijevaju znatno specifičnije i osjetljivije postupke detekcije karijesa, nego što je to konvencionalan vizualno – taktilni pristup. Nerijetko se čak uklanja zdravo tkivo zbog lažno – pozitivne dijagnoze, ili je pak lezija nedostatno rano detektirana. Zato lasersko-dijagnostički uređaj DIAGNOdent (KaVo, Dental GmbH, Njemačka) predstavlja važan preokret. On se odlikuje visokim stupnjem preciznosti, mjerenja se mogu ponavljati, jednostavan je, neštetan, a osigurava dugotrajno praćenje lezija jer rezultate izražava kvantitativno. Svrha istraživanja bila je usporedba vizualno - taktilne detekcije karijesa s laserskom fluorescencijom. Od ukupno 960 zuba, karijes je dijagnosticiran uređajem DIAGNOdent kod 90 (9,4%), a vizualno – taktilnim pristupom ustanovljen je na 58 zuba (6%). Potpuno neslaganje zabilježeno je u 3,54% slučajeva. Više od polovice nepoznatih karijesa u vizualno – taktilnom pristupu, ubraja se u kategoriju karijesa površine cakline (vrijednost na DIAGNOdentu 14 - 20). McNemarim testom ustanovljeno je da postoje statistički znatne razlike između procjene karijesa DIAGNOdentom i vizualno-taktilnim pristupom.

Zaprimljen: 14. veljače 2007.

Prihvaćen: 13. travnja 2007.

Adresa za dopisivanje

Prof. dr. sc. Zrinka Tarle
Sveučilište u Zagrebu
Stomatološki fakultet
Zavod za endodonciju i restaurativnu
stomatologiju
Gundulićeva 5, 10000 Zagreb
tarle@sfzg.hr

Ključne riječi

zubni karijes; laseri

Uvod

Moderni koncepti i smjer razvoja današnje stomatologije temelje se na ranom prepoznavanju i liječenju karijesa. Takav pristup zahtijeva razumijevanje dinamike fizikalno – kemijskih reakcija u početnim stadijima bolesti, budući da se novi terapijski postupci temelje na čuvanju tvrdih zubnih tkiva i iskorištavanju remineralizacijskog potencijala (1).

Iako je u razvijenim zemljama preventivnim postupcima znatno smanjen udio karijesa u populaciji, karijes u fisurnom sustavu okluzijskih ploha i dalje je velik problem. Postaviti ranu dijagnozu postaje znatno složenije, a klasični dijagnostički postupak često daje lažne negativne ili lažne pozitivne rezultate.

Introduction

Modern concept and the course of today's dentistry are based on early detection and prompt caries treatment. This approach seeks understanding of the dynamics in physico-chemical processes in the early stages of the disease due to the fact that new therapeutic procedures are based on conservation of hard dental tissues and usage of the remineralisation potential (1).

Although it is a common fact that ratio of caries in developed countries has decreased markedly by preventive measures, it occurs that caries of the occlusal fissures still represents a significant problem. Making an early diagnosis becomes more complex, and conventional methods of caries detection often lead to false – negative or false – positive results.

Glavna dijagnostička sredstva u svakodnevnoj stomatološkoj praksi - sonda i stomatološko zrcalo, to jest vizualno - taktilni postupak, ne jamče da će se uočiti najranije karijesne lezije. Osnovne promjene na površini cakline u ranoj fazi rezultat su demineralizacijskog procesa i vidljive su na mikroskopskoj razini. S druge strane, prateća remineralizacija u pojedinim vremenskim razmacima može biti i dominirajući proces (2). Nastale strukturne nepravilnosti u leziji zahtijevaju znatno osjetljivije dijagnostičke postupke. Oni uključuju precizne sustave za mjerenje električne otpornosti tkiva te laserske sustave koji se temelje na fluorescenciji zubnih tkiva (3-5).

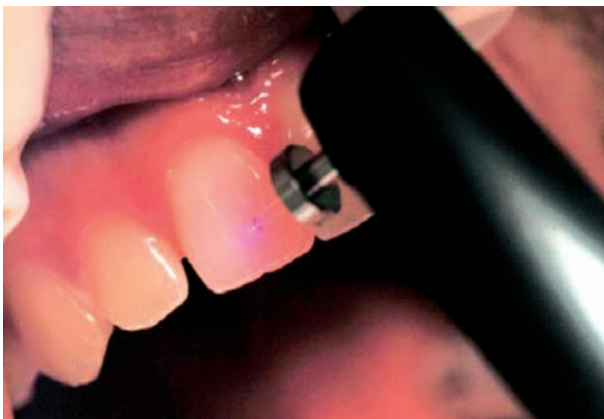Materijali i postupci

Svrha istraživanja bila je usporediti točnost dijagnoze karijesa okluzijskih ploha uređajem DIAGNOdent (KaVo, Dental GmbH, Njemačka), u odnosu prema konvencionalnom vizualno - taktilnom dijagnostičkom postupku. U ispitivanju je sudjelovalo 30 ispitanika. Bili su obaviješteni o zadatku istraživanja te su svi potpisali pristanak. Mjerenja su obavljena na 960 zuba, uglavnom premolara i molara. Nakon procjene ima li karijesnih lezija različitog stupnja vizualno – taktilnim postupkom, to jest uporabom stomatološkog zrcala i sonde, na suspektnim je zubima obavljeno mjerenje uređajem DIAGNOdent. Neposredno prije mjerenja, zubi su profesionalno očišćeni uređajem PROPHYFlex 3 (KaVo Dental GmbH, Njemačka). DIAGNOdent je prije mjerenja kalibriran na keramičkoj pločici, a nakon toga prilagođen svakom ispitaniku. Individualna prilagodba sastojala se od mjerenja osnovne fluorescencije zdravog zuba, najčešće labijalne plohe centralnog inciziva. Dobiveni rezultat oduzeo se

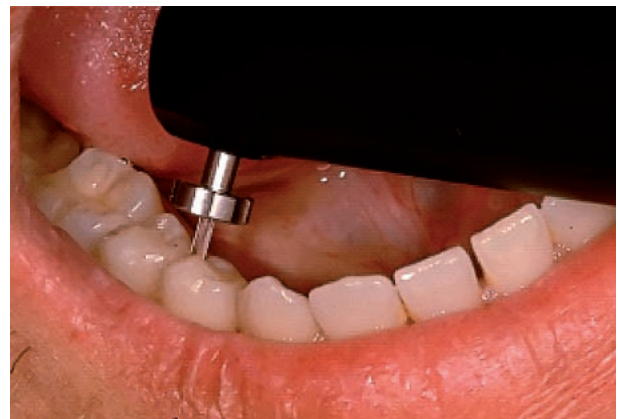Commonly used instruments in everyday practice – dental explorer and mirror, or visual-tactile diagnostic method, do not guarantee the detection of the earliest caries lesions. Basic changes of the enamel surface in the early stage of the disease are the result of demineralisation process visible on a microscopic level. On the other hand, in some periods of time the following remineralisation can be a dominant process in the lesion (2). Structural anomalies of the lesion are formed by these interchanging processes, and demand highly sensitive diagnostic methods. This includes systems that are based on electric resistance measurement, and laser fluorescence based systems. (3-5).

Materials and methods

The purpose of this study was comparison of occlusal caries detection by conventional visual - tactile diagnostic method and DIAGNOdent (KaVo, Dental GmbH, Germany) device. The investigation comprised 30 patients, of age 5 to 50, who were informed of the study's purpose, and their written consent was obtained. A total of 960 teeth were included in the study. After the assessment of caries lesions by visual-tactile examination, the suspected teeth were also examined by DIAGNOdent device. Prior to laser measurement, the investigated teeth were professionally cleaned by PROPHYFlex 3 (KaVo Dental GmbH, Germany) device. DIAGNOdent was calibrated with a ceramic standard and then customised according to individual patient. The individual adjustment was made by measuring a baseline fluorescence value of a healthy tooth surface, in most cases labial surface of the central incisor. The value was then subtracted from the fluorescence of the suspected teeth. The measurement



Slika 1. Individualna prilagodba DIAGNOdent uređaja.
Figure 1 Individual adjustment of DIAGNOdent unit.



Slika 2. Detekcija karijesa DIAGNOdent uređajem.
Figure 2 Caries detection by DIAGNOdent unit.

od očitano rezultata na ispitivanim zubima. Mjerenje je obavljeno u uvjetima suhog radnog polja, kao što je preporučio proizvođač.

Rezultati

Uzorak je činilo 960 zuba 30 ispitanika kod kojih je karijes dijagnosticiran na dva načina: vizualno – taktilno te uređajem DIAGNOdent. Vrijednosti očitane DIAGNOdentom transformirane su za potrebe statističke analize u dvije nominalne kategorije (0 – nema karijesa i 1 – karijes) i u četiri ordinalne kategorije (0 – nema karijesa, 1 – karijes površine cakline, 2 – karijes do CDS-a i 3 – karijes dentina - Tablica 1.). Kao granična vrijednost na uređaju DIAGNOdent, kako bi se zaključilo postoji li karijes, uzeta je vrijednost 13 (3). Kako su promatrane varijable uglavnom bile kategorijalne, koristili su se postupci neparametrijske statistike (McNemar test i Phi coefficient) uz razinu znatnosti od 95%, a statistička analiza obavljena je u softveru SPSS 10.0 (SPSS Inc. Chicago, IL, Sjedinjene Države).

was carried out in dry conditions, as suggested by the manufacturer.

Results

The sample of 960 teeth from 30 patients was used to investigate the existence of caries lesions by two methods; visual-tactile and by DIAGNOdent device. In order to make statistical analysis DIAGNOdent values were transformed in two nominal categories (0 – no caries and 1 – caries), and four ordinal categories (0 – no caries, 1 – enamel surface caries, 2 – caries up to EDJ; 3 – dentine caries (Table 1)). The borderline DIAGNOdent value for caries was considered 13 (3). The methods of non-parameter statistic analysis (McNemar's test and Phi coefficient) with significance level of 95% were used, while the observed variables were mostly categorical. The statistical analysis was made in SPSS 10.0 software (SPSS Inc. Chicago, IL, USA).

Tablica 1. Kriteriji u detekciji karijesa DIAGNOdentom (3)
Table 1 Caries Criteria assessed by DIAGNOdent (3)

Kod • Code	Kriterij • Criteria	Dijagnoza • Diagnosis
0	< 13	nema karijesa • no caries
1	14-20	karijes površine cakline • enamel surface caries
2	21-29	karijes do CDS-a • caries up to EDJ
3	>30	karijes dentina • dentine caries

Od ukupno 960 zuba, uređajem DIAGNOdent karijes je dijagnosticiran na 90 zuba (9,4%), a vizualno – taktilnim pristupom ustanovljen je na 58 zuba (6%) - Tablica 2., Slika 3. – uglavnom kod premolara i molara. Vizualno – taktilna dijagnostika i dijagnostika DIAGNOdentom u 90,52% slučajeva pokazuju podudarnost da karijesa nema te za 5,94% slučajeva da karijes postoji. Omjer stvarnog slaganja je 96,46%, a omjer slučajnog slaganja 85,73%. Apolutno neslaganje zabilježeno je kod 3,54% slučajeva. Više od polovice vizualno – taktilnim pristupom neprepoznatih karijesa je iz kategorije karijesa površine cakline (DIAGNOdent vrijednosti 14 - 20). Iako Phi koficijent upućuje na korelaciju između dvaju postupaka procjene (0,773; $p < 0,001$), McNemarim testom je ustanovljeno da postoje statistički znatne razlike između procjene karijesa DIAGNOdentom i vizualno-taktilnim postupkom (28,265; $p < 0,001$). Isto su tako signifikantne razlike u dijagnostici karijesa između obaju pristupa i na

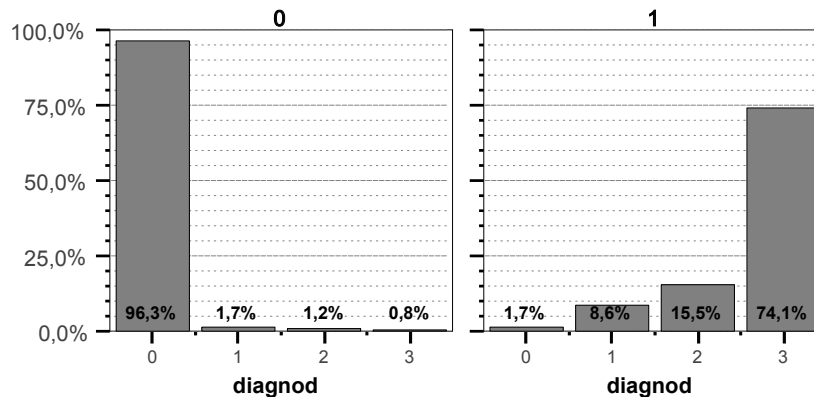
Out of 960 teeth, caries was diagnosed in 90 teeth (9,4%) using DIAGNOdent. Using the visual – tactile method, dental caries was diagnosed in 58 teeth (6%), mostly premolars and molars (Table 2, Figure 3). Visual – tactile and DIAGNOdent agree in the non-existence of caries in 90,52%, and in 5,94% in the existence of caries. True agreement ratio is 96,46%, while accidental agreement ratio is 85,73%. Absolute disagreement was found in 3,54% cases. Over 50% of caries lesions that were undetected by visual-tactile examination are considered to be enamel surface caries lesions according to DIAGNOdent readings (values range from 14 to 20). Although Phi coefficient indicates a high correlation between the two methods (0,773; $p < 0,001$), the McNemar's test pointed out a statistically significant difference in caries detection by visual - tactile examination and DIAGNOdent measurement (28,265; $p < 0,001$). The similar differences between two methods were established in diagnosis between

Tablica 2. Slaganje vizualno – taktilnog i DIAGNOdent postupka
Table 2 Visual – tactile and DIAGNOdent agreement in detection of caries

			DIAGNOdent						
			0	1	2	3	Ukupno • Total 1+2+3	Ukupno • Total	
Vizualno -taktilno • Visual - tactile	0	N % Viz.-takt. • Vis. – tact. % DIAGNOdent	869 96,3% 99,9%	15 1,7% 75,0%	11 1,2% 55,0%	7 0,8% 14,0%	33 3,7% 36,7%	902 100,0% 94,0%	
	1	N % Viz.-takt. • Vis. – tact. % DIAGNOdent	1 1,7% 0,1%	5 8,6% 25,0%	9 15,5% 45,0%	43 74,1% 86,0%	57 98,3% 63,3%	58 100,0% 6,0%	
	Ukupno • Total	N % Viz.-takt. • Vis. – tact. % DIAGNOdent	870 90,6% 100,0%	20 2,1% 100,0%	20 2,1% 100,0%	50 5,2% 100,0%	90 9,4% 100,0%	960 100,0% 100,0%	

Legenda • Legend:

Taktilno • Tactile: 0 – nema karijesa • no caries; 1 – karijes • caries. DIAGNOdent: 0 – nema karijesa • no caries; 1 – karijes površine cakline • enamel surface caries; 2 – karijes do CDS-a • caries up to EDJ; 3 – karijes dentina • dentine caries; Ukupno 1+2+3 • Total 1+2+3 – zbroj karijesa dijagnosticiranih DIAGNOdentom • sum of caries detected by DIAGNOdent.



Slika 3. Slaganje vizualno – taktilnog i DIAGNOdent postupka u detekciji karijesa (slika lijevo za kategoriju nema karijesa detektiranog vizualno - taktilno, a desno za kategoriju karijes).

Figure 3 Visual – tactile and DIAGNOdent agreement in detection of caries (left figure for category no caries diagnosed by visual-tactile method, and right figure for caries diagnosed).

lijevoj i na desnoj strani, te u gornjoj i u donjoj čeljusti, kao i kod pojedine vrste zuba osim kod inciziva, gdje razlika između pristupa nije značajna ($p=0,125$, Tablica 3., Slika 4.).

Ispitivanje je proveo jedan ispitivač čija je reproducibilnost u detekciji vizualno-taktilnim pristupom provjerena prije početka ispitivanja. On je dva puta u razmaku od sedam dana pregledao zube sedmero ispitanika.

Omjer stvarnog slaganja iznosio je 96%. Interklasni korelacijski koeficijent bio je 0,86 ($p<0,001$), a Cohenov kapa upozorava da se radi o znatnoj podudarnosti ($\kappa=0,75$; $p<0,001$).

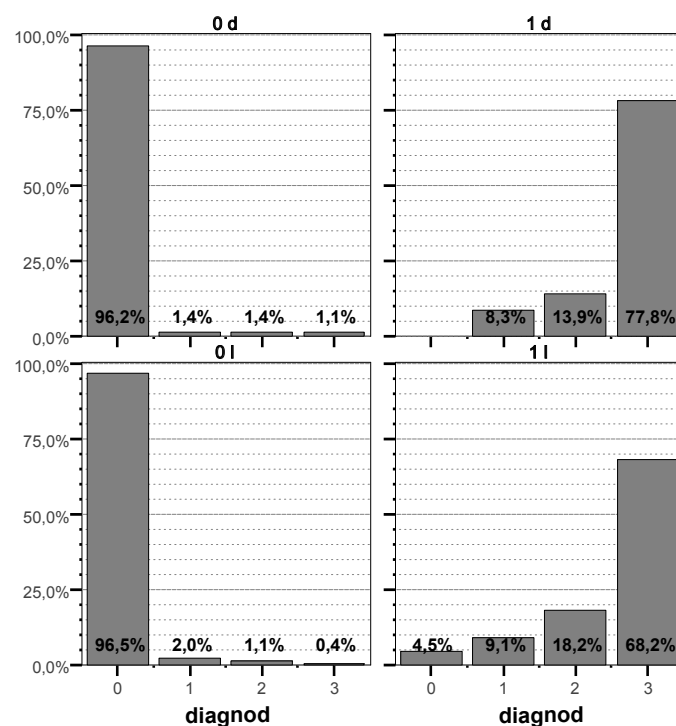
the right and the left side, and between the upper and the lower jaw, and also between different teeth groups, besides incisors- in which there was no significant difference between the methods ($p=0,125$, Table 3, Figure 4).

A single investigator, who had been calibrated prior to the commencement of the study, collected all clinical data. The intra-examiner reliability was evaluated by means of repeated visual-tactile assessment of decay with a 7-day interval from the first examination. The proportion of agreement was 96%. Intraclass correlation coefficient was 0,86 ($p<0,001$) and Cohen Kappa 0,75 ($p<0,001$). Tests showed significant reproducibility and respectable agreement.

Tablica 3. Slaganje vizualno – taktilnog i DIAGNOdent postupka
Table 3 Visual – tactile and DIAGNOdent agreement in detection of caries

Kriterij • Criteria	VIZ.-TAKT. • VIS. – TACT.	DIAGNOdent			p*
		0	1	Ukupno • Total	
Incizivi • Incisors	0	218	6	224	0,125
	1	1	15	16	
	Ukupno • Total	219	21	240	
Kanini • Canines	0	110	7	117	0,016
	1	0	3	3	
	Ukupno • Total	110	10	120	
Premolari • Premolars	0	216	11	227	<0,001
	1	0	13	13	
	Ukupno • Total	216	24	240	
Molari • Molars	0	325	9	334	<0,001
	1	0	26	26	
	Ukupno • Total	325	35	360	
Maksila • Maxilla	0	434	17	451	<0,001
	1	0	29	29	
	Ukupno • Total	434	46	480	
Mandibula • Mandibula	0	435	16	451	<0,001
	1	1	28	29	
	Ukupno • Total	436	44	480	
Desno • Right	0	427	17	444	<0,001
	1	0	36	36	
	Ukupno • Total	427	53	480	
Lijevo • Left	0	442	16	458	<0,001
	1	1	21	22	
	Ukupno • Total	443	37	480	

* McNamarin test • McNamar`s test: 0 – nema karijesa • no caries; 1 – karijes • caries



Slika 4. Slaganje vizualno – taktilnog i DIAGNOdent postupka na lijevoj (0l i 1l) i desnoj strani čeljusti (0d i 1d).
Figure 4 Visual – tactile and DIAGNOdent agreement in detection of caries on left (0l and 1l) and right jaw side (0d and 1d).

Rasprava

Suvremeni stomatološki koncepti primarno su usmjereni na biološku zaštitu zuba. To uključuje i karijesne lezije u ranom stadiju, kada je moguće zaustaviti proces i potaknuti remineralizaciju lezije (6). Kod manjih oštećenja preporučuje se atraumatska i minimalno - invazivna terapija (7). Kako bi se zadovoljili ti zahtjevi, najvažnija je točna i rana dijagnoza. Konvencionalni dijagnostički postupak temelji se na vizualno – taktilnoj procjeni. Nažalost, osjetljivost takvog postupka ne odgovara potpuno zahtjevima moderne stomatologije. Često su lažno negativni rezultati uvjetovani morfoloijom fisurnoga sustava, ali i intenzivnom fluoridacijom, te je osigurano stvaranje otpornih kristala fluorapatita na površini lezije. Kristalni fluorapatiti uvjetuju prividnu stabilnost površine i odgađaju kavitaciju, pa karijesni proces nesmetano napreduje u dubinu. Osim toga, zabilježeno je i kako pritiskom sonde na nekavitiranu leziju često dolazi do njezina atrogenog produblivanja (8), što je suprotno načelima biološke zaštite tvrdih zubnih tkiva. Nedostaci konvencionalnog dijagnostičkog postupka mogu se poboljšati budu li se koristili novi, osjetljiviji dijagnostički postupci u svakodnevnoj stomatološkoj praksi.

Uređaj koji je u komercijalnoj uporabi, a radi na načelu laserske fluorescencije, jest DIAGNOdent (KaVo, Dental GmbH, Njemačka). Pogodan je za svakodnevni rad, neinvazivan, brz i jednostavan. Pokazao se kao izvrsna dopuna klasičnom dijagnostičkom postupku, a kvantitativno izražavanje dobivenih rezultata omogućuje i dugotrajno praćenje lezija te se možemo uvjeriti u uspješnost primijenjenih preventivnih postupaka (9). DIAGNOdent reagira već i na najmanje promjene u građi cakline nastale demineralizacijom, pa se preventivni postupci temeljeni na remineralizaciji mogu primijeniti u fazi kada su potpuno učinkoviti. Načelo rada uređaja je na mjerljivoj razlici između fluorescencije intaktne cakline prema onoj zahvaćenoj karijesom. Osnovu fluorescencije zdrave cakline čine anorganske komponente tkiva, a u manjoj mjeri i organske. Kod karijesom zahvaćenih tvrdih zubnih tkiva za fluorescenciju se odgovornima smatraju produkti bakterijskog metabolizma - porfirini. Oni se sintetiziraju i ostaju u leziji, mijenjajući osnovnu fluorescenciju tkiva. Molekule porfirina pokazuju maksimum apsorpcije u crvenom dijelu spektra, a primljenu energiju emitiraju blizu infracrvenog zračenja (10). Te su spoznaje temelj rada DIAGNOdenta. Osnovu uređaja čini laserska dioda koja služi kao izvor koherentnoga monokromatskog zračenja

Discussion

The modern concepts in dentistry are primarily oriented on the biological conservation of the tooth. This includes recognizing the carious changes in the early stages, when it is possible to terminate the progression of the process and to stimulate the remineralization of the lesion (6). In more extended lesions non - traumatic and minimally - invasive therapeutic procedures are recommended (7). Accurate and prompt diagnosis is crucial in order to satisfy these requirements. The conventional diagnostic procedure is commonly based on visual - tactile caries assessment. Unfortunately, the sensitivity of such procedure is inadequate to fulfil the requirements of modern dentistry. The false - negative results are often determined by the morphology of the fissures system, and also by the intensive fluoridation measures, that cause the formation of highly resistant crystals of flour-apatite on the surface of the lesion. These crystals cause an illusively stable enamel surface and the delay of cavitation, while the disease progresses un-interfered in the deeper parts of the tooth. It is also recorded that the pressure of the dental probe on such non-cavitated lesion can artificially increase the lesion's depth (8), which stands against the principles of the biological conservation of the hard dental tissues. The imperfections of the classical diagnostic procedure can be successfully improved by introducing new, more sensitive diagnostic tools in everyday practice.

The device that is in commercial use, and that is based on the laser fluorescence principles is DIAGNOdent (KaVo, Dental GmbH, Germany). It is suitable for everyday practice, non-invasive, fast and simple. It has proven to be an excellent supplementation to the conventional diagnostic tools, and the quantitative expression of the results allows the long-term monitoring of the lesions and suspected areas, and evaluation of the effectiveness of the preventive measures (9). DIAGNOdent reacts even to the slightest changes in the enamel structure caused by demineralisation, so preventive procedures can be used in the stage when they are completely effective. The instrument is based on different fluorescence levels between sound tissue and the infected one. The baseline fluorescence of the sound enamel is the result of combining the inorganic matrix with small amount of organic molecules. In caries lesions, fluorescence is probably based on porphyrines – molecules that are synthesised in the lesion as products of bacterial metabolism, changing the basic fluorescence level. The porphyrine molecules show the maximal absorption in the red-excitation light. They produce fluorescence in the near-in-

valne duljine 655 nm. Zračenje se na površinu zuba prenosi optičkim vlaknom, čime se ispitivane molekule potiču da emitiraju povratno zračenje različitih valnih duljina natrag u uređaj. Dakle, na radnom se nastavku nalazi i detekcijski dio koji se također sastoji od sustava optičkih vlakana. Dobivene vrijednosti emitirane s površine zuba uređaj izražava kvantitativno, što je lako razumljivo svakom terapeutu. U mnogobrojnim istraživanjima na modelima *in vivo* i *in vitro* (3,4,11-15) ustanovljene su granične vrijednosti koje odgovaraju pojedinim stupnjevima karijesa, a u skladu s tim izrađene su i terapijske smjernice (4).

Posebna prednost uređaja je mogućnost prilagodbe za svakog pacijenta, pa čak i za pojedini zub. Na taj su način osigurani potpuno objektivni rezultati mjerenja. DIAGNOdent je opremljen dvjema vrstama radnih vršaka posebno oblikovanih za okluzijske i glatke, odnosno aproksimalne plohe (za mjesta, dakle, s najvećim rizikom razvoja karijesa). Tijekom mjerenja potrebno je osigurati blizak kontakt s površinom te pomicati i blago naginjati instrument, kako bi ispitana površina bila što veća. Bilježi se trenutni rezultat te najveći postignuti rezultat. Ako ima velikih promjena, javlja se zvučni signal koji mijenja jakost i frekvenciju. Na taj se način alarmira ne samo terapeut, nego i pacijent te on tako aktivno sudjeluje u pregledu. Posebice je koristan u praćenju promjena tijekom razdoblja mješovite i rane trajne denticije (16, 17).

Vrijednosti iznad 30 zahtijevaju klasične terapijske postupke, uz prednost minimalno - invazivnom pristupu i intenzivnim mjerama profilakse (3).

Poznate su svakodnevne nedoumice u dijagnostici karijesa, posebice u fisurnom sustavu. Osnovni nedostatak vizualno - taktilnog postupka je postavljanje rane dijagnoze, što je vrlo važno kako bi bio primijenjen minimalno invazivni terapijski postupak. To ispitivanje pokazalo je kako je polovica karijesa, neprepoznatih klasičnim pristupom, prema vrijednostima na DIAGNOdentu, bila u kategoriji karijesa površine cakline. Iako razlika u pristupima kod dijagnoze karijesa na incizivima nije signifikantna, većina je lezija bila na premolarima i molarima, pa je i stvarni omjer neslaganja točniji u toj kategoriji. McNemarinim testom utvrđeno je da postoje statistički znatne razlike između procjene karijesa DIAGNOdentom i vizualno-taktilnim postupkom. Unatoč tome, ispitivanje je pokazalo veliku podudarnost između pristupa (96,46%), vjerojatno i zbog temeljitog pregleda ispitivača, čime je veći broj suspektnih lezija uvršten u kategoriju karijesa.

frared spectra (10). These findings are the basis for the DIAGNOdent device. The instrument contains a laser photo diode (wavelength = 655 nm) as the coherent monochromatic light source. The excitation light is transmitted to the tooth surface by an optical fibre, causing the excitation of the molecules and resulting in emitting the fluorescent radiation back into the device. It is obvious that the same device simultaneously performs the excitation and the detection of the radiation. The detection part of the instrument also consists of optical fibres. The values gathered from the examined surface are expressed in quantitative form, easily understood by any operator. According to numerous researches on *in vitro* and *in vivo* models (3, 4, 11-15), borderline values for specific caries stages are determined, and according to these values different therapeutic procedures are advised (4).

An important advantage of the instrument is the possibility of individual adjustment. It is also possible to customise the device according to a specific tooth. This ensures completely objective measuring results. DIAGNOdent is equipped with two types of working tips: specially designed for occlusal and smooth, approximal surfaces (which represent the highest caries-risk spots). In order to ensure maximal surface examination, the examiner must keep the operating tip as close to the tooth as possible, and tilt the instrument along the measuring site. The moment value in real time, and also the peak value are recorded. When significant values are reached a tone with altering frequency and rising intensity is emitted. This sound alarms not only the therapist, but the patient as well, making him an active participant in the procedure. During the periods of mixed and early permanent dentition DIAGNOdent can help considerably in order to monitor the suspected sites (16, 17).

Values over 30 require an operative intervention, with emphasis on minimally - invasive treatment and intensive prophylactic procedures (3).

In everyday practice fissure and approximal caries can be easily overlooked, or falsely diagnosed. Basic flaw of the visual-tactile method is in making an early diagnosis, which is of great importance in order to use a minimal- invasive therapeutic procedure. This research has shown that half of the caries unidentified by conventional method falls into surface caries category according to DIAGNOdent values. Although the difference between two methods in diagnosing caries on the incisors wasn't significant, most of the lesions were on premolars and molars, so that true disagreement was more accurate in this category (96, 46%). However, the research has

Nerijetko se terapeut suočava s činjenicom da je uklonio potpuno zdravo tkivo, iako se vizualno, pa i taktilno, činilo da je riječ o karijesnoj leziji. Upravo u takvim dvojbjenim situacijama DIAGNOdent se nameće kao idealan sustav. Osim toga, dobivena očitavanja automatski usmjeravaju daljnji smjer terapije. Time se stvara zaokružen dijagnostičko - terapijski model.

Terapija, kojom se za kratko vrijeme prekida napredovanje karijesnog procesa i potiče remineralizacija lezije, prava je inovacija u stomatologiji. Riječ je o terapiji ozonom, koja zadovoljava sve zahtjeve moderne stomatologije – učinkovita je, brza, jednostavna, neštetna, atraumatska i prilagođena pacijentima bez obzira na dob. Terapija se temelji na izlaganju zahvaćenog zuba kontroliranoj dozi ozona. Uređaj u komercijalnoj uporabi, a koji osigurava sintezu i aplikaciju plina, naziva se HealOzone (KaVo, Dental GmbH, Njemačka). Ozon je poznato virucidno, baktericidno i fungicidno sredstvo, čije se djelovanje temelji na rupturi bioloških membrana mikroorganizama, osiguravajući dugotrajan dezinfekcijski učinak (18). To je u cijelosti nov, etiološki pristup problematici karijesa i znatno odstupa od konvencionalnih traumatskih terapijskih postupaka. Cijeli se postupak obavlja u strogo kontroliranim uvjetima. Brzo i dugotrajno djelovanje osigurava eliminaciju glavnoga kariogenog mikroorganizma *S. mutans* tijekom više mjeseci (19).

HealOzone koristi se kao samostalno preventivno i terapijsko sredstvo ili kao dopuna minimalno invazivnim i klasičnim restaurativnim postupcima. Moderan pristup uključuje ranu lasersku dijagnozu karijesa te terapiju ozonom prema standardima.

Zaključak

Zahtjevi suvremene stomatologije za što ranije liječenje karijesnih lezija prije kavitacije, te dostupnost biološki usmjerenih neinvazivnih i minimalno invazivnih terapijskih postupaka, uvjetovani su ponajprije točnim, pravodobnim i visokoosjetljivim dijagnostičkim postupcima. Vizualno - taktilni pristup često se pokazao nedostatnim u ranom otkrivanju karijesne lezije. Novi sustavi na načelima laserske fluorescencije, u svakodnevnoj stomatološkoj praksi imaju sve širu primjenu kao dodatno dijagnostičko sredstvo zahvaljujući jednostavnosti, učinkovitosti, mogućnosti ponavljanja mjerenja, neinvazivnosti i osiguranju praćenja pojedinih lezija tijekom određenoga razdoblja.

shown a significant correlation between these methods, also probably because of the precise examination by the investigator, who marked great number of suspected sites as "caries".

Unfortunately, falsely diagnosed caries leads practitioners into removing healthy tissue and making the unnecessary damage to the tooth structure, although visual and tactile examination confirmed the existence of the disease. Specifically in these situations, the DIAGNOdent could be the ideal doubt-removing tool. At the same time, the practitioner is automatically guided into the right therapeutic procedures. These facts ensure the establishment of a complete diagnostic - therapeutic system.

The existence of therapy that is able to terminate the progression of caries in short time and to induce remineralisation at the same time makes quite a revolution in dentistry. Ozone therapy meets all the requirements of modern dentistry – it is efficient, fast, simple, safe, non-traumatic, and suitable for patients regardless to their age. The therapy is based on the tooth exposure to a controlled dose of ozone gas. The device in commercial use is called HealOzone (KaVo, Dental GmbH, Germany). Ozone is a well-known virucide, bactericide and fungicide, basing its action on the rupture of cell membranes and walls, ensuring a long-lasting disinfection effect (18). The whole procedure is performed in a strictly controlled environment. Rapid and long-lasting action ensures the elimination of the leading cariogenic microorganism *S. mutans* through several months (19).

HealOzone can be used as an independent preventive and therapeutic unit, or as a supplement to minimally - invasive and classical operating procedures. The modern approach includes early laser-based caries diagnose and ozone treatment carried out according to previously established guidelines.

Conclusion

The aims of modern dentistry for early treatment of caries lesions, before cavity formation and accessibility of biologically based non-invasive and minimally invasive therapeutic methods are primarily preconditioned by accurate, punctual and highly sensitive diagnostic methods. Visual – tactile method often seems insufficient in early lesion detection. New instruments, based on the principles of laser fluorescence, have found their place in everyday practice as useful supplementary method, due to simplicity, effectiveness, reproducibility, non – invasive approach, and ability for lesion monitoring in long-term periods. Usage of new diagnostic

Uporabu novih dijagnostičkih i terapijskih postupaka prate i promjene u načinu razmišljanja terapeuta, a usmjerenost na biološku zaštitu zuba, atraumatska i minimalno - invazivna terapija, logične su smjernice koje slijedi suvremena stomatologija.

and therapeutic methods is followed by changes in therapist's comprehension, leading contemporary dentistry to tooth conservation, non – traumatic and minimally invasive therapy.

Zahvala

Sve opisano rezultat je znanstvenog projekta (Nanostruktura restaurativnih materijala i interakcije s tvrdim zubnim tkivima), obavljenog zahvaljujući potpori Ministarstva znanosti, obrazovanja i športa Republike Hrvatske.

Acknowledgement

This study was supported by Ministry of Science, Education and Sports of the Republic of Croatia, as part of the project "Nanostructure of restorative materials and interactions with hard tooth tissues" Grant No. 065-0352851-0410.

Abstract

Modern concepts in caries treatment require highly specific and sensitive methods of caries detection opposed to the conventional visual – tactile method. Unnecessary removal of sound dental tissue is quite often due to false – positive caries diagnosis. On the other hand, lesion can be undetected for a long period of time. DIAGNOdent (KaVo, Dental GmbH, Germany), a laser fluorescence – based device, presents an important turnover in diagnostic procedure. DIAGNOdent reading is highly accurate, repeatable, simple, safe, and ensures a long-term lesion monitoring because the result is quantified. The purpose of the study was the comparison of visual - tactile method of caries detection with laser fluorescence. Out of 960 teeth, caries was diagnosed in 90 teeth (9,4%) by DIAGNOdent. Using the visual – tactile method, dental caries was diagnosed in 58 teeth (6%). Absolute disagreement was found in 3,54% cases. More than half of lesions that have remained undetected were in the category of enamel surface caries (DIAGNOdent values 14-20). McNamar's test showed statistically significant differences between DIAGNOdent based caries detection and visual – tactile method.

Received: February 14, 2007

Accepted: April 13, 2007

Address for correspondence

Prof. Zrinka Tarle
University of Zagreb
School of Dental Medicine
Department of Endodontics and
Restorative Dentistry
Gundulićeva 5, 10000 Zagreb Croatia
tarle@sfzg.hr

Key words

Dental Caries; Lasers

References

1. Chow LC, Vogel GL. Enhancing remineralization. *Oper Dent* 2002; 6 Suppl: 27-38.
2. Iijima Y, Takagi O. In situ acid resistance of in vivo formed white spot lesions. *Caries Res.* 2000;34(5):388-94.
3. Lussi A, Hibst R, Paulus R. DIAGNOdent: an optical method for caries detection. *J Dent Res.* 2004;83 Spec No C: C80-3.
4. Lussi A, Megert B, Longbottom C, Reich E, Francescut P. Clinical performance of a laser fluorescence device for detection of occlusal caries lesions. *Eur J Oral Sci.* 2001;109(1):14-9.
5. Lussi A, Firestone A, Schoenberg V, Hotz P, Stich H. In vivo diagnosis of fissure caries using a new electrical resistance monitor. *Caries Res.* 1995;29(2):81-7.
6. Anderson MH, Bales DJ, Omnell KA. Modern management of dental caries: the cutting edge is not the dental burr. *J Am Dent Assoc.* 1993;124(6):36-44.
7. Knežević A, Tarle Z, Negovetiž Mandiž V, Prskalo K, Panduriž V, Jankoviž B. Primary Fissure Carious Lesion Reversal Using Ozone. *Acta Stomatol Croat.* 2007;41(1):31-8.
8. Yassin OM. In vitro studies of the effect of a dental explorer on the formation of an artificial carious lesion. *ASDC J Dent Child.* 1995;62(2):111-7.
9. Heinrich-Weltzien R, Kuhnisch J, Oehme T, Ziehe A, Stösser L, Garcia-Godoy F. Comparison of different DIAGNOdent cut-off limits for in vivo detection of occlusal caries. *Oper Dent.* 2003;28(6):672-80.
10. Hibst R, Paulus R, Lussi A. Detection of occlusal caries by laser fluorescence. Basic and clinical investigations. *Med Laser Appl* 2001;16:205-13.
11. Shi XQ, Welander U, Angmar-Mansson B. Occlusal caries detection with KaVo DIAGNOdent and radiography. An in vitro comparison. *Caries Res.* 2000;34(2):151-8.
12. Reis A, Zach VL Jr, de Lima AC, de Lima Navarro MF, Grande RH. Occlusal caries detection: a comparison of DIAGNOdent and two conventional diagnostic methods. *J Clin Dent.* 2004;15(3):76-82.
13. Astvaldsdottir A, Holbrook WP, Traanaeus S. Consistency of DIAGNOdent instruments for clinical assessment of fissure caries. *Acta Odontol Scand.* 2004;62(4):193-8.

14. Sheehy EC, Brailsford SR, Kidd EA, Beighton D, Zoitopoulos L. Comparison between visual examination and a laser fluorescence system for in vivo diagnosis of occlusal caries. *Caries Res.* 2001;35(6):421-6.
15. Angnes V, Angnes G, Batistella M, Grande RH, Loguercio AD, Reis A. Clinical effectiveness of laser fluorescence, visual inspection and radiography in the detection of occlusal caries. *Caries Res.* 2005;39(6):490-5.
16. Olmez A, Tuna D, Oznurhan F. Clinical evaluation of DIAGNOdent in detection of occlusal caries in children. *J Clin Pediatr Dent.* 2006;30(4):287-91.
17. Attrill DC, Ashley PF. Occlusal caries detection in primary teeth: a comparison of DIAGNOdent with conventional methods. *Br Dent J.* 2001;190(8):440-3.
18. Nagayoshi M, Fukuizumi T, Kitamura C, Yano J, Terashita M, Nishihara T. Efficacy of ozone on survival and permeability of oral microorganisms. *Oral Microbiol Immunol.* 2004;19(4):240-6.
19. Knežević A, Tarle Z, Prskalo K. Terapija karijesnih lezija ozonom. *Acta Stomatol Croat.* 2004;38(4):365-74.