

Dimitrios Andreadis, George Laskaris, Panagiotis Kapsokefalos, Eleni Gagari

Idiopatski Sweetov sindrom s oralnim manifestacijama: prikaz slučaja i pregled literature

Idiopathic Sweet's Syndrome with Oral Manifestations: Case Report and Review of the Literature.

Zavod za Oralnu medicinu, KB-a "A.Sygos", Medicinskog fakulteta Sveučilišta u Ateni, Grčka
Department of Oral Medicine, 'A. Sygos' Hospital, Medical School of University of Athens, Greece

Sažetak

Sweetov sindrom ili akutna febrilna neutrofilna dermatoza, rijetka je kožna bolest nepoznate etiologije i patogeneze, povremeno udružena s malignitetom, a najčešće se javlja kod sredovječnih žena. Klinički su to bolne papule koje oblikuju plakove na koži te ustrajna vrućica i bolni zglobovi, a najdosljedniji je laboratorijski nalaz leukocitoza s neutrofilijom.

Predstavljamo dobro dokumentiran slučaj pacijentice u dobi od 62 godine s idiopatskim Sweetovim sindromom, prvim prijavljenim slučajem s oralnim lezijama u Grčkoj te opisom kliničkih i histoloških nalaza i terapije. Također dajemo uvid u literaturu o slučajevima koji uključuju i oralne lezije.

Zaprimljen: 17. siječnja 2007.

Prihvaćen: 10. svibnja 2007.

Adresa za dopisivanje

Dr Andreadis Dimitrios
"A. Sygos" Hospital
Department of Oral Medicine
5 I. Dragoumi Str, Athens,
GR-16121, Greece
Tel/Fax: +302107239965
uvomorulin@hotmail.com

Ključne riječi

Sweetov sindrom, akutna febrilna neutrofilna dermatoza

Uvod

Sweetov sindrom ili akutna neutrofilna dermatoza rijetka je dermatoza prvi put opisana godine 1964. Karakteriziraju ju četiri glavne značajke:

- znakovi konstitucije i simptomi (vrućica i malaksalost);
- povišeni polimorfonuklearni leukociti u perifernoj krvi;
- eritematozne kožne lezije, kao što su plakovi, čvorići i rijetko bule;
- histopatološki nalazi gustih perivaskularnih neutrofilnih infiltrata s minimalnim dokazom vaskulitisa (1).

Introduction

Sweet's syndrome or acute febrile neutrophilic dermatosis is an uncommon dermatosis, first described in 1964. It is characterized by four (4) main features:

- constitutional signs and symptoms (fever and malaise),
- increase of polymorphonuclear leukocytes in peripheral blood,
- erythematous skin lesions such as plaques, nodules and rarely bullae,
- histopathological findings of dense perivascular neutrophilic infiltration with minimal evidence of vasculitis (1).

Od Sweetova sindroma uglavnom obolijevaju sredovječne žene i nije obilježen bilo kakvom rasnom predileksijom. Može se manifestirati kao klasični idiopatski Sweetov sindrom, ili se može pojaviti s infekcijama (gornji respiratorni/ gastrointestinalni trakt), zatim udružen s malignošću, autoimunim bolestima, inflamatornom crijevnom bolešću, lijekovima ili trudnoćom (2-4). Kako se u većini slučajeva Sweetova sindroma javljaju kožne lezije, oralne su manifestacije rijetko opisane i to uglavnom kao aftozni vrijed (5).

U ovom članku izveštujemo o prvom, dobro dokumentiranom slučaju Sweetova sindroma s intraoralnim lezijama u Grčkoj, opisujemo kliničke i laboratorijske nalaze bolesti te dajemo pregled suvremene literature u vezi s oralnim manifestacijama sindroma.

Prikaz slučaja

Pacijentica u dobi od 62 godine primljena je Zavod za oralnu medicinu, kliničke bolnice "A. Sygros", u Ateni s oralnim i perioralnim lezijama i manifestacijama na gornjim ekstremitetima, posebice na nadlamicama. Lezije su se naglo pojavile, zajedno s pireksijom do 39,2°C.

Iz bolesnične povijesti bolesti bilo je jasno da nema drugih bolesti te da nije primala nikakvu terapiju lijekovima. Prvi je put prijavila kožne i oralne lezije prije desetak dana, ali su one nestale nakon terapije niskom dozom sistemskih kortikosteroida. Kožne su se lezije ponovno javile odmah nakon završetka terapije, ali s težim simptomima (bolovima).

Kožne su se lezije pojavile u obliku eritematoznih plakova i multiplih edematoznih i krustiranih papula te nekoliko bula na licu, rukama i leđima (Slike 1a, 1b). Tijekom kliničkog pregleda uočene su bolne krustirane papule i vrijedovi zaostali nekoliko dana nakon što su puknule papule, i to na oralnoj sluznici i na granici vermilliona donje usne (Slike 2a, 2b). Osim toga zahvaćene su bile i očne strukture u obliku upale spojnice – konjunktivitisa.

Analizom kompletne krvne slike ustanovljena je samo povišena vrijednost bijelih krvnih stanica - 37,1 K/ml s 90%-tnim udjelom neutrofila. Serološke pretrage ANA-e, reumatoidnog čimbenika (RF-a), stanica Lupus erythematosus (LE-a) i anti-DNK antitijela, pokazale su normalne vrijednosti. Rendgenska snimka toraksa te CT-snimka nisu otkrile osobitosti. Analitičkim i hematološkim te organskim pregledima, nije dokazana bilo kakva hematološka, ili neka druga malignost, ili imunološki poremećaj. Mikrobiološko ispitivanje pokazalo je infekciju bakterijom *S. aureus*.

Sweet's syndrome affects mainly middle-aged women and is not characterized by any racial predilection. It may manifest as classical or idiopathic Sweet's syndrome, or it may be associated with infections (upper respiratory / gastrointestinal tract), malignancies, autoimmune diseases, inflammatory bowel disease, drugs or pregnancy (2-4). Although most cases of Sweet's syndrome are characterized by skin lesions, oral manifestations have also rarely been described mainly as aphthous-like ulcers (5).

In this paper we report the first well-documented case of Sweet's syndrome with intraoral lesions in Greece, describe its clinical and laboratory findings and review current literature with regards to oral manifestations of the syndrome.

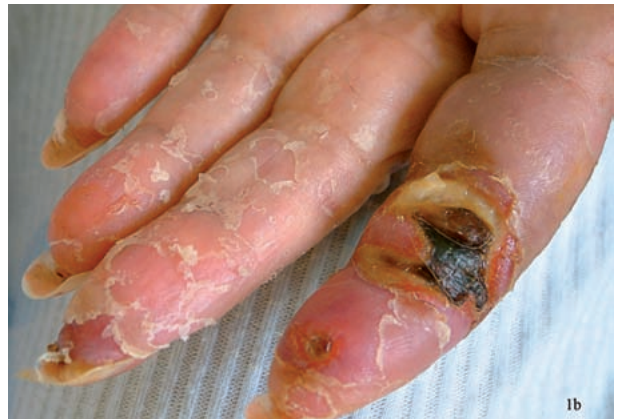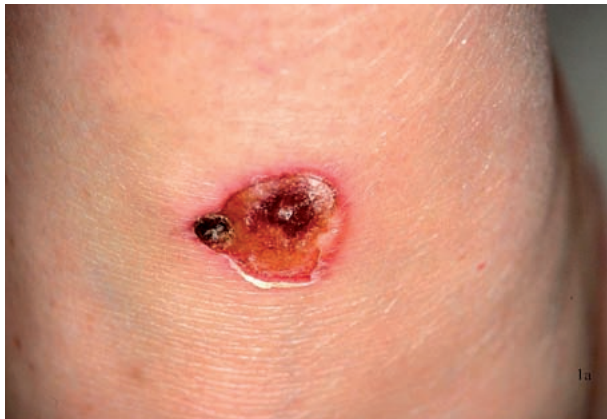Case Report

A 62-year-old female patient was presented to the Department of Oral Medicine of 'A. Sygros' Hospital, with oral and perioral lesions and manifestations of the upper extremities, especially on the fingers. The lesions were characterized by sudden onset and accompanied by pyrexia of up to 39.2°C.

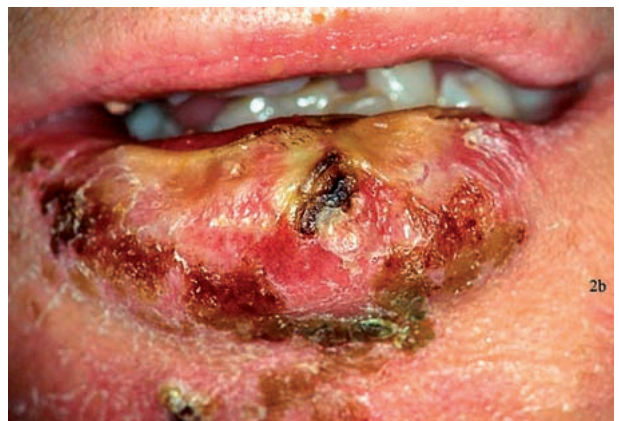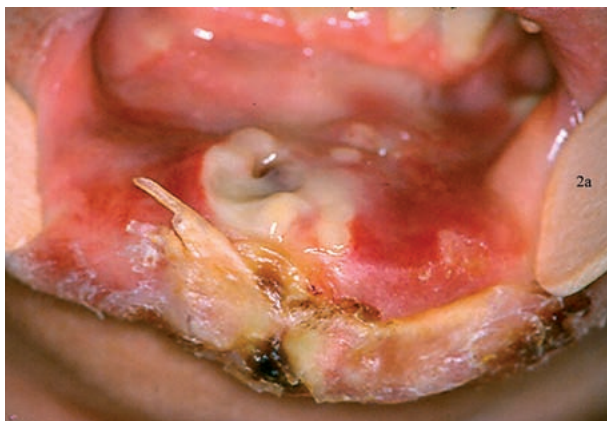
Patient's medical history was free of any other disease and did not receive any pharmaceutical treatment. She reported first onset of the skin and oral lesions about 10 days ago, which disappeared after treatment with low dose of systemic corticosteroids. Immediately after the end of treatment there was a recurrence of the cutaneous lesions, which presented with more severe symptoms (pain).

The cutaneous lesions were presented as erythematous plaques and multiple edematous and crusted papules and few bullae as well locating on the face, hands and the back (fig 1a, 1b). On clinical examination painful crusted papules and ulcers after papules' rupture few days later were also found on the oral mucosa and the vermillion border of the lower lip (fig 2a, 2b). In addition, ocular involvement with conjunctivitis was presented.

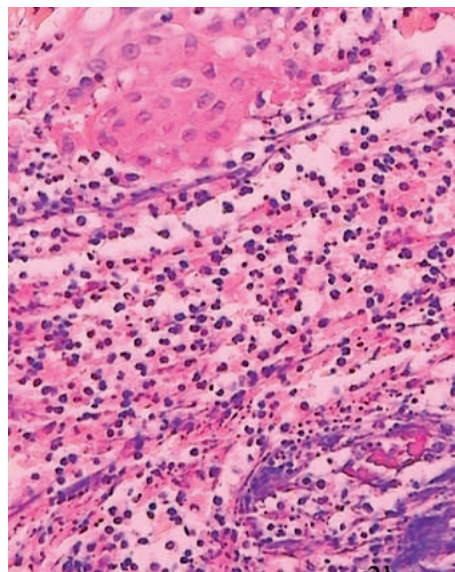
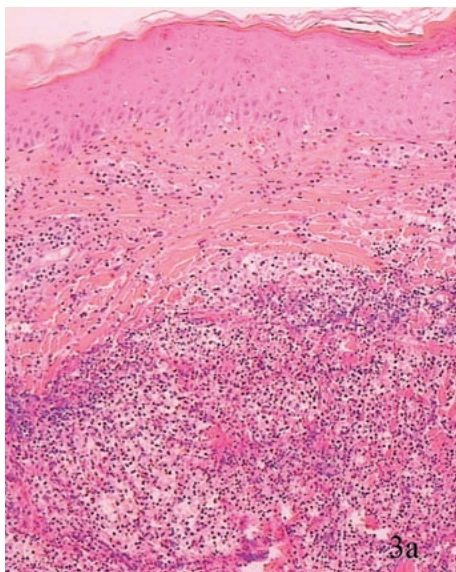
A complete blood examination showed only an increased white blood cell count of 37.1 K/ml with 90% neutrophils. Serologic tests for ANA, Rheumatoid factor, Lupus Erythematosus (LE) cells and anti-DNA antibodies ranged in normal values. Chest radiography and computed tomography revealed no findings. From the analytical haematological and organs examination, the existence of any hematologic or other malignancy as well as immunologic disorder was excluded. Microbiological examination showed infection by *S. aureus*.



Slika 1. Tipična lezija kod Sweetova sindroma na koži trupa (Sl. 1a) i prstima ruku (Sl. 1b) u obliku nježnih papula i nodula koji konfluiraju kako bi tvorili nepravilne, oštro-ograničene plakove bez svrbeža ili rupturirane bule ili pustule.
Figure 1 Typical lesion of Sweet's syndrome on the skin of the trunk (Fig 1a) and fingers (Fig 1b) presented as tender papules and nodules that coalesce to form irregular, well-demarcated, non-pruritic plaques or ruptured bullae or pustules.



Slika 2. Slične lezije na oralnoj sluznici (Sl. 2a) i na granici vermilionia (Sl. 2b) donje usne.
Figure 2 Similar lesions on the oral mucosa (Fig 2a) and the vermilion border (Fig 2b) of the lower lip.



Slika 3. Mikroskopski Sweetov sindrom karakteriziraju difuzne upalne stanične infiltracije površinskog vezivnog tkiva (Sl. 3a), uglavnom od neutrofila koje su primijećene u perivaskularnoj orijentaciji (Sl. 3b). (Hematoksilin/eozin X100 i X300)
Figure 3 Microscopically, Sweet's syndrome is characterized by the diffuse, inflammatory cell infiltration of superficial connective tissue (Fig 3a), mainly consisting of neutrophils, which are observed in a perivascular orientation (Fig 3b). (Hematoxylin/eosin X100 and X300)

Biopsija obavljena na kožnoj leziji i njezina histopatološka analiza pokazale su upalnu staničnu infiltraciju u površinskom vezivnom tkivu, a neutrofilu su uočeni u perivaskularnoj orijentaciji, no bez dokaza u prilog vaskulitisa (Slike 3a i 3b). Klinički i laboratorijski nalazi poduprli su dijagnozu idiopatskog slučaja Sweetova sindroma.

Bolesnica je liječena sistemski primijenjenim Prednizolonom 50 mg/dl i antibioticima i.v. Teicoplaninom 400 mg i Piperacillin-tazobactamom te je vrlo dobro podnijela terapiju i brzo se oporavila. Tjedan dana nakon početka terapije, broj bijelih krvnih stanica reduciran je na 14 K/ml s 60%-tnim udjelom neutrofila. Doza prednizolona postupno se smanjivala, sve dok bolest nije otišla u remisiju. Bolesnica je boravila u bolnici dva mjeseca. Nakon dvije godine ne pokazuje recidive, ni znakove drugih sistemskih bolesti.

Rasprava

Sweetov je sindrom rijetka bolest uglavnom ženske populacije u dobi između 30 i 50 godina, iako je mogu dobiti i mladi odrasli ljudi te djeca (5, 6). Sweetov sindrom počinje naglom vrućicom i često bolnim kutanim erupcijama. Tipična distribucija lezija uključuje lice, glavu i vrat te gornje udove, posebice dorzalni aspekt šaka. U obliku su nježnih papula i nodula koje konfluiraju i time tvore oštro ograničene, non-pruritične crvene ili plavičasto-crvene plakove. Ponekad se mogu razviti pustule ili bule. Tada su asimetrično raspoređene, a mogu biti pojedinačne ili višestruke. Zahvaćenost očnih struktura (konjunktivitis, iridociklitis i episkleritis) i artralgijske (arthritis, mialgija) prijavljene su u 20 – 50% slučajeva. Ponekad, jedan do tri tjedna prije nego što se pojave kožne lezije, kod bolesnika se javlja infekcija gornjih dišnih puteva s vrućicom, proljevom ili simptomima poput influence (7).

Histopatološki, Sweetov sindrom pokazuje gust upalni infiltrat, uglavnom od zrelih neutrofila smještenih primarno u površinskom dermisu. Edem dermalnih papila i papilarnog dermisa može također biti prisutan. Prevladava neutrofilna infiltracija, a može biti žarišna ili perivaskularna bez znakova vaskulitisa. Koji put se mogu uočiti i eozinofili i limfociti (4).

Dva su glavna i četiri sporedna kriterija predložena u dijagnozi Sweetova sindroma iz godine 1986. (8):

A biopsy was performed on a skin lesion and histopathologic examination showed inflammatory cell infiltration in superficial connective tissue and neutrophils observed in a perivascular orientation, without evidence of vasculitis (fig 3a and 3b). The clinical and laboratory findings supported the diagnosis of an idiopathic case of Sweet's syndrome.

The patient was treated with systemic prednisolone 50 mg/dl and antibiotics i.v. teicoplanin 400mg and piperacillin-tazobactam, and she responded very well, making a rapid recovery. Within a week after initiation of treatment, the white blood cells were reduced to 14 K/ml with 60% neutrophils. The prednisolone dose was gradually tapered until the disease went completely into remission. The patient stayed in hospital for about 2 months. Two years later she is free of recurrences and presents no evidence of any other systemic disease.

Discussion

Sweet's syndrome is a rare disease mostly affecting women of 30 to 50 years of age, however the condition may also affect younger adults and children (5, 6). Sweet's syndrome is characterized by the sudden onset of fever and cutaneous eruptions that are frequently painful. The typical distribution of the lesions includes face, head and neck, upper extremities, especially the dorsal aspect of the hands. Lesions present as tender papules and nodules that coalesce to form irregular, well-demarcated, non-pruritic plaques with red or bluish-red colour. Occasionally, bullae or pustules may be developed. They are asymmetrically distributed and may be single or multiple. The cutaneous lesions usually spontaneously resolve in 6-12 weeks but recur in about 30% of the patients. Eye involvement (conjunctivitis, iridocyclitis and episcleritis) and arthralgias (arthritis, myalgia) have been reported in 20-50% of the cases. Occasionally, 1-3 weeks before the onset of the cutaneous lesions many patients have preceding infections of the upper respiratory system with fever, diarrhoea or influenza-like symptoms (7).

Histopathologically, Sweet's syndrome exhibits a dense inflammatory infiltrate predominantly composed of mature neutrophils located primarily in the superficial dermis. Edema of the dermal papillae and papillary dermis may also be present. The neutrophilic infiltration is prevalent and may be focal or perivascular without evidence of vasculitis. Occasionally, eosinophils and lymphocytes may also be observed (8).

There are two major and four minor diagnostic criteria that have been proposed for Sweet's syndrome since 1986, (9):

Glavni kriteriji:

- a) nagli nastup kutanih lezija;
- b) histopatološki nalazi (neutrofilna infiltracija);

Sporadni kriteriji:

- a) vrućica i nespecifična respiratorna infekcija;
- b) artralgijske, konjunktivitis, hematološka malignost;
- c) leukocitoza;
- d) osjetljivost na liječenje kortikosteroidima.

Dijagnoza je utemeljena na istodobnoj zajedničkoj evaluaciji kliničkih kriterija i mikroskopskih nalaza. Diferencijalna dijagnoza uključuje: eritemu multiforme, Behcetovu bolest, Wegenerovu granulomatozu, limfom kože, leishmanijazu, sindrom PFAPA, aftozne vrijedove, pioderma gangerosum, sarkoidozu, ostale neutrofilne dermatoze te duboke gljivične infekcije. Iako je patogeneza i dalje nepoznata, postulirano je da reakcija preosjetljivosti može voditi neutrofilnoj aktivaciji. Japanski pacijenti sa Sweetovim sindromom često imaju HLA-Bw54 antigen, što upućuje na genetsku podlogu (5), iako u istraživanju o kavkaskim Europljanima nije pronađena korelacija s HLA-ima (9). Prema etiologiji, sindrom je razvrstan u šest (6) skupina:

- 1) idiopatska;
- 2) udružena s infekcijama respiratornog/gastrointestinalnog trakta, na primjer s *Yersinijom* (10, 11);
- 3) lijekovima inducirana, primjerice trimetoprim-sulfametoksazolom, antiepilepticima, antihipertenzivima, retinoidima ili granulocitnim colony-stimulated faktorom (G-CSF) (2, 12);
- 4) paraneoplastična malignost, uključujući hematološku malignost (posebice akutnu mijelogenu leukemiju) (13), karcinome genitalnih organa, solidne tumore (2);
- 5) udruženo s autoimunim bolestima te inflamatornim crijevnim bolestima (14);
- 6) vezano za trudnoću (15).

Terapija Sweetova sindroma općenito uključuje ordiniranje sistemskih kortikosteroida. Prednizolon 0,5-1 mg/kg per diem tijekom 4 - 6 tjedana, uobičajeno je dostatan za kontrolu bolesti. Alternativno, u nekim je slučajevima zabilježen uspjeh kod terapije Dapsonom 100-200 mg/d, kolhicinima 1,5 mg/d ili kalijevim jodidom 900 mg/d. Kada je bolest vezana za poznatu infekciju, primjerice streptokokom ili stafilokokom, potrebno je ordinirati i antibiotike. Drugi lijekovi uključuju i Takrolimus, Talidomid ili Ciklosporin. Slično ekstrakutanim manifestacijama Sweetova sindroma na drugim lokalitetima, oralne lezije uglavnom zacjeljuju nakon početka liječenja sistemskim kortikosteroidima (4).

Major criteria:

- a) sudden onset of cutaneous lesions,
- b) histopathologic findings (neutrophilic infiltration),

Minor criteria:

- a) fever and non specific respiratory infection,
- b) arthralgias, conjunctivitis, hematologic malignancy,
- c) leukocytosis,
- d) response to systemic corticosteroids.

The diagnosis is based on the concurrent evaluation of both clinical criteria and microscopic findings. The differential diagnosis includes erythema multiforme, Behcet's disease, Wegener's granulomatosis, lymphoma cutis, leishmaniasis, pFAPA syndrome, aphthous ulcers, pyoderma gangerosum, sarcoidosis, other neutrophilic dermatosis and deep fungal infections. Although the pathogenesis remains unclear, it is postulated that a hypersensitivity reaction may lead to neutrophil activation. Japanese patients with Sweet's syndrome frequently have HLA-Bw54 antigen indicating a genetic background (5), although in a study of Caucasian Europeans no correlation with HLAs was observed (9). According to the etiology, the syndrome has been divided into six subgroups:

- 1) idiopathic;
- 2) associated with infections of the respiratory/gastrointestinal tract for example with *Yersinia* (10, 11);
- 3) drug induced such as trimethoprim-sulfamethoxazole, antiepileptics, antihypertensives, retinoids or granulocyte colony-stimulated factor (G-CSF) (2, 12);
- 4) paraneoplastic including hematologic malignancy (especially acute myelogenous leukaemia) (13), carcinomas of the genital organs, solid tumours (2);
- 5) associated with autoimmune and inflammatory bowel diseases (14);
- 6) pregnancy related (15).

The treatment of Sweet's syndrome generally involves administration of systemic corticosteroids. Prednisolone 0.5-1 mg/kg per day for 4-6 weeks is usually enough to achieve disease control. Alternatively, some cases respond to dapsone 100-200 mg/d, or colchicines 1.5 mg/d or potassium iodide 900 mg/d. When the disease is related to known infection such as streptococcus or staphylococcus, antibiotics are necessary. Other therapies include tacrolimus, thalidomide or cyclosporine administration. Similar to extracutaneous manifestations of Sweet's syndrome at other sites, the oral lesions typically resolve after the initiation of treatment with systemic corticosteroids (4).

Uključenost oralne regije rijetka je u idiopatskom Sweetovu sindromu i aftozni se vrijedovi mogu javiti kod bolesnika s hematološkim poremećajima¹⁶. U samo nekoliko opisanih slučajeva u svjetskoj literaturi, također su uključene oralne manifestacije poput bula i vezikula, nekrotizirajućih ulcerativnih periodontalnih manifestacija, nodula, papula, pustula, nespecifičnih vrijedova i jakog oticanja jezika (vidi Tablicu 1. za lokaciju i vrste intraoralnih lezija, dob pacijenata i njihov spol) (5, 12, 13, 17-23).

Sweetov sindrom trebaju prepoznati kliničari koji se bave oralnim bolestima, posebice u slučajevima aftoznih vrijedova zajedno s kožnim ili genitalnim sličnim lezijama. Rana je dijagnoza nužna, a uključuje laboratorijsko ispitivanje i povremenu kontrolu, zato što se recidivi javljaju kod 30% pacijenata. Zatim, tijekom kliničke evaluacije pacijenta treba imati na umu moguće supostojanje Sweetova sindroma i malignosti (18).

Oral involvement is uncommon in idiopathic Sweet's syndrome and aphthous ulcers may be presented in Sweet's patients with haematologic disorders (16). The few reported cases in the world literature also included oral manifestations such as bullae and vesicles, necrotizing ulcerative periodontal manifestations, nodules, papules, pustules, unspecified ulcers and massive swelling of the tongue (see Table 1 for location and types of intraoral lesions, patients's ages and gender) (5, 12, 13, 17-23).

Sweet's syndrome should be recognised by the clinicians dealing with oral diseases, especially in cases of aphthous-like ulcers accompanied with skin or genital similar lesions. Early diagnosis including laboratory examination and periodic follow up are required because recurrences occur in 30% of patients. Furthermore, during the clinical evaluation of patients, one should always be in mind the possible co-existence of Sweet's syndrome with a malignancy (18).

Tablica 1. Prijavljeni slučajevi Sweetova sindroma s oralnim manifestacijama
Table 1 Reported cases of Sweet's syndrome with oral manifestations

Autori • Authors	Spol • Gender	Dob • Age	Manifestacije • Manifestations
Femiano et al. 2003	F	42	Ulceracija nepca i alveole • Palate and alveolous ulceration
Notami et al. 2000	F	34	Palatina ulceracija • Palate ulceration
Brandy et al. 1999	M	3	Bijele papule na jeziku, tvrdom i mekom nepcu • White papules on the tongue, the hard and the soft palate
Arberter et al. 1999	M	33	Erupcije i bule na labijalnoj i gingivalnoj sluznici • Eruptions and bullae on labial and gingival mucosa
Evans et al. 1999	F	19	Teška opsežna destruktivna gingivalna inflamacija i nekrotički ulcerativni periodontitis s gubitkom kosti • Severe widespread destructive gingival inflammation and necrotic ulcerative periodontitis with loss of bone
Bamelis et al. 1995	F	55	Masivna oteklina jezika • Massive swelling of the tongue
Thurnheer et al. 1998	F	62	Pustularne lezije na mekom nepcu • Pustular lesions of the soft palate
Mizogushi et al. 1988	M	41	Aftozni vrijedovi • Aphthous like ulcers
Mizogushi et al 1987*	65 (1:1-1:2.6)	30-50	Aftozni vrijedovi • Aphthous like ulcers
Driban and Alvarez. 1984	M	38	Pustule i oralni aftozni vrijedovi • Pustules and aphthous-like oral ulcers
Trenutni slučaj • Present case	F	62	Granica vermilionna usnice i sluznice usne • Vermillion border of the lip and lip mucosa

* slučajevi prijavljeni u Japanu i drugim zemljama do 1985., F:M omjer za japanske pacijente 1:1 i 1:2.6 za druge zemlje • cases reported in Japan and other countries up to 1985, F:M ratio for Japan patients 1:1, and 1:2.6 for other countries

Abstract

Sweet's syndrome or acute febrile neutrophilic dermatosis is an uncommon skin disease of unknown cause and pathogenesis, occasionally associated with malignancy, which is mostly occurring in middle aged women. Clinically, painful plaque-forming inflammatory papules on the skin are accompanied by high persistent fever and arthralgia and the most consistent laboratory findings are peripheral leukocytosis with neutrophilia. We present a well-documented case of a 62 year-old female patient, with idiopathic Sweet's syndrome, the first reported in Greece with oral lesions, describing its clinical and histological findings and the treatment, and we also review the relative literature focusing on cases with oral involvement.

Received: January 17, 2007

Accepted: May 10, 2007

Address for correspondence

Dr Andreadis Dimitrios
"A. Sygros" Hospital
Department of Oral Medicine
5 I. Dragoumi Str, Athens,
GR-16121, Greece
Tel/Fax: +302107239965
uvomorulin@hotmail.com

Key words

Sweet's Syndrome; Acute Febrile
Neutrophilic Dermatitis

References

- Sweet RD. An acute febrile neutrophilic dermatosis. *Br J Dermatol.* 1964;76:349-56.
- Cohen PR, Kurzrock R. Sweet's syndrome and cancer. *Clin Dermatol.* 1993;11(1):149-57.
- Walker DC, Cohen PR. Trimethoprim-sulfamethoxazole-associated acute febrile neutrophilic dermatosis: case report and review of drug-induced Sweet's syndrome. *J Am Acad Dermatol.* 1996;34(5 Pt 2):918-23.
- Cohen PR, Kurzrock R. Sweet's syndrome revisited: a review of disease concepts. *Int J Dermatol.* 2003;42(10):761-78.
- Mizoguchi M, Chikakane K, Goh K, Asahina Y, Masuda K. Acute febrile neutrophilic dermatosis (Sweet's syndrome) in Behcet's disease. *Br J Dermatol.* 1987;116(5):727-34.
- Boatman BW, Taylor RC, Klein LE, Cohen BA. Sweet's syndrome in children. *South Med J.* 1994;87(2):193-6.
- Cohen PR, Kurzrock R. Sweet's syndrome: a neutrophilic dermatosis classically associated with acute onset and fever. *Clin Dermatol.* 2000;18(3):265-82.
- Su WP, Liu HN. Diagnostic criteria for Sweet's syndrome. *Cutis.* 1986;37(3):167-74.
- von den Driesch P, Simon M Jr, Djawari D, Wassmuth R. Analysis of HLA antigens in Caucasian patients with acute febrile neutrophilic dermatosis (Sweet's syndrome). *J Am Acad Dermatol.* 1997;37(2 Pt 1):276-8.
- Sitjas D, Puig L, Cuatrecasas M, De Moragas JM. Acute febrile neutrophilic dermatosis (Sweet's syndrome). *Int J Dermatol.* 1993;32(4):261-8.
- von den Driesch P. Sweet's syndrome (acute febrile neutrophilic dermatosis). *J Am Acad Dermatol.* 1994;31(4):535-56.
- Arbetter KR, Hubbard KW, Markovic SN, Gibson LE, Phylly RL. Case of granulocyte colony-stimulating factor-induced Sweet's syndrome. *Am J Hematol.* 1999;61(2):126-9.
- Bamelis M, Boyden B, Sente F, Madoe V. Sweet's syndrome and acute myelogenous leukemia in a patient who presented with a sudden massive swelling of the tongue. *Dermatology.* 1995;190(4):335-7.
- Darvay A. Sweet's syndrome preceding inflammatory bowel disease. *Clin Exp Dermatol.* 1996;21(2):175.
- Satra K, Zalka A, Cohen PR, Grossman ME. Sweet's syndrome and pregnancy. *J Am Acad Dermatol.* 1994;30(2 Pt 2):297-300.
- Cohen PR, Talpaz M, Kurzrock R. Malignancy-associated Sweet's syndrome: review of the world literature. *J Clin Oncol.* 1988;6(12):1887-97.
- Femiano F, Gombos F, Scully C. Sweet's syndrome: Recurrent oral ulceration, pyrexia, thrombophlebitis and cutaneous lesions. *Oral Surg Oral Med Oral Pathol Oral Radiol Endod.* 2003;95(3):324-7.
- Notani K, Kobayashi S, Kondoh K, Shindoh M, Ferguson MM, Fukuda H. A case of Sweet's syndrome (acute febrile neutrophilic dermatosis) with palatal ulceration. *Oral Surg Oral Med Oral Pathol Oral Radiol Endod.* 2000;89(4):477-9.
- Mizoguchi M, Matsuki K, Mochizuki M, Watanabe R, Oga K, Harada S. Human leukocyte antigen in Sweet's syndrome and its relationship to Behcet's disease. *Arch Dermatol.* 1988;124(7):1069-73.
- Thurnheer R, Stammberger U, Hailemariam S, Rusi EW. Bronchial manifestation of acute febrile neutrophilic dermatosis (Sweet's syndrome). *Eur Respir J.* 1998;11(4):978-80.
- Brady RC, Morris J, Connelly BL, Boiko S. Sweet's syndrome as an initial manifestation of pediatric human immunodeficiency virus infection. *Pediatrics.* 1999;104(5 Pt 1):1142-4.
- Evans AV, Sabroe RA, Setterfield J, Greaves MW. Erythema elevatum diutinum/Sweet's syndrome overlap with gastrointestinal and oral involvement. *Br J Dermatol.* 1999;141(4):766-7.
- Driban NE, Alvarez MA. Oral manifestations of Sweet's syndrome. *Dermatologica.* 1984;169(2):102-3.