

Gülsüm Ak¹, Aslı Hayırlıoğlu¹, Sertan Ergun¹, Mine G. Güllüoğlu², Dilek Batu², Alp Saruhanoğlu¹, Hakkı Tanyeri¹

Karcinom acinusnih stanica donje usne: prikaz slučaja

Acinic Cell Carcinoma of the Lower Lip: a Case Report

¹ Zavod za oralnu medicinu Stomatološkog fakulteta Sveučilišta u Istanbulu
Istanbul University, Faculty of Dentistry, Department of Oral Medicine and Surgery

² Zavod za patologiju Medicinskog fakulteta Sveučilišta u Istanbulu
Istanbul University, Faculty of Medicine, Department of Pathology

Sažetak

Karcinom acinusnih stanica rijetka je bolest – to je tumor žlijezda slinovnica niskog stupnja malignosti. Najčešće se nalazi u velikim žlijezdama slinovnicama, gotovo uvijek u parotidnoj žlijezdi, a rijetko u malim žlijezdama slinovnicama.

U ovom opisu predstavljamo slučaj muškarca u dobi od 64 godine s perzistentnom dvogodišnjom oteklinom u sluznici donje usnice u ravnini očnjaka. Lezija je bila bezbolna, meke teksture, nalikovala je na mukokelu, bila je veličine 1x1,5 cm te pokrivena sluznicom normalne boje. Kirurški je uklonjena te je histopatološki potvrđen karcinom acinusnih stanica.

Zaprimljen: 30. siječnja 2007.

Prihvaćen: 10. svibnja 2007.

Adresa za dopisivanje

Sertan Ergun, D.D.S, Ph.D.
Istanbul University, Faculty of Dentistry,
Department of Oral Medicine and
Surgery,
34393 Capa, Istanbul, Turkey
sertanergun@gmail.com

Ključne riječi

karcinom acinarnih stanica, žlijezde
slinovnice

Uvod

Karcinom acinusnih stanica rijetka je bolest žlijezda slinovnica – među svim tumorima svih žlijezda slinovnica javlja se u 1 – 6 posto slučajeva (1). Klinički to je tumor niskog stupnja malignosti i uzrokuje asimptomatsku oteklinu koja polagano raste, a rjeđe i facijalnu parezu (3, 4). Tumor se histopatološki javlja u četiri oblika: solidnom, mikrocističnom, papilarnom i folikularnom, no njegovo biološko ponašanje ne može se predvidjeti isključivo na osnovi histoloških podskupina (5). Te stanice pozitivno reagiraju na intracitoplazmatsko Schiffovo periodično kiselinsko bojenje (PAS). Do 16 posto tih tumora ima metastaze na regionalnim limfnim čvorovima, a prvi izbor među metodama li-

Introduction

Acinic cell carcinoma is a rare tumor of the salivary glands with a rate of 1-6% of tumors of all salivary glands (1). It generally originates from major salivary glands (most common from parotid gland) and rarely from minor glands (2). Clinically, tumor is a low-grade malignancy tumor and causes an asymptomatic swelling which grows slowly and facial paralysis is rare (3, 4). Histopathologically, tumor has four types as solid, microcystic, papillary and follicular, but biological behavior of the tumor cannot be predicted only on the basis of histological subtypes (5). Tumor includes serous cells showing acinar differentiation. These cells give positive reaction with periodic acid schiff staining (PAS) in-

ječanja jest kirurška ekscizija, ako nema metastaza (2).

U ovom je izvještaju opisan karcinom acinusnih stanica u malim žlijezdama slinovnicama na donjoj usni, a oponaša mukocelu.

Prikaz slučaja

Muškarac u dobi od 64 godine imao je dvije godine oteklinu u usnoj šupljini. Iz anamneze se nije moglo razabrati koji su čimbenici tome najviše pridonijeli. Tijekom intraoralnoga pregleda otkrivena je masa veličine 1x1,5 cm na donjoj usnici u razini očnjaka (Sl.1). Lezija je bila glatka, bezbolna, meka pri palpaciji, apokrovna sluznica bila je normalno obojena i bez ulceracija.

Nije bilo parestezija, facijalnih deformiteta ni palpabilne regionalne limfadenopatije.

Radiografski nalazi bili su nespecifični.

Na temelju tih kliničkih ispitivanja privremeno su se razmatrale dijagnoze mukokele, pleomorfnog adenoma i hiperplastične žlijezde slinovnice. Obavljena je zatim kirurška ekscizija lezije (Sl.2.).

Tijekom makroskopskoga pregleda reseksijski se specimen sastojao od tumora dimenzija 1,5x1,2x0,5 cm s reznom površinom od svijetlosmeđe do crvene boje (Sl. 3.). Mikroskopski, djelomice učahuren tumor, pokazuje skupine uniformnih stanica s velikom bazofilnom granularnom citoplazmom, okruglim i centralno smještenim jezgrama i stromom bogatom limfocitima (Sl.4). Vidljiva je bila i minimalna atipija jezgara. Neoplastične su stanice bile poredane u mikrofolikularne i mikrocistične obrasce (Sl.5.). Tumorske stanice sadržavaju u citoplazmi granule pozitivne na Schiffovo periodično kiselinsko bojenje (PAS) te je indeks stanične proliferacije Ki67 ustanovljen na razini od 12 do 15 posto. Tumor je dijagnosticiran kao karcinom acinusnih stanica (Sl. 6.). Granice kirurške resekcije specimena bile su slobodne od tumorskih stanica. Pacijent je dolazio dvije godine na kontrole.

Rasprava

Karcinom acinusnih stanica (ACC/Acinus Cell Carcinoma) rijedak je tumor žlijezda slinovnica niskog stupnja malignosti, a javlja se najčešće u velikim žlijezdama slinovnicama te rjeđe u malima. Kada je 1950-ih godina prvi put opisan, izraz "tumor" koristio se češće negoli "karcinom" zbog benignog ponašanja, no SZO ističe u objašnjenju da je sinonim neprikladan, budući da se dobro zna

tracytoplasmically (2). Upto 16% of these tumors show metastasis to regional lymph nodes and treatment of choice is surgical excision of the tumor if there is no metastasis (2).

This report presents a case of acinic cell carcinoma which originated from minor salivary glands of the lower lip mimicking a mucocele.

Case report

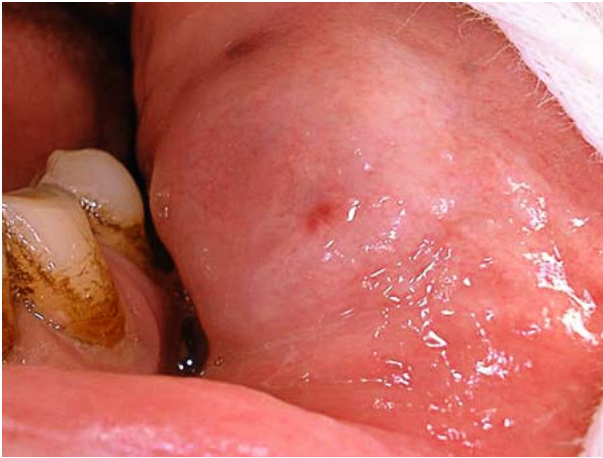A 64-year-old man was suffering from a persistent swelling in the oral cavity for two years. His medical history was non-contributory. Intraoral examination revealed a 1x1.5 cm mass located in the lower lip at the line of the canine tooth (Fig. 1). The lesion was smooth, painless, soft on palpation and the overlying mucosa was normal in color with no ulceration. There was no paresthesia, facial deformity or palpable regional lymphadenopathy. Radiographic findings were nonspecific.

Based on these clinical examinations, a preliminary diagnosis of mucocele, pleomorphic adenoma and a hyperplastic salivary gland was considered. Surgical excision of the lesion was performed (Fig. 2).

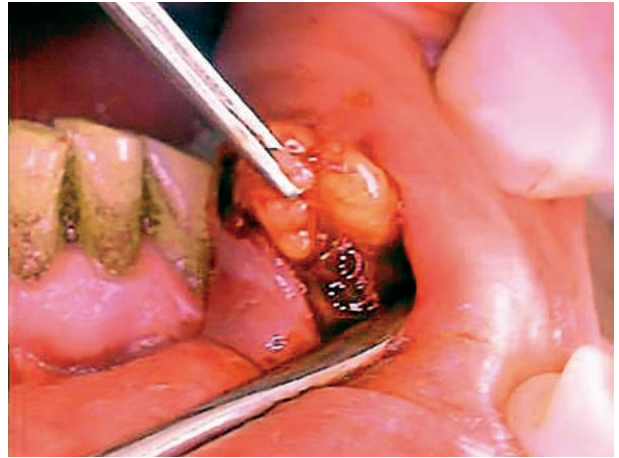
In macroscopic examination, all resection specimen consisted of the tumor measuring 1,5x1,2x0.5 cm with a tan to reddish colored cut surface (Fig. 3). Microscopically, partially encapsulated tumor showed groups of uniform cells with large basophilic granular cytoplasm, round centrally located nuclei and stroma rich in lymphocytes (Fig. 4). Minimal nuclear atypia was present. The neoplastic cells were arranged in microfollicular and microcystic patterns (Fig. 5). Tumor cells contain PAS (periodic acid schiff stain) positive granules in the cytoplasm and Ki67 cell proliferation index was detected to be 12-15%. The tumor was diagnosed as an acinic cell carcinoma (Fig.6). Surgical margins of the resection specimen were free of tumoral cells. The patient has been under control for 2 years with no recurrence.

Discussion

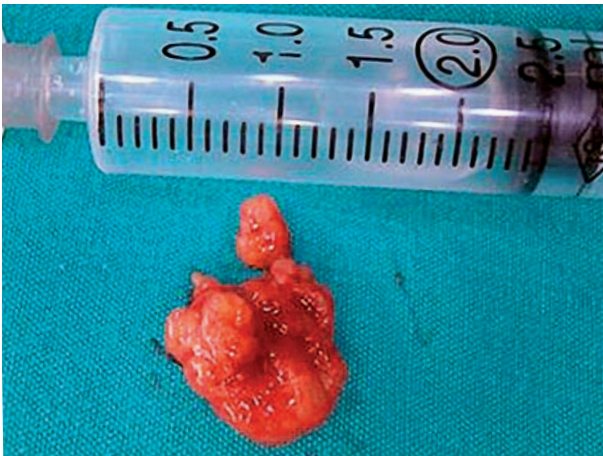
Acinic cell carcinoma (ACC) is a rare, low-grade malignant tumor of the salivary glands, which occurs most frequently in major salivary glands but rarely in minor salivary glands. When ACC first described in 1950s, the term of "tumor" has been used rather than "carcinoma" because of its benign behaviour but WHO explains that this is an inappropriate synonym since the malignant biologic behavior of this neoplasm



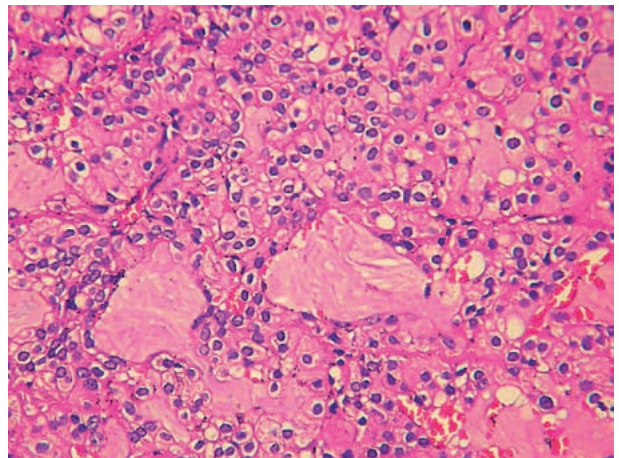
Slika 1. Tkivo veličine 1x1,5 cm locirano u donjoj usnici u razini kanina
Figure 1 1x1.5 cm mass located in the lower lip at the line of the canine tooth



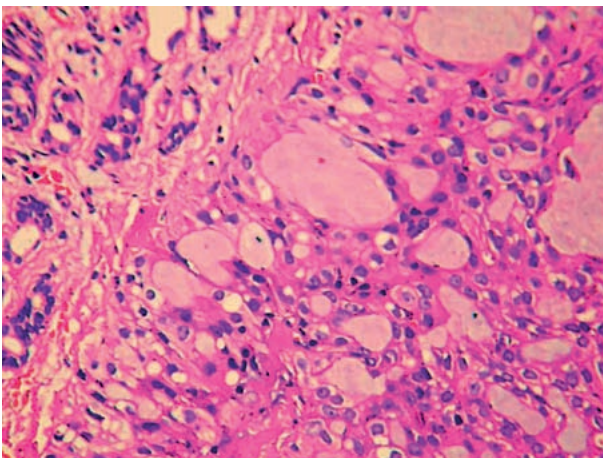
Slika 2. Kirurška ekscizija lezije
Figure 2 Surgical excision of the lesion



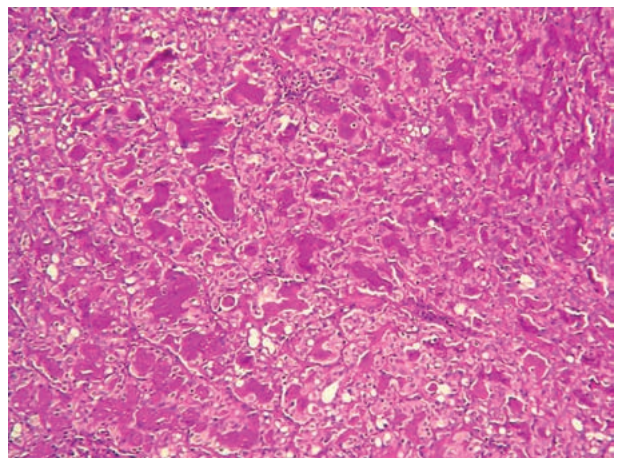
Slika 3. Makroskopski izgled
Figure 3 Macroscopic view



Slika 4. Tipično neoplastične acinarne stanice su jednobrazne, okrugle do poligonalne stanice s velikom bazofilnom granuliranom citoplazmom, okruglom, centralno lociranom jezgrom i stromom bogatom limfocitima (HE x200).
Figure 4 Typically neoplastic acinar cells are uniform, round to polygonal cells with large basophilic granular cytoplasm, round centrally located nuclei and stroma rich in lymphocytes (HE x200).



Slika 5. Male, normalne duktoacinarne jedinice žlijezde slinovnice, adenokarcinom aciničnih stanica, mikrocistični rast (HE x400)
Figure 5 Small, normal ductoacinar unit of salivary gland, acinic cell adenocarcinoma, microcystic growth pattern (HE x400).



Slika 6. Pozitivno PAS bojanje tumorskih stanica (PAS x100).
Figure 6 Positive PAS staining of tumor cells (PAS x100).

za maligno biološko ponašanje te neoplazme (6). Gotovo 80 posto karcinoma acinusnih stanica javlja se u parotidnim žlijezdama, te oko 17 posto uključuje intraoralne male žlijezde slinovnice (6). No, neki su slučajevi ACC-a opisani u mandibuli, submandibularnim i podjezičnim žlijezdama, nepcu, usni, obraznoj sluznici i jeziku (7-12). Klinički se ACC javlja u širokom presjeku dobnih skupina - od drugog do sedmog desetljeća života, te u srednjoj dobi u petom desetljeću i to s neznatnom predomancijom žena. Kod djece je rijedak. (13, 14).

Obično se tumor javlja pojedinačno kao bezbolna masa koja sporo raste, pa pacijenti često nisu svjesni njegova postojanja. Bol i parestezije nisu česte, ali su prijavljene (8, 11, 15). Te kliničke manifestacije ACC-a slične su mnogobrojnim benignim lezijama, no teško je postaviti kliničku dijagnozu prije biopsije.

U opisanom je slučaju pacijent patio od dugotrajne otekline sluznice donje usnice – čak dvije godine. Spomenuo je da je lezija bila manja te da je u tom razdoblju narasla do 1x1,5 cm. Intraoralno je lezija bila bezbolna, mekana na palpaciju te prekrivena normalnom sluznicom. Na temelju tih kliničkih nalaza, kao preliminarna dijagnoza razmatrala se mogućnosti mukokele, pleomorfnog adenoma i hiperplastične žlijezde. Mukokele mogu narasti i često ih se nalazi u labijalnoj sluznici. Pleomorfnu se adenom također razmatrao zbog ustrajnog i polaganog povećanja lezije, te razmjernе demarkacije.

Citološki ključ dijagnoze ACC-a je u prepoznavanju neoplastičnih acinarnih stanica (16). Ipak, ACC-i mogu sadržavati i rijetko bistre/svijetle stanice (7). To sugerira da ACC predstavlja histogenetske mogućnosti diferencijacije kroz mnogobrojne fenotipske puteve (11). Ellis i Corio ističu da je ACC s ishodištem u malim žlijezdama slinovnicama manje agresivan od onog u parotidnoj žlijezdi (8).

Karcinom acinusnih stanica može imati regularna omeđenja ako je malih dimenzija, no rastom postaje infiltrativan. Prema nekim stručnjacima ACC-i su razvrstani u tri stupnja:

Stupanj I. (nizak stupanj malignosti) – tumori su potpuno učajureni i bez lokalne infiltracije;

Stupanj II. (srednji stupanj malignosti) - tumori pokazuju kapsularnu invaziju;

Stupanj III. (visok stupanj malignosti) - pripadaju mu tumori s papilarnim cističnim zonama i infiltracijom u okolno tkivo (13, 14).

is well established.(6). Almost 80% of acinic cell carcinomas occur in the parotid gland and about 17% involve the intraoral minor salivary glands (6). However some cases of ACC have been described in the mandible, submandibular and lingual glands, palate, lip, buccal mucosa and tongue (7-12). Clinically ACC occurs over a broad age range from second to the seventh decades of life and a mean age at presentation in the fifth decade with a slight female predominance. Occurrence in children is considered to be rare (13, 14).

Typically the tumor presents itself as a slowly growing, painless mass therefore patients may be unaware of the lesion. Pain and paresthesia are not common manifestations but have been reported (8, 11, 15). These clinical manifestations of ACCs are similar to a number of benign lesions so it is difficult to make a clinical diagnosis prior to biopsy.

In this reported case the patient was suffering from a persistent swelling in the lower lip mucosa for two years. He mentioned that the lesion was smaller and increased steadily 1x1.5 in cm size during that time. Intraorally the lesion was painless, soft on palpation and covered with a normal mucosa. Based on these clinical findings preliminary diagnosis was considered as a mucocele, pleomorphic adenoma and hyperplastic salivary gland. Mucoceles may grow in the course of time and are frequently seen in labial mucosa. Also pleomorphic adenoma was regarded due to persistently and slowly increasing size and the relative demarcation.

The cytological key for the diagnosis of ACC resides in the recognition of the neoplastic acinar cells (16). However ACCs may also contain intercalated duct type cells, vacuolated cells, non-specific glandular cells and rarely clear cells (7). This suggests that ACC histogenetically represents differentiation along number of phenotypic pathways (11). Ellis and Corio mentioned that ACC originating from minor salivary glands is histologically less aggressive than that originating from parotid gland (8).

Acinic cell carcinomas may have regular margins if they are small in size but they become infiltrative by growing. According to some investigators ACCs have been divided into three grades. They are defined as such:

Grade I (low grade malignancy) completely encapsulated tumors without local infiltration;

Grade II (moderate malignancy) tumors showing capsular invasion;

Grade III (high grade malignancy) comprises tumors having papillary cystic zones and infiltrate the surrounding tissues (13, 14).

No, SZO ističe da su pokušaji histološkog stupnjevanja proturječni i nepostojani. Svojstva koja su često pridružena agresivijim tumorima uključuju češće mitoze, fokalnu nekrozu, neuralnu invaziju, pleomorfizam, infiltraciju i stromalnu hijalinizaciju (6). Ipak, mnogi znanstvenici definiraju ACC kao tumor niskog stupnja malignosti, zbog niskih stopa recidiva, metastaziranja i smrtnosti (7, 11, 15).

Metastaziranje u limfne čvorove rijetko je u ACC-ima - samo 5-10 posto ima metastaze u regionalnim limfnim čvorovima (10, 13). Spiro i suradnici izvijestili su o vratnim metastazama kod 11 od 67 (16%) pacijenata s ACC-om (17). Abrams i Melrose nisu identificirali metastaze u malim slinovnicama (7). Druge metastatske lokacije ACC-a su pluća i kosti (8, 14, 17).

Potpuna ili površinska parotidektomija prva je prihvaćena metoda izbora u liječenju većine parotidnih tumora i može se kombinirati s radioterapijom - ovisno o stupnjevanju, tj. stadiju (stagingu) bolesti (18-22). Disekcija vrata se ne obavlja ako nema metastaza u cervikalnim limfnim čvorovima. Radioterapija se nije pokazala učinkovitom u kontroli te neoplazme i kod ove vrste inicijalne terapije vezane za prognozu (20). Perzin i Livolsi opisali su lokalno rekurentni i perzistentni tumor u 14 od 15 slučajeva liječenog ACC-a s limitiranim lokalnim ekscizijama, no samo kod 13 od 28 slučajeva liječenih širokim lokalnim ekscizijama (20). No, Rassai i suradnici izjavili su da je dostatna kirurška ekscizija lezije i radioterapija najbolji način liječenja (23). U našem je slučaju obavljena kirurška ekscizija, te patološka analiza koja je otkrila karcinom acinusnih stanica. Zbog malignosti dijagnoze, izvedena je re-ekscizija lezije.

Kod ACC-a je poznata sklonost lokalnoj rekurenciji i povoljnoj prognozi, no njegov je tijek skriven i štetan te zahtijeva dugotrajnu kontrolu. Mendenhall i suradnici objavili su parametre pridružene slaboj prognozi koja uključuje uznapredovali stadij bolesti, necjelovitu resekciju i histologiju visokog stupnja (19). Lokalna je rekurencija uočena kod oko 33 posto pacijenata, s razvojem metastaza u nekih 15 posto slučajeva (8). U 82 posto slučajeva javile su se i sekundarne lezije tijekom pet godina nakon liječenja. Stopa preživljavanja kod 5 godina iznosi 89 – 96%, a kod 20 godina 56%, što potvrđuje da je pacijente prijeko potrebno dugotrajno kontrolirati (13). Keane i suradnici opisali su slučaj ACC-a malih slinovnica u usnoj šupljini koji je pacijent nakon

But WHO suggests that attempts at histological grading have been controversial and inconsistent. Features that are often associated with more aggressive tumors include frequent mitoses, focal necrosis, neural invasion, pleomorphism, infiltration and stromal hyalinization (6). However most investigators define ACC as low grade malignancy because of low recurrence rate, low metastatic rate and low death rate (7, 11, 15).

Metastasizing to lymph nodes are rarely seen in ACCs so that only 5-10% of these tumors show metastasis to regional lymph nodes (10, 13). Spiro et al. have reported cervical lymph node metastasis in 11 of 67 (16%) patients with ACC (17). Abrams and Melrose have not identified metastasis of ACC originating from minor salivary glands (7). The other metastatic sites for ACCs are lungs and bones (8, 14, 17).

Total or superficial parotidectomy is the accepted primary choice for treatment in the majority of parotid tumors and may be combined with radiotherapy depending on disease staging. (18-22). Neck dissection is not performed if there is no cervical lymph node metastasis. Radiotherapy did not appear effective in controlling this neoplasm and type of initial therapy correlated with prognosis (20). Perzin and Livolsi have reported locally recurrent or persistent tumor in 14 of 15 cases of ACC treated with limited local excisions, but only in 13 of 28 cases treated by wide local excisions (20). However Rassai et al. have reported that adequate surgical excision of the lesion followed by radiation therapy may offer the best way of treatment (23). In our case surgical excision of the lesion was performed and pathological examination revealed acinic cell carcinoma. Because of the diagnosis of malignancy re-excision of the lesion area was performed and revealed no visible evidence of persistent disease. We did not consider any other treatment procedures after adequate excision of the lesion.

ACCs are known as having a tendency of local recurrence and a good prognosis but they follow an insidious course requiring long term follow up. Mendenhall et al. have reported the parameters associated with a poor prognosis include advanced stage disease, incomplete resection and high-grade histology (19). Local recurrence is seen in about 33% of patients and metastasis occurring in around 15% of cases (8). In 82% of cases secondary lesions appear within five years after treatment. The survival rates of 89- 96% at 5 years and 56% at 20 year prove the need for long term follow-up (13). Keane et al. have reported a case of ACC of minor salivary gland origin within the oral cavity that the patient

biopsije odbio liječiti kirurškim putem, te je iduće dvije godine bio bez znakova bolesti (24).

Zaključak

ACC-i su maligni tumori sporog rasta i općenito asimptomatskoga tijeka, dakle, većina pacijenata nije svjesna tih lezija. To što se taj tumor rijetko javlja u malim slinovnicama i njegova sličnost s benignim oralnim lezijama otežavaju diferencijalnu dijagnozu, te su stomatolozi vrlo važni u njegovoj dijagnozi. Pozornost kod sumnjivih povijesti bolesti, pažljiva klinička procjena i histopatološke potvrde imaju velik utjecaj na dijagnozu rijetkih oblika oralnoga raka.

has refused surgical treatment after the biopsy and remained disease free for two years (24).

Conclusion

ACCs are malignant tumors which grow slowly and generally asymptotically, therefore most of the patients are unaware of the lesions. Infrequent presentation of the tumor in minor salivary glands and its similarity to benign oral lesions make the differential diagnosis troublesome and attribute the dentists an important role in diagnosis. Being aware of any suspicious history, making a careful clinical assessment and having a histopathological confirmation has the major impact on the diagnosis of rarely seen oral cancers.

Abstract

Acinic cell carcinoma is a rare, low grade malignant tumor of the salivary glands. Most frequently it originates from major salivary glands almost exclusively in parotid gland and rarely from minor salivary glands. In this report we present a case of 64-year-old man with a persistent swelling within the mucosa of the lower lip at the line of the canine tooth for two years. The lesion was painless, soft in texture, mimicked a mucocel and had the dimensions of 1x1.5 cm with an overlying mucosa normal in color. Surgical excision of the lesion is performed and histopathological confirmation revealed acinic cell carcinoma.

Received: January 30, 2007

Accepted: May 10, 2007

Address for correspondence

Sertan Ergun, D.D.S, Ph.D.
Istanbul University, Faculty of Dentistry,
Department of Oral Medicine and
Surgery,
34393 Capa, Istanbul, Turkey
sertanergun@gmail.com

Key words

Carcinoma; Acinar Cell; Salivary
Glands

References

- Ito FA, Ito K, Vargas PA, de Almeida OP, Lopes MA. Salivary gland tumors in a Brazilian population: a retrospective study of 496 cases. *Int J Oral Maxillofac Surg.* 2005;34(5):533-6.
- Vidyadhara S, Shetty AP, Rajasekaran S. Widespread metastases from acinic cell carcinoma of parotid gland. *Singapore Med J.* 2007;48(1):e13-5.
- Keane WM, Denny JC 3rd, Atkins JP Jr, McBrearty F. Acinic cell carcinoma of the oral cavity. *Otolaryngol Head Neck Surg.* 1982;90(6):696-9.
- Ellis GL, Corio RL. Acinic cell adenocarcinoma. A clinicopathologic analysis of 294 cases. *Cancer.* 1983;52(3):542-9.
- Boscolo-Rizzo P, da Mosto MC, Marchiori C, Boccato P. Transglottic acinic cell carcinoma. Case report and literature review. *ORL J Otorhinolaryngol Relat Spec.* 2004;66(5):286-9.
- Ellis G, Simpson RHW. Acinic cell carcinoma. In: Barnes L, Eveson JW, Reichart PA, Sidransky D, editors. *Pathology and genetics of head and neck tumours.* Lyon: IARC press; 2005. p. 216-8.
- Abrams AM, Melrose RJ. Acinic cell tumors of minor salivary gland origin. *Oral Surg Oral Med Oral Pathol.* 1978;46(2):220-33.
- Ellis GL. Odontogenic ghost cell tumor. *Seminars in Diagnostic Pathology.* 1999;16(4):288-92.
- Gross M, Eliashar R, Ben-Yaakov A, Maly B, Sichel JY. Acinic cell carcinoma of the tongue base. *Otolaryngol Head Neck Surg.* 2004;131(6):1024-6.
- Hara I, Ozeki S, Okamura K, Toshitani K, Taniguchi K, Honda T, Ohishi M. Central acinic cell carcinoma of the mandible. Case Report. *J Craniomaxillofac Surg.* 2003;31(6):378-82.
- Loudon JA, Larsen PE, Allen CM. Buccal submucosal mass. *Oral Surg Oral Med Oral Pathol Oral Radiol Endod.* 2000;90(3):263-5.
- Spencer ML, Neto AG, Fuller GN, Luna MA. Intracranial extension of acinic cell carcinoma of the parotid gland. *Arch Pathol Lab Med.* 2005;129(6):780-2.
- Sato T, Kamata SE, Kawabata K, Nigauri T, Mitani H, Beppu T, Sato M. Acinic cell carcinoma of the parotid gland in a child. *Pediatr Surg Int.* 2005;21(5):377-80.
- Tucci FM, Bianchi PM, Bottero S, Partipilo P, Pierro V. Acinic cell carcinoma of the parotid gland in childhood. *Int J Pediatr Otorhinolaryngol.* 1993;27(2):187-91.
- Neville BW, Damm DD, Allen CM, Bouquot JE. *Oral and maxillofacial pathology.* Philadelphia: WB Saunders; 1995. p. 351-3.
- Prieto-Rodriguez M, Artes-Martinez MJ, Navarro-Hervas M, Camanas-Sanz A, Vera-Sempere FJ. Cytological characteristics of acinic cell carcinoma (ACC) diagnosed by fine-needle aspiration biopsy (FNAB). A study of four cases. *Med Oral Patol Oral Cir Bucal.* 2005;10(2):103-8.

17. Spiro RH, Huvos AG, Strong EW. Acinic cell carcinoma of salivary origin. A clinicopathologic study of 67 cases. *Cancer*. 1978;41(3):924-35.
18. Chou C, Zhu G, Luo M, Xue G. Carcinoma of the minor salivary glands: results of surgery and combined therapy. *J Oral Maxillofac Surg*. 1996;54(4):448-53.
19. Mendenhall WM, Morris CG, Amdur RJ, Werning JW, Villaret BD. Radiotherapy alone or combined with surgery for salivary gland carcinoma. *Cancer*. 2005;103(12):2544-50.
20. Perzin KH, LiVolsi VA. Acinic cell carcinomas arising in salivary glands: a clinicopathologic study. *Cancer*. 1979;44(4):1434-57.
21. Tran L, Sadeghi A, Hanson D, Juillard G, Mackintosh R, Calcaterra TC, Parker RG. Major salivary gland tumors: treatment results and prognostic factors. *Laryngoscope*. 1986;96(10):1139-44.
22. Wahlberg P, Anderson H, Biorklund A, Moller T, Perfekt R. Carcinoma of the parotid and submandibular glands--a study of survival in 2465 patients. *Oral Oncol*. 2002;38(7):706-13.
23. Rassaei N, Frye DA, Harter KW, Troost TR, Ozdemirli M. Acinic cell carcinoma of the glottis: case report. *Am J Otolaryngol*. 2003;24(4):258-60.
24. Keane WM, Denny JC 3rd, Atkins JP Jr, McBrearty F. Acinic cell carcinoma of the oral cavity. *Otolaryngol Head Neck Surg*. 1982;90(6):696-9.