

Kittipong Dhanuthai¹, Kitti Torrungruang²

Veruciformni ksantom: prikaz triju slučajaja

Verruciform Xanthoma: Report of Three Cases

¹ Zavod za oralnu patologiju Stomatološkog fakulteta Sveučilišta Chulalongkorna, Tajland
Department of Oral Pathology, School of Dentistry, Chulalongkorn University, Thailand

² Zavod za mikrobiologiju Stomatološkog fakulteta Sveučilišta Chulalongkorna, Tajland
Department of Microbiology, School of Dentistry, Chulalongkorn University, Thailand

Sažetak

Veruciformni ksantom razmjerno je neuobičajena mukokutana lezija. Većina opisanih slučajeva bila je na mastikatornoj oralnoj mukozi, posebice gingivi. U ovom članku opisana su tri slučaja veruciformnog ksantoma na palatinalnoj gingivi. Lezije su bile male i bezbolne - dvije su bile papilarne, a jedna slična cvjetači. Histološki pregled otkrio je papilomatozu i akantozu povezanu s aglomeracijom ksantomatoznih stanica u papili vezivnog tkiva. Ksantomatozne stanice bile su pozitivne na antitijela CD 68, što upućuje na makrofagno podrijetlo. Sve su lezije bile obrađene konzervativnom kirurškom ekscizijom i nije bilo recidiva. Gledano diferencijalno dijagnostički i patogenetski, prema kliničkoj slici u obzir dolazi verukozni karcinom ili karcinom skvamoznih stanica. Kliničari bi zato trebali poznavati leziju, kako bi se izbjegle nepotrebne opsežne kirurške intervencije.

Zaprimljen: 18. rujna 2006.

Prihvaćen: 21. sudenog 2006.

Adresa za dopisivanje

Dr. Kittipong Dhanuthai
Chulalongkorn University
School of Dentistry
Department of Oral Pathology
Henri Dunant Rd.
Patumwan District, Bangkok 10330
Thailand
Tel : 662-2188801
Fax: 662-2188798
fibroma123@yahoo.com

Ključne riječi

ksantom, gingiva, melanoza, papilom

Uvod

Pojam "veruciformnog ksantoma" uveo je godine 1971. Shafer (1) kada je opisivao 15 slučajeva toga patološkog entiteta. To je rijetka lezija i uglavnom se javlja u usnoj šupljini. Santa Cruz i Martin (2) opisali su godine 1979. prva dva slučaja veruciformnog ksantoma u vulvi. Od tada je u literaturi opisano mnogo ekstraoralnih veruciformnih ksantoma (3-8).

Intraoralni veruciformni ksantom uglavnom je solitarna lezija. Samo se rijetko radi o multiplim lezijama (6, 9-11). Površina može biti ravna, lagano izdignuta, granularna/papilarna ili verukozna, sa širokom ili peteljkastom bazom (6, 9, 12, 13). Boje mogu biti od normalne boje mukoze do žute, sive, smeđe ili bijele (9, 10-12). Veruciformne ksantome usne šupljine imaju većinom osobe srednje dobi, a

Introduction

The term "verruciform xanthoma" was first coined by Shafer (1) in 1971 to report the first 15 cases of this pathological entity. Verruciform xanthoma is a rare lesion occurring predominantly in the oral cavity. Santa Cruz and Martin (2) reported the first two cases of verruciform xanthoma in the vulva in 1979. Since then, numerous extra-oral verruciform xanthomas have been reported in literature (3-8).

Intraoral verruciform xanthoma usually present clinically as a solitary lesion. Only on rare occasions does this lesion appear as multiple lesions (6, 9-11). The surface may appear flat, slightly raised, granular/papillary or verrucous with a sessile or pedunculated base (6, 9, 12, 13). Colors may range from that of the normal mucosa to yellow, gray, brown or

malo su češći kod muškaraca u usporedbi sa ženama. Većina lezija nalazi se na mastikatornoj mukozici, posebice gingivi (9, 11, 13).

Epitel mikroskopski pokazuje papilomatozu, akantozu i hiperparakeratozu s produljenim zupcima pile do ujednačene dubine. Nema citološke atipije u samoj leziji. Njezin histološki znak je akumulacija povećanih makrofaga s pjenastom citoplazmom (ksantomatozne stanice) u papilama vezivnog tkiva između epitelnih produljaka. Može se pojaviti i upalni infiltrat u epitelu i vezivnom tkivu ispod njega (6, 9, 10-15).

U ovom radu opisana su tri slučaja verruciformnog ksantoma dijagnosticirana u Zavodu za oralnu patologiju Stomatološkog fakulteta Sveučilišta Chulalongkorna u Tajlandu.

Prvi slučaj

Pacijentica u dobi od 44 godine žalila se na blagu neugodu tijekom četkanja nepca na desnoj strani, a to joj se događalo dvije godine. Stomatolog je propisao triamcinolon-acetonidinsku kremu, ali simptomi nisu nestali. Intraoralnim pregledom otkrivena je papilarna lezija veličine 3x12 mm² na palatinalnoj marginalnoj gingivi kod prvoga desnog molara (Slika 1.). Bila je blago izdignuta, hrapave granulirane površine i žućkasta. Pacijentica je negirala sve medicinske probleme, a njezin najnoviji nalaz lipida u krvi pokazivao je vrijednosti u granicama normale. Zaključeno je da je riječ o papilomu ili verruciformnom ksantomu te je lezija potpuno eksicidirana. Mikroskopska analiza otkrila je nekoliko blago izdignutih papilarnih lezija čiji je epitel pokazivao papilomatozu i akantozu, a bio je prekriven debelim slojem parakeratina. Zupci epitela bili su produljeni do iste dubine, a u papilama vezivnog tkiva bilo je mnogo velikih makrofaga pjenaste citoplazme (Slika 2.). U dubljem vezivnom tkivu pronađene su upalne stanice. Ksantomatske stanice reagirale su snažno na CD 68 antitijela (Slika 3.). Godinu i pol nakon operativnog zahvata lezija se nije ponovno pojavila.

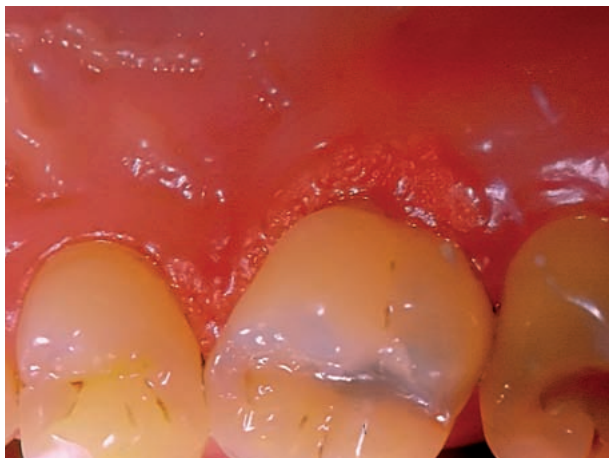
white (9, 10-12). Verruciform xanthomas of the oral cavity are usually encountered in the middle-aged persons. They afflict male patients slightly more than female patients. The majority of cases occur in the masticatory mucosa, especially the gingival (9, 11, 13).

Microscopically, epithelium shows papillomatosis, acanthosis and hyperparakeratosis with the elongation of the rete ridges to a uniform depth. No cytologic atypia is encountered in the lesion. The histological hallmark of this lesion is the accumulation of swollen macrophages with foamy cytoplasm (xanthoma cells) in the connective tissue papillae between epithelial rete ridges. There may be inflammatory cell infiltrate both in the epithelium and in the underlying connective tissue (6, 9, 10-15).

This article reports three cases of verruciform xanthoma, which have been diagnosed in the Department of Oral Pathology, School of Dentistry, Chulalongkorn University, Thailand.

Case 1

A 44-year-old female presented with a chief complaint of slight tenderness upon brushing at her right palate during the last two years. The patient had been treated with triamcinolone acetonide cream by a previous dentist, but her symptom was not improved. Intraoral examination revealed a papillary lesion, sized 3 x 12 mm² located at the palatal marginal gingiva of the upper right first molar (Fig 1). The lesion was slightly raised with a rough granular surface and yellowish in color. The patient denied any medical problems and her latest blood lipid profile was within normal limits. The clinical impression was papilloma or verruciform xanthoma. The lesion was totally excised. Microscopic examination revealed several slightly raised papillary lesions, the epithelium of which showed papillomatosis and acanthosis and was covered by thick layer of parakeratin. The rete ridges of the epithelium were elongated to a uniform depth. There were numerous large macrophages with foamy cytoplasm confined to the connective tissue papillae (Fig 2). Chronic inflammatory cells were found in deeper connective tissue. Xanthoma cells demonstrated strong reaction in the cytoplasm with antibody to CD 68 (Fig 3). No recurrence was noted one and a half year after the surgery.



Slika 1. Papilarna lezija veličine 3×12 mm² na palatinalnoj marginalnoj gingivi gornjega prvog desnog molara.

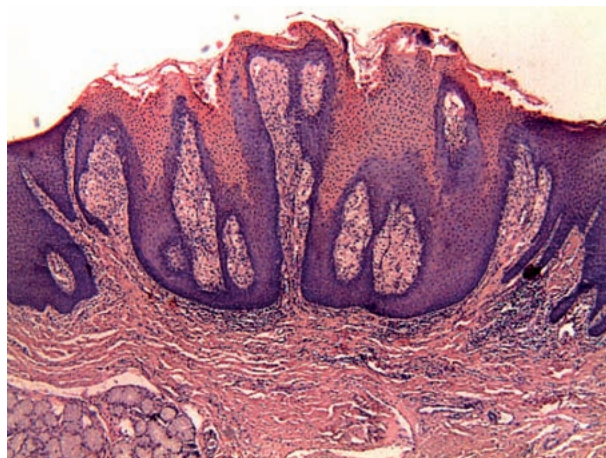Figure 1 A papillary lesion, sized 3 x 12 mm² located at the palatal marginal gingiva of the upper right first molar.

Drugi slučaj

Pacijent od 33 godine došao je na redovitu kontrolu te je njegov stomatolog uočio multiple lezije na lijevoj strani nepca u području premolara veličine 4×3 mm², a nalikivale su na cvjetaču. Tkivo je bilo blijedoružičasto i čvrsto. Pacijent nije imao nikakvih simptoma te nije bio svjestan lezije. No, rekao je da se tijekom spolnog odnosa s partnericom dogodio i oralni seks. Kliničke dijagnoze bile su condyloma acuminatum, verruca vulgaris te papilloma. Mikroskopski pregled otkrio je blago odignutu papilomatoznu leziju prekrivenu višeslojnim skvamoznim epitelom s produljenim zupcima jednake dubine. Nakupine ksantomskih stanica zapažene su u papilama vezivnog tkiva ispod epitelnog sloja (Slika 4.). Dodatno se u vezivnom tkivu mogao vidjeti upalni infiltrat. Ksantomske su stanice imale jaku reakciju na CD 68 antitijela (Slika 5.). Postavljena je dijagnoza veruciformnog ksantoma. Lezija je uklonjena kirurškim zahvatom, a pacijent nije imao recidiva tijekom petogodišnjih kontrola.

Treći slučaj

Pacijentica u dobi od 57 godina imala je malu papilarnu leziju veličine 1×2 cm² na palatinalnoj gingivi u razini 24 zuba. Bila je ružičasta i mekana, a uočila ju je prije dva mjeseca bez ikakvih drugih simptoma. Klinička dijagnoza bila je papilloma ili bradavica. Mikroskopska analiza otkrila je papilar-



Slika 2. Mikrofotografija koja prikazuje papilarnu leziju i produljene zupce. Nakupine ksantomskih stanica ograničene su na papile vezivnoga tkiva (Bojenje hematoxilinom i eozinom, originalno povećanje 40×).

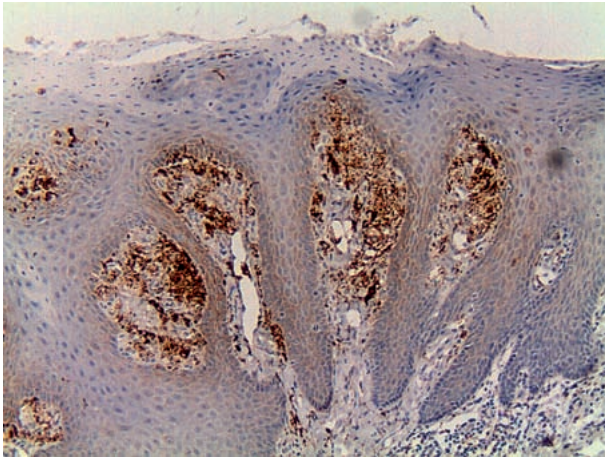
Figure 2 A photomicrograph showing a papillary lesion, the rete ridges of which extended to a uniform depth. Aggregates of xanthoma cells were confined to the connective tissue papillae. (Haematoxylin and eosin stain, original magnification 40x).

Case 2

A 33-year-old man underwent a routine dental check-up. His attending dentist noticed multiple cauliflower-like lesions at his left palate area #24&25, sized 4x3 mm². The lesional tissues were pale pink in color and firm in consistency. The patient reported no other symptoms and was unaware of the lesion. However, he gave a history of having oral sex. The clinical diagnoses were condyloma acuminatum, verruca vulgaris and papilloma. Microscopic examination revealed a slightly raised papillomatous lesion covered by stratified squamous epithelium, the elongated rete ridges of which extended to a uniform depth. Aggregates of xanthoma cells were observed in the connective tissue papillae underneath the epithelial layer (Fig 4). In addition, there was inflammatory cell infiltration in the underlying connective tissue. Xanthoma cells demonstrated strong reaction in the cytoplasm with antibody to CD 68 (Fig 5). The diagnosis was verruciform xanthoma. The patient was treated by surgical excision and there was no recurrence 5 years after the surgery.

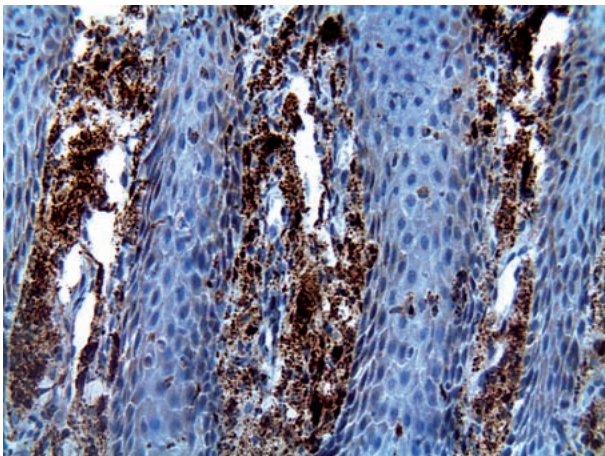
Case 3

A 57-year-old female patient had a small papillary lesion, sized 1x2 cm² at the palatal gingiva of tooth #24. It was pink in color and soft in consistency. The patient noticed that the lesion had been there for 2 months without any other symptom. The clinical diagnoses were papilloma or wart. Microscopic exam-



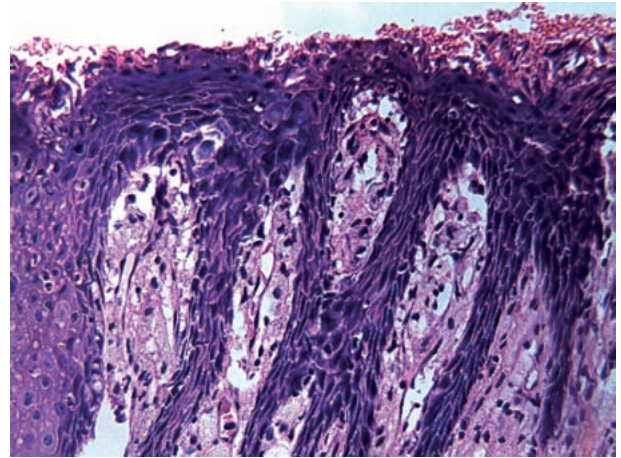
Slika 3. Mikrofotografija pozitivne reakcije na CD 68 antitijela u citoplazmi ksantomskih stanica (Bojenje imunoperoxidazom, originalno povećanje 100×).

Figure 3 A photomicrograph showing positive reaction with antibody to CD68 in the cytoplasm of xanthoma cells. (Immunoperoxidase stain, original magnification 100x).



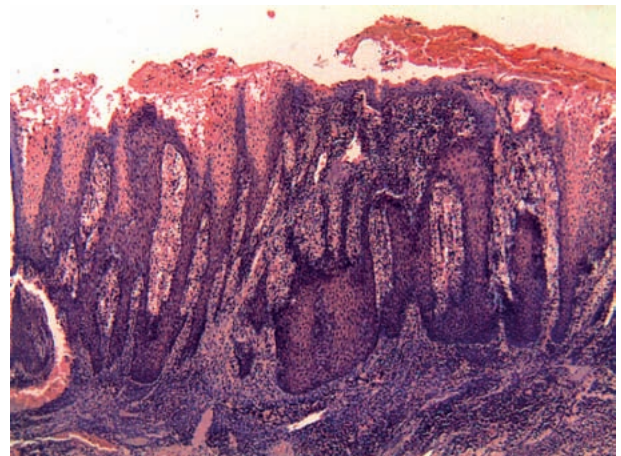
Slika 5. Mikrofotografija pozitivne reakcije na CD68 antitijela u citoplazmi ksantomskih stanica (Bojenje imunoperoxidazom, originalno povećanje 200×).

Figure 5 A photomicrograph showing positive reaction with antibody to CD68 in the cytoplasm of xanthoma cells. (Immunoperoxidase stain, original magnification 200x).



Slika 4. Mikrofotografija nakupina ksantomskih stanica između zubaca epitela (Bojenje hematoksilinom i eozinom, originalno povećanje 200×).

Figure 4 A photomicrograph showing aggregates of xanthoma cells between epithelial rete ridges. (Haematoxylin and eosin stain, original magnification 200x).



Slika 6. Mikrofotografija papilarne lezije prekrivene parakeratiniziranim epitelom s nakupinama ksantomskih stanica u papilama vezivnog tkiva te velikim infiltratom upalnih stanica u vezivnom tkivu (Bojenje hematoksilinom i eozinom, originalno povećanje 40×).

Figure 6 A photomicrograph showing a papillary lesion covered by parakeratinized epithelium with aggregates of xanthoma cells in the connective tissue papillae and massive inflammatory cell infiltrate in the underlying connective tissue. (Haematoxylin and eosin stain, original magnification 40x).

nu leziju prekrivenu parakeratiniziranim višeslojnim skvamoznim epitelom. Nakupine ksantomskih stanica dosezale su u vezivnom tkivu do kraja produljenih zubaca (Slika 6.), a u vezivnom su bile velike nakupine upalnih stanica i krvne žile. Dijagnoza je bila inficirani veruciformni ksantom. Lezija je uklonjena kirurški, a tijekom osmogodišnjeg praćenja recidiva nije bilo.

ination revealed papillary lesion covered by parakeratinized stratified squamous epithelium. There were aggregates of xanthoma cells in the connective tissue papillae extending as far as the tip of the elongated rete ridges (Fig 6). Massive chronic inflammatory cell infiltration and blood vessels proliferation were observed in the underlying connective tissue. The diagnosis was infected verruciform xanthoma. The patient was treated by surgical excision and there was no recurrence 8 years after the surgery.

Rasprava

Veruciformni ksantom može imati niz kliničkih slika. Kao rezultat lezije, Fordyceove granule, papilomi, *verruca vulgaris*, *condyloma acuminatum*, verukozni karcinom i karcinom skvamoznih stanica, mogu biti na popisu diferencijalnih dijagnoza za veruciformni ksantom. Fordyceove granule mogu se dijagnosticirati klinički, a mogu se diferencirati od ksantoma prema multiplim lezijama i predilekcijskim mjestima na bukalnoj mukozi i usnici, za razliku od solitarnih lezija na mastikatornoj mukozi kod veruciformnog ksantoma. U slučaju *condyloma acuminatum*, pozitivna anamneza za seksualni odnos jasno upućuje na dijagnozu. Ostatak lezija može se samo mikroskopskim pregledom razlikovati od veruciformnog ksantoma.

Papilom, *verruca vulgaris* i *condyloma acuminatum* ne sadržavaju ksantomske stanice, ali imaju koilocite kojih nema kod veruciformnog ksantoma. Dodatno su zadebljani zupci kod *condyloma acuminatum* i verukoznog karcinoma, za razliku od dugih i stanjenih kod veruciformnog ksantoma. Karcinom skvamoznih stanica može se razlikovati od veruciformnog ksantoma prema celularnoj atipiji, invaziji i nedostatku ksantomskih stanica. Važno je postaviti ispravnu dijagnozu kako se veruciformni ksantom ne bi zamijenio s verukoznim karcinomom ili karcinomom skvamoznih stanica. Na taj se način mogu izbjeći opsežni kirurški zahvati. Manje agresivna klinička slika može razlikovati veruciformni ksantom od verukoznog karcinoma ili karcinoma skvamoznih stanica. Dodatno, manjak predisponirajućih čimbenika u anamnezi, kao što je pušenje, alkohol ili kronična iritacija, također mogu pomoći da se postavi ispravna dijagnoza i eliminira verukozni karcinom ili karcinom skvamoznih stanica.

Točna etiologija veruciformnog ksantoma i dalje je nepoznata. Iako ima malo slučajeva veruciformnog ksantoma kod pacijenata s metaboličkim poremećajima (14), većina oboljelih nema hiperlipidemiju (10). Humani papiloma virus (HPV) također je mogući etiološki patogen zbog sklonosti veruciformnog ksantoma da se pojavljuje u istoj oralnoj i anogenitalnoj regiji kao infekcija HPV-om, ali i zbog kliničkog izgleda sličnog kondilomima. No, nekoliko postupaka - imunohistokemija, PCR te in-situ hibridizacija, kojima se pokušavalo otkriti HPV u veruciformnom ksantomu - bilo je bezuspješno (6, 9, 10, 15, 16). Iako su Khaskhely i suradnici (17) opisali uspješno otkrivanje DNK HPV-a tipa 6a u veruciformnom ksantomu na skro-

Discussion

Verruciform xanthoma may take after numerous lesions clinically. As a result, lesions such as Fordyce's granules, papilloma, *verruca vulgaris*, *condyloma acuminatum*, verrucous carcinoma and squamous cell carcinoma may enter the list of differential diagnosis for verruciform xanthoma. Fordyce's granules are almost diagnosed clinically. They can be differentiated from verruciform xanthoma clinically by their multiple lesions and different sites of predilection at buccal mucosa and lip as opposed to the solitary lesion and the masticatory mucosa site in verruciform xanthoma. In case of *condyloma acuminatum*, the history of sexual exposure tremendously guides toward this diagnosis. The rest of the lesions in the differential diagnosis list can only be differentiated from verruciform xanthoma by means of microscopic examination.

Papilloma, *verruca vulgaris* and *condyloma acuminatum* do not contain xanthoma cells, but do show koilocytes which are absent in verruciform xanthoma. In addition, the rete ridges in *condyloma acuminatum* and verrucous carcinoma are bulbous as opposed to the long and slender ones in verruciform xanthoma. Squamous cell carcinoma can be distinguished from verruciform xanthoma by its cellular atypia, invasion and lack of xanthoma cell. It is important that the accurate diagnosis is rendered in order not to misdiagnose verruciform xanthoma as verrucous carcinoma or squamous cell carcinoma to avoid unnecessary extensive surgical intervention. Less aggressive clinical features can distinguish verruciform xanthoma from verrucous carcinoma or squamous cell carcinoma. In addition, lack of predisposing factors such as cigarette smoking, alcohol consumption and chronic irritation can help rule out verrucous carcinoma or squamous cell carcinoma.

The exact etiology of verruciform xanthoma remains unknown. Although there are a few cases of verruciform xanthoma occurring in patients with metabolic disorders (14), the majority of patients do not have hyperlipidemia (10). Human papilloma virus (HPV) is also suspected as the putative etiological pathogen due to the proclivity of verruciform xanthoma to occur in the same oral and anogenital region as in HPV infection and the condyloma-like clinical appearance. However, several attempts like immunohistochemistry, PCR and in situ hybridization, to detect HPV in verruciform xanthoma are fruitless (6, 9, 10, 15, 16). Even though Khaskhely et al (17) reported the successful detection of HPV type 6a DNA in verruciform xanthoma of the scrotum of one male

tumu jednog pacijenta, a Iamaroon i Vickers (18) pronašli su samo jedan HPV tip 6/11 kod 12 uzoraka veruciformnog ksantoma pomoću in-situ hibridizacije, postavlja se pitanje je li HPV bio kontaminant (15), budući da je sveprisutan te se može izolirati čak i iz normalnog tkiva (19). Postoje dvije glavne teorije o etiologiji veruciformnog ksantoma. Zegarelli sa suradnicima (14) smatra da se prije stvaranja ksantomskih stanica razara epitel. Oni drže da se tijekom ljuštenja epitela "zarobljavaju" stanice u kriptama na površini te one zatim otpuštaju svoje lipide. Oni prolaze kroz epitel te ih na kraju razaraju makrofagi koji se diferenciraju u ksantomске stanice. Tu teoriju podupiru dokazi dobiveni elektroničkim nalazom epitelne degeneracije, otečenih mitohondrija, dilatacije endoplazmatskog retikuluma i Golgijeve uređaja, te razaranjem spojnog kompleksa i činjenica da se većina veruciformnih ksantoma nalazi u mastikatornoj sluznici koja je neprestance pod traumom i senzibilizirajućim agensima iz hrane (9). Nowparast i suradnici (12), pak, ističu da verukozna i papilarna građa nastaju zbog ksantomskih stanica. Sama njihova prisutnost u papilama vezivnog tkiva utječe na prehranu i metabolizam epitelnih stanica, što rezultira parakeratotičnim stanicama, preanom eksfolijacijom te stvaranjem kripta.

Možemo zaključiti da je veruciformni ksantom rijetka benigna oralna lezija. Iako mu patogeneza nije jasna, čini se da nastaje zbog inflamatorne reakcije, a ne virusne infekcije. Klinički se može zamijeniti s papilom, a katkad i s verukoznim karcinomom ili karcinomom skvamoznih stanica. Definitivna se dijagnoza može postaviti samo na temelju karakterističnog histološkog nalaza. Zato kliničari moraju poznavati tu leziju kako ne bi obavljali nepotrebne opsežne kirurške intervencije.

patient and Iamaroon and Vickers (18) found only 1 HPV type 6/11 in 12 specimens of verruciform xanthoma by in situ hybridization, these raise the possibility that HPV they detected may be a contaminant since HPV is a ubiquitous organism and can be isolated even from normal tissue (15,19). There are two major theories accounting for the etiology of verruciform xanthoma. Zegarelli et al (14) hypothesized that the epithelial breakdown preceded the formation of xanthoma cells. They proposed that the epithelial which was shed and entrapped in the crypts or along the epithelial surfaces degenerated and released its lipid contents. The lipids permeated through the epithelium and were finally scavenged by macrophages which transformed themselves into xanthoma cells. This theory is supported by the electronmicroscopic evidence of epithelial degeneration such as swollen mitochondria, dilation of endoplasmic reticulum and golgi apparatus as well as the disruption of junctional complex and the fact that the majority of verruciform xanthoma cases occurs in the masticatory mucosa which is constantly subjected to trauma and the sensitizing agents of food stuff (9). On the contrary, Nowparast et al (12) suggested that the verrucal and papillary architecture may be secondary to the presence of xanthoma cells. The presence of xanthoma cells in the connective tissue papillae affected the nutrition and metabolism of epithelial cells leading to the formation of parakeratotic cells as well as premature exfoliation of these cells and crypt formation.

In conclusion, verruciform xanthoma is a rare benign oral lesion. Although its pathogenesis remains unclear, it is likely to be the result of inflammatory reaction rather than viral infection. Clinically, it may be misdiagnosed as papilloma, and occasionally as verrucous carcinoma or squamous cell carcinoma. The definitive diagnosis can only be obtained through its distinct histological features. Therefore, clinicians should be aware of this lesion to avoid an unnecessary excessive surgical intervention.

Abstract

Verruciform xanthoma is a relatively uncommon mucocutaneous lesion. Most of the reported cases occur in masticatory oral mucosa, especially the gingiva. This article reports three cases of verruciform xanthoma, all of which were located in the palatal gingiva. The lesions were small and painless. Two were papillary lesions, and the other was cauliflower-like. Histological examinations revealed papillomatosis and acanthosis associated with xanthoma cell aggregation within connective tissue papillae. Xanthoma cells were positive to CD 68 antibody, indicating a macrophage origin. All lesions were treated by conservative surgical excision, and no recurrence was observed. Differential diagnosis and pathogenesis of verruciform xanthoma are discussed. In some cases, its clinical appearance may resemble verrucous carcinoma or squamous cell carcinoma. Therefore, clinicians should be acquainted with this lesion to avoid an unnecessary excessive surgical intervention.

Received: September 18, 2006

Accepted: November 21, 2006

Address for correspondence

Dr. Kittipong Dhanuthai
Chulalongkorn University
School of Dentistry
Department of Oral Pathology
Henri Dunant Rd.
Patumwan District, Bangkok 10330,
Thailand
Tel : 662-2188801
Fax: 662-2188798
fibroma123@yahoo.com

Key words

Xanthomatosis; Gingiva; Melanosis;
Papilloma

References

1. Shafer WG. Verruciform xanthoma. *Oral Surg Oral Med Oral Pathol.* 1971;31(6):784-9.
2. Santa Cruz DJ, Martin SA. Verruciform xanthoma of the vulva. Report of two cases. *Am J Clin Pathol.* 1979;71(2):224-8.
3. Xia TL, Li GZ, Na YQ, Guo YL. Verruciform xanthoma of the penis: report of a case. *Chin Med J (Engl).* 2004;117(1):150-2.
4. Herrera-Goepfert R, Lizano-Soberon M, Garcia-Perales M. Verruciform xanthoma of the esophagus. *Hum Pathol.* 2003;34(8):814-5.
5. Than T, Birch PJ, Dawes PJ. Verruciform xanthoma of the nose. *J Laryngol Otol.* 1999;113(1):79-81.
6. Mohsin SK, Lee MW, Amin MB, Stoler MH, Eyzaguirre E, Ma CK et al. Cutaneous verruciform xanthoma: a report of five cases investigating the etiology and nature of xanthomatous cells. *Am J Surg Pathol.* 1998;22(4):479-87.
7. Jensen JL, Liao SY, Jeffes EW 3rd. Verruciform xanthoma of the ear with coexisting epidermal dysplasia. *Am J Dermatopathol.* 1992;14(5):426-30.
8. Nakamura S, Kanamori S, Nakayama K, Aoki M. Verruciform xanthoma on the scrotum. *J Dermatol.* 1989;16(5):397-401.
9. Philipsen HP, Reichart PA, Takata T, Ogawa I. Verruciform xanthoma--biological profile of 282 oral lesions based on a literature survey with nine new cases from Japan. *Oral Oncol.* 2003;39(4):325-36.
10. Sopena J, Gamo R, Iglesias L, Rodriguez-Peralto JL. Disseminated verruciform xanthoma. *Br J Dermatol.* 2004;151(3):717-9.
11. Hu JA, Li Y, Li S. Verruciform xanthoma of the oral cavity: clinicopathological study relating to pathogenesis. Report of three cases. *APMIS.* 2005;113(9):629-34.
12. Nowparast B, Howell FV, Rick GM. Verruciform xanthoma. A clinicopathologic review and report of fifty-four cases. *Oral Surg Oral Med Oral Pathol.* 1981;51(6):619-25.
13. Oliveira PT, Jaeger RG, Cabral LA, Carvalho YR, Costa AL, Jaeger MM. Verruciform xanthoma of the oral mucosa. Report of four cases and a review of the literature. *Oral Oncol.* 2001;37(3):326-31.
14. Zegarelli DJ, Zegarelli-Schmidt EC, Zegarelli EV. Verruciform xanthoma. Further light and electron microscopic studies, with the addition of a third case. *Oral Surg Oral Med Oral Pathol.* 1975;40(2):246-56.
15. Agarwal-Antal N, Zimmermann J, Scholz T, Noyes RD, Leachman SA. A giant verruciform xanthoma. *J Cutan Pathol.* 2002;29(2):119-24.
16. Orchard GE, Wilson Jones E, Russell Jones R. Verruciform xanthoma: an immunocytochemical study. *Br J Biomed Sci.* 1994;51(1):28-34.
17. Khaskhely NM, Uezato H, Kamiyama T, et al. Association of human papillomavirus type 6 with a verruciform xanthoma. *Am J Dermatopathol.* 2000;22(5):447-52.
18. Iamaroon A, Vickers RA. Characterization of verruciform xanthoma by in situ hybridization and immunohistochemistry. *J Oral Pathol Med.* 1996;25(7):395-400.
19. Antonsson A, Forslund O, Ekberg H, Sterner G, Hansson BG. The ubiquity and impressive genomic diversity of human skin papillomaviruses suggest a commensalic nature of these viruses. *J Virol.* 2000;74(24):11636-41.