

## INTRAVESICAL FOREIGN BODY AS A RESULT OF SELF CATHETERIZATION: CASE REPORT

Igor Grubišić, Goran Štimac, Ivan Pezelj, Ivan Svaguša, Josip Katušić and Borislav Spajić

Clinical Department of Urology, Sestre milosrdnice University Hospital Center, Zagreb, Croatia

**SUMMARY** – Foreign bodies inside urinary tract are a relatively rare condition in our practice. There are several reports published and in most cases the reason for self insertion of an object was autoerotic stimulation or psychiatric illness. Self treatment by homemade instruments is a rarely seen scenario. A 62-year-old man presented to our department complaining of lower urinary tract symptoms. On examination, a foreign body was detected inside the urinary bladder. Urethral stricture was also detected for which the patient had been previously treated on several occasions. The patient stated that he had attempted self catheterization using a homemade catheter. He had succeeded in emptying his bladder; however, the catheter entered the bladder completely and was irretrievable to him. Sachse urethrotomy was performed following retrieval of the foreign body. No psychiatric illness was detected in our patient. The patient's postoperative course was uneventful.

**Key words:** *Urinary bladder; Foreign bodies – complications; Foreign bodies – therapy; Intermittent urethral catheterization; Urethrotomy; Case reports*

### Introduction

Foreign bodies inside urinary tract are a relatively rare condition. Introduction into the bladder may be through self-insertion, iatrogenic means, or migration from adjacent organs<sup>1</sup>. The motives for self-insertion are most commonly autoerotic stimulation, psychiatric illness and drug abuse and, in this case, attempts of self catheterization. In this group of patients, items such as electric wire, safety pin, hairclip, battery, leech, hairballs, and even fish have been discovered<sup>2</sup>. In cases of iatrogenic insertion, surgical gauze, pieces of Foley catheter, teflon beak of resectoscope sheath, and intrauterine contraceptive devices were found<sup>2</sup>. The leading symptoms are usually pain, urinary frequency, dysuria, hematuria, and urinary retention<sup>3</sup>. There are several methods of extraction. In most cas-

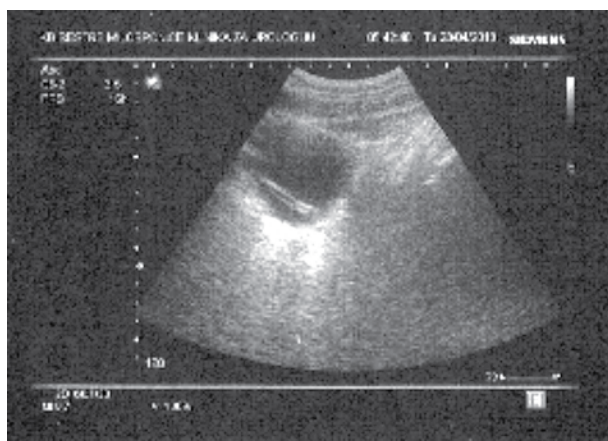
es, endoscopic method is used<sup>4</sup>; however, there are reports where percutaneous and even open surgery was needed to successfully extract the object.

### Case Report

A 62-year-old man presented to our department complaining of dysuria, thin urinary stream and hematuria. He had been treated several times for urethral stricture. Recurrent strictures were the result of a polytrauma that included pelvic fractures and trauma to the urethra followed by open urethra surgery. Since then, multiple urethrotomy using Sachse knife had been performed, most recently three years before his present symptoms began. Standard examination was performed, which included ultrasound examination of the bladder, where a long coiled foreign body was visualized (Fig. 1). The patient stated that he had used a piece of silicone insulated rope from which he had removed the fiber interior, thus ending up with a silicone tube 5 mm in diameter to self catheterize himself in an attempt to relieve his aforementioned

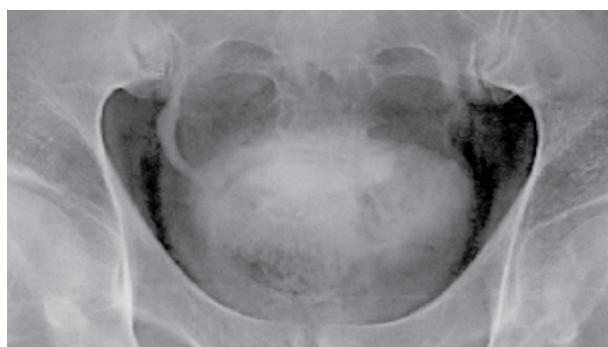Correspondence to: *Igor Grubišić, MD*, Clinical Department of Urology, Sestre milosrdnice University Hospital Center, Vinsogradska c. 29, HR-10000, Zagreb, Croatia  
E-mail: igor.grubisic2@zg.t-com.hr

Received November 26, 2013, accepted January 21, 2014



*Fig. 1. Ultrasonographic image of the urinary bladder showing the foreign body.*

symptoms. His behavior gave no indication of psychiatric illness, drug abuse or erotic stimulation intent. The self-made catheter slid up the urethra and coiled itself in the bladder. Complete examination was performed, followed by intravenous pyelography and mycturition cystourethrography (Fig. 2). There was no evidence for intravesical calculus. No significant pathologic results were found except for the foreign body and urethral stricture of 2 cm in length. A permanent catheter was placed to allow urine flow until the procedure. Urethroscopy was done with a 22.5 cm cystoscopic sheath and 12 degree scope. The patient had a stricture in the bulbomembranous part of the urethra. Internal urethrotomy using Sachse knife was then performed, followed by cystoscopy. The stricture itself was of rigid consistency resembling cartilage. A piece of silicone insulation approximately 30 cm long was located inside the urinary bladder (Fig. 3). No in-




*Fig. 2. Cystogram phase of intravenous pyelography showing a long coiled tube without urethral extension.*

juries or mucosa defects were observed. The tube was extracted using a calculus forceps and a Ch. 18 Foley catheter was placed. Prophylactic antibiotics were administered. There were no postoperative complications. The patient was discharged from the hospital three days after the procedure. When the catheter was removed, on follow up two weeks after the procedure, the patient could urinate without difficulties.

## Discussion

Intravesical foreign bodies are a rare condition in our practice. Although usually self-introduced with a motive of sexual gratification, in this case the reason was self-treatment. The patient's behavior gave no indication of possibly undiagnosed psychiatric condition or that autoerotic stimulation was intended. There are numerous reports, dating back to the 19<sup>th</sup> century, of most unusual foreign bodies imaginable including light bulbs, different tools and even fish. With the object, microorganisms are introduced into the bladder, so recurrent infections are common. The shape and consistency of the object are important for both explaining the symptoms and choosing the method of extraction. For example, if the object is sharp, it will cause injuries to the lower urinary tract, so hematuria will be the leading symptom and can be massive with systemic consequences such as anemia or hypovolemic shock. Extracting such a body without considering the possible complications can cause severe intraoperative injuries. Sometimes the object is too large to extract with minimally invasive techniques. In those



*Fig. 3. The extracted silicone tube was approximately 30 cm in length.*

cases, fragmentation is attempted (*via* laser or using endoscopic instruments) to retrieve the object piece by piece, but sometimes open surgery is required<sup>5</sup>. In some cases, cystoscopy and cystotomy were used in combination to remove the objects too large to retrieve through the urethra and too solid to fragment them<sup>6</sup>.

Our patient is specific as he attempted to copy the catheterization procedure he had seen performed on him multiple times. Although self-treatment related complications are common in everyday practice, we found no case report on attempting self catheterization with a homemade catheter without proper training.

Introduction of foreign bodies into the bladder may be through self-insertion, as a result of medical procedures, migration from adjacent organs and trauma. Extraction methods should be tailored according to the nature of the foreign body and the specific anatomy to minimize bladder and urethral trauma. An intravesical foreign body should be considered as a possible diagnosis in any patient with chronic unexplained lower urinary tract symptoms.

## References

1. ECKFORD SD, PERSAD RA, BREWSTER SF, GINGELL JC. Intravesical foreign bodies: five-year review. *Br J Urol* 1992;69(1):41-5.
2. DATTA B, GHOSH M, BISWAS S. Foreign bodies in urinary bladders. *Saudi J Kidney Dis Transpl* 2011;22:302-5.
3. PAL DK, BAG AK. Intravesical wire as foreign body in urinary bladder. *Int Braz J Urol* 2005;31:472-4.
4. RAFIQUE M. Intravesical foreign bodies: review and current management strategies. *Urol J* 2008;5:223-31.
5. HABERMACHER G, NADLER RB. Intravesical holmium laser fragmentation and removal of detached resectoscope sheath tip. *J Urol* 2005;174:1296-7.
6. DeLAIR SM, BERNAL RM, KEEGAN KA, ELLISON LM. Ship in a bottle: rapid extraction of large intravesical foreign bodies. *Urology* 2006;67:612-3.

## Sažetak

### STRANO TIJELO U MOKRAĆNOM MJEHURU KAO ISHOD SAMOKATETERIZACIJE: PRIKAZ SLUČAJA

*I. Grubišić, G. Štimac, I. Pezelj, I. Svaguša, J. Katušić i B. Spajić*

Strana tijela unutar mokraćnog sustava su relativno rijetko stanje u našoj praksi. U većini objavljenih slučajeva razlog umetanja stranog tijela je autoerotska stimulacija ili psihijatrijska bolest. Umetanje stranog tijela kao povod za rješavanje mokraćne opstrukcije je rijedak događaj. Bolesnik u dobi od 62 godine javio se na našu kliniku zbog simptoma donjeg mokraćnog trakta. Tijekom pregleda otkriveno je strano tijelo unutar mokraćnog mjehura. Kod bolesnika je u više navrata rađena unutarnja uretrotomija, a jednom otvorena operacija uretre s terminoterminalnom anastomozom. Bolesnik je naveo da je pokušao samokateterizaciju s improviziranim kateterom. Uspio je riješiti mokraćnu opstrukciju, no dio stranog tijela je zaostao u mokraćnom mjehuru. Nakon dodatne obrade učinjena je unutarnja uretrotomija po Sachseu s ekstrakcijom stranog tijela iz mokraćnog mjehura. Psihijatrijskih bolesti se kod bolesnika ne nalazi.

Ključne riječi: *Mokraćni mjehur; Strana tijela – komplikacije; Strana tijela – terapija; Intermitentna uretralna kateterizacija; Uretrotomija; Prikazi slučaja*