

# Rheumatic heart disease with triple valve involvement

**MATTEO BRAMBATI • FIORANGELA MARLETTA • GIORGIA MANINA • DENISE PROVVIDENZA COMINA • NGAMBE MANDI PRESTON • GIUSEPPINA CASSETTI • CHIARA MERLO • MICHELE VOLPI • ROBERTA MUSSO • PIER FRANCESCO LAURENZI • ROBERTO LA ROCCA**

MATTEO BRAMBATI (✉) •  
PIER FRANCESCO LAURENZI  
Università degli studi di Milano  
Facoltà di medicina e chirurgia  
Via Kennedy 18  
20097 San Donato Milanese  
Milano (MI), Italy  
Phone: +39 328-80 28 910  
E-mail: brambati@hotmail.it

FIORANGELA MARLETTA •  
GIORGIA MANINA •  
DENISE PROVVIDENZA COMINA • NGAMBE  
MANDI PRESTON •  
GIUSEPPINA CASSETTI •  
CHIARA MERLO •  
MICHELE VOLPI •  
ROBERTA MUSSO •  
ROBERTO LA ROCCA  
Emergency department, IRCCS Policlinico  
San Donato, San Donato Milanese, Italy

## ABSTRACT

*Acute rheumatic fever (ARF) is a postinfectious, nonsuppurative sequela of pharyngeal infection caused by Streptococcus pyogenes, or Group A  $\beta$  hemolytic Streptococcus (GABHS). Of the associated symptoms, only damage to the heart's valvular tissue, or rheumatic heart disease (RHD), can become a chronic condition leading to congestive heart failure, stroke, endocarditis, and death. ARF is the most common cause of cardiac disease in children in developing countries. A joint meeting of the World Health Organization and the International Society estimated that 12 million people in developing countries were affected by acute rheumatic fever and rheumatic heart disease, with the majority of these being children. This level of morbidity is comparable to developed countries' in the last century, before an increase in the standard of living and the introduction of penicillin. Significant trivalvular disease, involving the mitral, aortic and tricuspid valves, is uncommon. Although rare, trivalvular disease has been described in the literature. Clinical and hemodynamic manifestations depend on the severity of each lesion. We reported this case because of the rare presentation of an uncommon disorder and to highlight the fact that the presence of trivalvular disease can be difficult to diagnose, even for a trained physician.*

**Key words:** rheumatic heart disease, triple valve disease, rheumatic valve disease

## Introduction

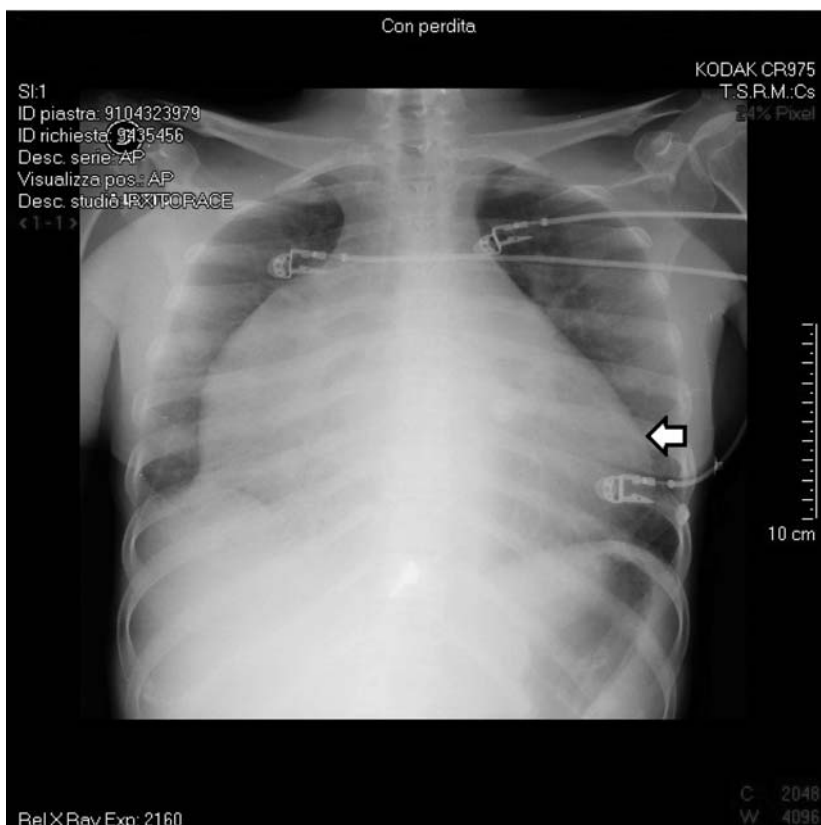
Acute rheumatic fever (ARF) is a postinfectious, nonsuppurative sequela of pharyngeal infection caused by Streptococcus pyogenes, or Group A  $\beta$  hemolytic Streptococcus (GABHS). Of the associated symptoms, only damage to the heart's valvular tissue, or rheumatic heart disease (RHD), can become a chronic condition. A joint meeting of the World Health Organization estimated that 12 million people in developing countries were affected by acute rheu-

matic fever and rheumatic heart disease, with the majority of these being children. This level of morbidity is comparable to that in developed countries' in the last century, before the introduction of penicillin. (1) RHD is the most common cause of mitral stenosis (MS) in adults in developing countries (2) but it is also the most common cause of multivalvular disease. About 60% of patients with rheumatic MS have concurrent mild-to-moderate aortic insufficiency (AI), and 10% of patients with rheumatic MS have concurrent severe AI. (3) The presence of concomitant AI may augment the volume of mitral regurgitation (MR) flow leading to left ventricle (LV) enlar-

gement. The presence of both severe MR and severe AI is poorly tolerated. Significant trivalvular disease involving mitral, aortic and tricuspid valves is uncommon. Although rare, trivalvular disease has been described in the literature. We reported this case because of the rare presentation of an uncommon disorder and to highlight the fact that the presence of trivalvular disease can be difficult to diagnose, even for a trained physician.

## Case report

A 19-year-old Senegalese female presented to our Emergency Department in April 2013 complaining of dyspno-



**Figure 1. Chest radiography demonstrating cardiomegaly.**

ea and severe hypotension. Her vital signs included an undetectable blood pressure, heart rate of 115 beats/min and oxygen saturation of 100% while receiving 9 l/min oxygen via a simple face mask. On examination, she had severe mental deterioration, heart sounds were dysrhythmic and tachycardic but without murmur, bruit or rubs, and her lungs demonstrated a diminished vesicular murmur bilaterally. Hemoglobin was 11.9 g/dl and hematocrit was 34.8%. Her 12 lead electrocardiogram showed atrial fibrillation with a prominent R and S wave in all leads. Chest radiography revealed an extremely large heart with a prominent aortic knob and four chamber enlargement (figure 1). An echocardiography examination and a cardiology consultation were arranged. Echocardiography revealed severe bilateral atriomegaly, severe MS, concentric left ventricle hypertrophy with reduced ejection fraction (48%), mild AI, severe tricuspid insufficiency, peri-

cardial and pulmonary effusion and a thrombus in the left atrium. Following the echocardiography examination, the patient was given low molecular weight heparin (5000 IU) to avoid artery embolization and admitted to the cardiology intensive care unit. In the following days she underwent triple surgical valve repair. After surgical reparation of both the aortic and mitral valve and substitution of the tricuspid valve, the patient experienced three episodes of paroxysmal supraventricular tachycardia. Each episode ended spontaneously. The patient was immediately treated with high doses of diuretics (furosemide 160 mg per day and potassium canrenoate 50 mg per day), oral anticoagulant (acenocoumarol 4 mg per day), nitrates (nitroglycerine 60 mg per day) and carbonic anhydrase inhibitor (acetazolamide 500 mg per day). Two months after surgery, echocardiography demonstrated the absence of tricuspid insufficiency, mild AI, mild mitral insufficiency, normalization of left

ventricular function with an ejection fraction of 55%. Final oral therapy included diuretics (furosemide 75 mg per day and potassium canrenoate 25 mg per day), ACE inhibitor (ramipril 5 mg per day), beta blocker (bisoprolol 1.25 mg per day), oral anticoagulant (acenocoumarol 1 mg per day) and proton pump inhibitor (omeprazole 20 mg per day).

## Discussion

### Pathophysiology

The role of GABHS infection as an initial event is clear, and has been supported by outbreaks of ARF following pharyngitis, as well as rising antistreptococcal antibodies in patients with ARF. (4) ARF is believed to be an autoimmune reaction to GABHS infection. In 1945 anti-cardiac autoantibodies were identified. These antibodies could damage host tissue without the continued presence of streptococci. In 1962, cross-reactivity between human heart tissue and GABHS was demonstrated. This cross-reactivity is believed to occur through molecular mimicry: in ARF and RHD, the foreign antigen is the M-protein and it cross reacts with cardiac myosin. Although all four heart valves can be involved in rheumatic carditis, there is marked predominance of mitral valve involvement. The reason for this prevalence is yet unknown. Once heart valves have been damaged, blood is allowed to regurgitate. This can cause acute congestive heart failure, which can be the presenting symptom of ARF. Patients that recover from initial rheumatic carditis are likely to have permanent valve damage in the form of stenosis or regurgitation. RHD is the most common cause of MS. MS typically induces a pressure overload in the left atrium, which leads to progressive atrial dilatation and, finally, to the creation of a profibrillatory environment in the left atrium that manifests clinically as atrial fibrillation. The other main features of MS are the development of pulmonary hypertension (5) and tricuspid regurgitation (TR). (6) More than one third of patients with MS have been reported to have at least moderate TR. (7) Atrial fibrillation is a common dysrhythmia in

patients with MS (8) and predisposes a patient to the development of TR.

#### Diagnosis

The diagnostic criteria for ARF were first developed by Jones in 1944 (9) and have been modified several times. The criteria are divided into Major and Minor criteria. Diagnosis is made by the presence of either 2 Major or 1 Major and 2 Minor criteria, plus evidence of recent streptococcal infection, either by a pharyngeal swab culture positive for GABHS or positive rapid GABHS antigen test.

#### Therapy

Patients with known chronic valvular RHD are managed individually accor-

ding to lesion severity, location, and number of valves involved. Nonsurgical recommendations include restriction of physical exertion in symptomatic patients to reduce cardiovascular load and prophylactic antibiotics to prevent endocarditis. Medical therapy for patients with MS aims to reduce heart rate and decrease blood volume with beta-blockers, cautious use of oral diuretics, and even digoxin if atrial fibrillation is present. Significant trivalvular disease involving mitral, aortic, and tricuspid valves is uncommon. Yet, for those presenting with advanced heart failure it is recommended that all three valvular lesions should be surgically corrected.

Triple valve replacement is long and complex with mortality reported being between 20% and 40%. (10) Although improved surgical techniques have evolved, declining mortality rates, triple valve replacement is usually avoided. Our patient underwent tricuspid substitution and plastic surgery of the mitral and aortic valve.

### Conclusion

RHD is an uncommon pathology in developed countries, for this reason we chose to report what we saw. This manuscript aims to remind all clinicians that sooner or later they may come across a forgotten disease.

---

## REFERENCES

1. Kumar R. Controlling rheumatic heart disease in developing countries. *World Health Forum* 1995;16:47–51.
2. Hameed AB, Tummala PP, Goodwin TM, Nuno I, Wani OR, Karaalp IS, et al. Valvular disease in pregnancy: Effects on maternal and fetal outcome. *Circulation* 1999;100:1-148.
3. Gash AK, Carabello BA, Kent RL, Frazier JA, Spann JF. Left ventricular performance in patients with coexistent mitral stenosis and aortic insufficiency. *J Am Coll Cardiol* 1984;3:703.
4. Cunningham MW. Pathogenesis of group A streptococcal infections. *Clin Microbiol Rev* 2000;13:470–511.
5. Fawzy ME, Osman A, Nambiar V, Nowayhed O, Badr A, Canver CC. Immediate and long-term results of mitral balloon valvuloplasty in patients with severe pulmonary hypertension. *J Heart Valve Dis* 2008 Sep;17(5):485-91.
6. Song JM, Kang DH, Song JK, Jeong YH, Lee CW, Hong MK, et al. Outcome of significant functional tricuspid regurgitation after percutaneous mitral valvuloplasty. *Am Heart J* 2003 Feb;145(2):371-6.
7. Sagie A, Freitas N, Chen MH, Marshall JE, Weyman AE, Levine RA. Echocardiographic assessment of mitral stenosis and its associated valvular lesions in 205 patients and lack of association with mitral valve prolapse. *J Am Soc Echocardiogr* 1997 Mar;10(2):141-8.
8. Kim HK, Kim YJ, Kim KI, Jo SH, Kim KB, Ahn H, et al. Impact of the maze operation combined with left-sided valve surgery on the change in tricuspid regurgitation over time. *Circulation* 2005 Aug 30;112(9 Suppl):114-9.
9. Jones TD. Diagnosis of rheumatic fever. *JAMA* 1944;126:481–4.
10. Coll-Mazzei JV, Jegaden O, Janody P, Rumolo A, Bonnefoy JY, Mikaeloff P. Results of triple valve replacement: perioperative mortality and long term results. *J Cardiovasc Surg* 1987 Jul-Aug;28(4):369-73.